

Letters

Singing in the brain: a new form of complex partial seizure?

Sir: The occurrence of verbal automatisms during complex partial seizures (CPS) is well known.¹⁻⁴ Whistling and humming have been described but singing is rare.³ We report a case of "forced singing" in a patient with a left mesial frontal lobe tumour.

A 51 year old right-handed woman developed focal motor seizures on the right side at the age of 36 and was treated with phenobarbitone. Four years later she developed a frontal lobe syndrome. The CT scan showed a large infiltrating lesion of the left frontal lobe, corpus callosum, and a small portion of the right frontal lobe. Calcification was present but no mass effect or contrast enhancement. The lesion appeared to be an oligodendroglioma, but the patient refused a biopsy. She was treated by teniposide and carmustine chemotherapy until the age of 43, with clinical improvement, but the radiological aspect of the tumour remained unchanged. When she was 51 years she complained of episodes of "forced singing" which occurred several times a day. She recalled either humming or "singing in her brain" followed by loud *a capella* singing. The lyrics were usually related to her activities and the melodies, though varied, were always familiar. Neither her mood nor the surrounding events could influence the spells nor could she voluntarily stop or change the tune. The episodes frequently occurred while falling asleep, and their number increased when she forgot to take her anticonvulsant drugs. One episode, which was witnessed, occurred when the patient was sitting quietly on her bed. She produced a clear humming with no recognisable melody or lip movements. The onset was sudden with no prodromal symptoms, lasted one minute and ended abruptly. During the episode the patient did not lose consciousness but was unable to read, answer questions or follow commands. She could remember her conversation before the episode but not the details. When the humming stopped, she remained confused for less than one minute. Physical examination showed frontal lobe-like signs such as reduced spontaneous activity, distractibility, perservations, utilisation and imitation behaviour and reduced verbal fluency. Sphincter control was normal. On the CT and MRI scans there was no evidence of additional tumour growth and the temporal lobes appeared normal (figure). Standard

external EEG recordings showed bilateral intermittent slow waves, more marked on the left side. No forced singing was recorded during the EEG sessions. The episodes stopped when valproate and phenobarbital were administered.

Transient compulsions (urge to move or shout) have been observed with frontal lobe lesions.⁵ The forced singing observed in our patient cannot be considered a compulsive disorder, however, since the patient could not automatically stop or modulate the song. An epileptic origin is therefore the most probable explanation. The attacks were intermittent, of short duration with sudden onset and termination. They occurred during the evening and responded to anticonvulsant therapy. The clinical features were different from the musical hallucinations reported recently in a patient with a frontal lobe meningioma.⁶ Our patient may have experienced a CPS, since verbal automatisms (singing is rare), partial loss of contact with the environment, partial amnesia concerning the event were observed.^{1,3} CPS are produced by frontal and temporal lesions.³ Vocal and musical hallucinations have been obtained by stimulating the supplementary motor area and the temporal lobes, respectively.⁷ The forced singing described in this patient may thus have resulted from frontal dysfunction leading to "impaired modulation of the temporal lobe structures" as proposed by Keshavan, *et al.*⁶

The authors thank Dr J Bancaud for his helpful advice.

MARIE VIDAILHET,
MICHEL SERDARU,
YVES AGID

Clinique de Neurologie and INSERM U 289,
Hôpital de la Salpêtrière,
47 boulevard de l'Hôpital,
75651 Paris CEDEX 13,
France

References

- 1 Geier S, Bancaud J, Talairach J, Bonis A, Szikla G, Enjelvin M. The seizures of frontal lobe epilepsy: a study of clinical manifestations. *Neurology* 1977;27:951-8.
- 2 Williamson PD, Spencer DD, Spencer SS, Novelly RA, Mattson RH. Complex partial seizures of frontal lobe origin. *Ann Neurol* 1985;18:497-504.
- 3 Theodore WH, Porter R, Penry JK. Complex partial seizures: clinical characteristics and differential diagnosis. *Neurology* 1983;53:115-21.
- 4 Waterman K, Purves SJ, Kosaka B, Strauss E, Wada JA. An epileptic syndrome caused by mesial lobe foci. *Neurology* 1987;37:577-82.
- 5 Ward CD. Transient feelings of compulsion caused by hemispheric lesions: 3 cases. *J Neurol Neurosurg Psychiatry* 1988;5:266-8.
- 6 Keshavan MS, Khan EM, Barr J. Musical hallucinations following removal of a right frontal meningioma. *J Neurol Neurosurg Psychiatry* 1988;51:1235-6.
- 7 Penfield W, Jasper H. *Epilepsy and the functional anatomy of the human brain*. Boston: Little and Brown, 1954.

Correspondence to Y Agid.

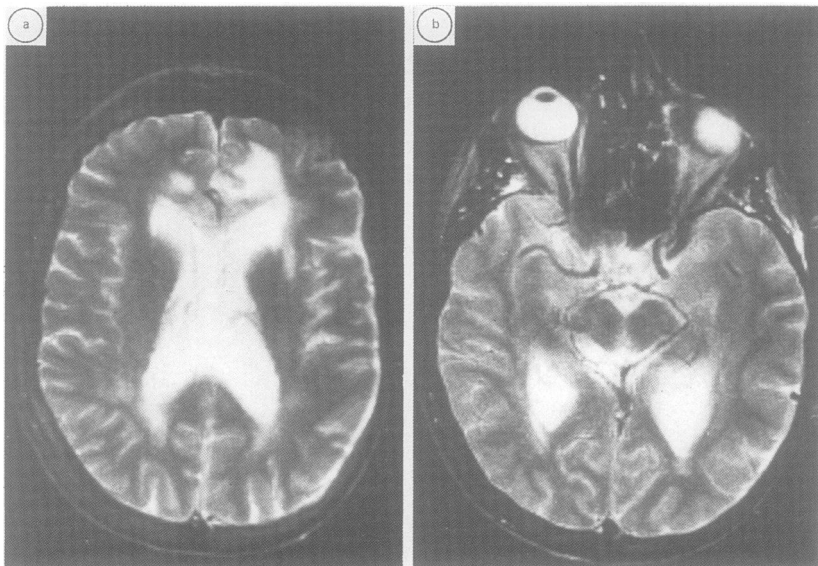


Fig (a) Lesion of the lower medial left frontal lobe involving the corpus callosum and a small portion of the lower right frontal lobe. (b) Normal appearance of the temporal lobes.