

Blindness in eclampsia: CT and MR imaging

RODERICK DUNCAN, DONALD HADLEY, IAN BONE, E M SYMONDS,
B S WORTHINGTON, P C RUBIN

From the Institute of Neurological Sciences, Southern General Hospital, Glasgow and University Hospital, Nottingham NG7 2UH

SUMMARY Three cases of cortical blindness complicating eclampsia are described, with magnetic resonance imaging (MRI) and X-ray computed tomography (CT). The correspondence of MRI lesions (hyperintense on T₂ weighted, and hypointense on T₁ weighted sections) and low attenuation lesions on CT scan indicated ischaemia rather than haemorrhage as the pathological mechanism.

Reversible focal neurological lesions are a rare feature of eclampsia, most reports being of patients with cortical blindness. Where X-ray computed tomography (CT) has been carried out, this has either shown low attenuation lesions in the occipital cortex,^{1-7,9-11} multiple low attenuation lesions,^{6,7} or has been normal.¹²⁻¹⁵ We present three cases of blindness complicating eclampsia, and discuss CT and magnetic resonance imaging (MRI) findings.

Methods

Unenhanced CT was carried out using a Philips 310 Tomoscan, producing 6 mm axial cuts parallel to the orbito-meatal line. Corresponding T₂ weighted (SE 2000/120) and T₁ weighted (IR 1600/400/40) 8 mm thick axial MRI sections were obtained using a Picker 0.15 Tesla resistive imager.

Case 1

A 38 year old para 1 + 0 in the 38th week of pregnancy was admitted to hospital with a history of acute visual loss and frontal headache. She had been hypertensive during her first pregnancy and had no past history of migraine. The visual loss had woken her in the morning, and had progressed over two hours until she was blind. On admission to hospital, she was hypertensive with a blood pressure of 165/120 mm Hg, and proteinuric. She had a tonic/clonic seizure, eclampsia was diagnosed and a caesarean section was performed.

On transfer to the Regional Neurological Unit, she was drowsy, but oriented. She could perceive only strong light, but pupillary responses were normal. There was a conjugate palsy of upward and left lateral gaze. Tendon reflexes were exaggerated with clonus in the left leg. Plantars were downgoing. Vibration sense was absent below the waist, but sensory testing was otherwise normal. There were no rashes

Address for reprint requests: Dr Duncan, Institute of Neurological Sciences, Southern General Hospital, Glasgow G51 4TF, UK.

Received 17 November 1988 and in revised form 3 February 1989.
Accepted 6 February 1989

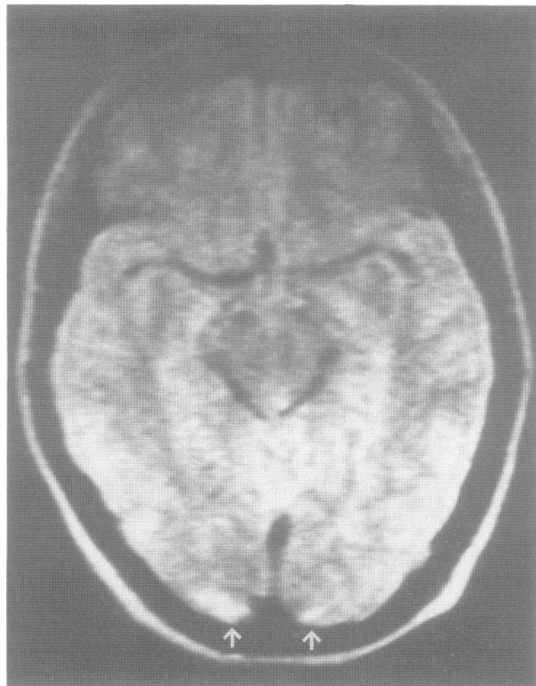


Fig 1 Case 1: axial T₂ weighted MR image showing high signal lesions at both occipital poles (arrows).

or other clinical evidence of systemic vasculitis. Blood pressure was 138/95 mm Hg.

ESR was raised to 86 mm in the first hour, she had a platelet count of $137 \times 10^9/\text{mm}^3$, and a urea of 7.4 mmol/l. Fibrin degradation products, and a clotting screen were normal. Autoantibody studies were negative. Cranial CT performed on admission showed no abnormality.

Her vision and abnormal neurological signs recovered to normal over 24 hours, despite continuing poor control of her blood pressure. MRI was performed on day 3 and showed

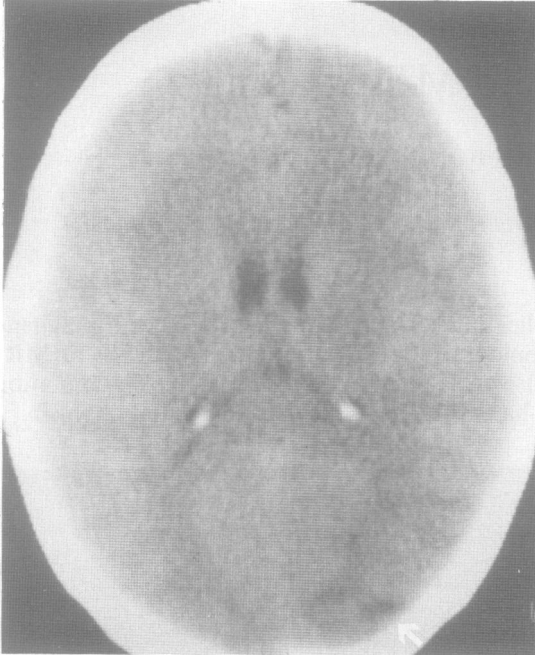

Fig 2 Case 2: axial unenhanced CT image showing low density in the right occipital lobe. A higher section showed a similar lesion on the left (arrow).

focal lesions in both occipital poles. These were non-space occupying and gave a hyperintense signal on the T₂ weighted images, and a hypointense signal on the T₁ weighted images (fig 1). Follow up MRI performed 2 months later showed complete resolution of the occipital lesions.

Case 2

A 20 year old para 0 + 0 had a caesarean section at 34 weeks for severe pre-eclampsia, diagnosed on the basis of hypertension, proteinuria and headache. She had no past history of hypertension or migraine. Post partum her blood pressure remained high despite treatment with atenolol, intermittently reaching levels as high as 200/100 mmHg. The fourth evening post partum she became confused and complained of severe frontal headache. The next morning she was alert and oriented, but her headache persisted. Over three hours her vision deteriorated until she was blind. She was transferred to the Regional Neurological Unit, where she suffered 2 tonic/clonic seizures. On examination, blood pressure was 165/110 mmHg. The fundi were normal, as were eye movements and pupillary reflexes. Vision had improved to perception of bright light throughout the visual fields. Neurological examination was otherwise normal.

Routine haematological and biochemical tests were normal. Cranial CT on admission showed bilateral occipital low attenuation lesions (fig 2). MRI carried out on the day of admission showed several focal non-space occupying lesions, hyperintense and hypointense on the T₂ weighted and T₁ weighted images respectively. These lay in both occipital lobes in the right posterior temporal cortex (figs 3 and 4), and

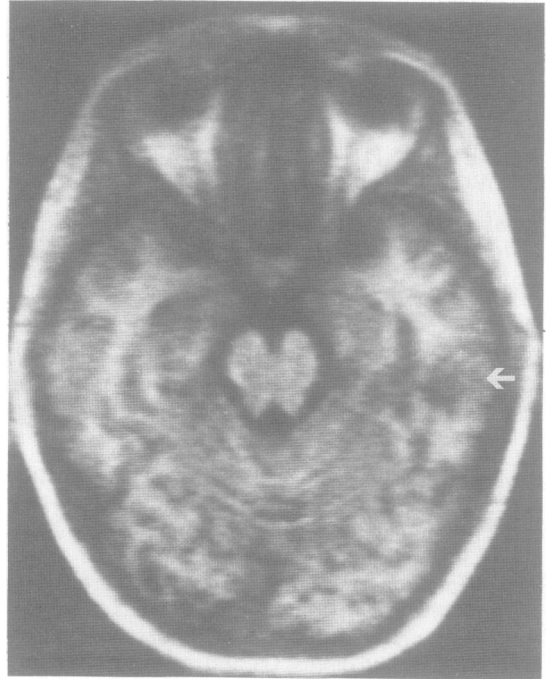


Fig 3 Case 2: axial T₁ weighted MR image showing low signal lesion in the left temporal lobe (arrow).

in the white matter of the left temporal and occipital lobes, extending into the lateral cortex.

Vision returned to normal within 36 hours, despite her blood pressure remaining poorly controlled. Follow up MRI carried out 6 weeks later showed complete resolution of the occipital lesions, and near complete resolution of the temporal lesion.

Case 3

A 26 year old para 1 + 0 was admitted at 18 weeks gestation. Her previous pregnancy had been unremarkable, but ultrasound examination in this pregnancy carried out at 14 weeks had suggested foetal abnormality. She had been well until a few hours prior to admission when she had two tonic/clonic convulsions. She regained consciousness but then developed complete blindness over two hours. There was no history of migraine. On examination, visual acuity was limited to the perception of bright light. Fundal examination and pupillary responses were normal, as was the remainder of the neurological examination. Blood pressure was 150/90 mmHg, and she had proteinuria. Eclampsia was diagnosed, and the pregnancy terminated the same day.

Routine haematological and biochemical tests were normal, as was cranial CT performed on the day of admission. MRI performed on day 3, at which time visual acuity had recovered to counting fingers, showed a focal non-space occupying lesion in the right occipital pole, hyperintense and hypointense on the T₂ weighted and T₁ weighted images respectively (fig 5). Necropsy on the foetus revealed holoprosencephaly and a molar placenta.

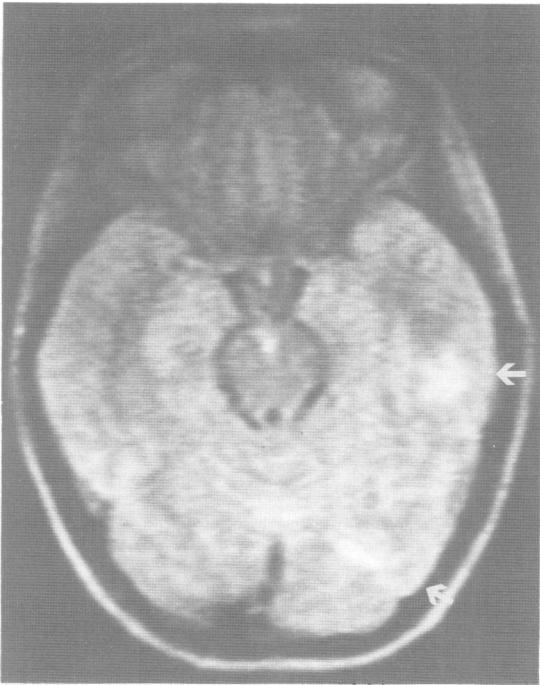


Fig 4 Case 2: axial T_2 weighted MR image showing high signal lesion in the white matter of the left temporal lobe corresponding to the lesion seen in fig 3 and in the left occipital lobe (arrows).

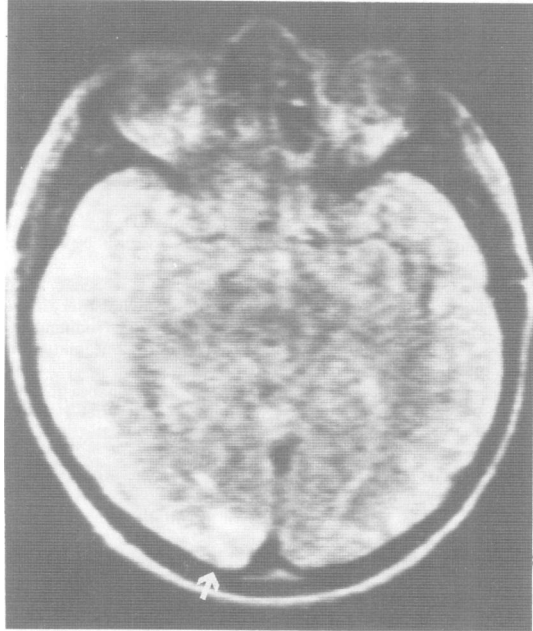


Fig 5 Case 3: axial T_2 weighted MR image showing a high signal lesion at the right occipital pole (arrow).

Her vision returned to normal over 3 days, despite poor blood pressure control. Follow up MRI done 3 months later was normal.

Discussion

In all three cases the diagnosis of eclampsia seems certain, with hypertension, proteinuria and seizures occurring in association with pregnancy. Although Case 3 occurred at 18 weeks, this was in association with molar degeneration, an established risk factor for early eclampsia.¹⁶ Despite the statistical association between the two conditions,¹⁷ none of our patients had a history of migraine.

Blindness due to eclampsia may be due to lesions at any site along the visual pathway, but the majority of case reports are of cortical blindness. Although there were minor retinal changes in Case 1, intact pupillary reflexes and the radiological finding of occipital cortical lesions in our cases confirm that they too were of cortical origin. The majority of patients with cortical blindness due to eclampsia recover vision, over a period varying from 2 hours to 21 days,^{1-15 19-22} although there is one reported case of persistent deficit.⁵ In Case 1 blindness was the presenting feature of eclampsia, while in Case 2 it occurred 5 days post partum. Approximately 50% of the cases in the literature have occurred post partum,^{4 8 9 12 13 20 21} by up to 7 days.¹³ Blindness was the presenting feature of eclampsia in six cases.^{2 7 12 13 15}

Clinically, there also were lesions at other sites in Case 1. The finding of gaze palsies indicated a low midbrain/high pontine lesion. The sensory level to vibration sense suggested the possibility of a spinal cord lesion, as did the findings of increased reflexes and clonus. In the other two cases there was no clinical evidence of focal lesions other than those in the occipital cortex. In cases in the literature, increased tendon reflexes are common,^{3 4 6 7 12 15 21 22} and are not always associated with seizures. More definite evidence of pyramidal dysfunction such as ankle clonus, upgoing plantars and hemiparesis is also found,^{3 4 14 21} as are gaze palsies,^{3 7} nystagmus⁷ and fluent dysphasia.¹³ In one case cortical lesions on CT coexisted with bilateral retinal detachments.⁹

Most recent reports feature the results of CT, and this either was normal,^{7 12 13 15} showed focal low attenuation occipital lesions,^{1-5 9-11} or more widespread low attenuation lesions.^{6 7} The lesions were non-enhancing, and were ascribed to localised oedema or to infarction. Repeat CT has shown partial resolution of lesions in 3-5 days^{2 3 7} and complete resolution in 9-14 days.^{1 6 9 10} A recent report²⁴ describes the results of MRI in a single case of eclampsia. Although clinically the patient had no focal neurological features, lesions with similar signal characteristics to those seen in our cases were shown in the right occipital lobe and left parietal lobe. They had resolved by the time a further scan was carried out 3 weeks post partum, and were ascribed to localised oedema. They were not detected by CT. CT and MRI findings in hypertensive encephalopathy are similar.²⁴

Our MRI findings are consistent with those in

transient ischaemic lesions,²⁵ and reflect focal increases in brain water content,²⁶ which may persist for several days after the resolution of neurological signs.²⁷ This results in increases in T₁ and T₂ relaxation times, giving hypointensity on T₁ weighted images and hyperintensity on T₂ weighted images. In contrast, acute focal haemorrhage gives a hypointense signal on T₂ weighted images or, at the subacute stage, a hyperintense signal on T₁ weighted images.

In the large necropsy series of Sheehan and Lynch²⁸ and Govan²⁹ gross haemorrhage was the most frequent cause of death, but the most common finding was of cortical groups of small (0.3–1 mm) haemorrhages associated with infarcts of similar size. It seems likely that our findings represent such lesions, and that they are primarily ischaemic rather than haemorrhagic. Small haemorrhages are seen in the placental vascular bed in eclampsia, and ultrastructural studies suggest that they are secondary to ischaemic vascular damage.³⁰

Angiographic studies in eclampsia show generalised large vessel spasm,³¹ and tend to support the view that ischaemia is the cause of focal neurological dysfunction. However, angiographically demonstrated spasm does not always relate well to cerebral blood flow,³² and spasm may occur without ischaemia and vice versa.

The finding of ischaemic lesions in eclampsia suggests that aggressive treatment of hypertension is likely to exacerbate neurological damage. It would appear that the most appropriate treatment in such cases would be a drug with cerebral vasodilator activity such as nifedipine. Alternatively, a more specific cerebral vasodilator agent such as nimodipine might be used in conjunction with other antihypertensive agents.

We thank the obstetricians and neurologists who looked after our three patients for allowing us to report them. The MRI Unit was funded by grants from the Medical Research Council and other bodies.

References

- 1 Beeson JH, Duda EE. Computed axial tomography scan demonstration of cerebral oedema in eclampsia preceded by blindness. *Obstet Gynaecol* 1982;**60**:529–32.
- 2 Goodlin RC, Streib E, Sun SF, Cox TA, Williams NA. Cortical blindness as the initial symptom in severe pre-eclampsia. *Am J Obstet Gynaecol* 1983;**147**:841–2.
- 3 Grimes DA, Ekbladh LE, McCartney WH. Cortical blindness in pre-eclampsia. *Int J Obstet* 1980;**17**:601–3.
- 4 Gyr T, Tamzin MS, Zimmerli W. Postpartum amaurosis in patients with pre-eclampsia. *Z Geburtshilfe Perinatol* 1983;**187**:293–5.
- 5 Ferrando M, Gil-Vernet S, Sabater R, Romero R, Poveda R. Occipital infarct after an episode of eclampsia. Importance of computerised axial tomography. *Rev Clin Esp* 1984;**173**:183–4.
- 6 Hill JA, Devoe LD, Elgammal TA. Central haemodynamic findings associated with cortical blindness in severe eclampsia. *J Reprod Med* 1985;**30**:435–8.

Duncan, Hadley, Bone, Symonds, Worthington, Rubin

- 7 Liebowitz HA, Hall PE. Cortical blindness as a complication of eclampsia. *Ann Emerg Med* 1984;**13**:365–7.
- 8 McNamee PT, McComb JM, O'Connor FA, Adgey AAJ. Complete recovery from late puerperal eclampsia with associated blindness. *Int J Cardiol* 1982;**1**:327–8.
- 9 Moodley J, Pillay M, Pillay R. Temporary blindness and eclampsia. A report of 2 cases. *S Afr Med J* 1985;**68**:677–8.
- 10 Tongyai T, Virutamasen P, Sawanwela N. Transient blindness in pre-eclamptic patient: a case report. *J Med Assoc Thai* 1984;**67**:629–33.
- 11 Lau SPC, Chan FL, Yu YL, Woo E, Huang CY. Cortical blindness in toxemia of pregnancy; findings of computed tomography. *Br J Radiol* 1987;**60**:347–9.
- 12 Arulkumaran S, Gibb DMF, Rauff M, Kek LP, Ratnam SS. Transient blindness associated with pregnancy induced hypertension. Case reports. *Br J Obstet Gynaecol* 1985;**92**:847–9.
- 13 Beal MF, Chapman PH. Cortical blindness and homonymous hemianopia in the postpartum period. *JAMA* 1980;**244**:2085–7.
- 14 Levavi H, Neri A, Zoldan J, Segal J, Ovadia J. Pre-eclampsia, "HELLP" syndrome and postictal cortical blindness. *Acta Obstet Gynaecol Scand* 1987;**66**:91–2.
- 15 Nishimura RN, Koller R. Isolated cortical blindness in pregnancy. *West J Med* 1982;**137**:335–7.
- 16 Scott JS. Pregnancy toxemia associated with hydrops fetalis, hydatidiform mole and hydramnios. *J Obst Gynaecol Brit Emp* 1958;**65**:689.
- 17 Rotton WN, Sachtheben MR, Friedman EA. Migraine and eclampsia. *Obstet Gynaecol* 1959;**14**:322–30.
- 18 Rubin PC, McCabe R. Postpartum migraine and severe pre-eclampsia. *Lancet* 1984;**ii**:286.
- 19 Chew SY, Tay D. Temporary blindness in severe pre-eclampsia. *Sing J Obstet Gynaecol* 1981;**12**:55–7.
- 20 Singh BM, Morris LJ, Strobos RJ. Cortical blindness in puerperium. *JAMA* 1989;**243**:1134.
- 21 Hauswald M. Cortical blindness and late postpartum eclampsia. *Am J Emerg Med* 1987;**5**:130–2.
- 22 Neunteufel W, Riss W. Amaurosis in EPH gestosis. *Z Geburtshilfe Perinatol* 1986;**190**:95–7.
- 23 Crawford S, Varner MW, Digre KB, Servais G, Corbett JJ. Cranial magnetic resonance imaging in eclampsia. *Obstet Gynaecol* 1987;**70**:474–7.
- 24 Hauser RA, Lacey DM, Knight MR. Hypertensive encephalopathy—magnetic resonance demonstration of reversible cortical and white matter lesions. *Arch Neurol* 1988;**45**:1078–83.
- 25 Brant-Zawadzki M, Kucharczyk W. Vascular disease-ischaemia. In: Brant-Zawadzki M, Norman D, eds. *Magnetic Resonance Imaging of the Central Nervous System*. New York: Raven Press, 1987:221–34.
- 26 Gotoh O, Asano T, Koide T, Takakura K. Ischaemic brain oedema following occlusion of the middle cerebral artery in the rat. I. The time courses of the brain water, sodium and potassium contents and blood-brain barrier permeability to I-125 albumin. *Stroke* 1985;**16**:101–9.
- 27 Kucharczyk W, Brant-Zawadzki M. Magnetic resonance imaging of cerebral ischaemia and infarction. In: Kressel HY, ed. *Magnetic Resonance Annual* 1987. New York: Raven Press, 1987:49–69.
- 28 Sheehan HL, Lynch JB. *Pathology of Toxaemia of Pregnancy*. Edinburgh: Churchill Livingstone, 1973.
- 29 Govan ADT. The pathogenesis of eclamptic lesions. *Pathol Microbiol* 1961;**24**:561–75.
- 30 DeWolf F, Robertson WB, Brosen I. The ultrastructure of acute atherosclerosis in hypertensive pregnancy. *Am J Obstet Gynaecol* 1975;**123**:164–74.
- 31 Lewis LK, Hinshaw DB, Will AD, Hasso AN, Thompson JR. CT and angiographic correlation of severe neurological disease in toxemia of pregnancy. *Neuroradiology* 1988;**30**:59–64.
- 32 Bergvall V, Steiner L, Forster DMC. Early pattern of cerebral circulatory disturbances following subarachnoid haemorrhage. *Neuroradiology* 1973;**5**:24–32.