

# *Actinomyces israelii* and *Fusobacterium nucleatum* brain abscess in an immunocompetent patient: case report

Mouhsine Lamtri Laarif<sup>1,\*</sup>, Raphael Schils<sup>2</sup>, Frédéric Lifrange<sup>3</sup>, Christophe Valkenborgh<sup>4</sup>, Pauline Pitti<sup>1</sup>, Pauline Brouwers<sup>1</sup>, Elettra Bianchi<sup>3</sup>, Cécile Meex<sup>1</sup> and Marie-Pierre Hayette<sup>1</sup>

## Abstract

**Introduction.** Brain abscess is the most common focal infectious neurological injury. Until the nineteenth century this condition was fatal, however the development of neuroimaging for early diagnosis, neurosurgery and antibiotic therapy in the twentieth century has led to new therapeutic strategies decreasing mortality from 50% in the 1970s to less than 10% nowadays. In this context we report a case of brain abscess with a dental origin.

**Case report.** A immunocompetent man without any addiction presented to the emergency department with dysarthria and frontal headache at home. The clinical examination was normal. Further investigations revealed a polymicrobial brain abscess as a consequence of an ear, nose or throat (ENT) infection with locoregional extension with a dental starting point involving *Actinomyces israelii* and *Fusobacterium nucleatum*. In spite of a rapid diagnosis and a neurosurgical management associated with an optimal treatment by a dual therapy made of ceftriaxone and metronidazole the patient unfortunately died.

**Conclusion.** This case report shows that despite a low incidence and a good prognosis following the diagnosis, brain abscesses can lead to patient's death. Thereby, when the patient's condition and urgency allow, a thorough dental examination of patients with neurological signs following the recommendations would improve the diagnosis made by the clinician. The use of microbiological documentation, the respect of pre-analytical conditions, the interaction between the laboratory and the clinicians are indispensable for an optimal management of these pathologies.

## DATA SUMMARY

In order to carry out this work, we have associated all the services involved in the diagnosis and management of the patient with the publication. The clinical data were retrieved from the patient's medical record via the OMNIPRO software. The magnetic resonance imaging and X-rays were transmitted and interpreted by the radiology department. Grocott and hematoxylin and eosin stains were performed and interpreted by the anatomopathology department. Gram-staining and bacterial culture results were provided and interpreted by the microbiology department. The therapeutic strategy and antibiotic therapy was passed on and decided by the infectious diseases department.

In this clinical case all the examinations that were carried out were described in detail. No additional data needed to be added.

## INTRODUCTION

Brain abscess is an intracerebral infection characterized by localized cerebritis that develops into a focus of pus, bounded by a well-vascularized capsule, in response to infection or trauma [1]. Pyogenic infections of the central nervous system

Received 08 September 2022; Accepted 09 May 2023; Published 26 June 2023

**Author affiliations:** <sup>1</sup>Department of Clinical Biology, Microbiology, University of Liège Hospital, Liège, Belgium; <sup>2</sup>Department of Internal Medicine, Infectious Diseases, University of Liège Hospital, Liège, Belgium; <sup>3</sup>Department of Pathology, University of Liège Hospital, Liège, Belgium; <sup>4</sup>Department of Radiology, University of Liège Hospital, Liège, Belgium.

\*Correspondence: Mouhsine Lamtri Laarif, m.lamtiri@chuliege.be

**Keywords:** *Actinomyces israelii*; actinomycosis; brain abscesses; *Fusobacterium nucleatum*; periodontitis.

**Abbreviations:** ADC, apparent diffusion coefficient; *A. israelii*, *Actinomyces israelii*; CNS, central nervous system; CT, computed tomography; DWI, diffusion-weighted imaging; ENT, ear, nose or throat; EUCAST, European Committee on Antimicrobial Susceptibility Testing; *F. nucleatum*, *Fusobacterium nucleatum*; MRI, magnetic resonance imaging; *S.*, *Streptococcus*.

000499.v4 © 2023 The Authors



This is an open-access article distributed under the terms of the Creative Commons Attribution License.

(CNS) may be a consequence of traumatic or surgical events (10–20%), bacterial invasion of the brain via neighbouring sites (20–30%) or by hematogenous spread (20–40%) [2, 3]. The incidence of brain abscesses is estimated to one to eight cases per 100000 population per year [3, 4] with a masculine predominance [5–7]. Improvements in neuroimaging, neurosurgery and antibiotic therapy have led to new therapeutic strategies that have reduced mortality from 50% in the 1970s to less than 10% nowadays [3, 4]. Although the most common distant site origins of brain abscess are pulmonary or cardiac [8], a few rare clinical cases have been reported in the literature with a dental origin such as caries, gingivitis, periodontitis, or osteomyelitis of the jaws [6, 9, 10].

We describe here a fatal case of an immunocompetent patient with probable periodontitis causing *Actinomyces israelii* (*A. israelii*) and *Fusobacterium nucleatum* (*F. nucleatum*) brain abscess leading to the patient's death in spite of an adapted antibiotic therapy.

## CASE PRESENTATION

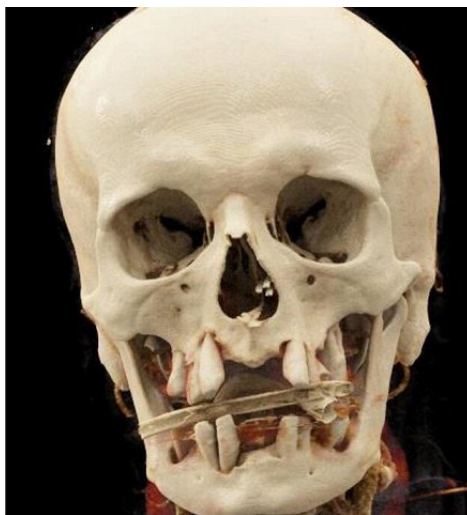
### Investigations

An immunocompetent man presented spontaneously to the emergency department with several episodes of intermittent dysarthria, which have been evolving since a week, followed by attention and language disorders. The patient also suffered from frontal headaches responding to level I analgesics and a progressive decrease in visual acuity, which has been evolving for several weeks. He was not addicted to any drugs.

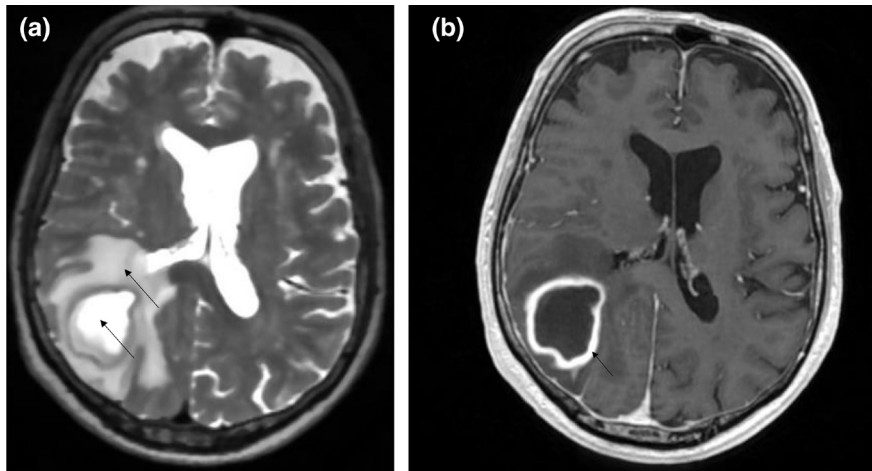
### Clinical findings

During his admission, his parameters were normal except for a *de novo* hypertension of 151/97 mmHg. Also, the general clinical and oral examination of the patient, revealed only significant dental degradation (Fig. 1) and a significant loosening of the teeth 25/26/37 due to his very poor dental hygiene. The neurological examination showed a left lateral homonymous hemianopia and dysarthria. Blood tests showed a mild inflammatory syndrome with c-reactive protein at  $14\text{ mg l}^{-1}$  (normal range :  $<5\text{ mg l}^{-1}$ ), fibrinogen at  $4.8\text{ g l}^{-1}$  (normal range:  $1.79\text{--}3.86\text{ g l}^{-1}$ ), white blood cells at the upper limit of the reference range:  $8.60\times 10^3/\text{mm}^3$  (normal range:  $4.60\times 10^3\text{--}10.10\times 10^3/\text{mm}^3$ ), and mild hyponatremia  $135\text{ mmol l}^{-1}$  (normal range:  $136\text{--}145\text{ mmol l}^{-1}$ ). Blood cultures taken at the admission were negative after 5 days of incubation. A brain computed tomography (CT) showed an intracranial mass syndrome ( $49\times 41\times 35\text{ mm}$ ) in the right parieto-temporo-occipital junction.

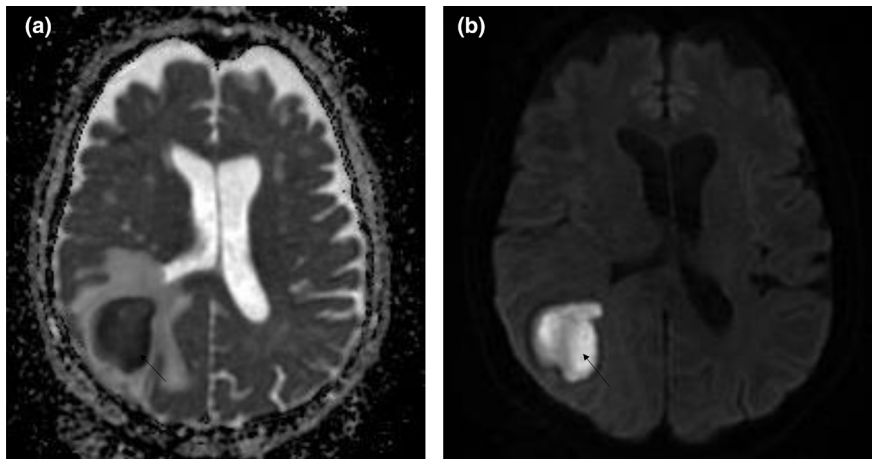
When the patient was hospitalized, brain magnetic resonance imaging (MRI) showed a lesion with hyper-/isointense-T2 fluid content and diffusion-restricting (Fig. 2a). The walls of the lesion appeared relatively regular and homogeneously enhanced (Fig. 2b), allowing us to conclude, as a first hypothesis in the presence of an abscess of the right posterior junction (Fig. 3). The thoracic-abdominal-pelvic CT scan refuted the presence of a primary oncological or infectious lesion.



**Fig. 1.** Volume Rendering Technique of cranial CT scan demonstrating alveolar bone loss and significant dental degradation.



**Fig. 2.** (a): Axial section in T2 sequence showing hypo-isointense content and a significant oedema around the mass. (b) Axial slice T1 sequence +contrast showing a mass with regular contours and homogeneous wall enhancement.



**Fig. 3.** Restriction of diffusion at the mass level and lack of restriction at the capsule level argues for an infectious process. (a): Apparent Diffusion Coefficient (ADC) sequence (b): Diffusion-weighted imaging (DWI) sequence.

### Diagnostic assessments

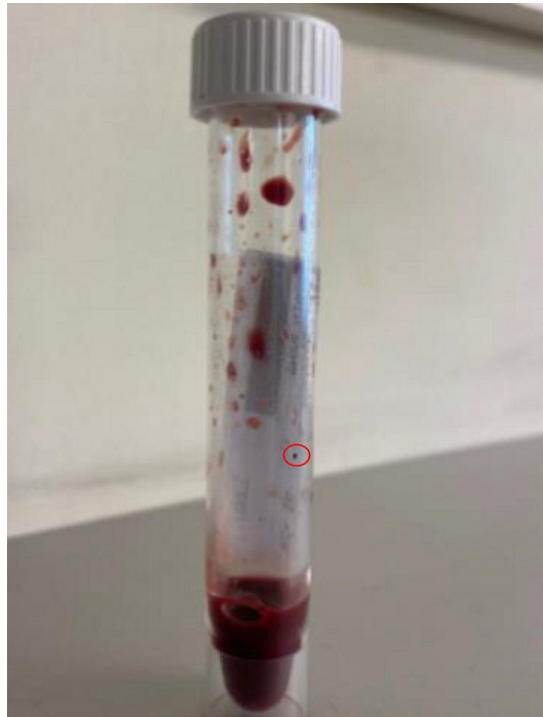Based on various arguments in favour of the initial hypothesis, the patient was admitted in neurosurgery for drainage of this abscess in the right temporo-parietal-occipital junction.

### Therapeutic interventions

Despite the suspicion of a brain abscess, but given the absence of clinical evidence of sepsis (according to quick sequential organ failure assessment criteria), no antibiotic therapy was started pre-operatively.

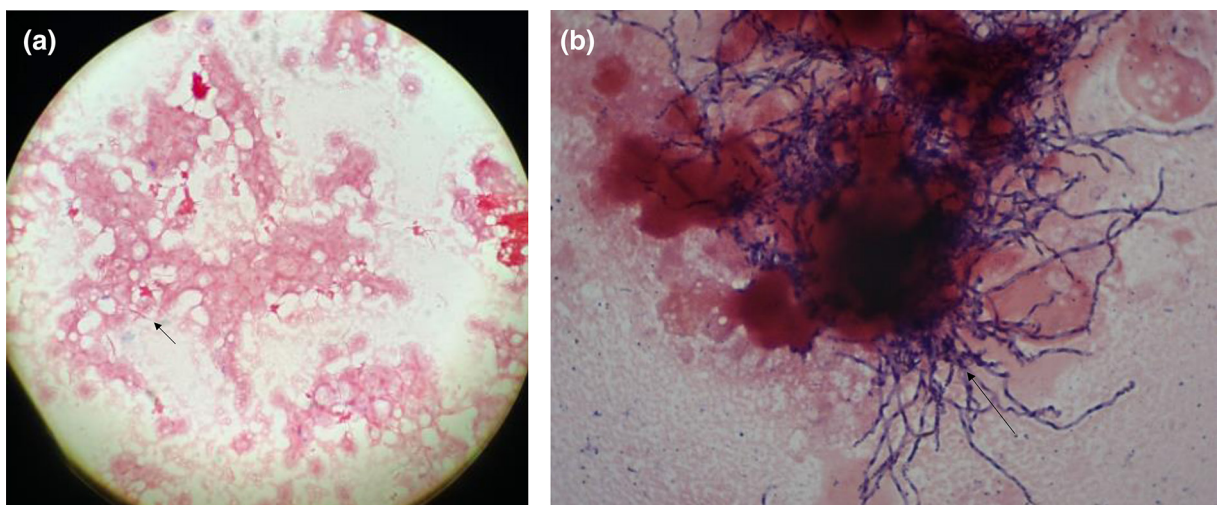
During surgery, the cerebrospinal fluid was drained, and no intraoperative complication was observed. The diagnosis of brain abscess was confirmed by the collection of a thick purulent fluid in the the right temporoparietal-occipital junction (Fig. 4). The abscess fluid was subsequently sent to the laboratory for bacteriological and histological analysis.

Post-operatively, the patient rapidly developed a septic state with diaphoresis, acute confusion, fever at 39.6°C and tachypnea (30 min<sup>-1</sup>). In this context, empirical antibiotics were started after taking two blood cultures from different anatomical sites, including ceftriaxone IV 2 g once daily, metronidazole 1500 mg once daily and vancomycin IV 40 mg/kg/24 h. The neurological state deteriorated rapidly with the occurrence of left hemiplegia associated with an altered state of consciousness (Glasgow score 12/15), which led to admission to intensive care.

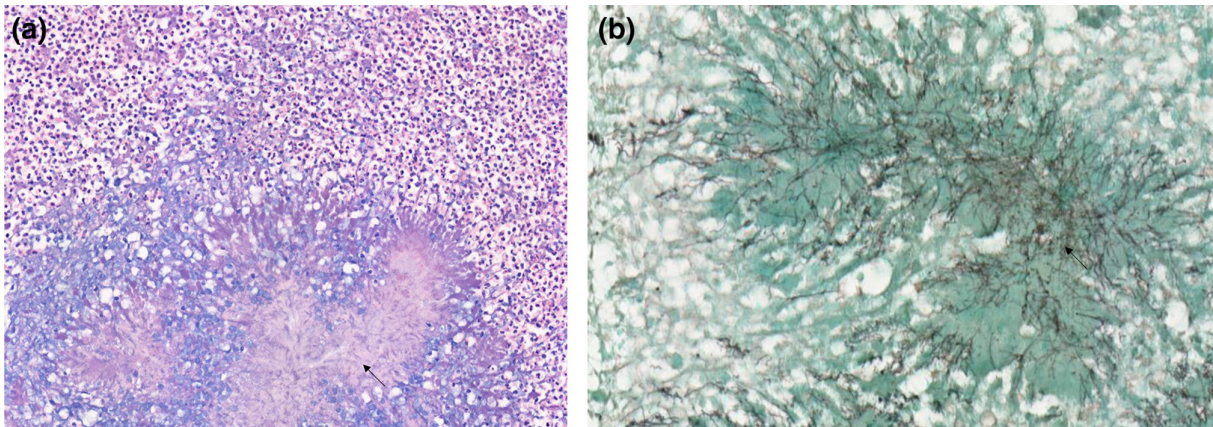


**Fig. 4.** Collection of brain abscess showing sulphur granules.

Concerning the microbiology, macroscopic analysis showed the presence of sulphur granules viewable on the collection tube, suggesting the presence of a bacterium of the actinomycetal family (Fig. 4). In this context, after crushing these and taking a smear for direct examination at  $\times 1000$  magnification after Gram-staining, the sulphur granules proved to contain branched Gram-positive bacilli microscopically similar to *Actinomyces* sp. Microscopic analysis of the abscess drainage fluid at  $\times 1000$  magnification following Gram-staining revealed moderately numerous leukocytes (6–30/field) and a polymicrobial population. Rare spindle-shaped Gram-negative bacilli suggestive of *Fusobacterium* sp. (Fig. 5a), as well as rare Gram-positive cocci and fine pleomorphic, branched Gram-positive bacilli consistent with *Nocardia* sp. or *Actinomyces* sp. were observed as in crushed granules (Fig. 5b). The anaerobic culture performed at 35–37°C, confirmed after 2 days of incubation the presence of *F. nucleatum* in moderate quantity and rare *Propionibacterium acnes* (likely skin contaminant). After 3 days of incubation, aerobic and anaerobic culture confirmed the presence of moderate quantity of *A. israelii*. The aerobic culture



**Fig. 5.** (a): Gram-staining suggestive of *Fusobacterium* sp. (b): Gram-staining suggestive of *Actinomyces* sp.

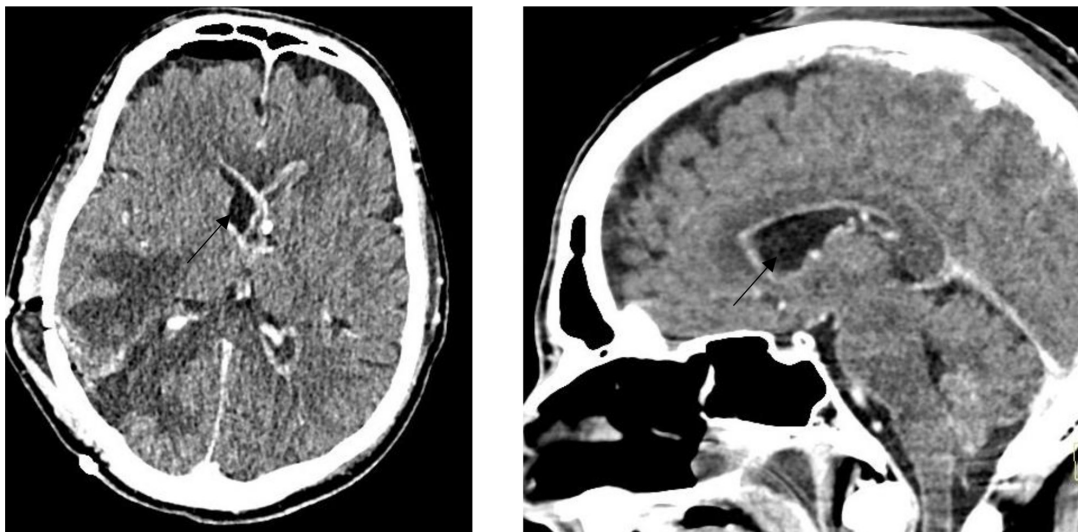


**Fig. 6.** (a): Hematoxylin and Eosin staining suggestive of *Actinomyces* sp. (b): Grocott staining suggestive of *Actinomyces* sp.

also demonstrated the presence of a rare quantity of two other bacteria with unknown clinical significance: *Micrococcus luteus* (likely skin contaminants) and *Janibacter indicus* (likely environmental contaminant). All bacterial identifications were performed by Matrix Assisted Laser Desorption Ionization - Time of Flight, mass spectrometry. An antibiotic susceptibility testing for *A. israelii* was performed, using the European Committee on Antimicrobial Susceptibility Testing (EUCAST) v.9.0 (2019) breakpoints for Gram-positive anaerobic bacteria for the interpretation. It demonstrated the susceptibility of *A. israelii* to penicillin, piperacillin/tazobactam and clindamycin. Otherwise, no antibiogram could be performed for *F. nucleatum* because of growth failure after subculture.

Pathologically, the samples taken showed fragments of brain parenchyma with numerous necrotic, abscessed cavities, consisting mainly of neutrophils and a few rare lymphocytes. Rare colonies of *Actinomyces* sp. were found in the centre of some cavities (Fig. 6). The rest of the parenchyma showed a glial reaction. The leptomeninges and vessels passing through them were surrounded by a lymphocytic reaction. No significant atypia was observed. The immunohistochemically examinations performed were reassuring and ruled out a malignant process.

Based on these bacteriological findings, vancomycin was stopped. Although the necessary additional dental examinations could not be carried out, oral examination and CT scan of the face showed the most likely hypothesis to be periodontitis. The hypothesis of an ear, nose, or throat infection with locoregional extension causing the brain abscess was maintained as the most likely one.



**Fig. 7.** Post-operative brain contrast-enhanced computed tomography demonstrating the ventriculitis.

## Follow-up and outcome

During the hospitalization in intensive care, a massive ventriculitis progressively appeared and was refractory to attempts of external shunting and antibiotic therapy (Fig. 7). Due to the lack of recovery of consciousness despite the gradual cessation of sedation and the prognosis, comfort care was instituted in a collegial manner, leading inevitably to the patient's death a few hours later.

## DISCUSSION

With more than 1200 bacterial types, the oral cavity is a major entry point for various pathogens. Several studies have demonstrated the involvement of bacteria of the oropharyngeal flora in the pathophysiology of many systemic, cardiovascular and cerebral diseases [3, 8]. Dental infection, and particularly periodontitis and dental caries are a rare but possible starting point for brain abscesses through haematogenous spread [1–6, 8, 11–14].

Bacterial infection are at least involved in 85% of spontaneous cases of brain abscesses, the two-thirds are caused by dental and oropharyngeal microbiota [15]. Between 30–60% of brain abscesses are polymicrobial, making the identification of the primary infection cause difficult [7]. Periodontitis and caries leading to periapical involvement are the main dental diseases that can lead to CNS infection [6]. In this context, the identification of the causal microorganisms becomes an essential element.

Such as in this case report, the fragility of some bacteria, particularly anaerobic microorganisms, may prevent the performance of an antibiogram [8]. The strict anaerobic nature of some bacteria requires the most efficient coordination between the laboratory and clinicians to minimize the delay in sample delivery. In oral CNS infections, aerobic bacteria promote the growth of the anaerobic via overconsumption of oxygen at the infection site. In this context, anaerobic bacteria are three times more involved than the aerobic in this pathology [6]. The literature describes the responsibility of the oral microbiota in brain abscesses, showing the major involvement (32%) of viridans streptococci of the milleri family (*Streptococcus (s). anginosus*, *S. constellatus* and *S. intermedius*), followed by *F. nucleatum* (13.6%), *Porphyromonas gingivalis* (6.8%) and *Actinomyces* sp. (2%) [9, 16].

*A. israelii*, the predominant bacteria isolated in the brain abscess, is a bacterium belonging to the *Actinomyces* group. Filamentous prokaryotic microorganisms, Gram-positive bacilli, branching filamentous rods (except *A. meyeri*), non-acid-fast, anaerobic or microaerophilic, *Actinomyces* are present in the commensal flora of the oropharynx, gastrointestinal and urogenital tract [10, 17]. *Actinomyces* take advantage of the phenomenon of co-aggregation. Indeed, they profit of the hypoxia caused by aerobic bacteria, the toxins and enzymes that the latter secrete, to potentially cause actinomycosis, which is a rare, suppurative, granulomatous endogenous infection [6, 18]. Unlike the usual bacterial infections, actinomycosis penetrates the anatomical planes to become a lobular 'pseudotumour' responsible for a chronic granulomatous infection characterized by the formation, in 75% of cases, of tiny clusters (0.1 to 1 mm) called sulphur granules [10]. Observed in our patient and strongly suggestive of actinomycosis, sulphur granules owe their name to their yellowish colour and allow the microorganisms to resist phagocytosis [10, 19, 20]. *Actinomyces* grow on blood-enriched agar medium with a 2–4 days incubation at 35–37 °C under anaerobic conditions [21]. In agreement with the antibiogram performed in our laboratory, the literature describes a sensitivity of all *Actinomyces* sp. to beta-lactam antibiotics, making this class of antibiotics the first line of treatment for actinomycosis, while metronidazole is considered inactive [10, 22].

*F. nucleatum*, a non-spore-forming, non-motile Gram-negative bacillus, is the main pathogen of the *Bacteroidaceae* family. As a strict anaerobe, which can be found in the oral cavity, respiratory, gastrointestinal and genitourinary tracts, *F. nucleatum* is able to bridge the gap between oral colonisers and dental plaque bacteria. It then facilitates the formation of a biofilm allowing the coexistence of bacteria with conflicting environmental requirements [23, 24]. *F. nucleatum* is strongly implicated in periodontal disease [25] through lectin-like interactions, and has a strong ability to invade gingival epithelial cells leading to an exacerbation of neutrophilic activity, resulting in tissue damage, which can lead to abscess formation [26]. *Fusobacterium* can evade the immune system due to their ability to bind to the constant fragment of immunoglobulins suggesting that dissemination can occur during transient bacteremia [27]. In correlation with our patient, rare cases of *F. nucleatum* associating brain abscesses with a periodontal origin via haematogenous spread have been described in the literature [25, 28]. At the therapeutic level, azithromycin, metronidazole, clindamycin and colistin are considered active. Reduced susceptibility to neomycin, erythromycin, amoxicillin and ampicillin has been observed [26, 29]. The secretion of  $\beta$ -lactamase or penicillinase by *F. nucleatum* has been described [26, 30].

Considered a public health problem, periodontitis in our case remains uncertain. The presence of oral germs found on the samples and frequently associated with periodontitis; the loss of alveolar bone estimated radiographically, and the significant loosening of the teeth observed on dental examination; are elements in favour but insufficient for a diagnosis of definite periodontitis [31]. Unfortunately, due to the critical condition of the patient requiring intubation as well as the lack of contribution to the immediate management of the patient, a more thorough diagnosis of the patient's oral pathology was not performed before the patient's death.

In the absence of international guidelines, recommendations for antibiotic therapy were published on behalf of the British Society of Antimicrobial Chemotherapy in 2000 [32]. Thus, empirically, after removal and/or aspiration of the brain abscess, the choice and duration of antibiotic therapy depends on the initial site of infection and the location of the abscess. In polymicrobial abscesses, the use of ceftriaxone/metronidazole dual therapy covers Gram-positive and Gram-negative bacteria as well as anaerobes and

appears to be effective [28, 32, 33]. Although this dual therapy seems to be a good therapeutic approach for brain abscesses with a suspected oral aetiology, bacteriological documentation is of great importance for the adaptation of antibiotic therapy towards less broad spectra, or in the case of the demonstration of resistance mechanisms.

In conclusion, periodontal abscesses, and other infections of dental origin in rare cases, can be responsible for brain abscesses. The clinical examination of patients with neurological disorders that can be explained by the presence of a brain abscess should include a systematic dental inspection to check for periapical abscesses. Given the difficulty of growth and the anaerobic nature of the bacteria originating from the oral microbiota and involved in brain abscess, special attention should be paid to the rapid transport of the sample to the laboratory and to the prolonged incubation of the culture. As demonstrated in our case, the macroscopic examination of the specimens can be as important as the microscopic examination for the orientation of further investigations in the laboratory. Based on the microbiological findings, surgical drainage and empirical dual therapy with ceftriaxone/ metronidazole appears to be the optimal treatment strategy. However, despite the existence of multiple effective antibiotic therapies, brain abscesses can be fatal as demonstrated in our case. *F. nucleatum* plays a very important role in the co-aggregation of bacteria in the oral microbiota. In this context, empirical coverage of this pathogen in cases of oral brain abscesses is therefore crucial. This underlines the importance of following the international recommendations for empirical treatment of abscesses according to their suspected origin.

#### Funding information

This work received no specific grant from any funding agency.

#### Author contributions

L.L.M.: Investigation, Methodology, Visualization Writing original draft & conceptualization. S.R.: Proofreading and modification of the infectiology section. P.P.: Formal analysis. B.P.: Formal analysis. L.F.: Proofreading and modification of the anapatomology section. V.C.: Proof-Reading and modification of the radiology section. B.E.: Proofreading of the anapatomology section. M.C.: Review & editing. H.M.P.: Review & editing, oversight & validation.

#### Conflicts of interest

The authors declare that there are no conflicts of interest.

#### Consent to publish

After writing the manuscript, all the authors confirmed their wish of association. All authors gave their agreement without the need for their signature. The approval of the ethics committee was not required due to the nature of this case report. In accordance with the Declaration of Helsinki, patient anonymity was guaranteed. Following the death of the patient, several attempts were made to contact the patient's family but unfortunately without any success. It was therefore not possible to obtain the consent of the next of kin and therefore indirect identifiers were removed from the case report.

#### References

1. Khattak A, Rehman R, Alam W. Etiological factors of brain abscess. *J Med Sci* 2010;18:194–196.
2. Sakamoto H, Karakida K, Otsuru M, Arai M, Shimoda M. A case of brain abscess extended from deep fascial space infection. *Oral Surg Oral Med Oral Pathol Oral Radiol Endod* 2009;108:e21–5.
3. Mueller AA, Saldamli B, Stübinger S, Walter C, Flückiger U, et al. Oral bacterial cultures in nontraumatic brain abscesses: results of a first-line study. *Oral Surg Oral Med Oral Pathol Oral Radiol Endod* 2009;107:469–476.
4. Ewald C, Kuhn S, Kalff R. Pyogenic infections of the central nervous system secondary to dental affections—a report of six cases. *Neurosurg Rev* 2006;29:163–166.
5. Hilmani S, Riyahi S, Ibaioin K, Naja A, El Kamar A, et al. Les abcès cérébraux (à propos de 80 cas). *Neurochirurgie* 2009;55:40–44.
6. Moazzam AA, Rajagopal SM, Sedghizadeh PP, Zada G, Habibian M. Intracranial bacterial infections of oral origin. *J Clin Neurosci* 2015;22:800–806.
7. Brook I. Microbiology and treatment of brain abscess. *J Clin Neurosci* 2017;38:8–12.
8. Nath A, Berger J. Brain Abscess and Parameningeal Infections. In: *Goldman's Cecil Medicine*. Elsevier, 2012. pp. 2371–2376. [accessed 22 August 2022].
9. Stimac D, Jankovic D, Peric L, Anic K, Nimsky C. Intracerebral abscess caused by *Actinomyces israelii*. *Cureus* 2020;12:e12058.
10. Valour F, Sénéchal A, Dupieux C, Karsenty J, Lustig S, et al. Actinomycosis: etiology, clinical features, diagnosis, treatment, and management. *Infect Drug Resist* 2014;7:183–197.
11. Pereira A da S, Tavares AT, Prates M, Ribeiro N, Fonseca LF, et al. Brain abscess: a rare clinical case with oral etiology, editor. *Case Rep Infect Dis* 2022;2022:5140259.
12. Yang SY. Brain abscess: a review of 400 cases. *J Neurosurg* 1981;55:794–799.
13. Chen KP, Lee YP, Hwang MJ, Chiang CP. *Fusobacterium nucleatum*-caused brain abscess – Case report. *J Dent Sci* 2021;16:776–777.
14. Ben Hadj Hassine M, Oualha L, Derbel A, Douki N. Cerebral abscess potentially of odontogenic origin. *Case Rep Dent* 2015;2015:267625.
15. Andersen C, Bergholt B, Ridderberg W, Nørskov-Lauritsen N. Culture on selective media and amplicon-based sequencing of 16S rRNA from spontaneous brain abscess—the view from the diagnostic laboratory. *Microbiol Spectr* 2022;10:e0240721.
16. Burgos-Larraín LF, Vázquez-Portela Á, Cobo-Vázquez CM, Sáez-Alcaide LM, Sánchez-Labrador L, et al. Brain complications from odontogenic infections: a systematic review. *J Stomatol Oral Maxillofac Surg* 2022;123:e794–e800.
17. Nissotakis C, Sakorafas GH, Koureta T, Revelos K, Kassaras G, et al. Actinomycosis of the appendix: diagnostic and therapeutic considerations. *Int J Infect Dis* 2008;12:562–564.
18. Kumar LS, Keluskar V, Naik Z. Actinomycotic osteomyelitis of the maxilla in a female patient: a rare case report with the review of the literature. *Dent Med Probl* 2022.
19. Sezer B, Akdeniz BG, Günbay S, Hilmioglu-Polat S, Başdemir G. Actinomycosis osteomyelitis of the jaws: report of four cases and a review of the literature. *J Dent Sci* 2017;12:301–307.
20. M.Kliegman MR. *Actinomyces*, 21st ed. Nelson Textbook of Pediatrics, 2020.
21. Könönen E, Wade WG. *Actinomyces* and related organisms in human infections. *Clin Microbiol Rev* 2015;28:419–442.
22. Smith AJ, Hall V, Thakker B, Gemmell CG. Antimicrobial susceptibility testing of *Actinomyces* species with 12 antimicrobial agents. *J Antimicrob Chemother* 2005;56:407–409.

23. Bradshaw DJ, Marsh PD, Watson GK, Allison C. Role of *Fusobacterium nucleatum* and coaggregation in anaerobe survival in planktonic and biofilm oral microbial communities during aeration. *Infect Immun* 1998;66:4729–4732.
24. Kolenbrander PE, Andersen RN, Moore LV. Coaggregation of *Fusobacterium nucleatum*, *Selenomonas flueggei*, *Selenomonas infelix*, *Selenomonas noxia*, and *Selenomonas sputigena* with strains from 11 genera of oral bacteria. *Infect Immun* 1989;57:3194–3203.
25. Denes E, Barraud O. *Fusobacterium nucleatum* infections: clinical spectrum and bacteriological features of 78 cases. *Infection* 2016;44:475–481.
26. Bolstad AI, Jensen HB, Bakken V. Taxonomy, biology, and periodontal aspects of *Fusobacterium nucleatum*. *Clin Microbiol Rev* 1996;9:55–71.
27. Guo M, Han YW, Sharma A, De Nardin E. Identification and characterization of human immunoglobulin G Fc receptors of *Fusobacterium nucleatum*: identification of Fc receptors of *Fusobacterium*. *Oral Microbiol Immunol* 2000;15:119–123.
28. Sonnevile R, Ruimy R, Benzonana N, Riffaud L, Carsin A, *et al.* An update on bacterial brain abscess in immunocompetent patients. *Clin Microbiol Infect* 2017;23:614–620.
29. Lenoir F. *Fusobacterium* spp. au CHU de Rennes: épidémiologie des bactériémies chez les alcoolodépendants. Rennes; 2019. <https://dumas.ccsd.cnrs.fr/dumas-02147451> [accessed 10 August 2022].
30. Mosca A, Miragliotta L, Iodice MA, Abbinante A, Miragliotta G. Antimicrobial profiles of *Prevotella* spp. and *Fusobacterium nucleatum* isolated from periodontal infections in a selected area of southern Italy. *Int J Antimicrob Agents* 2007;30:521–524.
31. Kwon T, Lamster IB, Levin L. Current concepts in the management of periodontitis. *Int Dent J* 2021;71:462–476.
32. De Louvois EM, Brown R, Bayston J. The rational use of antibiotics in the treatment of brain abscess. *Br J Neurosurg* 2000;14:525–530.
33. Darlow CA, McGlashan N, Kerr R, Oakley S, Pretorius P, *et al.* Microbial aetiology of brain abscess in a UK cohort: prominent role of *Streptococcus intermedius*. *J Infect* 2020;80:623–629.

#### Five reasons to publish your next article with a Microbiology Society journal

1. When you submit to our journals, you are supporting Society activities for your community.
2. Experience a fair, transparent process and critical, constructive review.
3. If you are at a Publish and Read institution, you'll enjoy the benefits of Open Access across our journal portfolio.
4. Author feedback says our Editors are 'thorough and fair' and 'patient and caring'.
5. Increase your reach and impact and share your research more widely.

Find out more and submit your article at [microbiologyresearch.org](https://microbiologyresearch.org).



## Peer review history

---

### VERSION 3

---

#### Editor recommendation and comments

<https://doi.org/10.1099/acmi.0.000499.v3.1>

© 2023 Rudkin J. This is an open access peer review report distributed under the terms of the Creative Commons Attribution License.

**Justine Rudkin**; University of Oxford, Nuffield Department of Population Health, UNITED KINGDOM, Oxford

Date report received: 09 May 2023

Recommendation: Accept

**Comments:** Thank you for addressing all points raised during peer review. I am now satisfied that all ethical considerations have been covered appropriately and can approve this manuscript for publication.

---

### VERSION 2

---

#### Editor recommendation and comments

<https://doi.org/10.1099/acmi.0.000499.v2.2>

© 2023 Rudkin J. This is an open access peer review report distributed under the terms of the Creative Commons Attribution License.

**Justine Rudkin**; University of Oxford, Nuffield Department of Population Health, UNITED KINGDOM, Oxford

Date report received: 06 April 2023

Recommendation: Minor Amendment

**Comments:** Thank you to all reviewers for their careful consideration of this manuscript. During the peer review process there have been some conflicts between requests for patient metadata to be added to the manuscript and the need to remove patient identifiers for ethical reasons, as consent to publish could not be acquired from the patient's next of kin. These conflicts were not picked up by myself and I apologise for that. In the case of this manuscript, as the metadata aren't crucial to the case presentation we ask that authors remove the non-direct patient identifiers that were added during revisions, and amend the ethical statement to- "Approval from the ethical committee was not required due to the nature of this case report. Abiding by the Declaration of Helsinki, patient anonymity was guaranteed." and add some of the explanation that patient consent from the next of kin could not be acquired and as such indirect identifiers were removed from the Case Report. We shall be improving journal guidelines to make these situations clearer for authors and reviewers in future.

---

#### Reviewer 1 recommendation and comments

<https://doi.org/10.1099/acmi.0.000499.v2.1>

© 2023 Ardila C. This is an open access peer review report distributed under the terms of the Creative Commons Attribution License.

**Carlos Ardila**; Universidad de Antioquia, COLOMBIA

<https://orcid.org/0000-0002-3663-1416>

Date report received: 02 April 2023

Recommendation: Minor Amendment

**Comments:** Nothing is indicated regarding the informed consent of the patient or about the ethical aspects to be considered in the presentation of cases.

*Please rate the quality of the presentation and structure of the manuscript*

Good

*To what extent are the conclusions supported by the data?*

Strongly support

*Do you have any concerns of possible image manipulation, plagiarism or any other unethical practices?*

No

*Is there a potential financial or other conflict of interest between yourself and the author(s)?*

No

*If this manuscript involves human and/or animal work, have the subjects been treated in an ethical manner and the authors complied with the appropriate guidelines?*

No: Nothing is indicated regarding the informed consent of the patient or about the ethical aspects to be considered in the presentation of cases.

---

## **Author response to reviewers to Version 1**

### **Responses to the reviewers**

Dear Editor, Dear Reviewers,

Thank you for your feedback regarding the manuscript "Actinomyces israelii and Fusobacterium nucleatum brain abscess in an immunocompetent patient: case report".

Your comments and advices were very precious and relevant; I tried to get involved as much as possible to answer them in order to improve the quality of our case report.

You will find in this PDF file all the actions taken to try to answer your expectations and questions. I hope that I have understood your expectations and that the associated answers will satisfy you.

I look forward to hearing from you and send you my best regards.

### **Reviewer 1**

#### **I. Abstract**

1. Question/Comments : Introduction: The objective is not presented.

Author's action : Addition of the objective in the introduction.

2. Question/Comments : Case report: Indicate the age and gender of the patient.

Author's action : Addition of the age and gender of the patient.

3. Question/Comments : Conclusion: The importance of a routine dental evaluation is indicated; however, nothing is reported about it in this case.

Author's action : Modification of the text to support the indication of a dental examination.

#### **II. Introduction**

1. Question/Comments :Dental infections have different origins. Describe them.

Author's action : Modification of the text and addition of some dental pathologies associated with brain infections.

2. Question/Comments : There is speculation regarding the diagnosis of periodontitis. The diagnosis of this disease requires a detailed clinical and radiographic evaluation. A detailed clinical dental and periodontal evaluation was not performed in this case. These aspects should be clarified throughout the manuscript and should be commented on in the discussion. In that same section, it should be described as limitations

Author's action : Modification of the text in its totality on the various parts concerning the diagnosis of a periodontitis, and specification of the fact that the latter was the most probable hypothesis. This element was also detailed in the discussion and added as a limitation of the case report.

After checking the patient's medical records, a dental opinion was given describing a significant loosening of teeth 25/26/37 (the patient was intubated, so the examination could not be more thorough). The dentist also wished to perform a mandibular scan to consolidate his strong suspicion of periodontitis. Unfortunately, due to the urgency of the situation and the lack of input on the immediate management of the patient, the dental examination was not further investigated before the patient died.

However, in view of the results of the radiological examinations, the germs involved and the limited information gathered during the clinical examination of the patient's mouth, the most likely hypothesis was periodontitis.

### III. Case presentation

1. Question/Comments : Please provide more sociodemographic information about the patient, in addition to age and gender.

Author's action : Modification of the text by adding, ethnicity and country of life of the patient. Unfortunately, despite a thorough search of the patient's file, we could not find any socio-demographic information about the patient.

2. Question/Comments : Figure 1. It does not represent poor dental hygiene. It could rather be the consequences of it. However, the authors cannot ensure any type of diagnosis of the oral cavity based on an image alone.

Author's action : Modification and adjustment of the text by highlighting the bone degradation visible on the CT scan and the state of dental degradation.

3. Question/Comments : Please define all acronyms appropriately: CRP, MRI, CT, qSOFA, MALDI-TOF, ENT, CNS

Author's action : Text modification. All acronyms have been correctly defined.

4. Question/Comments : Describe the anatomical sites from which cultures were taken.

Author's action : Modification of the text.

5. Question/Comments : A CT cannot be the basis for a periodontal diagnosis or to determine the presence of periapical abscesses. The clinical evaluation of the patient's oral cavity is essential. Moreover, the diagnosis of "diffuse periodontitis" does not exist.

Author's action : I modified the text by adding a new reference concerning the complementary examinations necessary for a certain diagnosis of periodontitis and I specified that the various elements collected only allowed a strong suspicion of this pathology, and that it was thus not a certain diagnosis.

6. Question/Comments : Figure 1. The legend should consider the aspects already described.

Author's action : Modification of the text.

### IV. Discussion

1. Question/Comments : Periodontal abscesses and other infections of dental origin also occur.

Author's action : Text correction.

2. Question/Comments : Limitations should be detailed. Some of them have already been described above.

Author's action : Modification of the text and addition of the limits concerning the lack of documentary on the anamnesis and the oral examinations for the specific diagnosis of a periodontitis. Throughout the article, several limitations have been detailed concerning the microbiological and infectious aspect of the management (difficulty in culturing anaerobic germs, difficulty in respecting the transport time, difficulty in judging the clinical impact of certain germs...) but also the difficulty in carrying out all the examinations necessary for a detailed diagnosis and in carrying out multidisciplinary consultations when the patient's vital prognosis is at stake.

### Reviewer 2

1. Question/Comments : Is "cerebral angioscanner" a computed tomography (CT), a CT angiography, or a cerebral angiography? This term does not seem to be common.

Author's action : Modification of the text. It was a computed tomography.

2. Question/Comments : I am interested in post-operative images and the results of the preoperative blood culture. This patient presented no signs of sepsis pre-operatively, but rapidly developed a septic state post-operatively. Was cerebrospinal fluid drained during the drainage operation of the abscess? It is possible that the right lateral ventricle was opened and the abscess was spread to the ventricles during the drainage operation. This may have caused the severe ventriculitis that required external shunting and was fatal.

Author's action : Modification of the text to specify the negativity of the preoperative blood culture after 5 days of incubation (as recommended). Addition of postoperative brain CECT demonstrating ventriculitis. In addition, your hypothesis cannot be ruled out, but unfortunately in the absence of formal information justifying this situation I have not described it in this case report.

---

## VERSION 1

---

### Editor recommendation and comments

<https://doi.org/10.1099/acmi.0.000499.v1.5>

© 2023 Rudkin J. This is an open access peer review report distributed under the terms of the Creative Commons Attribution License.

**Justine Rudkin**; University of Oxford, Nuffield Department of Population Health, UNITED KINGDOM, Oxford

Date report received: 17 February 2023

Recommendation: Minor Amendment

**Comments:** I have now received two peer review reports on your manuscript, which express a few queries over the work presented and question the validity of a diagnosis of periodontitis. Can you please address the reviewers comments, making amendments to your manuscript where necessary. Editorial Office note: One of the reviewers raised a concern regarding ethics. Proof of exemption from ethical approval has now been provided by the author and is available on request.

---

### Reviewer 2 recommendation and comments

<https://doi.org/10.1099/acmi.0.000499.v1.3>

© 2023 Anonymous. This is an open access peer review report distributed under the terms of the Creative Commons Attribution License.

**Anonymous.**

Date report received: 17 February 2023

Recommendation: Minor Amendment

**Comments:** The authors reported the brain abscess of odontogenic origin in immunocompetent patient. 1. Description of the case(s), 2. Presentation of results In this report, there are no problems about description of the case and presentation of result. 3. How the style and organization of the paper communicates and represents key findings It is well described that the brain abscess caused by poor dental hygiene occurred in immunocompetent patient and the causative organisms were rare. 4. Literature analysis or discussion There are no problems about literature analysis and discussion. 5. Any other relevant comments Line 76 Is "cerebral angioscanner" a computed tomography (CT), a CT angiography, or a cerebral angiography? This term does not seem to be common. I have interests and questions in the following points, although they may not particular necessary in case of focusing on infections. I am interested in post-operative images and the results of the preoperative blood culture. This patient presented no signs of sepsis pre-operatively, but rapidly developed a septic state post-operatively. Was cerebrospinal fluid drained during the drainage operation of the abscess? It is possible that the right lateral ventricle was opened and the abscess was spread to the ventricles during the drainage operation. This may have caused the severe ventriculitis that required external shunting and was fatal.

*Please rate the quality of the presentation and structure of the manuscript*

Good

*To what extent are the conclusions supported by the data?*

Partially support

*Do you have any concerns of possible image manipulation, plagiarism or any other unethical practices?*

No

*Is there a potential financial or other conflict of interest between yourself and the author(s)?*

No

*If this manuscript involves human and/or animal work, have the subjects been treated in an ethical manner and the authors complied with the appropriate guidelines?*

Yes

---

### Reviewer 1 recommendation and comments

<https://doi.org/10.1099/acmi.0.000499.v1.4>

© 2022 Ardila C. This is an open access peer review report distributed under the terms of the Creative Commons Attribution License.

**Carlos Ardila**; Universidad de Antioquia, COLOMBIA

<https://orcid.org/0000-0002-3663-1416>

Date report received: 01 December 2022

Recommendation: Major Revision

**Comments:** The manuscript "Actinomyces israelii and Fusobacterium nucleatum brain abscess in an immunocompetent patient: case report." was submitted to AM. The case deals with an interesting issue; however, there are concerns related to the report. Specific comments are noted below. Abstract -. Introduction: The objective is not presented. -. Case report: Indicate the age and gender of the patient. -. Conclusion: The importance of a routine dental evaluation is indicated; however, nothing is reported about it in this case. Introduction -. Lines 58-60. Dental infections have different origins. Describe them. -. Lines 61. There is speculation regarding the diagnosis of periodontitis. The diagnosis of this disease requires a detailed clinical and radiographic evaluation. A detailed clinical dental and periodontal evaluation was not performed in this case. These aspects should be clarified throughout the manuscript and should be commented on in the discussion. In that same section, it should be described as limitations. Case presentation -. Please provide more sociodemographic information about the patient, in addition to age and gender. -. Line 71. Figure 1. It does not represent poor dental hygiene. It could rather be the consequences of it. However, the authors cannot ensure any type of diagnosis of the oral cavity based on an image alone. -. Please define all acronyms appropriately: CRP, MRI, CT, qSOFA, MALDI-TOF, ENT, CNS, etc. -. Line 92. Describe the anatomical sites from which cultures were taken. -. Lines 122-123. A CT cannot be the basis for a periodontal diagnosis or to determine the presence of periapical abscesses. The clinical evaluation of the patient's oral cavity is essential. Moreover, the diagnosis of "diffuse periodontitis" does not exist. -. Figure 1. The legend should consider the aspects already described. Discussion -. Lines 217-218. Periodontal abscesses and other infections of dental origin also occur. -. Limitations should be detailed. Some of them have already been described above. Nothing is indicated regarding the informed consent of the patient or about the ethical aspects to be considered in the presentation of cases.

*Please rate the quality of the presentation and structure of the manuscript*

Satisfactory

*To what extent are the conclusions supported by the data?*

Partially support

*Do you have any concerns of possible image manipulation, plagiarism or any other unethical practices?*

No

*Is there a potential financial or other conflict of interest between yourself and the author(s)?*

No

*If this manuscript involves human and/or animal work, have the subjects been treated in an ethical manner and the authors complied with the appropriate guidelines?*

No: Nothing is indicated regarding the informed consent of the patient or about the ethical aspects to be considered in the presentation of cases.

---

### SciScore report

<https://doi.org/10.1099/acmi.0.000499.v1.1>

© 2022 The Authors. This is an open-access article report distributed under the terms of the Creative Commons License.

**iThenticate report**

<https://doi.org/10.1099/acmi.0.000499.v1.2>

© 2022 The Authors. This is an open-access article report distributed under the terms of the Creative Commons License.