

# Adrenoleukodystrophy: heterogeneity in two brothers

G M ELRINGTON, D E BATEMAN, M J JEFFREY, N F LAWTON

*From the Wessex Neurological Centre, Southampton, UK*

**SUMMARY** A man with hypoadrenalism died from a rapidly progressive pseudobulbar palsy, due to adult onset adrenoleukodystrophy. This diagnosis suggested that his brother, with a longstanding spastic paraparesis, suffered from adrenomyeloneuropathy. Both cases were confirmed biochemically. The heterogeneity of expression of this x-linked disorder is described, with the consequent difficulty in diagnosis and nomenclature.

X-linked recessive adrenoleukodystrophy (ALD) was initially recognised in male children between 4 and 8 years old who characteristically suffered dementia, visual and hearing loss, and paralysis, usually in a setting of hypoadrenalism.<sup>1</sup> Less commonly, adult males may present with a progressive leukodystrophy in association with hypoadrenalism and hypogonadism.<sup>2</sup> Both these diseases are usually fatal. The more typical adult manifestation, adrenomyeloneuropathy (AMN), is not life threatening. It affects both sexes, presents as a spastic paraparesis some time after the second decade and is distinguished by hypoadrenalism, hypogonadism, and polyneuropathy.<sup>3</sup> In female heterozygotes, endocrine abnormalities are characteristically absent. Childhood ALD, adult ALD, and AMN may occur within a single kindred and are associated with the same biochemical defect, the accumulation of very long chain fatty acids (VLCFA).<sup>2</sup> This heterogeneity of expression of a presumably identical genetic abnormality has not yet been accounted for.

It is now clear that not all cases fit neatly into the categories described above; for example, an adult female with lethal leukodystrophy,<sup>4</sup> and a male infant with chronic cerebral disease<sup>5</sup> have been described. Clearly the clinical expression of ALD and AMN is very variable. The question arises whether a number of subtly different genetic defects accounts for a clinical spectrum despite biochemical similarity. The presence of more than one manifestation within a kindred would argue against this possibility. Childhood ALD, and AMN, the two commonest manifestations,<sup>2</sup> frequently occur within a single kindred. Previously reported British cases of adult onset ALD were two

brothers with onset of ALD around the age of 20 years<sup>6</sup> and a man dying in his fifties from leukodystrophy.<sup>7</sup> We report the cases of two brothers with this disease, illustrating phenotypic variation as the proband had adult onset ALD, and his brother AMN.

## Case reports

### Case 1

A 43 year old man, known to suffer from hypoadrenalism, presented with a progressive pseudobulbar palsy. He described 10 months dysarthria and 2 months dysphagia with nasal regurgitation. Six months gait difficulty had initially been rapidly progressive, with subsequent gradual deterioration. The arms were also weak, to a lesser extent. For 6 months the left leg had felt numb and the vision had become blurred. At the age of 20 yr, he had been admitted to hospital with pneumonia and was found to be hypotensive and hyponatraemic. The clinical diagnosis of Addison's disease had been confirmed by urinary steroid excretion studies, and since that time he had taken steroid replacement therapy, remaining well until his terminal illness. Hospital admission was again precipitated by a chest infection. He was taking cortisone acetate, fludrocortisone, potassium supplements, and amoxycillin.

His brother had a long history of gait disturbance, said to be due to multiple sclerosis. His mother had died at the age of 72 from dementia of uncertain cause. He had two healthy teenage children, a son and a daughter.

Examination revealed him to be of short stature, with marked frontal balding. He was not abnormally pigmented. The left second toe was bifid. Higher mental function was normal on bedside testing. There was bilateral lid retraction, with corrected visual acuity 6/36 right, 6/24 left. Visual fields, optic discs, and ocular movements were normal. He had mild bilateral facial weakness, and a spastic dysarthria with slow and limited tongue movements. Gag reflexes were brisk and the jaw jerk exaggerated. He could walk unaided, despite a mild spastic tetraparesis, with bilaterally extensor plantar responses. Sensation of pain and vibration was diminished throughout the left leg. There were no cerebellar signs.

Investigations showed ESR and full blood count to be normal, apart from a modest neutrophil leukocytosis; serum

Address for reprint requests: Dr G M Elrington, Neurosciences Group, Institute of Molecular Medicine, John Radcliffe Hospital, Oxford OX3 9DV, UK

Received 19 April 1988 and in revised form 16 October 1988.  
Accepted 21 October 1988

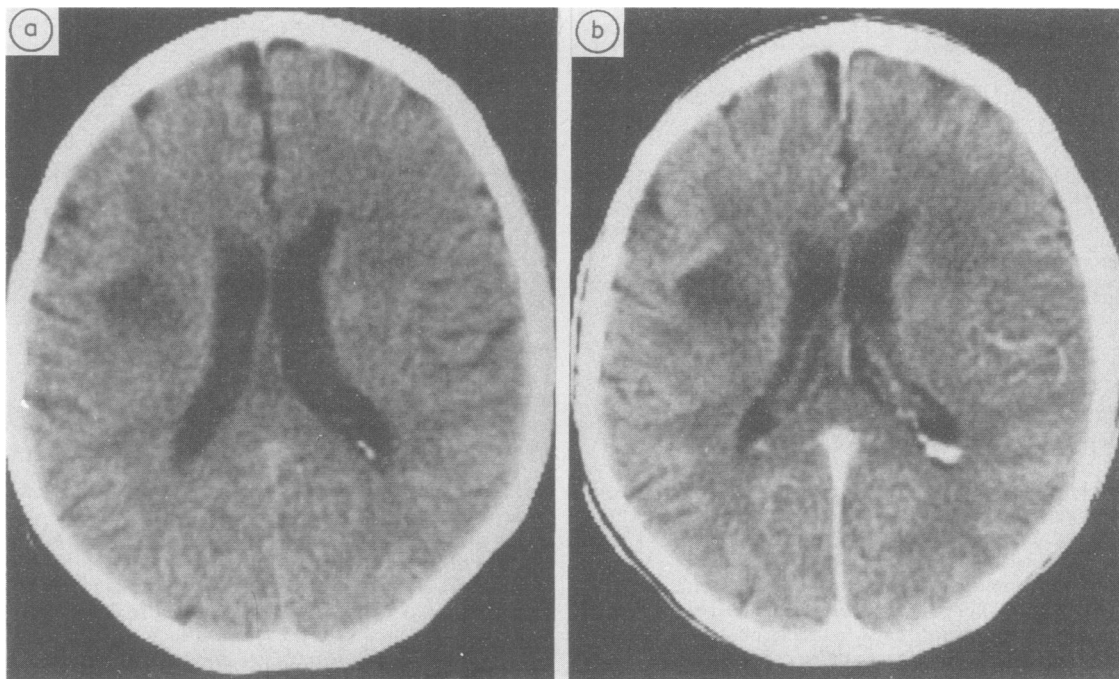


Fig 1 CT brain scan of patient one (1) unenhanced, (2) contrast enhanced.

B12 level was normal. Biochemical tests were normal and included electrolytes, liver function tests, glucose, calcium, thyroxine, protein electrophoresis, and fasting lipids. TPHA and autoimmune profile were negative. Radiographs of skull, chest, and abdomen were normal. CT of the brain revealed generalised atrophy, worse above than below the tentorium; and reduced attenuation in both cerebral hemispheres, especially the right, where there was a margin of contrast enhancement (fig 1). CSF was under normal pressure and contained elevated total protein at 760 mg/100 ml, but no excess of IgG and no oligoclonal bands. CSF glucose, cell count, and culture were normal. EEG was moderately abnormal, the dominant rhythm on the right being slowed to delta. Visual evoked potentials were of above average latency but within the normal range. Brainstem auditory evoked potentials were bilaterally delayed. Nerve conduction was slow in both sural and tibial nerves; both were 38 m/s. Tibial F response was prolonged to 62 m/s; but the sural amplitude

was normal at 11  $\mu$ V. Median nerve studies were normal. Neuropsychological tests revealed mild to moderate impairment of visuospatial and verbal memory performance. A short synacthen test showed no cortisol response to synacthen 250  $\mu$ g, but TRH and LH RH tests were normal, as was serum testosterone. Very long chain fatty acid (VLCFA) analysis confirmed the clinical diagnosis of ALD (see table).

He remained in hospital for 3 weeks. Because of his rapidly progressive disease he was treated with prednisolone 80 mg daily, in addition to his replacement therapy. There was subjective improvement only. He was readmitted 5 weeks later, after rapid deterioration, and was now bedbound, doubly incontinent and anarthric, although he appeared to recognise people. Two weeks later he died of bronchopneumonia.

At necropsy the lungs showed bronchopneumonic changes. The adrenals were very small, being 0.5 cm wide and together weighing 3 g; microscopy revealed marked cortical

Table VLCFA levels in patients and controls

	Case 1	Case 2	Normal	Hemizygote*	Heterozygote†
C22%‡	0.792	0.949	1.18 $\pm$ 0.61	1.63 $\pm$ 0.58	1.33 $\pm$ 0.54
C24%	0.874	0.938	0.78 $\pm$ 0.32	1.73 $\pm$ 0.76	1.90 $\pm$ 0.80
C25%	0.035	0.032	0.03 $\pm$ 0.03	0.12 $\pm$ 0.06	0.20 $\pm$ 0.34
C26%	0.036	0.029	0.01 $\pm$ 0.01	0.07 $\pm$ 0.04	0.05 $\pm$ 0.05
C26 $\mu$ g/ml	0.709	0.554	0.33 $\pm$ 0.18	1.62 $\pm$ 0.87	0.82 $\pm$ 0.32
C24/C22 ratio	1.104	0.998	0.84 $\pm$ 0.08	1.63 $\pm$ 0.20	1.20 $\pm$ 0.24
C26/C22 ratio	0.045	0.031	0.01 $\pm$ 0.01	0.07 $\pm$ 0.02	0.04 $\pm$ 0.02

\*Males with ALD/AMN.

†Obligate heterozygotes.

‡VLCFA levels expressed as percentage of total fatty acid.

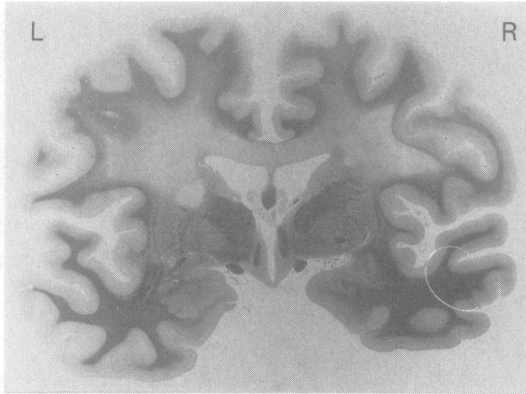


Fig 2 Coronal section of brain at level of foramina of Munro showing pallor of myelin staining. Luxol Fast Blue.

atrophy and normal medullae. The cardiovascular, gastrointestinal, and genitourinary systems were normal. The brain weighed 1605 g and appeared normal externally. Coronal sections revealed extensive grey discoloration and softening of the white matter in both centra semiovalea with sparing of the subcortical fibres. These changes extended caudally from the level of the olfactory bulbs to the occipital lobes; and were maximal at the level of the foramina of Munro and extended into the superior part of the left internal capsule (fig 2). The cerebellum, brain stem and spinal cord appeared macroscopically normal.

Microscopy revealed loss of myelin sheaths with relative preservation of axons within the affected centra semiovalea. Some axons showed partial demyelination (fig 3). Within the areas of demyelination reactive astrocytes and gliosis were prominent and perivascular accumulations of foamy macrophages were seen (fig 4). At the periphery of the demyelinated area the perivascular infiltrate was composed of lymphocytes.

A similar area of demyelination with relative sparing of axons was present in the left cerebellar hemisphere. Focal areas of myelin and axon loss were observed in the cerebral peduncles of the midbrain, in the pons, medulla and spinal

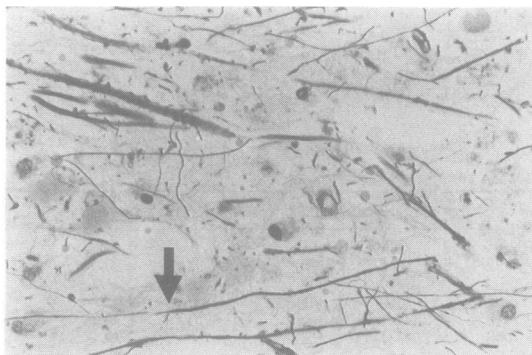


Fig 3 Section from centrum semiovale showing demyelination with preservation of axons. Luxol Fast Blue/Palmgren  $\times 480$ .

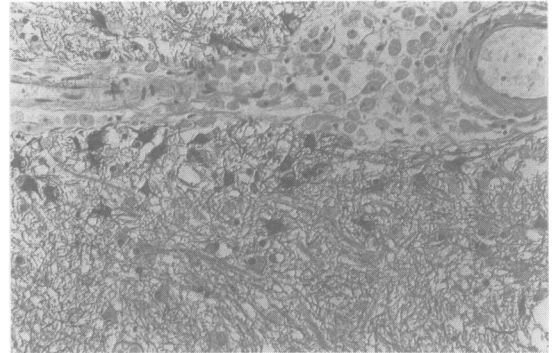


Fig 4 Section from centrum semiovale showing reactive astrocytes and perivascular accumulation of macrophages. Immunoperoxidase technique for Glial Fibrillary Acidic Protein, haematoxylin counterstain  $\times 220$ .

cord, reflecting degeneration of the cortico-spinal and cortico-pontine tracts. Loss of myelin sheaths and axons was also seen in the gracile tracts of the dorsal columns of the spinal cord. Electron microscopy of a section from the left internal capsule revealed trilaminar cytoplasmic inclusions within perivascular macrophages (fig 5). The inclusions were formed by two electron dense lamellae each approximately 3 nm in width and separated by an electron lucent zone approximately 7 nm in width.

These appearances confirmed the clinical and biochemical diagnosis of ALD.

#### Case 2

The brother of Case 1 presented an entirely different clinical picture. He was a 51 year old warehouseman, who had experienced 15 years increasing stiffness in his legs. During episodes of intercurrent infection, he would lose the use of his legs for about 24 hours. Occasional spasms in the legs were responsive to baclofen. He admitted to occasional numbness in the right leg. Generally, he enjoyed good health and had lost only 2 days work from illness in the preceding 18 years. He has three asymptomatic teenage children.

Examination revealed him to be mildly pigmented, and bald. Blood pressure was 130/75 mm Hg supine, 140/75 mm Hg erect. He had a mild spastic paraparesis and tongue

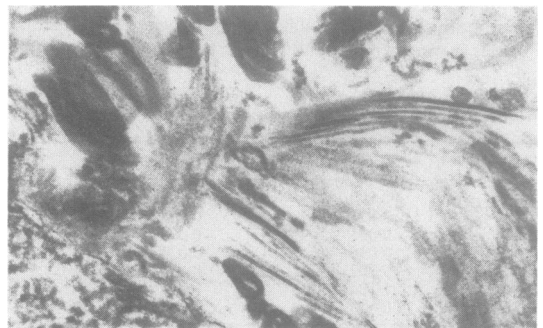


Fig 5 Electron microscopy: trilaminar inclusions within macrophage cytoplasm.  $\times 59,000$ .

movements were slow. Tendon reflexes were brisk throughout, with bilaterally extensor plantar responses, although ankle jerks were relatively diminished. Sensory change was confined to distal loss of vibration sense in the legs.

Nine a.m. cortisol was diminished at 130 nmol/l, and failed to rise after synacthen 250 µg intramuscularly. Full blood count, ESR, B12, glucose, calcium, thyroxine, and TRH tests were all normal with negative TPHA and autoimmune profile. Skull and chest radiographs, and CT of the brain were normal. Myelography, and CSF analysis had been performed earlier and found to be normal. Neuropsychological tests were normal, and EEG was within normal limits. Tibial nerve conduction was bilaterally slowed to 38 m/s and 36 m/s, with prolonged F wave latencies of 61 and 69 m/s. Sural nerve conduction speed was normal at 44 m/s, with amplitude 8 µV; median and radial nerves were also normal. VLCFA analysis revealed an elevated C25 fraction and C26/22 ratio, though not in the range usually seen in ALD hemizygotes (see table).

He is now on steroid replacement therapy and continues to lead a normal life.

## Discussion

ALD/AMN is a peroxisomal disorder. The peroxisome is a subcellular organelle, responsible for the  $\beta$ -oxidation of VLCFA. Disease may result in the accumulation of VLCFA, especially hexacosanoate (C26) although it is not clear why this is associated with endocrine and neurological dysfunction. Other peroxisomal disorders include Zellweger's cerebro-hepato-renal syndrome, hyperpipecolic anaemia, infantile Refsum's disease, and neonatal ALD which is distinct from the x-linked ALD described above.<sup>8,9</sup> Moser has shown that analysis of plasma VLCFA is a reliable diagnostic procedure in suspected ALD/AMN and that the pattern of VLCFA abnormality distinguishes this from other peroxisomal disorders. VLCFA are derived from endogenous synthesis as well as from the diet, and their role in the pathogenesis of the disease is unknown.<sup>2</sup>

Case 1 presented with rapidly progressive and fatal neurological deficit. This type of ALD is more commonly seen in childhood although it occasionally affects adults. Only five of Moser's 303 cases of ALD and AMN presented thus, with adult onset ALD.<sup>2</sup>

Case 2, despite having the same abnormal x chromosomal region as case one, presented in a radically different way, with the typical clinical picture of AMN. The absence of clinically obvious hypoadrenalism is not unusual, and illustrates the value of a synacthen test in screening male patients with spastic paraparesis of unknown cause. The presence of neuropathy may be a useful clinical pointer to AMN but in Case 2 this was easily overlooked. Sixteen percent of Moser's 153 cases of childhood ALD had normal adrenal function, as do females with AMN, so biochemical tests of adrenal function cannot be used

to exclude the diagnosis.<sup>2</sup> Case 2's relatively normal VLCFA profile might not have established the diagnosis with certainty if this test alone had been used for screening. We conclude that dynamic tests of adrenal function, and VLCFA analysis, should be regarded as complementary investigations in such cases.

Prenatal diagnosis of ALD/AMN and detection of the carrier state are now possible. A search for affected relatives is therefore important, because both steroid replacement therapy and genetic counselling may be indicated. Interestingly, the daughter of the proband had a normal VLCFA profile although she is an obligate heterozygote.

It might be thought that AMN is the adult form of ALD; this presumably accounts for a diagnosis of AMN being applied to adults with cerebral disease and ALD-type VLCFA accumulation.<sup>5,7</sup> The term AMN is better reserved for patients with the relatively benign spinal and neuropathic form of this disease. Clinical features, rather than age of onset, distinguish between ALD and AMN.

We are grateful to Dr H W Moser, and Prof M Hjelm, for VLCFA analysis.

## References

- 1 Schaumburg HH, Powers JM, Raine CS, Suzuki K, Richardson EP. Adrenoleukodystrophy: a clinical and pathological study of 17 cases. *Arch Neurol* 1975;**32**: 577-91.
- 2 Moser HW, Moser AE, Singh I, O'Neill BP. Adrenoleukodystrophy: survey of 303 cases; biochemistry, diagnosis, and therapy. *Ann Neurol* 1984;**16**:628-41.
- 3 Griffin JW, Goren E, Schaumburg H, Engel WK, Loriaux L. Adrenomyeloneuropathy: a probable variant of adrenoleukodystrophy. *Neurology* 1977;**27**: 1107-13.
- 4 Simpson RHW, Rodda J, Reinecke CJ. Adrenoleukodystrophy in a mother and son. *J Neurol Neurosurg Psychiatry* 1987;**50**:1165-72.
- 5 James ACD, Kaplan P, Lees A, Bradley JJ. Schizophreniform psychosis and adrenomyeloneuropathy. *J R Soc Med* 1984;**77**:882-5.
- 6 Esiri MM, Hyman MN, Horton WL, Lindenbaum RH. Adrenoleukodystrophy: clinical, pathological, and biochemical findings in two brothers with the onset of cerebral disease in adult life. *Neuropathol Appl Neurobiol* 1984;**10**:429-45.
- 7 Jeffcoate WJ, McGivern D, Cotton RE, Hopkinson GR. Late onset adrenomyeloneuropathy. *J Neurol Neurosurg Psychiatry* 1987;**50**:1238-9.
- 8 Auborg P, Robain O, Rocchiccioli F, Dancea S, Scotto J. The cerebro-hepato-renal (Zellweger) syndrome: lamellar lipid profiles in adrenocortical, hepatic mesenchymal, astrocyte cells and increased levels of very long chain fatty acids and phytanic acid in the plasma. *J Neurol Sci* 1985;**69**:9-25.
- 9 Goldfischer S. Peroxisomes and human metabolic diseases: the cerebrohepato-renal syndrome, cerebro-tendinous xanthomatosis, and Schilder's disease. *Ann NY Acad Sci* 1982;**386**:526-9.