

## Oligodendroglioma occurring after radiation therapy for pituitary adenoma

CHUN-I HUANG, WEN-HSYANG CHIOU, DONALD M HO\*

*From the Department of Surgery (Neurosurgery) and Pathology,\* Veterans General Hospital, and National Yang-Ming Medical College, Taipei, Taiwan*

**SUMMARY** A 38 year old male dentist developed an oligodendroglioma of the left medial temporal lobe and parasellar region 12 years after radiotherapy with 6600 rads of acromegaly. The 30 cases of radiation-induced gliomas reported in the English literature are reviewed and analysed. The criteria for defining radiation-induced tumours of the central nervous system are proposed as follows: the tumour has a long quiescent “latency period”, a location in the previously irradiated field, a verified histological difference from a primary condition, and does not arise from a primary condition associated with a genetic syndrome such as neurofibromatosis or tuberous sclerosis. The reported case fulfilled these criteria but appears to be the only reported radiation-induced oligodendroglioma.

The correlations between radiation and oncogenic effects have been studied in animal models, epidemiological analyses and case reports. Certain tumour types are more closely related to irradiation, especially thyroid and breast carcinoma, leukaemia, multiple myeloma, and various sarcomas. In the central nervous system (CNS), irradiation was not previously thought to be an oncogenic stimulus but more recently, evidence has shown that both benign and malignant intracranial tumours can develop after cranial irradiation.<sup>1</sup> Most reports concern sarcoma and meningioma;<sup>2,3</sup> radiation-induced gliomas were rarely documented<sup>4</sup> but increasing numbers have been reported recently. This might be because patients with CNS tumours now live for longer after the effort of multimodal treatments. We review the 30 reported cases of radiation-induced glioma previously published in the English literature and add a further case of an oligodendroglioma. We also seek a correlation between the dose of irradiation and the latency before tumour development.

### Case report

A 26 year old male who had just graduated from dental school was admitted to Veterans General Hospital, Taipei

on 29 July, 1974, because of progressively enlarged hands and feet, and protruding mandible over the previous 6 years. Excessive thirst, polyuria, and headache had been experienced during the previous 3 months. On examination, enlargement of the jaw, thickening of the heel pads, and malocclusion of the temporo-mandibular joint were found. There were no cutaneous stigmata of neurofibromatosis. Plain radiographs of the skull showed an enlarged and deepened sella turcica, increased density and thickening of cranial bones, prognathism, and prominent frontal sinuses. Laboratory analysis detected hyperglycaemia. The serum level of growth hormone was not available at that time. The patient received cobalt-60 radiotherapy with a total dose of 6600 rads in 33 fractions to the pituitary fossa through bi-temporal ports (2400 rads in each side) and a frontal port (1800 rads). After discharge, the patient did well. Polyuria and polydipsia were much improved. Serum glucose levels returned to the normal range. The patient returned to his dental practice and there was no medical follow-up. In March 1986 after a 12 year quiescent period he began to experience lethargy and forgetfulness. There was a sudden onset of weakness of the right side limbs on 20 August 1986. A CT scan of the brain showed a mass in the medial temporal lobe and the parasellar and retrosellar regions, with calcification and possible haemorrhage (fig 1a). He was readmitted on 20 September when physical examination revealed acromegalic features, lethargy, decreased power in the right limbs, and disorientation. Laboratory tests showed a normal level of human growth hormone (2.48 ng/ml), and decreased levels of cortisol (<2.0 µg/dl at 7 am), testosterone (<0.1 ng/ml), T3 (74.20 ng/dl), and T4 (4.67 µg/dl). Free T4 (0.82 ng/dl) and TSH (<1.25 uU/ml) were within normal limits. There was a right homonymous hemianopia and optic atrophy. After replacement of steroid and thyroid hormones, the patient underwent a left

Address for reprint requests: Chun-I Huang, M.D., Division of Neurosurgery, Department of Surgery, Veterans General Hospital, Taipei, Taiwan 11217.

Received 10 February 1987 and in revised form 20 April 1987.  
Accepted 27 May 1987

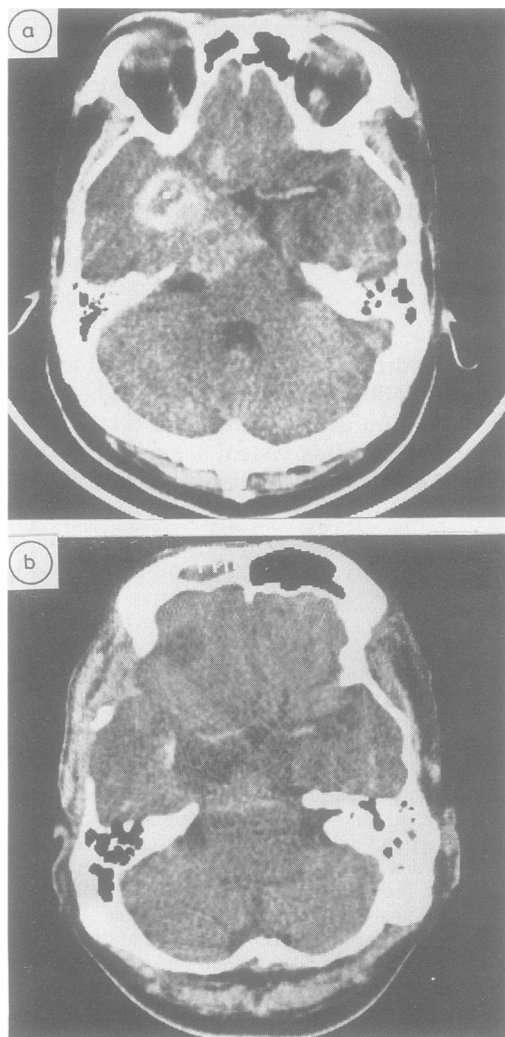


Fig 1 Contrast-enhanced CT scan of the brain, (a) preoperatively showing mass in the left medial temporal lobe, and the parasellar and retrosellar regions with calcification and possible haemorrhage. (b) postoperatively showing a much reduced mass-effect and little presence of residual tumour.

frontotemporal craniotomy with subtotal removal of tumour (fig 2) on 3 October 1986. The tumour was a highly cellular oligodendroglioma with compact collections of uniform cells. The nuclei were moderately pleomorphic and most of the tumour cells had a perinuclear halo or fried egg appearance (fig 3a). Although mitotic figures were few, some features of anaplasia were present in places with endothelial proliferation (fig 3b) and necrosis (fig 3c). Other than the oligodendroglioma, there were no other neoplastic elements. Immunohistochemical staining for GFAP was negative except for occasional entrapped astrocytes. Because the patient

had had a growth hormone secreting pituitary tumour, we also applied immunohistochemical staining for growth hormone and prolactin; all these stains were negative.

The patient's postoperative course was uncomplicated. He regained consciousness and normal mental status, but the right hemiparesis persisted. The postoperative CT scan showed a much smaller mass and little residual tumour (fig 1b).

## Discussion

Radiation therapy exerts its effect by ionisation which leads to the formation of pairs of free radical ions.<sup>5</sup> These free radicals then react with normal cellular structures to cause cell death or damage. If it is the DNA in the chromatin of the target cell that is damaged, these cells may then acquire new phenotypic properties, which may eventually express themselves as a neoplasm. It is not surprising that a relationship between radiation and tumour does exist at the molecular level.<sup>6</sup> Robinson<sup>7</sup> has suggested that patients who receive cranial irradiation for a simple brain tumour are then at higher risk for developing a second intracranial neoplasm, in particular a meningioma. Although post-radiation gliomas are rare in humans, the experimental initiation of gliomas by radiation has been shown in monkeys and rats.<sup>8-10</sup> The inability to establish a link between neoplastic cellular alterations after previous radiation makes the diagnosis extremely controversial in clinical cases. Cahan *et al*<sup>11</sup> proposed four criteria for post-radiation osteogenic sarcoma and these have been generally accepted. After modifying the criteria slightly, we suggest that the most important requirements for radiation-induced tumours of CNS should be as follows: The tumour must have (1) a long latency period sufficient to indicate that the lesion was not already present at the time of irradiation, (2) a location in the previously irra-

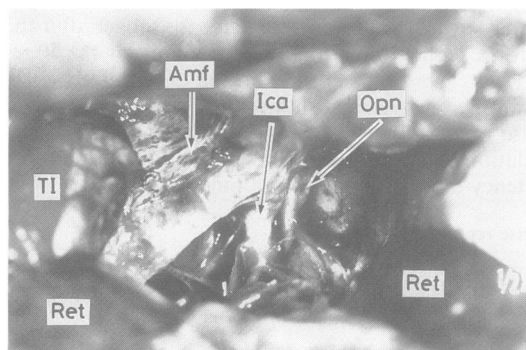


Fig 2 Operative findings after subtotal removal of tumour through left fronto-temporal craniotomy. T1: Temporal lobe, Ret: Retractor, Opn: Optic nerve, Ica: Internal carotid artery, Amf: Anterior middle fossa.

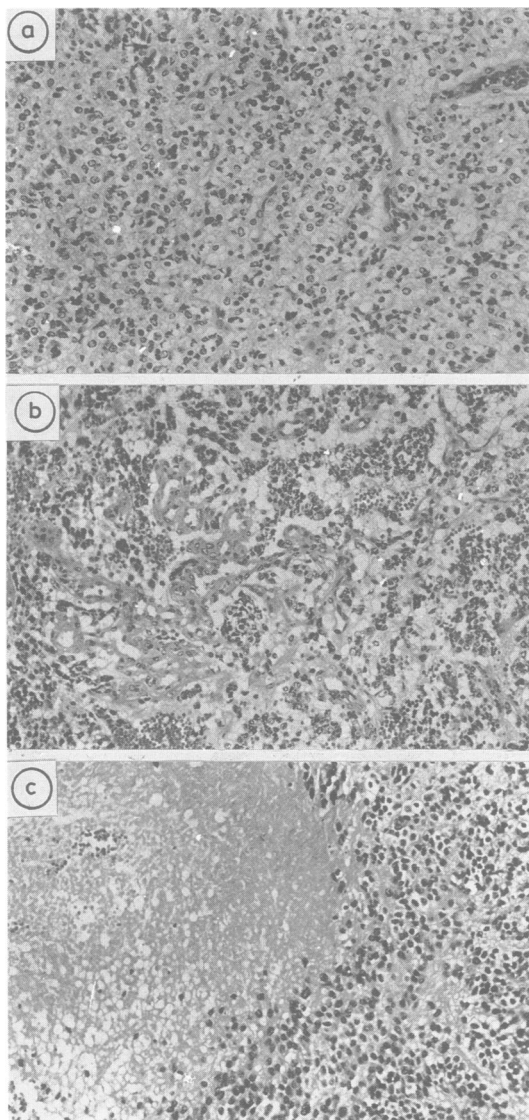


Fig 3 (a) Oligodendroglioma showing fried-egg appearance of the tumour cells. (H&E,  $\times 200$ ), (b) Oligodendroglioma with endothelial proliferation. (H&E,  $\times 160$ ), (c) Oligodendroglioma with necrosis. (H&E,  $\times 150$ ).

diated field, (3) a verified histological difference from the primary condition, and (4) an origin not recognised to be associated with a primary defined genetic syndrome such as neurofibromatosis or tuberous sclerosis. Because the phakomatoses are associated with an increased incidence of multiple tumours of both similar and differing histology,<sup>12,13</sup> it is more

logical, to include the fourth criterion for defining a radiation-induced tumour.

In our case, although there was no histological verification of the primary tumour, an enlarged and deepened sella turcica in an acromegalic patient supports the diagnosis of a growth hormone secreting pituitary adenoma. Furthermore, the long latency period excluded the possibility that an anaplastic oligodendroglioma was present in this location before irradiation. A genetic factor, as in neurofibromatosis or tuberous sclerosis was not present in our patient. Therefore, our case fulfilled our four criteria.

We reviewed and analysed the 31 reported cases of radiation-induced glioma (including our present case) (table 1).<sup>7,14-36</sup> The ratio of male to female is 20:10, with an average age of 13.9 years. The radiation dose ranged from 150 to 6600 rads, with an average latency period of 11.5 years. Most of these patients were young when first irradiated. The second tumour developed at a younger average age (25 to 35 years) compared with the age (40 to 50 years) when naturally occurring tumours are expected within the general population. A long latency period (an average of 11 years) is needed for second tumours to occur, which may explain why most of the reported cases are in the younger age group. That radiation induced oncogenesis is stronger during tissue maturation may be another factor.<sup>5</sup> The male preponderance<sup>8,18,37</sup> is unexplained. The latency of radiation-induced gliomas and sarcomas has been compared with that of other cranial and intracranial tumours induced by radiation. We found that the average latency of reported radiation-induced gliomas and sarcomas has been around 11 years. Meningiomas have had even longer latencies (around 26 years). This discrepancy may be due to the histological behaviour of postradiation tumours. The more benign lesions seem to occur after a longer latency period. Iacoco *et al*,<sup>38</sup> who reviewed 35 patients with postradiation meningiomas, indicated that the average latency in the low-dose-irradiated group (less than 800 rads) was 31.3 years, whereas in the high-dose group it was 20.8 years. These data suggest that the higher the dose of irradiation, the shorter the latency period. However, there was not a correlation between dose and latency in our analyses of 31 cases of radiation-induced gliomas (table 2). We also did not find a correlation between latency and the type of the secondary tumour (table 3). Table 4 shows that a statistically significant difference did exist between the latency of primary haemopoietic system (HS) neoplasia (5.5 years), and that of primary non HS neoplasia (16.1 years). An increased risk of developing a malignant tumour has been noted in patients with congenital immunodeficiency.<sup>39</sup> The weaker immunity present in patients with HS neoplasia may be the explanation.

Table 1 Summary of radiation-induced gliomas in 31 cases

Case No.	Primary condition	Age at R/T (yr)	Sex	Dose (rads)	Latency (yr)	Type of glioma	Location of second tumour	First Author and reference	Published Year
1	Meningioma	?	M	4000	10	Astrocytoma	Cerebrum	Jones (14)	1960
2	Cervical adenitis	11	M	400	11	Glioblastoma	Cerebrum	Saenger (15)	1960
3	Tinea capitis	4	M	500-800	4	Astrocytoma	Optic chiasm	Albert (16)	1966
4	Tinea capitis	10	M	500-800	1	Astrocytoma	Not given	Albert (16)	1966
5	Craniopharyngioma	22	M	5400	6	Glioblastoma	Cerebrum	Komaki (17)	1977
6	Craniopharyngioma	9	F	6007	5	Anaplastic Astrocytoma	Cerebrum	Sogg (18)	1978
7	Medulloblastoma	12	M	5000	11	Anaplastic Astrocytoma	Cerebrum	Kleriga (19)	1978
8	Pineal teratoma	10	M	4000	26	Glioblastoma	Cerebrum	Robinson (7)	1978
9	Meningioma	36	M	2750	21	Glioblastoma	Cerebrum	Robinson (7)	1978
10	Histiocytosis	9 Months	?	600	15	Ependymoma	4th ventricle	Haselow (20)	1978
11	Ependymoma	1	F	3960	5	Glioblastoma	Cerebrum	Bachman (21)	1978
12	Glomus jugulare tumour	44	M	4480	8	Anaplastic Astrocytoma	Cerebrum	Pressig (22)	1979
13	Craniopharyngioma	4	F	6000	8	Glioblastoma	Cerebrum	Gutjahr (23)	1979
14	Pulmonary TB	20	F	150	25	Astrocytoma	Spinal cord	Steinbok (24)	1980
15	Hodgkin's disease	21	M	4969	6	Glioblastoma	Spinal cord	Clifton (25)	1980
16	Ac. lymphocytic leukaemia	2	M	2400	5	Glioblastoma	Cerebrum	Chung (26)	1980
17	Medulloblastoma	5	M	3000	13	Glioblastoma	Cerebrum	Pearl (27)	1980
18	Medulloblastoma	4	F	3500	16	Astrocytoma	Cerebrum	Cohen (28)	1981
19	Choriocarcinoma	17	F	4000	6	Glioblastoma	Cerebrum	Barnes (29)	1982
20	Ac. lymphoblastic leukaemia	4	F	2400	5	Glioblastoma	Cerebrum	Sanders (30)	1982
21	Pituitary adenoma	38	M	4900	14	Glioblastoma	Cerebrum	Piatt (31)	1983
22	Pituitary adenoma	25	M	4500	10	Glioblastoma	Cerebrum	Piatt (31)	1983
23	Ac. lymphoblastic leukaemia	3	F	2400	5	Astrocytoma	Cerebrum	Anderson (32)	1984
24	Scalp haemangioma	24	F	1610	15	Astrocytoma	Cerebrum	Zochodne (33)	1984
25	Craniopharyngioma	11	M	5900	25	Glioblastoma	Cerebrum	Liwnicz (34)	1985
26	Anaplastic ependymoma	2	M	3500	14	Glioblastoma	Cerebrum	Liwnicz (34)	1985
27	Retinoblastoma	2 weeks	M	5500	12	Glioblastoma	Cerebrum	Liwnicz (34)	1985
28	Burkitt's lymphoma	5	M	1800	5	Glioblastoma	Cerebrum	Liwnicz (34)	1985
29	Ac. lymphocytic leukaemia	13	F	2400	7	Anaplastic Astrocytoma	Cerebellum	Raffel (35)	1985
30	Meningioma	32	M	5600	10	Glioblastoma	Cerebrum	Zuccarello (36)	1986
31	Pituitary Adenoma (present case)	26	M	6600	12	Anaplastic Oligodendroglioma	Cerebrum	Huang	1987

R/T: Radiotherapy.  
Ac: Acute.

Multiple gliomas have been described in the literature and, according to Batzderf and Malamud,<sup>40</sup> account for 2-4% of all gliomas. Multiple primary brain tumours of different histological types are encountered rather less frequently. According to the report of Deen and Laws, most of them belong to meningioma-glioma combinations.<sup>41</sup> It has been suggested that the "irritative effect" of a low grade glioma will induce the development of a secondary meningeal tumour; vice versa, a meningioma could induce malignant transformation in the underlying brain parenchyma.<sup>37</sup> Our case is a pituitary

Table 2 Relationship between dose and latency in 31 patients

Dosage (rads)	No. of cases	Latency (average, yr)
Low (< or = 800)	5	11.2
High (> 800)	26	10.8

Table 3 Relationship between pathological type of second tumour and latency

Type	No. of cases	Latency (average, yr)
Astrocytoma	7	10.9
Anaplastic astrocytoma	4	7.8
Glioblastoma	18	11.2
Ependymoma	1	15.0
Anaplastic oligodendroglioma	1	12.0
Total	31	11.5

Table 4 Latency between primary HS\* neoplasia and Non HS neoplasia

Group	Total No.	Case No. in table 1	Latency (Average, yr)
Primary HS neoplasia	6	15, 16, 20, 23, 28, 29	5.5
Primary Non HS neoplasia	25	21-22, 24-27, 30-31	16.1

\*HS: haemopoietic system.

adenoma-oligodendroglioma combination and an "irritative effect" can not have had any role.

It has been suggested also that the presence of gliosis in brain tissue increases the chance of induction of a glioma by radiation.<sup>12-18</sup> Based on our case and our review of the literature it appears that in many cases the initial disease was not likely to be accompanied by gliosis. Thus, the presence of prominent gliosis is not essential for radiation induction of gliomas.

We found reports of only two cases of a glioma occurring in a patient who had received CNS irradiation for pituitary adenoma.<sup>31</sup> We report another case, in which the pathological type was an oligodendroglioma. It is not known why the same primary tumours, such as pituitary adenoma, can develop radiation-induced tumours of different cell types, such as fibrosarcomas, meningiomas or gliomas. From the relatively few reported cases, it is impossible to say for certain if the radiation played a singularly important role in the development of the new tumour or if some underlying or predisposing factors also contributed. Further studies and more data are necessary to elucidate this.

The benefit of postoperative radiation therapy for incompletely resected pituitary adenoma is well documented. The risk of inducing a second tumour should be considered, especially when radiation is used as a primary therapy for a functioning pituitary adenoma, as is suggested by our case report.

## References

- 1 United Nations scientific committee on the Effects of Atomic Radiation: Sources and Effects of Ionizing Radiation. 1977 report to General Assembly, with annexes. New York, United Nations Publications, 1977.
- 2 Modan B, Baidatz D, Mart H, Steinitz R, Levin SG. Radiation-induced head and neck tumours. *Lancet* 1974;i:277-9.
- 3 Noetzi M, Malamud N. Postirradiation fibrosarcoma of the brain. *Cancer* 1962;15:617-22.
- 4 United Nations Scientific Committee on the Effects of Atomic Radiation Report. General Assembly Official Records, New York, United Nations, 1969, 24th session, suppl 13(A/7613):76-77.
- 5 Fajardo LF. *Pathology of Radiation Injury*. New York. Masson Inc. 1982:252-5.
- 6 Vananckeran SC, Whelers KT. Relationship between the repair of radiation-induced DNA damage and recovery from potentially lethal damage in 9L rat brain tumor cells. *Cancer Res* 1984;44:1091-7.
- 7 Robinson RG. A second brain tumor and irradiation. *J Neurol Neurosurg Psychiatry* 1978;41:1005-12.
- 8 Castanera TJ, Tones DC, Kimeldorf DJ, Rosen VJ. The influence of whole body exposure to X-rays or neutrons on the life span distribution of tumors among male rats. *Cancer Res* 1968;28:170-82.
- 9 Kent SP, Pickering JE. Neoplasms in monkeys (*Macaca mulata*) spontaneous and irradiation-induced. *Cancer* 1958;11:138-47.
- 10 Haymaker W, Rubinstein LJ, Miquel J. Brain tumors in irradiated monkeys. *Acta Neuropathol (Berl)* 1972;20:267-77.
- 11 Cahan WG, Woodard HQ, Higinbotham NL, Stewart FW, Coley BL. Sarcoma arising in irradiated bone: Report of 11 cases. *Cancer* 1948;1:3-29.
- 12 Rubinstein LJ. *Tumors of the Central Nervous System (Atlas of Tumor Pathology, 2nd series fascicle 6)*. Washington DC, Armed Forces Institute of Pathology, 1972.
- 13 Courville CB. Multiple primary tumors of the brain: Reviews of the literature and report of 21 cases. *Am J Cancer* 1936;26:703-31.
- 14 Jones A. Supravoltage X-ray therapy of intracranial tumors. *Ann R Col Surg Engl* 1960;27:310-54.
- 15 Saenger EL, Silverman FN, Sterling T, Turner ME. Neoplasia following therapeutic irradiation for benign condition in childhood. *Radiology* 1960;74:889-904.
- 16 Albert RE, Omran AR, Brauen EW, et al. Follow-up study of patients treated by X-ray for tinea capitis. *Am J Publ Health* 1966;56:2114-20.
- 17 Komaki S, Komaki R, Choi H, Correa-paz F. Radiation and drug induced intracranial neoplasm with angiographic demonstration. *Neurol Med Chir (Tokyo)* 1977;17:55-62.
- 18 Sogg RL, Donaldson SS, Yorke CH. Malignant astrocytoma following radiotherapy of a craniopharyngioma. *J Neurosurg* 1978;48:622-7.
- 19 Kleriga E, Sher JH, Nallainathan SK, Sycie SC, Sacher M. Development of cerebellar malignant astrocytoma at site of medulloblastoma treated 11 years earlier. *J Neurosurg* 1978;49:445-9.
- 20 Haselow RE, Nesbit M, Dehner LP, Hkan FM, Mchugh R, Levitt SH. Second neoplasms following megavoltage radiation in a pediatric population. *Cancer* 1978;42:1185-91.
- 21 Bachman DS, Ostrow PT. Fatal long-term sequela following radiation "cure" for ependymoma. *Ann Neurol* 1978;4:319-21.
- 22 Pressig SH, Bohmfalk GL, Reichel GW, Smith MT. Anaplastic astrocytoma following irradiation for a glomus jugular tumor. *Cancer* 1979;43:2243-7.
- 23 Gutjahr P, Dieterich E. Risiko zweiter maligner Neoplasien nach erfolgreicher Tumorbehandlung in Kindersalter. *Deutch Med Wochenshr* 1979;104:969-72.
- 24 Steinbok P. Spinal cord glioma after multiple fluoroscopies during artificial pneumothorax treatment of pulmonary tuberculosis. *J Neurosurg* 1980;52:838-41.
- 25 Clifton MD, Amromim GD, Perry MC, Abadir R, Watt SC, Levy N. Spinal cord glioma following irradiation for Hodgkin's disease. *Cancer* 1980;45:2051-5.
- 26 Chung CK, Stryker JA, Cruse R, Vanucci R, Towfigi J. Glioblastoma multiforme following prophylactic cranial irradiation and intrathecal methotrexate in a child with acute lymphocytic leukemia. *Cancer* 1981;47:2563-6.
- 27 Pearl GS, Mirra SS, Miles ML. Glioblastoma multiforme occurring 13 years after treatment of a medulloblastoma. *Neurosurgery* 1980;6:546-551.
- 28 Cohen MS, Kushner MJ, Dell S. Frontal lobe astrocytoma following radiotherapy for medulloblastoma. *Neurology* 1981;31:616-9.
- 29 Barnes AE, Liwnicz BH, Schellhas HF, Altshuller G, Aron BS, Lippert WA. Successful treatment of placental choriocarcinoma metastatic to brain followed by primary brain glioblastoma. *Gynecol Oncol* 1982;13:108-14.
- 30 Sanders J, Sale GE, Ramberg R, Clift R, Buckner CD, Thomas ED. Glioblastoma multiforme in a patient with acute lymphoblastic leukemia who received a marrow transplantation. *Transplant Proc* 1982;14:770-4.
- 31 Piatt JH, Blue JM, Schold SC, Barger PC. Glioblastoma multiforme after radiotherapy for acromegaly. *Neurosurgery* 1983;13:85-9.
- 32 Anderson JR, Treip CS. Radiation-induced intracranial neoplasms: a report of three possible cases. *Cancer* 1984;53:426-9.
- 33 Zochodne DW, Cairncross JG, Arce FP, et al. Astrocytoma following scalp radiotherapy in infant. *Can J Neurol Sci* 1984;11:475-8.
- 34 Liwnicz BH, Berger TS, Liwnicz RG, Aron BS. Radiation-associated gliomas: A report of four cases and analysis of

- postradiation tumors of the central nervous system. *Neurosurgery* 1985;17:436-45.
- 35 Raffel C, Edwards MSB, Davis RL, Ablin AR. Postirradiation cerebellar glioma. Case report. *J Neurosurg* 1985;63:300-3.
- 36 Zuccarello M, Sawaya R, deCourten-Myers G. Glioblastoma occurring after radiation therapy for meningioma: case report and review of literature. *Neurosurgery* 1986;19:114-9.
- 37 Russell DS, Rubinstein LJ. *Pathology of Tumours of the Nervous System*. London. Arnold. 1977, ed 4.
- 38 Iacono RP, Apuzzo ML, Davis RL, Tsai FY. Multiple meningiomas following radiation therapy for medulloblastoma. *J Neurosurg* 1981;55:282-6.
- 39 Spector BD, Perry GS III, Kersey JH. Genetically determined immunodeficiency disease (GDID) and malignancy: report from the immunodeficiency — cancer registry. *Clin Immunol Immunopathol* 1978;11:12-29.
- 40 Batzdorf U, Malamud N. The problem of multicentric glioma. *J Neurosurg* 1963;20:122-36.
- 41 Deen HG, Laws ER. Multiple primary brain tumors of different cell types. *Neurosurgery* 1981;8:20-5.