

nor structural cause was found. The presence of biological markers of lead intoxication and the favourable response to chelation therapy allowed the diagnosis of acute lead encephalopathy.<sup>2</sup> The search for recent occupational and environmental exposure was negative. The normal blood lead in the patient's wife rules out some other environmental source which might be unnoticed. Therefore, the only apparent lead exposure was his past work. The previously reported cases of lead encephalopathy occurred shortly after recent lead exposure<sup>2</sup> except for patients with retained bullets.<sup>3-5</sup> On the other hand, it is known that lead can be stored in bone for decades<sup>6</sup> and mobilised by an intercurrent stress with increased bone turnover.<sup>1,3-5</sup> The gastroenteric process and bed rest in this patient could have been the conditions which caused lead mobilisation.

To our knowledge, this is the first case reported of acute encephalopathy as a likely delayed presentation of occupational lead exposure. This observation emphasises the possibility of severe late toxicity as the first manifestation of a remote lead exposure.

CARLOS GUIJARRO  
JUAN DE D GARCÍA-DÍAZ  
OLGA HERRERO  
JOSÉ L ARANDA  
*Departamento de Medicina Interna,  
Hospital Primero de Octubre,  
Universidad Complutense,  
Carretera de Andalucía, km. 5,400,  
28041 Madrid, Spain*

Correspondence should be addressed to Carlos Guijarro.

#### References

- 1 Cullen MR, Robins JM, Eskenazi B. Adult inorganic lead intoxication: presentation of 31 new cases and a review of recent advances in the literature. *Medicine (Baltimore)* 1983; **62**:221-47.
- 2 Witfield CR, Ch'ien LT, Whitehead JD. Lead encephalopathy in adults. *Am J Med* 1972; **52**:281-98.
- 3 Cagin CR, Diloy-Puray M, Westerman MP. Bullets, lead poisoning and thyrotoxicosis. *Ann Intern Med* 1978; **89**:509-11.
- 4 Dillman RO, Crumb CK, Lidsky MJ. Lead poisoning from a gunshot wound. Report of a case and review of the literature. *Am J Med* 1979; **66**:509-14.
- 5 Linden MA, Manton WI, Stewart RM, Thal ER, Feit H. Lead poisoning from retained bullets. Pathogenesis, diagnosis and management. *Ann Surg* 1982; **195**:305-14.
- 6 Rabinowitz MB, Wetherill GW, Kopple JD. Lead metabolism in the normal human: stable isotope studies. *Science* 1973; **182**: 725-7.

#### Progressive aphasia with right-sided extrapyramidal signs: another manifestation of localised cerebral atrophy

Sir: Slowly progressive aphasia without generalised dementia has been recognised as a degenerative condition with non-Alzheimer pathology<sup>1,2</sup> and localised histological changes have been demonstrated in the dominant perisylvian regions.<sup>3</sup> We report a unique case in which progressive aphasia is combined with right-sided tremor and rigidity. Computed tomography and single photon emission tomography indicated a striking, predominantly left hemisphere disorder.

A right handed 64 year old man presented with an 18 month history of insidiously progressive deterioration in his language together with tremor of the right hand. He had been previously well and there was no history of vascular disease or head injury. His mother, who died aged 83, was said to have had Parkinson's disease and became "confused and wandering" late in life. General physical examination was normal. Visual fields were intact but eye movements were abnormal with reduced voluntary upgaze and impaired convergence. He had an expressionless facies and slight right-sided facial asymmetry. Tone was minimally increased on the right and there was a resting tremor of the right hand. Reflexes were symmetrically brisk and plantar responses flexor. Sensory testing, dexterity and gait were normal.

Neuropsychological assessment revealed a selective language disorder. His spontaneous speech was non-fluent, stuttering and effortful with word finding difficulty and the occasional intrusion of literal and verbal paraphasias. Comprehension and repetition were mildly impaired. He could read aloud and understand single words, but misread complete phrases and sentences. His writing, although conveying the sense adequately, contained spelling errors and was telegraphic in style. In contrast to his impaired linguistic ability, praxis, visual perception, spatial localisation and navigational skills and non-verbal memory were preserved. His personality was unchanged and his social conduct was appropriate.

Computed tomography revealed widening of the left sylvian fissure and prominence of the left lateral ventricle. Otherwise, routine laboratory and neurological investigations including electroencephalography were normal. Carotid angiography demonstrated a tonsillar loop of the right internal carotid artery but was otherwise normal.

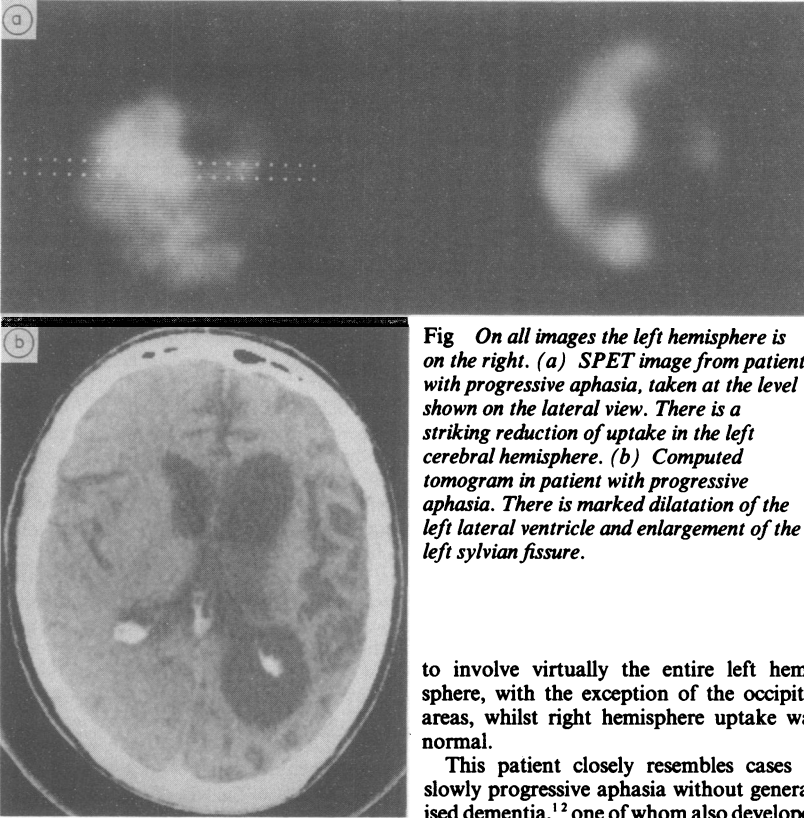
Two years later he had deteriorated both physically and in his powers of communica-

tion. Neurological examination revealed emotional lability, increase in tremor of his right hand, moderate right-sided hypertonia and bradykinesia. He dragged his right leg when walking. His spontaneous speech was limited to "yes", "no" and infrequent stereotyped phrases. Occasional neologisms occurred. Comprehension had deteriorated although he could follow elementary commands. He was severely anomic. He could no longer sign his name. He had difficulty communicating by gesture or pantomime. Perceptual and spatial abilities remained well preserved. Memory could not be formally tested, although his wife believed that he could recall day to day events.

Single photon emission tomography, using the tracer <sup>99m</sup>Tc-HMPAO, demonstrated a striking reduction in uptake in the left frontal, temporal and parietal regions and in the left subcortex, whilst right hemisphere uptake was normal (fig (a)).

One year later a mild right-sided pyramidal weakness had developed in addition to the extrapyramidal signs. Tendon reflexes on the right were brisk and the right plantar response equivocal. He had a right-sided grasp reflex, with pout and sucking reflexes. Speech was limited to arbitrary production of "yes" and "no", and comprehension to following midline commands. Perception and spatial functions again appeared preserved in that he negotiated his environment without becoming lost, and recognised objects, oriented and used them appropriately. Performance was normal on a forced choice object recognition test suggesting some preservation of visual memory. His personality remained unchanged and he continued to demonstrate initiative in daily activities. A repeated electroencephalogram remained normal whilst computed tomography demonstrated increased atrophy and ventricular dilatation on the left, with the addition of mild right-sided involuntional changes (fig (b)).

There are strong grounds for assuming that this patient has a degenerative condition due to localised cerebral atrophy. There has been a slow, progressive development of neurological signs in the complete absence of stroke-like episodes and without risk factors for vascular disease. Cerebral angiography has excluded large vessel disease and the possibility that emboli from the heart or small vessel disease would produce such a striking, predominant involvement of the left cerebral hemisphere is unlikely. Computed tomography showed no low density lesions to suggest cerebral infarction. The electroencephalogram was normal whereas in vascular dementia focal slowing is usual.<sup>4</sup>



**Fig** On all images the left hemisphere is on the right. (a) SPET image from patient with progressive aphasia, taken at the level shown on the lateral view. There is a striking reduction of uptake in the left cerebral hemisphere. (b) Computed tomogram in patient with progressive aphasia. There is marked dilatation of the left lateral ventricle and enlargement of the left sylvian fissure.

to involve virtually the entire left hemisphere, with the exception of the occipital areas, whilst right hemisphere uptake was normal.

This patient closely resembles cases of slowly progressive aphasia without generalised dementia,<sup>1,2</sup> one of whom also developed a right hemi-paresis.<sup>14</sup> Left temporal and parietal hypometabolism found by positron emission tomography<sup>2</sup> is consistent with the left hemisphere abnormality demonstrated in the present case. Although an association has previously been reported between progressive aphasia and extrapyramidal features,<sup>15</sup> unlike the present case, this was in the context of more widespread cognitive changes, indicating bilateral affection. Occasionally extrapyramidal disorder has occurred in combination with fronto-temporal atrophy,<sup>16</sup> but most commonly with additional clinical features of motor neuron disease.<sup>17,18</sup>

Common to forms of localised cerebral atrophy are the pathological findings of cell loss, gliosis and spongy change<sup>3,14,19,20</sup> and a minority of these cases have additional neuronal swellings and argyrophilic inclusions. There appears to be a spectrum of topographical distribution of pathological change. In most cases both frontal and temporal lobes are involved but purely frontal, purely temporal and predominantly subcortical presentations have been described.<sup>16,21</sup> In other cases with clinical features of motor neuron disease there has

been additional involvement of the corticospinal tracts and anterior horn cells.<sup>17,18</sup> Cases of progressive aphasia without dementia have demonstrated pathological change in the dominant perisylvian region. The case described in this letter is an example of a predominantly left hemisphere degeneration presumably involving primarily the perisylvian regions and subcortex.

It is suggested that the clinical picture in our patient of progressive aphasia and progressive right-sided extrapyramidal signs represents one of a spectrum of possible presentations of localised cerebral atrophy all of which may share a similar pathological basis.

PJ GOULDING  
B NORTHERN  
JS SNOWDEN  
N MACDERMOTT  
D NEARY

Department of Neurology,  
The Royal Infirmary,  
Manchester M13 9WL, UK

#### References

- Mesulam N-M. Slowly progressive aphasia without generalised dementia. *Ann Neurol* 1982;11:592-8.
- Chawluk JB, Mesulam M-M, Hurtig H, et al. Slowly progressive aphasia without generalised dementia: studies with positron emission tomography. *Ann Neurol* 1986;19:68-74.
- Kirshner HS, Tanridag O, Thurman L, Whetsell WO. Progressive aphasia without dementia; two cases with focal spongiform degeneration. *Ann Neurol* 1987;22:527-32.
- Roberts MA, McGeorge AP, Caird FI. Electroencephalography and computerised tomography in vascular and non-vascular dementia in old age. *J Neurol Neurosurg Psychiatry* 1978;41:903-6.
- Neary D, Snowden JS, Bowen DM, et al. Neuropsychological syndromes in presenile dementia due to cerebral atrophy. *J Neurol Neurosurg Psychiatry* 1986;49:163-74.
- Appel J, Kertesz A, Fisman M. A study of language functioning in Alzheimer patients. *Brain Lang* 1982;17:73-91.
- Johannesson G, Hagberg B, Gustafson L, Ingvar DH. EEG and cognitive impairment in presenile dementia. *Acta Neurol Scand* 1979;59:225-40.
- McGeer PL. Brain imaging in Alzheimer's disease. *Br Med Bull* 1986;42:22-8.
- Foster NL, Chase TN, Mansi L, et al. Cortical abnormalities in Alzheimer's disease. *Ann Neurol* 1984;16:649-54.
- Duara R, Grady C, Haxby J, et al. Positron emission tomography in Alzheimer's disease. *Neurology* 1986;36:879-87.
- Neary D, Snowden JS, Shields RA, et al. Single photon emission tomography using <sup>99m</sup>Tc-HM-PAO in the investigation of dementia. *J Neurol Neurosurg Psychiatry* 1987;50:1101-9.

It is unlikely that this patient suffers from Alzheimer's disease. The presence of progressive and selective language disorder in the absence of other cognitive deficits is distinct from the characteristic pattern of Alzheimer dementia, in which linguistic impairment is combined with profound amnesia and visuo-spatial impairment.<sup>3</sup> Moreover, the effortful, paraphasic speech is dissimilar to the fluent speech normally associated with Alzheimer's disease.<sup>6</sup> The normal electroencephalogram and strikingly asymmetric computed tomogram contrast with the significant slowing of wave forms on electroencephalography<sup>7</sup> and either normal or generalised atrophic scan appearances<sup>8</sup> reported in Alzheimer's disease. Reduced uptake in the temporo-parietal regions in Alzheimer's disease has consistently been demonstrated by positron emission tomography<sup>9,10</sup> and single photon emission tomography.<sup>11,12</sup> Whilst the left hemisphere may be predominantly affected in patients with disproportionate language disorder,<sup>13</sup> abnormalities are not exclusively unilateral. In the present case, abnormalities appeared

- 12 Johnson KA, Holman LB, Mueller SP, *et al.* Single photon emission computed tomography in Alzheimer's disease. *Arch Neurol* 1988;45:392-6.
- 13 Foster NL, Chase TN, Fedio P, *et al.* Alzheimer's disease: focal cortical changes shown by positron emission tomography. *Neurology* 1983;33:961-5.
- 14 Taboada E, Dickson D, Horoupian D, Davies P. Clinicopathologic and neurochemical studies of one case of dysphasic dementia. *J Neuropathol Exp Neurol* 1986;45:323.
- 15 Morris JC, Cole M, Banker BQ, Wright D. Hereditary dysphasic dementia and the Pick-Alzheimer spectrum. *Ann Neurol* 1984;16:455-66.
- 16 Tissot R, Constantinidis J, Richard J. Picks disease. In: Vinken PJ, Bruyn GW, Klawans HL, Fredriks JAM, eds. *Handbook of Clinical Neurology Neurobehavioural disorders*. Amsterdam, 1985;46:233-46.
- 17 Hudson AJ. Amyotrophic lateral sclerosis and its association with dementia, parkinsonism and other neurological disorders: a review. *Brain* 1981;104:217-47.
- 18 Salazar AM, Masters CL, Gadjusek DC, Gibbs CJ. Syndromes of amyotrophic lateral sclerosis and dementia: relation to transmissible Creutzfeldt-Jakob disease. *Ann Neurol* 1983;14:17-26.
- 19 Wechsler AF, Verity MA, Rosenchein S, Fried I, Scheibel AB. Pick's disease. A clinical, computed tomographic and histologic study with Golgi impregnation observations. *Arch Neurol* 1982;39:287-90.
- 20 Brun A. Frontal-lobe degeneration of non-Alzheimer type. I. Neuropathology. *Arch Gerontol Geriatr* 1987;6:193-207.
- 21 Munoz-Garcia D, Ludwin SK. Classic and generalised variants of Pick's disease: a clinicopathological, ultrastructural and immunocytochemical comparative study. *Ann Neurol* 1984;16:467-80.

earlier, over a week he developed severe progressive ataxia, complete external and internal ophthalmoplegia, the eyes remaining in neutral position, ptotic but without diplopia, and general arreflexia. Consciousness was normal. CSF showed 0 cells, glucose 0.68 g/l and protein 0.63 g/l. In the next few days, transitory breathing and swallowing difficulties developed, as well as mild weakness of the facial musculature. In this situation of complete ocular paralysis, the patient made constant gesticulation due to frequent, occasionally sustained, bilateral blepharospasm attacks. This picture regressed to the previous situation after the ophthalmoplegia resolved some months later.

The severe aggravation of facial spasms in our case was striking, well in excess of what could have been expected from the emotional stress of hospitalisation or appearance of new symptoms. A coincidental relation to an improbable midbrain lesion is purely speculative. A lesion located in the midbrain tegmentum was discovered in only one case of Fisher's syndrome<sup>3</sup> and had not been confirmed in other necropsy cases. On the other hand, in only one case of blepharospasm was a well-localised upper brain stem lesion found.<sup>4</sup> In our patient, the futility of efforts to counter ocular paralysis and palpebral weakness (m. elevator palpebrae) may have accentuated the actions of antagonist muscles (m. orbicularis oculi). The excess of frustrated central excitation and lack of reciprocal inhibition is considered the EMG pattern of dystonia<sup>5</sup> and could explain our case.

E GARCIA-ALBEA  
Neurology Service Hospital de Alcalá de  
Henares  
Ctra Alcalá-Meco  
Alcalá de Henares  
28880 Madrid Spain

Accepted 6 September 1988

### Severe aggravation of blepharospasm in Fisher's syndrome

Sir: Essential blepharospasm has been considered a cranial dystonia caused by a biochemical imbalance of the extrapyramidal system<sup>1,2</sup> with no relevant peripheral nervous system contribution. Fisher's syndrome is characterised by external ophthalmoplegia, ataxia and arreflexia and represents a limited form of acute idiopathic polyneuropathy (Guillain-Barré) syndrome. Both processes coincided in a 67 year old male. At 20 years of age he began to suffer occasional involuntary lid closure, more prominent in the right eye, but without disability. These spasms had increased slightly in recent years, often triggered by bright light. After an episode of acute febrile rhinopharyngitis 15 days

### Orthostatic tremor: diagnostic entity or variant of essential tremor?

Sir: Heilman<sup>1</sup> described three patients with orthostatic tremor, that is, tremor of the legs and trunk which commenced shortly after standing but disappeared when walking, leaning against a support, sitting or lying. Heilman considered orthostatic tremor to be a distinct neurological entity related to the maintenance of static posture.

Certain features distinguish orthostatic tremor from classical essential tremor. The oscillation frequency of orthostatic leg tremor has been reported to be between 14 and 18 Hz,<sup>2,4</sup> far higher than the frequency range of classical essential tremor.<sup>5</sup> Furthermore, it has been reported that propranolol, the drug of choice in essential tremor, is ineffective in orthostatic tremor.<sup>6</sup> Clonazepam (2-4 mg/day) has been found to be beneficial in orthostatic tremor<sup>1,6</sup> but to be of little benefit in essential tremor.<sup>7</sup>

There is, however, some overlap in the phenomenology of orthostatic tremor and essential tremor. One of Heilman's orthostatic tremor patients had a concurrent postural tremor of the hands and a family history of essential tremor.<sup>1</sup> Wee *et al*<sup>6</sup> described a family in which some members had a 7-8 Hz tremor of the hands which was responsive to propranolol, and others had a 6-7 Hz tremor of the legs on standing which was responsive to clonazepam but not to beta-blockers.

We describe a patient with a diagnosis of essential tremor of the hands and legs. Leg tremor, but not hand tremor was successfully treated with clonazepam.

A 53 year old woman had a 15 year history of trembling of the legs when standing unsupported. The tremor disappeared on walking or when leaning against a support. There was no tremor at rest or when seated with the legs held outstretched against gravity. For the last 3 years a postural tremor of the hands had been also present. On examination, there were no general or neurological abnormalities other than tremor (see below). In particular there were no cerebellar or Parkinsonian signs. Her father had a 6 year history of hand tremor. Objective (accelerometric) measures showed a 7.0 Hz tremor of the distal muscles of the upper limbs when held outstretched in pronated posture. A 6.4 Hz tremor was present in the proximal muscles of the lower limbs when standing but was absent during sitting and walking. Diazepam had been tried without success. Propranolol (30 mg/day) was ineffective but higher doses were not tried. Primidone initially produced a marked

### References

- 1 Marsden CD. Blepharospasm—oromandibular dystonia syndrome (Brueghel's syndrome). *J Neurol Neurosurg Psychiatry* 1976;39:1204-9.
- 2 Garcia-Albea E, Franch O, Muñoz D, Ricoy JR. Brueghel's syndrome, report of a case with postmortem studies. *J Neurol Neurosurg Psychiatry* 1981;44:437-40.
- 3 Derakshan I, Lofti J, Kautman B. Ophthalmoplegia, ataxia and hyporeflexia (Fisher's syndrome). *Eur Neurol* 1979;18:361-6.
- 4 Jankovic J, Patel SC. Blepharospasm associated with brainstem lesions. *Neurology* 1983;33:1237-40.
- 5 Rothwell JC, Obeso A, Marsden CD. Pathophysiology of dystonias. In: Desmond JE *Advances in Neurology*, vol. 39, ed New York: Raven Press. 1983:851-63.

Accepted 22 September 1988