

## Recovery after optic neuritis in childhood

A KRISS,\*† D A FRANCIS,†‡ F CUENDET,\*|| A M HALLIDAY,† D S I TAYLOR,\*†  
J WILSON,\* J KEAST-BUTLER,§ J R BATCHELOR,‡ W I McDONALD†

From The Hospital for Sick Children,\* London, The National Hospitals for Nervous Diseases,† and The Royal Postgraduate Medical School,‡ Hammersmith Hospital, London, Addenbrooke's Hospital,§ Cambridge, UK, and Hôpital de L'Enfance,|| Lausanne, Switzerland

**SUMMARY** Thirty-nine children who presented with optic neuritis in childhood were reviewed after a follow up period from 3 months to 29 years (mean 8.8 years). At follow-up, 30 out of 39 (77%) of the children had had no further episodes and in three (8%) there was recurrence of optic neuritis alone. Multiple sclerosis had developed in six patients (15%), a much lower frequency than after optic neuritis in adult life. Regardless of the initial degree of visual impairment or neurological outcome, the visual prognosis was excellent. Pattern evoked potentials at follow-up were much more frequently normal (55%) than in adults (10%) after optic neuritis.

Attacks of optic neuritis in childhood are usually bilateral and often associated with a febrile illness. Visual symptoms tend to improve rapidly, especially with steroid therapy, and visual acuities are often normal within 4-6 weeks of onset.<sup>1</sup> The frequency of multiple sclerosis after optic neuritis in childhood appears to be low.<sup>2-5</sup> In contrast, optic neuritis in adult life is usually unilateral, and the risk of developing multiple sclerosis is of the order of 70% in the UK.<sup>6</sup> Persistent visual loss is uncommon in both adults and children,<sup>5,6</sup> the former, however, often having severe optic atrophy and loss of the nerve fibre layer of the retina. Conduction in the optic nerve as inferred from the visual evoked potential (VEP) to pattern stimulation is persistently abnormal in most adults; little is known about it in childhood. Since a small study referred to in a review<sup>6</sup> had revealed a surprisingly high incidence of normal responses (10/18 cases),<sup>6</sup> we examined the VEPs in the course of a follow-up study 3 months to 29 years (mean 8.8 years) after an episode of optic neuritis in childhood. Clinical details and follow up data after a mean of 4.6 years on some of these patients has been reported previously.<sup>1</sup>

### Patients and methods

The medical records were reviewed of a total of 92 children

Address for reprint requests: Professor W I McDonald, Institute of Neurology, Queen Square, London WC1N 3BG, UK.

Received 1 March 1988.

Accepted 13 June 1988

with a diagnosis of "optic neuritis" who presented between 1951 and 1985 to the Hospital for Sick Children, Great Ormond Street, and the National Hospitals for Nervous Diseases, London.

Fifty-two patients were excluded for the following reasons: inadequate documentation or follow up of less than 3 months; evidence of previous neurological deficit; undiagnosed amblyopia or systemic diseases known to be associated with ocular pathology; diabetes; hypertension; leukaemia; syphilis; vitamin deficiency; and rheumatic heart disease. The remaining 39 patients were re-examined. VEPs were recorded in 20 patients and HLA typing was carried out in 28 patients.

All patients recalled for review were aged under 16 years at the onset of their acute visual loss, datable to within 14 days. The clinical diagnosis of optic neuritis was made on the basis of decreased central vision with at least two other signs: afferent pupillary defect; central or paracentral scotoma; colour vision deficit; or optic disc swelling. Patients were further classified as having either unilateral or bilateral optic neuritis; bilateral simultaneous optic neuritis was defined as involvement of both eyes simultaneously or within a period of 2 weeks, and bilateral sequential optic neuritis as involvement of the two eyes more than 2 weeks apart. The clinical development of multiple sclerosis was assessed using the criteria defined by Poser *et al.*<sup>7</sup>

### Visual evoked potentials

Visual evoked potentials to pattern flash stimulation were recorded in 20 patients. For pattern reversal stimulation a high-contrast (93%) black and white checkerboard pattern of 50 minute checks was projected on to a screen placed one metre in front of the subject. The stimulus field subtended a 16° radius at the viewing eye. The pattern was moved from side to side through one check at the rate of two per second; the transition time of the movement was 10 ms. Black and

white checks had an intensity of 8.2 cd/m<sup>2</sup> and 227 cd/m<sup>2</sup>, respectively.

Occipital responses were recorded from a transverse row of five electrodes, spaced 5 cm apart on a horizontal line 5 cm above theinion, referred to a common electrode (F<sub>2</sub>, 10–20 system). Responses to 200 movements of the checkerboard were averaged and responses were obtained to independent full field, left and right half field (0–16°r) and central field (0–4° r) stimulation. The recording band pass was set between 0.1 Hz to 2 kHz (–3 dB points).

Serial recordings (at presentation and later) were available in eight patients. VEPs from three patients had previously been recorded in another laboratory and included in a previous brief report;<sup>6</sup> these patients were re-examined for the present study.

#### Tissue typing

Twenty-eight patients were tissue-typed for HLA-A, -B, -Cw and DR antigens. Using conventional microcytotoxicity testing<sup>8</sup> with typing sera which defined a total of 65 HLA specificities. A control group of 164 healthy volunteers were tissue-typed for the same antigens.

## Results

### Clinical features

Findings during the attacks in some of the present patients have been described in detail elsewhere.<sup>1</sup> Briefly, there were 29 girls (74%) and 10 boys (26%). The ages at which the children experienced attacks ranged from 3 to 15 years (mean 8.6 years). There appeared to be a seasonal peak with nearly twice as many cases presenting in April as in any other month (see fig 1) and overall 46% of children had an associated febrile prodrome. Twenty-nine (74%) children in the group had bilateral attacks (25 bilateral simultaneous; four bilateral sequential; and 10 (26%) were unilateral (four right eye, six left eye). Twenty-nine children (74%) had swollen optic discs at onset and in 38 children (98%), there was a dense central scotoma and marked impairment of colour vision. Nine patients (23%) had other neurological signs or symptoms during or within 6 weeks of onset of optic neuritis (five patients had encephalomyelitis, one had meningitis, and three patients had pyramidal involvement).

Examination of the cerebrospinal fluid was performed in 21 children at presentation and was found to be normal in 11. In three cases there was a modest pleocytosis and elevated protein level; five had pleocytosis only and an isolated increase in protein was found in two cases.

**Follow up** The mean follow up period for the 39 cases was 8.8 years (SD 7, range 3 months–29 years). Most of the patients had normal acuities at follow up: in 53 of the examined eyes (78%) acuity was 6/6 or better. No visual field deficit was detected in 35 (65%) of the 54 eyes previously affected. Nine (17%) had a

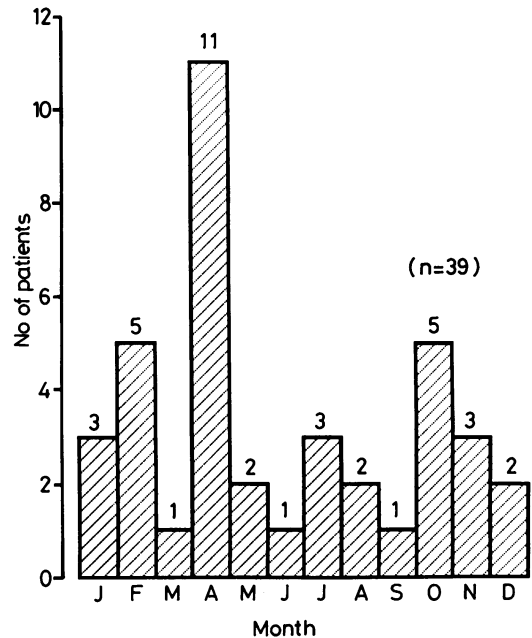


Fig 1 Histogram showing the month of onset of optic neuritis in the 39 children selected for the study.

residual central visual field defect and in 10 (18%) there was a peripheral defect consistent with moderate constriction of the visual field. Thirty-two patients (82%) had either a slight colour deficit or no deficit at all. In the remaining patients there were more definite problems with colour discrimination and in one patient the defect was marked.

Two patients (5%) fulfilled the criteria for clinically definite multiple sclerosis and four patients (10%) were classified as clinically probable multiple sclerosis. Both groups will be discussed together. Three were from the group of 25 patients who originally had bilateral simultaneous attacks and three were from the group of 14 patients who had unilateral or sequential attacks; the difference was not significant ( $p > 0.26$ ). Five of the 30 patients without additional neurological signs in the initial illness later developed multiple sclerosis, compared with one patient out of nine with them. These differences were not significant ( $p > 0.39$ ). Four patients (10%) in the whole series (two with unilateral optic neuritis and two with bilateral optic neuritis) had one or more recurrent attacks of optic neuritis. Only one of these developed other evidence of multiple sclerosis.

### Visual evoked potential findings

Table 1 gives details of the clinical findings for those patients who had a VEP examination. Four patients

Table 1 Summary of clinical findings in patients who had a VEP test

Eye involvement	Clinical findings at first presentation		Findings at follow up			
	Other CNS involvement?		Visual deficits on clinical testing*		VEP abnormal†	
	Yes	No	Unilateral	Bilateral	Unilateral	Bilateral
Unilateral 4 patients	0	4	3	0	3	1
Bilateral 16 patients	6	10	2	7	1	4

\*Visual field and/or colour deficits.  
†Latency beyond normal limits.

presented with unilateral attacks, while the remaining 16 had bilateral attacks which were either simultaneous or sequential.

The four patients presenting with unilateral attacks all had abnormal VEPs on follow-up. Three of the four cases had unilateral VEP abnormalities in the originally affected eye and one case had bilateral VEP delays. In contrast, only five out of 16 patients who had had bilateral attacks (four simultaneous, one sequential) showed VEP delays at follow-up. In four of these five cases, the delays were bilateral and in the remaining case it was unilateral.

Eight of the 20 patients (40%) had significantly delayed pattern VEPs to the wide field stimulus on follow-up (fig 2). Four of these had bilateral delays, and four had unilateral abnormalities, including one with no recordable response from the affected eye. In addition, there was one further patient who had a significantly delayed response from the affected eye on follow-up only when tested with a small (0-4° r) stimulus confined to the macular part of the visual field. Thus, in total, 45% of the patients had abnormal VEPs at final follow up.

Figure 3 (SJ) shows the responses of a patient who

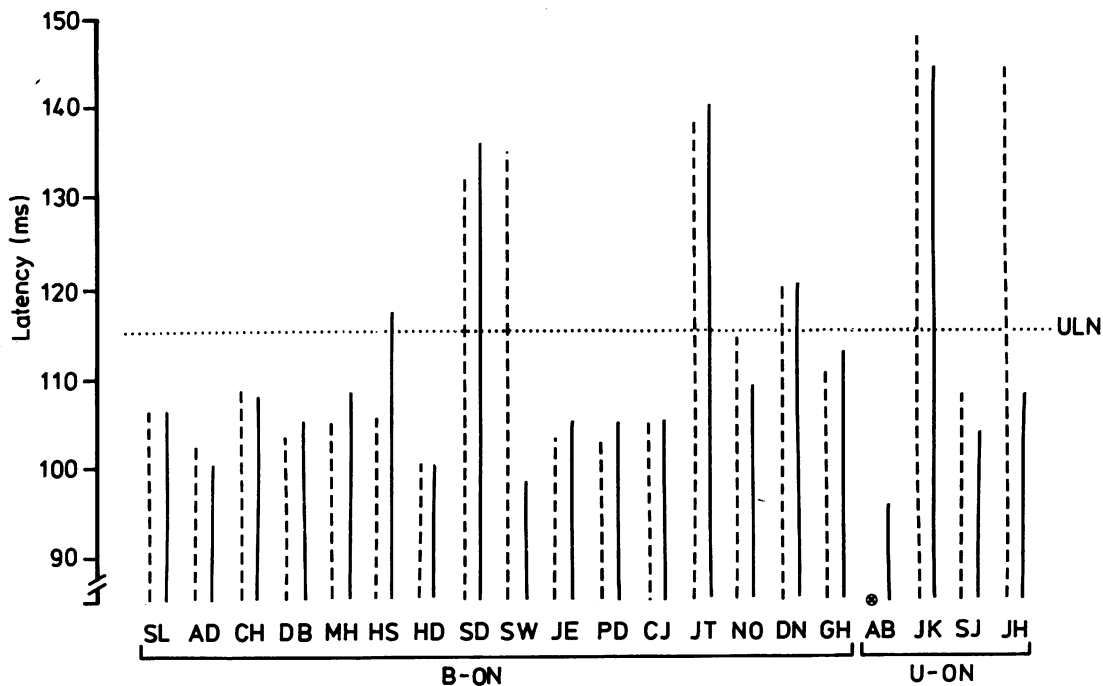


Fig 2 Latency of the pattern reversal P100 to full-field stimulation of the left eye (broken line) and right eye (solid line) recorded for each patient at follow-up. The +2.5 SD upper limit of normal (ULN) is shown by the dotted line. Patients who had bilateral optic neuritis (B-ON) and unilateral optic neuritis (U-ON) are grouped to the left and right, respectively. In one patient (AB) no response was detectable from the left eye.

S.J.

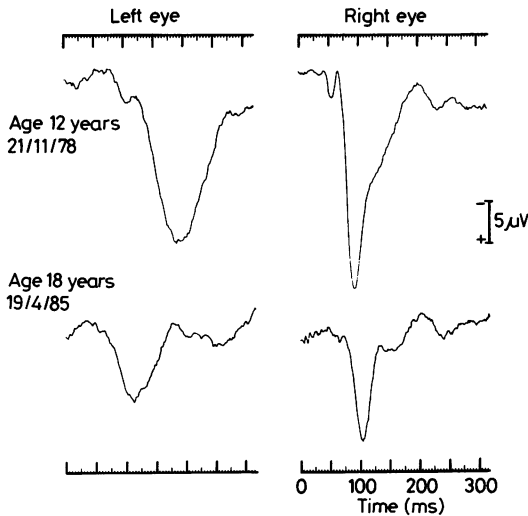


Fig 3 Mid-occipital pattern reversal VEPs to full-field stimulation in a patient (SJ) recorded at the time of the acute unilateral optic neuritis affecting the left eye (upper traces) and at follow-up (lower traces). Note the markedly delayed, broadened, P100 from the left eye at the first recording. At follow-up the left eye P100 is of normal latency but degraded in waveform compared to that from the right eye.

had a delayed response from the left eye at presentation with a left unilateral optic neuritis, and a response of normal latency six and a half years later.

Figure 4 (DM) contrasts with fig 3 in showing the responses of a patient who had mildly though significantly delayed responses from each eye on follow-up. He had presented with bilateral simultaneous optic neuritis without any other accompanying neurological signs or symptoms, at the age of 7 years. At follow-up, when he was aged 14 years, the pattern VEPs had a well-defined, delayed, main positive component from each eye (left eye, 120 ms; right eye, 120 ms).

#### Tissue-typing findings

Table 2 summarises the findings for the multiple sclerosis associated antigens in the 28 patients who were assessed. No statistically significant differences were found when comparing patients who had had optic neuritis with the control group, although a higher than expected frequency of HLA-DR2 types was noted (39.5% vs 21.5%;  $0.10 > p > 0.05$ ). The frequencies of the antigens HLA-A3, B7, DR2 and the combination B7-DR2 in those patients with bilateral optic neuritis did not differ significantly from their respective control frequencies; however both HLA-B7

and B7-DR2 were significantly increased ( $p < 0.05$ ) in the small group of nine patients with unilateral optic neuritis, and HLA-DR2 was twice the frequency found in controls, although this just failed to reach statistical significance ( $0.1 > p > 0.05$ ). Two of the nine tissue-typed individuals who had had unilateral optic neuritis subsequently developed multiple sclerosis. One of these patients carried the haplotype HLA A3-B7-DR2, and the other HLA A1-B8-DR3. One of the 19 typed patients who had suffered bilateral optic neuritis later developed multiple sclerosis, and this individual also had the type HLA A3-B7-DR2. However, these haplotypes occurred in four other individuals in whom no evidence was apparent of demyelination subsequent to the attacks of optic neuritis.

#### Discussion

The present findings represent the largest series published to date and confirm that both the visual and the neurological prognoses following optic neuritis in childhood are good. Despite the development of optic disc pallor in 88% of affected eyes, 78% recovered well to have a visual acuity of 6/6 or better. In only two eyes was the acuity at follow up worse than 6/60. These findings are concordant with those of Haller and Patzold<sup>9</sup> who found 18% of affected eyes to have an acuity of 6/12 or less, and with those of Parkin *et*

D.M.

Age 14

Date 3/4/85

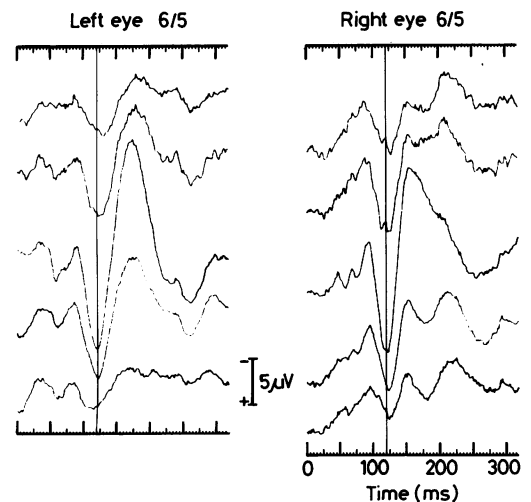


Fig 4 Delayed pattern VEPs from patient, aged 14 years, who presented with bilateral simultaneous optic neuritis at the age of 7 years. P100 latency at 120 ms for each eye (upper limit of normal 115 ms).

Table 2 Frequencies of the multiple sclerosis associated antigens in bilateral and unilateral optic neuritis of childhood compared with healthy controls

	Bilateral ON	Unilateral ON	Controls
A3	3/19 (16%)	3/9 (33%)	48/164 (30%)
B7	7/19 (37%)	6/9 (68%) <sup>P*</sup>	40/164 (25%)
DR2	7/19 (37%)	4/9 (44%)	35/164 (22%)
B7-DR2	6/19 (32%)	4/9 (44%) <sup>P†</sup>	21/164 (13%)

Unilateral ON vs controls <sup>P\*</sup> <0.011 (Fisher exact test).

Unilateral ON vs controls <sup>P†</sup> <0.05 (Fisher exact test).

*al*<sup>5</sup> who found only one eye in 19 patients with an acuity of less than 6/9.

We found at follow up that 33 patients (85%) had had no further neurological episodes and that six patients (15%) had developed evidence of multiple sclerosis. Three of these only were in the group of patients with simultaneously bilateral optic neuritis giving a frequency of multiple sclerosis of 7%. These findings are similar to those of Parkin *et al*<sup>5</sup> (in a different cohort) who found that only 1 of 19 patients had developed further evidence of multiple sclerosis after a mean follow up of 26 years; that patient was classified as clinically probable in 1981, but in 1987 she was seen again and now has clinically definite multiple sclerosis, 32 years after the original illness. Similar results were obtained by Kennedy and Carter<sup>3</sup> who reported an overall frequency of multiple sclerosis after childhood optic neuritis of 16.5% (3/18); however, when patients with unilateral optic neuritis or preceding neurological episodes were excluded, only one patient of the remaining 16 developed multiple sclerosis. The high ratio of unilateral to bilateral cases (18:7) may account for the observation of Haller and Patzold<sup>9</sup> that nearly half their cases of childhood optic neuritis subsequently developed multiple sclerosis.

We have been unable to identify with confidence risk factors for the development of multiple sclerosis, although it has been suggested that the risk is lower for bilateral than unilateral cases. Five of 30 patients with no additional neurological signs at presentation developed multiple sclerosis compared with one out of nine patients who did have evidence of disseminated lesions, but the numbers are too small to draw reliable conclusions. The same is true for the results of HLA typing: the apparently high frequency of HLA DR2 in the unilateral cases (in which there was a higher frequency of multiple sclerosis) was not statistically significant. Similarly the overall numbers were too small to correlate VEP recovery with HLA type. Further observations on a larger series of patients would be of considerable interest.

The aetiology was not established in any case, although the spring peak in incidence (also noted by

others,<sup>10 11</sup>) and the association with a febrile illness at onset in nearly half of our patients suggests the implication of an infectious agent. This was particularly striking for bilateral optic neuritis in which the association with febrile illness was twice the frequency of unilateral cases.

**Recovery** The most striking finding in the present study is the high frequency of normal pattern reversal VEPs after clinical recovery (55%) compared with that in adults (approximately 10%<sup>12</sup>). The pattern reversal VEP is abnormal in approximately 90% of patients in the acute stage of optic neuritis.<sup>13</sup> Central scotomas are associated with profound pattern VEP changes<sup>12</sup> and since 98% of the present patients had dense central scotomas, the VEPs must have been abnormal originally. The majority of those with normal pattern VEPs later must therefore have experienced a genuine recovery of conduction in the surviving nerve fibres, a conclusion which is supported by serial measurements in three cases.

It might be argued that the differences between adults and children reflect the long follow up in our series compared with others. Carroll *et al*<sup>14</sup> found a latency decrease of more than 9 ms in only 3 of 97 patients with multiple sclerosis (3%) and 2 of 19 adults (10%) who had had optic neuritis when they were studied serially for a mean of 20 months; in the present series the mean follow up was 78 months for the eight cases with delayed VEPs and 134 months for the 11 cases with normal VEPs. However in three cases recorded within 21 months the VEPs were already within the normal range.

Little is known of the pathological process affecting the optic nerve fibres in childhood optic neuritis, but the similarity of the clinical and electrophysiological features in the acute stage with those of optic neuritis in adults, and the completeness of clinical recovery, suggests that demyelination plays a prominent part. The more frequent, (and at times rapid) restoration of normal latency in children than in adults raises the question whether the potential for remyelination is greater in the young than the old. Recent *in vitro* experimental work on cells derived from the optic nerve of the rat suggests that it may be. The two types of cell necessary to provide the morphological substrate for normal conduction in central nerve fibres, the oligodendrocyte which forms myelin and the Type 2 astrocyte which forms the central analogue of the Schwann cell paranodal apparatus of the peripheral nervous system,<sup>15</sup> are derived from the same progenitor cell<sup>16</sup> which is abundant at birth. Progenitor cells are also present in the adult<sup>17</sup> but differ from their perinatal counterparts in several respects: of particular importance in the present context is the observation that the adult progenitors divide more slowly, and are present in smaller numbers (Wolswijk &

Noble, unpublished observations). Such differences if confirmed in vivo could contribute to the greater capacity for recovery after demyelinating lesions in children than in adults.

## References

- 1 Taylor D, Cuendet F. Optic neuritis in childhood. In: Hess RF, Plant GT. eds. *Optic Neuritis*. Cambridge: Cambridge University Press 1986:73–85.
- 2 Hierons R, Lyle TK. Bilateral retrobulbar optic neuritis. *Brain* 1959;**82**:56–7.
- 3 Kennedy C, Carter S. Relation of optic neuritis to multiple sclerosis in children. *Paediatrics* 1961;**28**:377–87.
- 4 Meadows SP. The Doyne Memorial Lecture: Retrobulbar and optic neuritis in childhood and adolescence. *Transactions Ophthalmol Soc UK* 1969;**89**:603–38.
- 5 Parkin PJ, Hierons R, McDonald WI. Bilateral optic neuritis. A long-term follow-up. *Brain* 1985;**197**:951–64.
- 6 McDonald WI. Doyne Lecture: The significance of optic neuritis. *Trans Ophthalmol Soc UK* 1983;**103**:230–46.
- 7 Poser CM, Paty DW, Scheinberg L, et al. New diagnostic criteria for multiple sclerosis: guidelines for research protocols. *Ann Neurol* 1983;**13**:227–31.
- 8 Bodmer JC, Pickbourne P, Richards S. Ia serology. In: Bodmer WF, Batchelor JR, Bodmer JG, Festenstein H, Morris PJ, eds. *Histocompatibility Testing 1977*. Copenhagen: Munksgaard, 1978:35–84.
- 9 Haller P, Patzold U. Die Optikusneuritis im Kindesalter. *Fortschr Neurol Psychiatr* 1979;**47**:209–16.
- 10 Bradley WG, Whitty CWM. Acute optic neuritis: its clinical features and their relation to prognosis for recovery of vision. *J Neurol Neurosurg Psychiatry* 1967;**30**:531–8.
- 11 Hutchinson WM. Acute optic neuritis and the prognosis for multiple sclerosis. *J Neurol Neurosurg Psychiatry* 1976;**39**:283–9.
- 12 Halliday AM. *Evoked Potentials in Clinical Testing*. Edinburgh: Churchill Livingstone, 1982.
- 13 Halliday AM, McDonald WI. Visual evoked potentials. In: Stalberg E, Young RR. eds. *Neurology I, Clinical Neurophysiology*. London: Butterworths, 1981:228–58.
- 14 Carroll WM, Halliday AM, Barrett G, Peringer E. Serial VEPs and visual pathway demyelination: a study of 116 patients with multiple sclerosis and isolated optic neuritis. In: Nodar R, Barber C, eds. *Evoked Potentials II*. Boston: Butterworths 1984:310–8.
- 15 French-Constant C, Raff MC. The oligodendrocyte-type 2 astrocyte cell lineage is specialized for myelination. *Nature* 1986;**323**:335–8.
- 16 Raff MC, Miller RH, Noble M. A glial progenitor cell that develops in vitro into an astrocyte or an oligodendrocyte depending on the culture medium. *Nature* 1983;**303**:390–6.
- 17 French-Constant C, Raff MC. Proliferating bipotential glial progenitor cells in adult rat optic nerve. *Nature* 1986;**319**:499–502.