

Temporal lobe and hypothalamic-pituitary dysfunctions after radiotherapy for nasopharyngeal carcinoma: a distinct clinical syndrome

E WOO, K LAM, YL YU, J MA, C WANG, RTT YEUNG

From the Department of Medicine, University of Hong Kong, Queen Mary Hospital, Hong Kong

SUMMARY Eleven patients with combined neurological and endocrine complications after external radiotherapy for nasopharyngeal carcinoma are described. Neurologically, memory disturbance, complex partial seizures and hypodense areas in one or both temporal lobes on CT were typical features. Endocrinologically, hypopituitarism was the prominent manifestation. This constellation of clinical features in a patient with previous radiotherapy to the nasopharynx characterises radiation injury to the inferomedial aspects of the temporal lobes and the hypothalamic-pituitary axis. While the parenchymal brain lesions may mimic metastases or glioma on CT, the associated endocrine disturbance would betray the correct diagnosis. The importance of recognising the hypopituitarism which may be clinically asymptomatic and which is amenable to therapy is emphasised, as is the need for a proper fractionation of the radiation dose to minimise the incidence of these disabling complications.

Nasopharyngeal carcinoma (NPC) is a common tumour among Southern Chinese, and radiotherapy (RT) is the mainstay of its treatment. With effective RT, a 5-year survival of 60% to 80% is currently achieved for stages I and II of the disease.¹ However, such radiation is not without hazard.² Over the last 5 years, we encountered a distinct clinical syndrome due to the effects of such radiation characterised by hypothalamic hypopituitarism and cerebral dysfunction associated with temporal hypodensities on computed tomography (CT) of the brain. We now report our experience and emphasise the diagnostic characteristics.

Patients and methods

Between 1982 and 1987, 11 patients were seen in the University Department of Medicine, Queen Mary Hospital, Hong Kong because of combined neurological and endocrine complications of radiotherapy (RT) for nasopharyngeal carcinoma (NPC). All patients were in clinical remission 6 to 22 years after external RT. With the exception of one patient (patient 3) who was treated in China and hence his radiation dosage was not available, RT to the nasopharynx in all other 10 patients was delivered through a pair of parallel opposed

lateral facial fields supplemented by an anterior facial field with the eyes shielded.³ A 4.5 MeV linear accelerator or a telecobalt machine was used. Three patients (Nos 5, 8 and 10) received a second course of RT to the nasopharynx for local recurrence. Of the 13 courses of RT, the fraction size was 200 rad in two, between 200 to 400 rad in four, and more than 400 rad in seven.

From 1976 to 1982 the Radiotherapy Department treated 80–100 new patients per year. During this period, the routine dosage to the nasopharynx was 420 rad twice weekly up to 5040 rad. With this dosage, the estimated dose for the temporal lobe was 4100 to 5950 rad, for the hypothalamus 4100 to 4500 rad,⁴ and for the pituitary 6200 to 6700 rad,⁴ based on an equivalent of 200 rad per fraction, five fractions per week.

Neurological assessment Clinical neurological assessment was performed for all patients with special emphasis on cortical functions. A Mini-mental State examination⁵ was administered to grade cognitive state. CT of the brain was performed in all patients at the time of initial neurological consultation and it was repeated in seven patients at varying intervals on follow-up.

Endocrinological assessment Clinical endocrinological assessment was performed for all patients with special attention to pituitary functions. Structural lesions in the hypothalamic-pituitary region were excluded by high-resolution CT of the parasellar area. Hormonal studies were performed after an overnight fast. Basal samples for serum luteinising hormone (LH), follicle-stimulating hormone (FSH), thyroid-stimulating hormone (TSH), thyroxine (T4), cortisol, prolactin, testosterone or oestradiol were taken. Subsequently, the growth hormone (GH) response to

Address for reprint requests: E Woo, University Department of Medicine, Queen Mary Hospital, Hong Kong.

Received 15 January 1988 and in revised form 22 April 1988.
Accepted 25 May 1988

insulin-induced hypoglycaemia (insulin tolerance test, insulin 0.15 units/kg), the LH and FSH responses to luteinising hormone releasing hormone (LHRH, 100 µg), and the TSH response to thyrotropin-releasing hormone (TRH, 200 µg) were assessed as previously described.⁴

Results

The demographic characteristics, the radiation doses and the main presenting features are summarised in table 1. There were eight men and three women with a median age of 48 years (range 33–64). The total dose delivered to the nasopharynx ranged from 4560 to 10950 rad. Five patients presented to the neurologist while six presented to the endocrinologist. The following complications were noticed 3 to 22 years after the initial RT.

Neurological features Although five presented with neurological complications, clinically evident neurological dysfunction eventually developed in all 11 patients and started 4 to 22 years (median 5 years) after the initial RT (table 1).

Eight patients had seizures, of which seven were complex partial seizures with or without generalisation and one nonfocal tonic-clonic convulsion. The complex partial seizures were in the form of visual hallucinations in four; déjà vu, auditory and olfactory hallucinations in each of the others. These seizures were well controlled with anticonvulsant monotherapy. Seven patients had progressive amnesia especially for recent events, and this was associated with significant cognitive impairment in six. They showed varying degrees of disorientation to time, place and person. They had poor general knowledge and social comprehension. Abstract thinking, problem solving and verbal reasoning were impaired. A change in personality was observed in six patients. Two patients became irritable and aggressive, one

became passive and dependent, while three became obsessive (table 2). Motor abnormalities were very uncommon features. Only two patients (Nos 1 and 10) showed a hemiparesis which was mild with no significant limitation of mobility. Somatosensory abnormalities were not observed.

In all 11 patients, CT of the brain showed hypodense areas in the temporal lobes. These changes were unilateral (fig. a and b) in six and bilateral (fig. c and d) in five. When the changes were bilateral, they were always asymmetrical with one temporal lobe affected more than the other. In three patients, the hypodense area extended into the adjacent frontal and parietal lobes (fig d). Mass effect was observed in five patients, being mild in four and moderate in one. Contrast enhancement was seen in six patients, the pattern being patchy, mild and irregular. Follow-up CT was available in seven patients after an interval varying between 1 and 4 years. There were no changes in the CT appearance in four patients while improvement was seen in three, consisting of reduction in the size of the hypodense areas and loss of mass effect and contrast enhancement.³

Endocrinological features Six patients presented to the endocrinologist with amenorrhoea-galactorrhoea (three patients), impotence and decreased sexual drive (two patients) and cold intolerance (two patients). Of the five patients presenting with neurological symptoms, three eventually developed clinical evidence of hormonal disturbance while two remained endocrinologically asymptomatic. Endocrinological dysfunction started 3 to 22 years (median 8) after the initial RT. None of these 11 patients had evidence of any mass lesion of the hypothalamic-pituitary region on CT (table 1).

All patients showed abnormalities in either the basal hormonal levels or the various stimulation tests. Five patients had decreased basal T4 and two patients

Table 1 Demographic data, radiation doses and clinical features of the patients

Patient/ Sex/Age	RT dose to nasopharynx (total dose in rad/fraction size in rad/yr)(y)	Presenting feature	Interval between RT and onset of neurological symptoms (yrs)	Interval between RT and onset of endocrine symptoms (yrs)	Duration of follow-up (months)	Current status
<i>Presenting to neurologist</i>						
1/M/49	5040/420/38 (1976)	seizure	8	9	38+	alive, working
2/M/42	4560/380/38 (1965)	bilateral optic atrophy	22	22	9+	alive, at home
3/M/33	unknown (1973)	amnesia	5	11	32+	alive, at home
4/M/35	5320/200/38 (1977)	cognitive dysfunction	5	8	54+	alive, at home
5/M/64	5320/200/34 (1974) 5000/250/37 (1981)	seizure	9	13	61	dead
<i>Presenting to endocrinologist</i>						
6/M/57	5040/420/38 (1981)	impotence	4	3	29+	alive, working
7/F/41	5040/420/38 (1980)	amenorrhoea-galactorrhoea	5	4½	23+	alive, working
8/F/43	5040/420/38 (1980) 4000/500/29 (1982)	amenorrhoea-galactorrhoea	4	3½	44+	alive, working
9/M/50	5040/420/38 (1971)	impotence, cold intolerance	13	12	12+	alive, at home
10/M/49	5950/350/38 (1982) 5000/250/37 (1983)	cold intolerance	5	3	30+	alive, at home
11/F/48	5040/420/38 (1977)	amenorrhoea-galactorrhoea	8	6	6	dead

Table 2 Neurological features of the patients

Clinical						CT		
Patient	Seizure	Amnesia	Cognitive dysfunction	Personality change	MMSE score	Hypodense area	Mass effect	Contrast enhancement
1	+	-	-	+	30	R temporal	-	+
2	-	+	+	-	24	L temporal	-	+
3	-	+	+	+	20	bitemporal (R > L)	-	-
4	+	+	+	+	19	bitemporal (L > R)	-	-
5	+	+	+	+	11	L temporal, extending into frontal and parietal	+	+
6	+	-	-	-	30	bitemporal (L > R), extending into frontal and parietal	+	+
7	+	+	-	+	30	bitemporal (L > R)	+	-
8	+	-	-	-	28	bitemporal (R > L), extending into frontal and parietal	+	+
9	-	+	+	+	14	R temporal	-	-
10	+	+	+	-	18	R temporal	-	-
11	+	-	-	-	30	L temporal	+	+

+ = present; - = absent; L = left; R = right; MMSE = Mini-mental State examination.

had low basal cortisol. Prolactin was increased in the three female patients with amenorrhoea-galactorrhoea, one of whom also had decreased oestradiol. Testosterone was decreased in five of the eight male patients. Impaired GH response to insulin-induced hypoglycaemia was present in nine patients, impaired and/or delayed TSH response to TRH in 10 patients and impaired FSH/LH response to LHRH in nine patients. These hormonal disturbances are consistent with defects in hypothalamic-pituitary regulation (table 3).

Follow-up Follow-up of these 11 patients ranged from 9 to 61 months. Four patients had a good outcome; they were active and gainfully employed despite a mild degree of cognitive or motor deficit. Seven patients had a poor outcome, including two deaths (one from intracerebral haemorrhage⁶ and one from aspiration pneumonia) and five who were unable to continue their previous occupation although still independent in activities of daily living (table 1).

Those patients with symptoms of hypopituitarism responded satisfactorily to replacement therapy with thyroxine, cortisol or sex hormones. Galactorrhoea was readily controlled with low-dose bromocriptine. **Pathology** Of the two deaths, one (No 11) had a postmortem examination in which the temporal lobes showed the typical pathological features of delayed radiation necrosis⁷ in the form of coagulative necrosis of the white matter, endothelial proliferation of the blood vessel with fibrinoid necrosis of the vessel wall and fibrin thrombi occluding the vascular lumen. The pituitary showed atrophy and focal replacement by fibrosis, consistent with the effects of irradiation.⁸ There was no evidence of tumour. These changes have been reported in a previous communication.⁶

Discussion

We have described 11 patients who had neurological dysfunction in association with hypopituitarism 3 to 22 years after external RT for NPC. Five patients presented with symptoms of cerebral dysfunction mainly in the form of seizures and/or memory impairment, while six others presented with endocrine abnormalities chiefly in the form of impotence or amenorrhoea-galactorrhoea. In spite of this difference in presentation, all patients had CT changes, namely areas of decreased attenuation in one or both temporal lobes consistent with cerebral radiation necrosis, and all had laboratory evidence of hypothalamic-pituitary dysfunction.

Since Fischer and Holfelder's original description in 1930,⁹ cerebral necrosis has been a recognised hazard of high dose radiation to any field which includes the brain. This applies not only to radiotherapy of intracranial tumours, but also extracranial neoplasms in close proximity to the skull. Hence, radiation necrosis of the brain has been observed following radiation of lesions of the scalp, paranasal sinuses, nasopharynx as well as lesions in the pituitary fossa.^{10 11} The true incidence and natural history of radiation necrosis of the brain remains unknown as no long-term studies have been performed, although one review¹² suggested an incidence varying from 0.5% to 25%.

Radiotherapy is the primary mode of treatment for NPC. As the inferomedial portions of the temporal lobes lie directly within the radiation ports, it is not unexpected that radiation damage to these structures occurs, especially when survival is prolonged because of more effective treatment. This is corroborated by

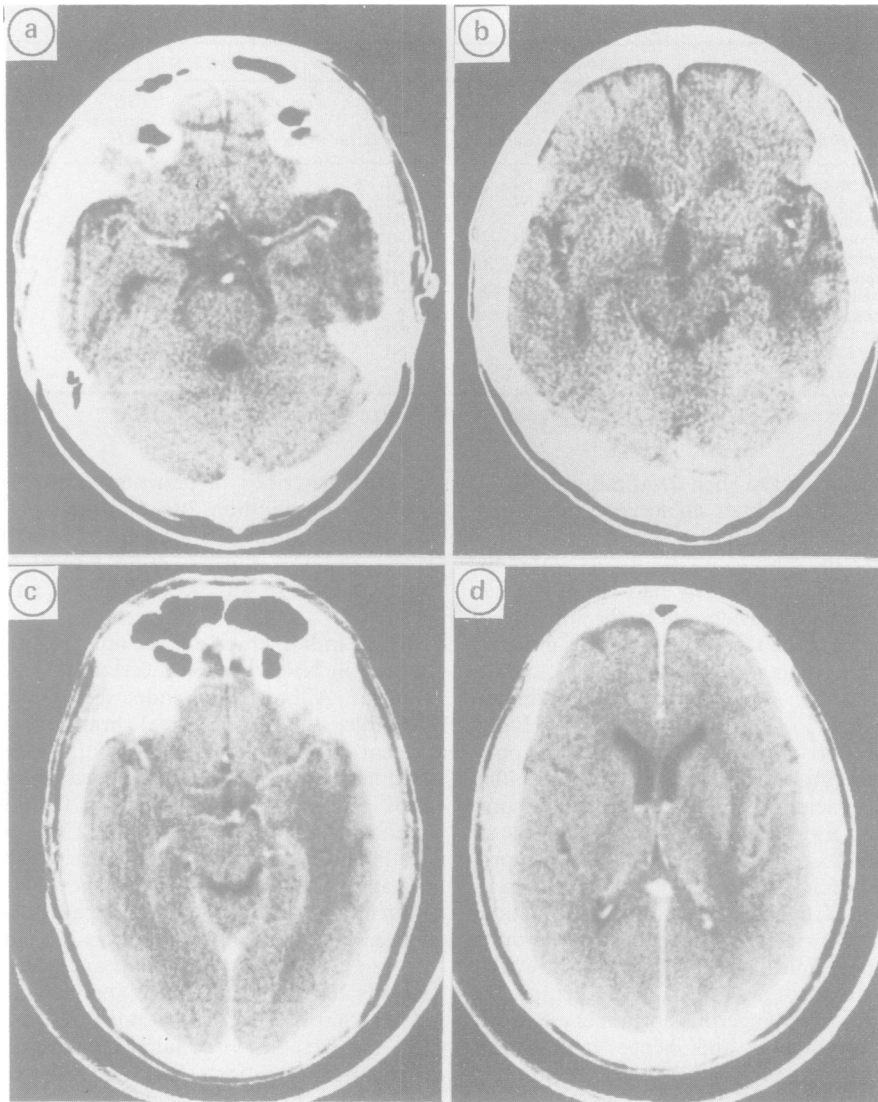


Fig (a, b) Patient 2. Contiguous 10 mm CT slices with intravenous contrast showing an area of decreased attenuation in the left temporal lobe. No mass effect with minimal contrast enhancement. (c, d) Patient 6. Enhanced CT scan showing bitemporal hypodense areas worse on the left, with mild mass effect. Note the extension into the adjacent frontal and parietal lobes.

the clinical manifestations in our patients. The prominent memory disturbance with sparse motor or sensory signs, the personality change and the frequent occurrence of complex partial seizures certainly suggest that the medial temporal areas suffer the major brunt of radiation injury. Similar CT appearances seen in the superior temporal regions and even the adjacent frontal and parietal lobes are in keeping with the vascular hypothesis¹³ of radiation necrosis, in that

the extent of injury is affected by arteriolar thickening and fibrinoid necrosis with resultant ischaemia to diverse regions of the brain and is therefore not limited by the anatomical extent of the tissue within the boundaries of the radiation beam. While patients reported in this series all have clinically evident disease, it is likely that subclinical cognitive deficits are present in an even larger number of patients. A prospective study of the neuropsychological status of

Table 3 Endocrinological features of the patients

Patient	Clinical features	Basal hormones			Stimulation tests		
		T4	Cortisol	Prolactin	GH response to ITT	TSH response to TRH	LH/FSH response to LHRH
1	impotence	↓	NL	NL	*	*	*
2	asymptomatic	NL	NL	NL	*	*	*
3	impotence, cold intolerance	↓	↓	NL	*	*	*
4	impotence	NL	NL	NL	*	*	*
5	asymptomatic	↓	↓	NL	*	ND	ND
6	impotence	↓	NL	NL	ND	*	*
7	amenorrhoea-galactorrhoea	NL	NL	↑	*	*	NL
8	amenorrhoea galactorrhoea	NL	NL	↑	*	*	*
9	impotence, cold intolerance	NL	NL	NL	*	*	*
10	cold tolerance	NL	NL	NL	*	*	*
11	amenorrhoea-galactorrhoea	↓	NL	↑	NL	*	*

↓ = decreased; ↑ = increased; NL = normal; ND = not done; * = impaired or delayed response.

patients who had received such focal radiotherapy is currently under way to obtain an accurate estimate of the magnitude of the problem.

The hypothalamic-pituitary axis also lies within the beam path and all our patients had hypothalamic-pituitary dysfunction, as evidenced by the impaired or delayed responses in the secretion of various pituitary hormones to hypothalamic releasing factors, consistent with previous reports of post-irradiation hypothalamic-pituitary injury.¹⁴⁻¹⁶ Hyperprolactinaemia has also been described in post-irradiation hypopituitarism,^{14,17} probably resulting from a defective secretion or delivery of hypothalamic prolactin-inhibitory factor. The actual incidence of this complication is difficult to assess, but in a prospective study⁴ of 31 patients, 28 had laboratory evidence of impaired hypothalamic-pituitary functions at 1 year, and four out of 21 patients followed up to 2 years developed clinical hypopituitarism. Since these endocrine disturbances are amenable to therapy and even more important, dangerous hormonal crisis may ensue in asymptomatic and hence undiagnosed patients under stress, it is advisable that pituitary assessment be carried out in patients who had radiation to the hypothalamic-pituitary region, especially in the presence of neurological dysfunction.

The constellation of hypothalamic and temporal lobe disturbances is strongly suggestive of radiation injury in a patient with previous radiotherapy for NPC, although metastasis and radiation-induced neoplasms may be considered in the differential diagnosis. While NPC tends to spread to contiguous tissues, it is unusual for large metastases to occur intracranially without local recurrence. There is no evidence of tumour recurrence in any of our patients and the prolonged period of follow-up would also argue against metastatic disease. Radiation-induced glioma has been reported¹⁸ but is most unlikely to be the case due to the lack of progression on CT, a feature which

we have described in patients with cerebral radionecrosis.³ In addition, tissue diagnosis of patient 11 showed that the pathological features in the temporal lesion and the pituitary were typical of radiation injury and there was no evidence of any neoplastic process.

While radiotherapy offers a much improved chance of cure in NPC, there are certainly some untoward sequelae. Although the endocrine abnormalities are treatable, the parenchymal brain injuries are at present irreversible. It is therefore imperative that such injuries be prevented or at least minimised. The total dose of radiation and its fractionation are important aetiological factors.^{2,19} Three patients were irradiated twice, the total dosage being 9000 to 10950 rad and it is not surprising that they developed radiation necrosis. Of the other seven patients with known dosages, the fractionated dose was 380 rad in one and 420 rad in five. It is known that once the fraction size exceeds 200 rad or when the nominal standard dose (NSD (that is, total dose in rad = NSD × N^{0.24} × T^{0.11}, where NSD = nominal standard dose in ret, N = number of fractions, T = time in days).²²) exceeds 1620 ret, the risk of complication increases markedly.¹⁹⁻²¹ Whether a smaller fractionated dose would adversely affect tumour eradication warrants further study, but readjusting the timing and the fractionation to keep the NSD below 1600 ret will certainly reduce the incidence of these disabling complications of radiation injury.

We thank Mrs Shirla Tam for secretarial assistance.

References

- 1 Ho JHC, Lau WH, Fong M, Chan CL, Au GKH. *Treatment of nasopharyngeal carcinoma (NPC)*, in: Grundmann P et al (eds): Cancer Campaign, Vol. 5, Nasopharyngeal Carcinoma. New York: Gustav Fischer, 1981:279-85.
- 2 Kramer S. The hazards of therapeutic irradiation of the central

- nervous system. *Clin Neurosurg* 1968;**15**:301-18.
- 3 Woo E, Lam K, Yu YL, Lee PWH, Huang CY. Cerebral radionecrosis—is surgery necessary? *J Neurol Neurosurg Psychiatry* 1987;**50**:1407-14.
 - 4 Lam KSL, Tse VKC, Wang C, Yeung RTT, Ma JTC, Ho JHC. Early effects of cranial irradiation on hypothalamic-pituitary function. *J Clin Endocrinol Metab* 1987;**64**:418-24.
 - 5 Folstein MF, Folstein SE, McHugh PR. "Mini-mental State". A practical method for grading the cognitive state of patients for the clinician. *J Psychiatr Res* 1975;**12**:189-98.
 - 6 Woo E, Chan YF, Lam K, Lok ASF, Yu YL, Huang CY. Apoplectic intracerebral hemorrhage: an unusual complication of cerebral radiation necrosis. *Pathology* 1987;**19**:95-98.
 - 7 Rubinstein LJ. Tumors of the central nervous system. Atlas of tumor pathology. Second series, fascicle 6. Washington, DC: Armed Forces Institute of Pathology, 1970:349-60.
 - 8 Woodruff KH, Lyman JT, Lawrence JH, Tobias CA, Born JL, Fabrikant JI. Delayed sequelae of pituitary irradiation. *Hum Pathol* 1984;**15**:48-54.
 - 9 Fischer AW, Holfelder H. Lokales amyloid im gehirn. *Dtsch Z Chirurg* 1930;**227**:475-83.
 - 10 Crompton MR, Layton DD. Delayed radionecrosis of the brain following therapeutic X-radiation of the pituitary. *Brain* 1961;**84**:85-101.
 - 11 Glass JP, Hwang TL, Leavens ME, Libshitz HI. Cerebral radiation necrosis following treatment of extracranial malignancies. *Cancer* 1984;**54**:1966-72.
 - 12 Di Lorenzo N, Nolletti A, Palma L. Late cerebral radionecrosis. *Surg Neurol* 1978;**10**:281-90.
 - 13 Layman RS, Kupalov PS, Scholz W. Effect of roentgen rays on the central nervous system. *Arch Neurol Psychiatry* 1933;**29**:56-87.
 - 14 Samaan NA, Bakdash MM, Caderao JB, Cangir A, Jesse RH Jr, Ballantyne AJ. Hypopituitarism after external irradiation. Evidence for both hypothalamic and pituitary origin. *Ann Intern Med* 1975;**83**:771-7.
 - 15 Shalet SM. Disorders of the endocrine system due to radiation and cytotoxic chemotherapy. *Clin Endocrinol* 1983;**18**:637-59.
 - 16 Grossman A, Cohen BL, Charlesworth M, et al. Treatment of prolactinomas with megavoltage radiotherapy. *Br Med J* 1984;**28**:1105-9.
 - 17 Hwang KE. Assessment of hypothalamic-pituitary function in women after external head irradiation. *J Clin Endocrinol Metab* 1979;**49**:623-7.
 - 18 Anderson JR, Treip CS. Radiation-induced intracranial neoplasms. A report of three possible cases. *Cancer* 1984;**53**:426-9.
 - 19 Marks JE, Baglan RJ, Prasad SC, Blank WF. Cerebral radionecrosis: incidence and risk in relation to dose, time, fractionation and volume. *Int J Radiation Oncol Biol Phys* 1981;**7**:243-52.
 - 20 Martins AN, Johnston JS, Henry JM, Stoffel TJ, di Chiro G. Delayed radiation necrosis of the brain. *J Neurosurg* 1977;**47**:336-45.
 - 21 Rottenberg DA, Chernik NL, Deck MDF, Ellis F, Posner JB. Cerebral necrosis following radiotherapy of extracranial neoplasms. *Ann Neurol* 1977;**1**:339-57.
 - 22 Ellis F. Nominal standard dose and the ret. *Br J Radiol* 1971;**44**:101-8.