

## *Short report*

# The pedunclopontine nucleus in Parkinson's disease, progressive supranuclear palsy and Alzheimer's disease

K JELLINGER

*From the Ludwig-Boltzmann Institute of Clinical Neurobiology and Department of Neurology, Lainz-Hospital, Vienna, Austria*

**SUMMARY** Significant loss of neurons in the pedunclopontine nucleus pars compacta (PPNc), a putative cholinergic nucleus involved in modulating somatic motor activities, has been demonstrated in progressive supranuclear palsy (PSP) and Parkinson's disease but not in Alzheimer's disease. A morphometric study of this nucleus was performed in two cases of PSP and in a cohort of cases of Parkinson's disease, Alzheimer's disease, senile dementia of Alzheimer type (SDAT), and age-matched controls. In PSP a significant 60% neuronal loss in PPNc was associated with neurofibrillary tangles in 40 to 64% of the remaining neurons. In Parkinson's disease there was a significant decrease in cell numbers and density by 53 and 51%, respectively, with Lewy bodies involving 6 to 39% of all neurons. In Alzheimer's disease and SDAT, large neurons were reduced by 29 and 33.8%, respectively, with tangles in 9 to 38% of the remaining cells. The selective affection of this putative cholinergic nucleus in PSP and Parkinson's disease appears to be related to motor dysfunctions in these disorders.

The parabrachial pedunclopontine nucleus (PPN) lying in the ventrolateral part of the caudal mesencephalic tegmentum is separated into two subnuclei: the ventral subnucleus dissipatus (A-8 of the mammalian brain) featured by a relative paucity of cells, and the subnucleus compactus (PPNc) constituted of densely arranged neurones of over 20  $\mu\text{m}$  diameter possessing an excentric nucleolus and peripherally arranged Nissl substance.<sup>1</sup> The PPNc is recognised as an important "loop nucleus" of the corpus callosum and is widely integrated into the circuitry of the basal ganglia,<sup>2</sup> for it receives inputs from the frontal cortex, internal pallidal segment, zona reticulata nigrae, subthalamic nucleus, ventral tegmental area and central amygdaloid nucleus and has widespread efferents to most of the same subcortical nuclei, to the zona com-

compacta nigrae and striatum.<sup>2-6</sup> Its principal projections appear to be to the intralaminar thalamic nuclei, pars compacta nigrae and subthalamic nucleus.<sup>3-6</sup> The latter connections, confirmed by electron microscopic autoradiography, appear to be cholinergic, excitatory and asymmetrically bilateral.<sup>4,7</sup> This putative cholinergic nucleus, projecting to portions of the neuraxis that modulate somatic motor activities at a cortical level,<sup>2,8</sup> lies in a region containing many cholinergic neurons and is thought to represent a "preextrapyramidal centre" and extrastriatal mechanisms for affecting the balance between cholinergic and dopaminergic functions of the basal ganglia.<sup>2</sup> Significant loss of neurons in the PPNc has been demonstrated recently in cases of progressive supranuclear palsy (PSP), of Parkinson's disease, and of Parkinson's disease combined with Alzheimer's disease (PD/AD).<sup>9-11</sup> In Parkinsonism induced by 1-methyl-4-phenyl-1, 2, 3, 6-tetrahydropyridine (MPTP) in the cynomolgus monkey overactivity of the PPN has been demonstrated by increased 2-deoxy-glucose uptake.<sup>12</sup> We present preliminary

Address for reprint requests: Prof K Jellinger, Ludwig-Boltzmann Institute of Clinical Neurobiology, Lainz-Hospital 1, Wolkersbergenstrasse, A-1130 Vienna, Austria.

Received 31 July 1987 and in revised form 29 October 1987.  
Accepted 2 November 1987

Table Major clinical and neuropathological data

Group	Controls	Parkinson's disease	PSP	Alzheimer's disease	Senile dementia Alzheimer type
N of cases (male/female)	15 (10/5)	14 (6/8)	2 (1/1)	5 (4/1)	17 (7/10)
Age (years) Mean, SEM	73.7, 3	77.3, 1.6	68	59.4, 1.0	85.3, 1.6
Range	65-84	73-83	65/71	54-72	77-92
Duration illness (mean SEM)	—	10.0, 1.0	13	6.2, 1.1	8.2, 2.0
Range	—	3-20	9/17	1-10	1-14
Dementia	0	5 (35%)	1 (50%)	5 (100%)	17 (100%)
Fresh brain weight (g) Mean, SEM	1212, 8	1201, 5	1095	1056, 12	1045, 9
Frontal cortex NP 4+	0	0	0	5 (100%)	17 (100%)
NFT 4+	0	0	0	5 (100%)	15 (88%)
Hippocampus NP 4+	0	4 (28%)	0	5 (100%)	15 (100%)
NFT 4+	0	2 (14%)	0	5 (100%)	15 (100%)
PPNc % cells:					
NFT	<1%	<1%	40/64%	18-38%	5-22.5%
Lewy bodies	<1%	6-39%	0	0	0-5%

NFT = neurofibrillary tangles; NP = neuritic plaques; 4 + high density.

data of morphological studies of the PPNc in a cohort of patients with Parkinson's disease, PSP, Alzheimer's disease and senile dementia of the Alzheimer type (SDAT), and in age-matched controls.

#### Material and methods

The sample included five groups of patients, the major clinical and neuropathological data of which are given in the table.

(a) Fourteen cases of Parkinson's disease, all except one with mixed tremor, rigidity and akinesia, presenting with a rigid akinetic syndrome; dementia was recorded in five. Neuropathology revealed focal damage to the substantia nigra and widespread Lewy bodies throughout the brainstem. Occasional senile plaques and/or neurofibrillary tangles in hippocampus and/or neocortex were seen in seven brains. Numerous Alzheimer lesions in hippocampus were present in four cases, two of which also had numerous plaques and tangles in the neocortex, indicating a combination of Parkinson's disease and SDAT.

(b) Two cases of PSP, presenting with ophthalmoplegia, rigidity and akinesia, were pathologically featured by widespread neurofibrillary degeneration (straight tangle type) with neuronal loss and gliosis in several subcortical nuclei, but preservation of the neocortex and hippocampus.<sup>13</sup>

(c) Seventeen cases of SDAT with clinical evidence of dementia were pathologically characterised by numerous senile plaques and tangles in hippocampus and neocortex; most had amyloid angiopathy.

(d) Five cases of Alzheimer's disease with severe dementia of several years duration showed severe Alzheimer changes in hippocampus and neocortex, and cerebral amyloid angiopathy.

(e) Fifteen patients without dementia or other neurological or psychiatric disorders served as controls. There were no neuropathological abnormalities except for a few senile plaques and/or tangles in hippocampus and/or neocortex of some cases.

The PPNc from each case was sampled at two levels from serially sectioned formalin-fixed, paraffin-embedded blocks of the brainstem cut at 5-7  $\mu$ m stained with cresyl violet,

haematoxylin and eosin, Bodian's silver and congo red stains. PPNc neurons of more than 20  $\mu$ m with prominent nucleoli and abundant Nissl substance were counted in cresyl violet sections under 400-fold magnification using an ocular micrometer. The area of the NPPc was calculated by counting the number of fields of 0.53  $\times$  0.75 mm (0.395 sqmm). Lewy bodies and tangles were counted within the same fields. Statistical significance was evaluated by Student's *t* test.

#### Results

While in controls the mean number of large neurons in NPPc was 91.47, (SEM 1.72) with a mean cell density of 58.3, (1.2) cells/mm<sup>2</sup>, in Parkinson's disease the mean neuronal number was 48.5, 1.44 with a mean density of 30.5, (1.2) cells/mm<sup>2</sup> that is a reduction by 53 and 51.3%, respectively. The two cases of PSP with mean cell numbers of 25 and 48 respectively, showed an average reduction of 60% versus controls. In SDAT; the number of large NPPc neurons was 65.1, 0.8 and the cell density was 41.5, (0.9)/mm<sup>2</sup> which corresponds to a reduction by 28.9 and 29%, respectively. In Alzheimer's disease neuronal numbers of 59.4, (0.6) and density of 37.3, (0.7) cells/mm<sup>2</sup> were reduced by 33.8 and 35.3% of controls (fig 1). In the control group, Lewy bodies and fibrillary tangles were seen in less than 1% of the NPPc neurons, while in Parkinson's disease Lewy bodies involved between 6 and 39% of the remaining cells, with only very occasional tangles in this nucleus (0-5% of the remaining neurons), which in PSP affected 40 to 64% of the remaining cells. In Alzheimer's disease, the incidence of tangles ranged from 18 to 38% and in SDAT from 5 to 22.5% of the remaining cells, with only very occasional Lewy bodies in both disorders. Obvious astrocytic gliosis was not recognised in either group of disorders. The adjacent mesencephalic trigeminal nucleus showed neither neuronal loss nor any Lewy bodies or tangles in its neurons.

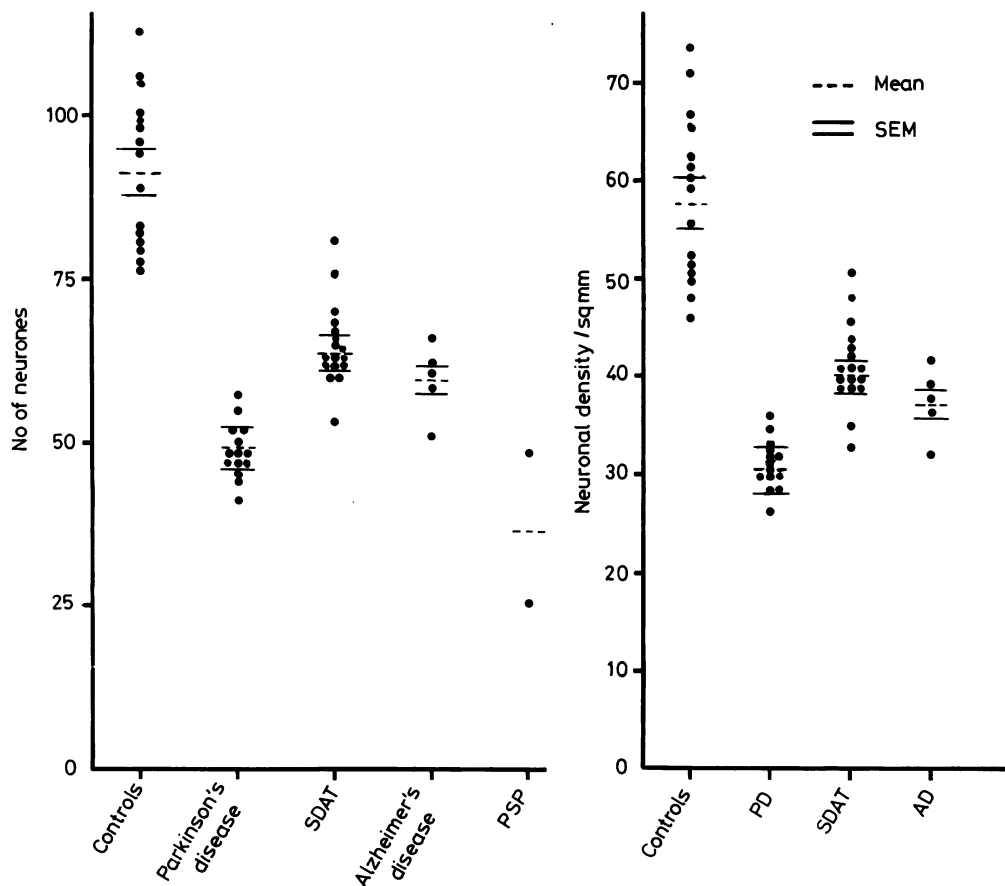


Fig Number of large neurons (left) and neuronal density/mm<sup>2</sup> in the nucleus tegmenti pedunculopontinus pars compacta.

## Discussion

Neuronal loss of variable intensity associated with cytoskeletal changes (Lewy bodies, neurofibrillary tangles) have been reported in several subcortical nuclei in both Parkinson's and Alzheimer's diseases.<sup>14-20</sup> In Parkinson's disease neuronal loss in zona compacta nigrae ranging from 66 to 85% is much more severe than in AD/SDAT showing 6% to 38% cell depletion. Cell loss in the noradrenergic locus coeruleus in both disorders ranges from 60 to 85%. In AD/SDAT topographic arrangement of cell loss and its correlation to neuronal depletion and density of neuritic plaques in the temporal cortex suggest retrograde degeneration due to primary cortical damage,<sup>19</sup> while no such correlation has been observed in Parkinson's disease. In the serotonergic dorsal raphe

nucleus neuronal loss in Parkinson's disease averages 42.2%, but in AD/SDAT shows a wide range from 6% to 77% of controls,<sup>14 15 18</sup> up to 90% of the remaining neurons showing fibrillary tangles.<sup>18</sup> Significant cell loss has been reported in the cholinergic nucleus basalis of Meynert in both Parkinson's disease and Alzheimer's disease/SDAT.<sup>14 15 17 20 21</sup> Cell depletion in this nucleus is much higher in demented Parkinson's subjects, irrespective of the cortical pathology, where it approaches the values of Alzheimer's disease, than in non-demented Parkinson's disease patients where cholinergic cell reduction is similar to the losses seen in SDAT.<sup>14 15 20</sup>

Recent studies of the NPPc have demonstrated a significant 49% to 69% cell loss in three cases of PSP,<sup>10</sup> an average cell reduction by 60% in four cases of Parkinson's disease and of 40% in four cases of

Parkinson's disease plus Alzheimer's disease as compared with age matched controls,<sup>9</sup> while no significant neuronal depletion was seen in cases of Alzheimer's disease.<sup>10</sup> Lewy bodies were abundant in all cases of Parkinson's disease and Parkinson's disease plus Alzheimer's disease, but infrequent in controls, while neurofibrillary tangles were common in all cases of Parkinson's disease plus Alzheimer's disease and Alzheimer's disease/SDAT.<sup>9,10</sup> Similar results were reported in both Parkinson's disease and PSP.<sup>11</sup> In the present series a significant 60% neuronal loss with fibrillary tangles in 40% to 64% of the remaining neurons was seen in two cases of PSP. In Parkinson's disease there was a significant decrease in neuronal numbers and density by over 50%, with Lewy bodies affecting 6% to 39% of the remaining cells. NPPc neuronal loss averaging 34% and 29%, respectively, was much less severe in Alzheimer's disease and SDAT. In these disorders, it was accompanied by the occurrence of fibrillary tangles, the incidence of which in NPPc, however, was much less than in other subcortical nuclei, for example the dorsal raphe nucleus.<sup>18</sup> These data suggest that putative cholinergic neurons of the PPnc are more selectively affected in Parkinson's disease and PSP, and could be related to disorders of motor performance and co-ordination in these disorders, while in Alzheimer's disease/SDAT this nucleus involved in somatic motor activities appears to be only mildly affected. Overactivity of the NPPc in experimental MPTP Parkinsonism<sup>12</sup> showing rather selective damage to the zona compacta nigrae<sup>22</sup> might indicate dysfunctions in the tegmento-nigro-subthalamo-cortical pathways, the pathogenetic factors and clinical significance of which in Parkinson's disease and PSP are still unknown. In the latter disorder, severe involvement of PPnc has been suggested to contribute to some disorders of movement, sleep-wake cycles and cognition<sup>10</sup> that are known to be characteristic in both Parkinson's disease and PSP. Understanding the mechanisms by which this cholinergic subcortical nucleus is related to motor disturbances and other dysfunctions in Parkinsonism could provide further insight into the pathophysiology of basal ganglia disorders.

## References

- 1 Olszewski J, Baxter D. *Cytoarchitecture of the Human Brain Stem*, 2nd ed. Basel: Karger 1982.
- 2 Graybiel AM. Neurochemically specified subsystems in the basal

- ganglia. In: Evered D, O'Connor M, eds. *Functions of the Basal Ganglia*. London: Pitman 1984:114-9.
- 3 Jackson A, Crossman AR. Nucleus tegmenti pedunculopontinus: efferent connections with special reference to the basal ganglia, studied in the rat by anterograde and retrograde transport of horseradish peroxidase. *J Comp Neurol* 1983;231:396-420.
- 4 Sugimura T, Hattori T. Organisation and efferent projections of nucleus tegmenti pedunculopontinus pars compacta with special reference to its cholinergic aspects. *Neuroscience* 1984;11:931-46.
- 5 Usonoff KG. Tegmentonigral projections in the cat. Electron microscopic observations. *Adv Neurol* 1984;40:55-61.
- 6 Beninato M, Spencer RF. A cholinergic projection to the rat substantia nigra from the pedunculopontine tegmental nucleus. *Brain Res* 1987;412:169-74.
- 7 Mesulam MM, Mufson EJ, Levey AI, Wainer BH. Atlas of cholinergic neurons in the forebrain and upper brainstem of the macaque based on monoclonal choline acetyltransferase immunohistochemistry and acetylcholinesterase histochemistry. *Neuroscience* 1984;12:669-86.
- 8 Carpenter MB. Anatomy of the basal ganglia. In: Vinken PJ, Bruyn GW, Klawans HR, eds. *Handbook of Clinical Neurology*. Amsterdam; Elsevier Scientific Publishers. vol. 5(49) 1986:1-18.
- 9 Zweig RM, Martin LJ, Jankel WR, Price DL. The pedunculopontine nucleus in Parkinson's disease (abstr.) *Neurology* 1987;37 Suppl 1:267.
- 10 Zweig RM, Whitehouse PJ, Casanova MF, Walker LC, Jankel WR, Price DL. Loss of pedunculopontine neurons in progressive supranuclear palsy. *Ann Neurol* 1987;22:18-25.
- 11 Hirsch EC, Graybiel AM, Duyckaerts C, Javoy-Agid F. Neuronal loss in the pedunculopontine tegmental nucleus in Parkinson's disease and progressive supranuclear palsy. *Proc Nat Acad Sci USA* 1987;84:5976-81.
- 12 Crossman AR. Basal ganglia functions in experimental movement disorders. *International Conference on the basal ganglia*, Leeds 1987:C6.
- 13 Jellinger K, Riederer P, Tomonaga M. Progressive supranuclear palsy: clinico-pathological and biochemical studies. *J Neural Transm* 1980;Suppl 16:111-28.
- 14 Jellinger K. The pathology of Parkinsonism. In: Marsden CD, Fahn ST eds. *Movement Disorders 2*. London: Butterworths 1987:124-65.
- 15 Jellinger K. Neuropathological substrates of Alzheimer's disease and Parkinson's disease. *J Neural Transm* 1987;Suppl 24:109-29.
- 16 Mann DMA, Yates PD. Neurotransmitter deficits in Alzheimer's disease and other dementing disorders. *Hum Neurobiol* 1986;5:147-58.
- 17 Chui HC, Mortimer JA, Slager U. *et al*. Pathologic correlates of dementia in Parkinson's disease. *Arch Neurol* 1986;43:991-5.
- 18 Yamamoto Y, Hirano A. Nucleus raphe dorsalis in Alzheimer's disease. *Ann Neurol* 1985;17:573-7.
- 19 Marcyniuk B, Mann DMA, Yates PO. Loss of nerve cells from locus coeruleus in Alzheimer's disease is topographically arranged. *Neurosci Lett* 1986;64:247-52.
- 20 Jellinger K. Quantitative changes in some subcortical nuclei in aging, Alzheimer's disease and Parkinson's disease. *Neurobiol Aging* 1987;8: (in press).
- 21 Whitehouse PJ. The concept of subcortical- and cortical dementias: another look. *Ann Neurol* 1986;19:1-6.
- 22 Langston JW. MPTP: The promise of a new neurotoxin. In: Marsden CD, Fahn ST, eds. *Movement Disorders 2*. London: Butterworths 1987:73-90.