

Patisiran for the Treatment of Transthyretin-mediated Amyloidosis with Cardiomyopathy

Adam Ioannou, Marianna Fontana and Julian D Gillmore

National Amyloidosis Centre, University College London, Royal Free Campus, London, UK

DOI: <https://doi.org/10.17925/HI.2023.17.1.27>

Transthyretin (TTR) is a tetrameric protein, synthesized primarily by the liver, that acts as a physiological transport protein for retinol and thyroxine. TTR can misfold into pathogenic amyloid fibrils that deposit in the heart and nerves, causing a life-threatening transthyretin amyloidosis cardiomyopathy (ATTR-CM), and a progressive and debilitating polyneuropathy (ATTR-PN). Recent therapeutic advances have resulted in the development of drugs that reduce TTR production. Patisiran is a small interfering RNA that disrupts the complementary mRNA and inhibits TTR synthesis, and is the first gene-silencing medication licensed for the treatment of ATTR amyloidosis. After encouraging results following the use of patisiran for the treatment of patients with ATTR-PN, there has been increasing interest in the use of patisiran for the treatment of ATTR-CM. Various studies have demonstrated improvements across a wide range of cardiac biomarkers following treatment with patisiran, and have changed the perception of ATTR-CM from being thought of as a terminal disease process, to now being regarded as a treatable disease. These successes represent a huge milestone and have the potential to revolutionize the landscape of treatment for ATTR-CM. However, the long-term safety of patisiran and how best to monitor cardiac response to treatment remain to be determined.

Keywords

Amyloidosis, cardiomyopathy, patisiran, polyneuropathy, safety, transthyretin, transthyretin-mediated amyloidosis

Disclosures: Julian Gillmore has consulting income from Alexion, Alnylam, Eidos, Ionis, Intellia and Pfizer. Adam Ioannou and Marianna Fontana have no financial or non-financial relationships or activities to declare in relation to this article.

Review process: Double-blind peer review.

Compliance with ethics: This article involves a review of literature and does not report on new clinical data, or any studies with human or animal subjects performed by any of the authors.

Data availability: Data sharing is not applicable to this article as no datasets were generated or analysed during the writing of this study.

Authorship: The named authors meet the International Committee of Medical Journal Editors (ICMJE) criteria for authorship of this manuscript, take responsibility for the integrity of the work as a whole, and have given final approval for the version to be published.

Access: This article is freely accessible at touchCARDIO.com. © Touch Medical Media 2023

Received: 24 February 2023

Accepted: 24 April 2023

Published online: 8 June 2023

Citation: *Heart International*. 2023;17(1):27–35

Corresponding author: Julian D Gillmore, National Amyloidosis Centre, University College London, Royal Free Hospital, Rowland Hill Street, NW3 2PF, London, UK. E: j.gillmore@ucl.ac.uk

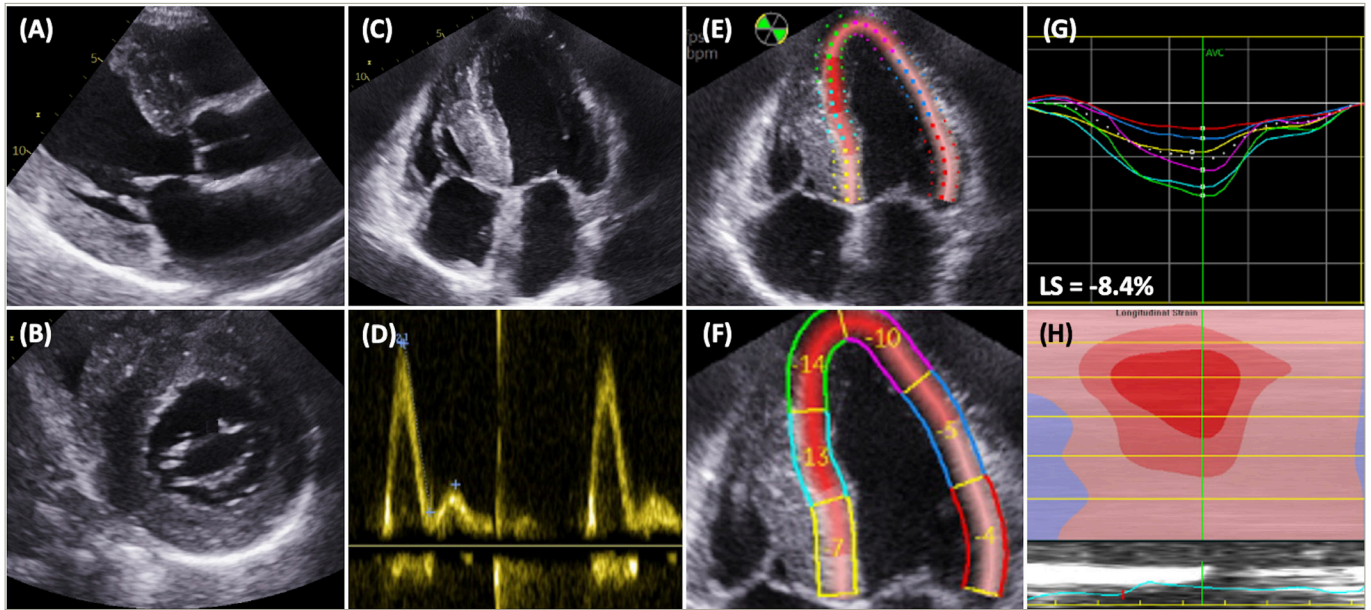
Support: No funding was received in the publication of this article.

The systemic amyloidoses are a group of heterogeneous diseases, which are characterized by the deposition of insoluble amyloid fibrils within the extracellular matrix of multiple organs throughout the body. Amyloid fibrils are formed from the misfolding of amyloid precursor proteins (APPs) into insoluble, beta-pleated sheets that are resistant to proteolysis. They are histologically characterized by apple-green birefringence when stained with Congo red and examined under cross-polarized light.^{1,2} Transthyretin amyloidosis, better known as ATTR amyloidosis, occurs secondary to the misfolding of the transthyretin (TTR) protein. TTR is synthesized by the liver and circulates as a tetramer, acting as a physiological vehicle for the transportation of retinol and thyroxine. ATTR amyloid fibrillogenesis occurs when the stable tetrameric form of TTR becomes unstable and dissociates into monomers or is cleaved into fragments, the substrate from which the fibrils are derived. Disease occurs when the aggregation of amyloid fibrils disrupts the structure and function of an affected organ.^{3,4} The factors that determine organ tropism of amyloid deposits remain uncertain. However, electron microscopic examination of cardiac and nerve biopsies has demonstrated basement membrane thickening or reduplication.⁵ This is associated with the formation of advanced glycosylation end products, which are thought to potentially play a role in promoting amyloid formation and fibril accumulation.⁵

The formation of ATTR amyloid fibrils either occurs secondary to a pathological process that is associated with age-related homeostatic mechanisms, known as wild-type ATTR (ATTRwt) amyloid, or occurs secondary to an inherited single-point mutation in the *TTR* gene, which is known as hereditary ATTR or variant ATTR (ATTRv) amyloid.⁶ The clinical characteristics depend on the underlying inherited genetic mutation. ATTRwt amyloidosis predominantly affects males and is typically seen in patients over 65 years of age, although it may present as young as 50 years of age.⁷

Myocardial deposition of ATTR fibrils causes an infiltrative and restrictive cardiomyopathy, typified by increased biventricular wall thickness and reduced myocardial compliance.⁸ Initially, stiffening of the myocardium results in increased left ventricular filling pressures and diastolic dysfunction. Evolution of the disease process leads to systolic impairment, which begins with longitudinal systolic dysfunction and is followed by radial systolic dysfunction. Amyloid infiltration begins in basal segments of the left ventricle and often results in a characteristic 'bull's eye' strain pattern on echocardiography, with an increased septal apical-to-basal strain ratio and relative apical sparing (*Figure 1*). Cardiac amyloid infiltration also results in characteristic features on cardiac magnetic resonance (CMR) imaging, with elevated myocardial native T1, biventricular circumferential subendocardial/transmural late gadolinium enhancement and an elevated myocardial extracellular volume (ECV) (*Figure 2*).^{8–10} Cardiac manifestations of amyloid infiltration also include aortic stenosis, conduction disease and atrial fibrillation with an increased risk of thrombus formation.^{3,11} Extra-cardiac sites of amyloid infiltration can result in carpal tunnel syndrome, lumbar spine

Figure 1: Characteristic echocardiographic features of transthyretin amyloidosis cardiomyopathy



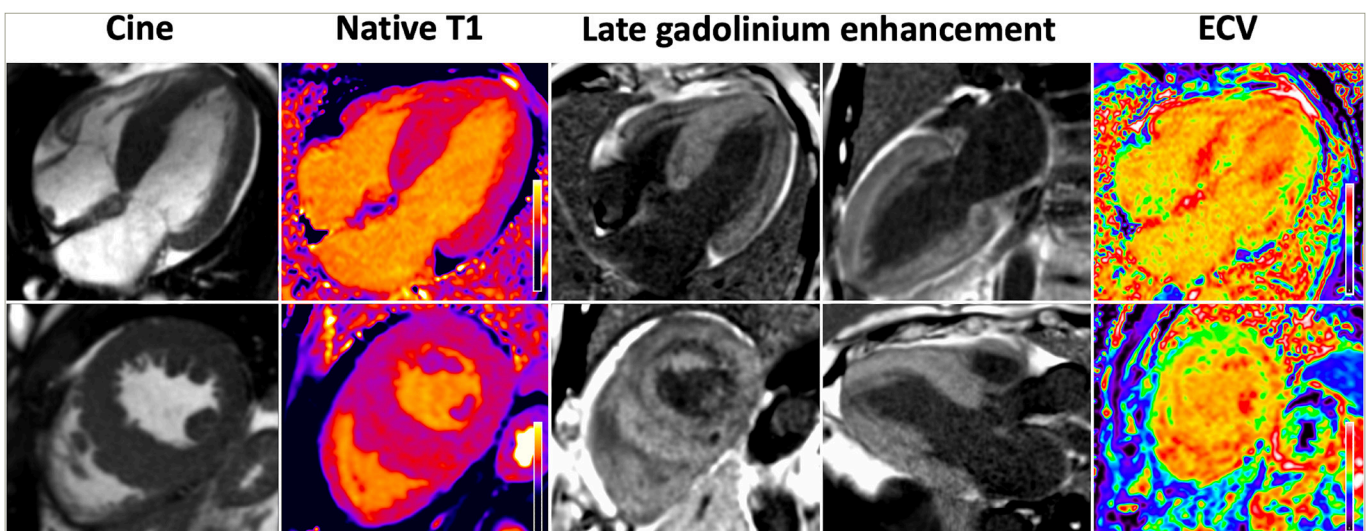
A: Parasternal long-axis view demonstrating increased interventricular and inferolateral wall thickness; B: Parasternal short-axis view demonstrating increased wall thickness; C: Four-chamber view demonstrating biventricular increased wall thickness; D: Pulsed wave Doppler of the mitral valve demonstrating an E/A ratio >2 and grade 3 diastolic dysfunction; E: Longitudinal strain (LS) measured in the four-chamber view; F: Increased septal apical-to-basal strain ratio; G, H: Longitudinal strain map demonstrating relative apical sparing and a 'bull's eye' strain pattern.

stenosis and tendinopathies.¹²⁻¹⁴ ATTRv amyloidosis may present at a younger age with a mixed clinical phenotype comprising ATTR cardiomyopathy (ATTR-CM) and a peripheral polyneuropathy (ATTR-PN). Patients presenting with polyneuropathy typically develop a progressive and debilitating, length-dependant, axonal sensory-motor peripheral polyneuropathy and/or autonomic neuropathy. The multisystem nature of ATTR amyloidosis is often best managed with multidisciplinary input from cardiologists, neurologists and orthopaedists.¹⁵ However, despite polyneuropathy causing severe debilitating symptoms, cardiac amyloid infiltration remains the main cause of mortality (Table 1).^{16,17}

Traditionally, ATTR amyloidosis was considered to be a rare disease, but developments in diagnostics and increased awareness of the condition have resulted in a substantial increase in diagnoses over the last two

decades. Increased recognition of ATTR amyloidosis has been driven in part by a non-biopsy diagnostic algorithm that utilizes the impressive sensitivity of bone scintigraphy for identification of cardiac ATTR amyloid deposits. In the absence of biochemical evidence such as a monoclonal gammopathy, the characteristic features of cardiac amyloidosis on echocardiography or CMR, combined with grade 2 or 3 cardiac uptake on bone scintigraphy, is diagnostic of ATTR-CM.¹⁸ This diagnostic algorithm has since been validated in several studies,¹⁹ including a large multicentre study that confirmed a high specificity and positive predictive value.²⁰ In cases in which the non-biopsy criteria are not fulfilled, diagnosis is confirmed with either grade 2 or 3 cardiac uptake on bone scintigraphy and ATTR amyloid in an extra-cardiac biopsy, or direct endomyocardial biopsy proof of ATTR amyloid (Table 1).

Figure 2: Characteristic cardiac magnetic resonance imaging features of transthyretin amyloidosis cardiomyopathy



Cine images demonstrate asymmetrical septal increased wall thickness and an increased left ventricular mass. Tissue characterization demonstrates a global elevation in myocardial native T1, biventricular circumferential subendocardial/transmural late gadolinium enhancement and a global elevation in myocardial extracellular volume. ECV = extracellular volume.

Table 1: Characteristics of transthyretin amyloidosis cardiomyopathy

Characteristics	Notes
Demographics	ATTRwt: age of onset >65 years ATTRv: age of onset between 30 and 80 years (dependant on the mutation) Male predominance
Prevalence	True prevalence is unknown: – In autopsy studies, ATTR deposits have been demonstrated in 25% of myocardial samples in elderly patients – p.(Val142Ile) variant is carried by 3–4% of African Americans – p.(Thr80Ala) variant is carried by ~1% of Irish descent. (Val50Met) variant is carried by ~0.1% in endemic areas of Portugal, Sweden and Japan
Cardiac manifestations	Restrictive cardiomyopathy Systolic and diastolic dysfunction Atrial fibrillation Aortic stenosis Conduction disease
Extra-cardiac manifestations	Carpal tunnel syndrome Biceps tendon rupture Lumbar spine stenosis Peripheral/autonomic neuropathy in patients with ATTRv and a mixed phenotype
Serum cardiac enzymes	Elevated N-terminal pro B-type natriuretic peptide Elevated troponin
Electrocardiographic findings	Small voltage QRS complexes Pseudo infarct pattern Ischaemic or non-specific T-wave abnormalities Left anterior hemiblock Heart block
Echocardiographic findings	Increased biventricular wall thickness Increased relative wall thickness Small left ventricular cavity Elevated left ventricular filling pressures (increased E/A ratio and E/e') Reduced mitral and tricuspid annular systolic plane excursion Bull's eye strain pattern with apical sparing
Cardiac magnetic resonance findings	Increased left ventricular mass Increased native T1 Diffuse subendocardial/transmural late gadolinium enhancement Increased extracellular volume
Bone scintigraphy	Grade 2 or 3 cardiac uptake in the majority of cases*

Continued

Table 1: Continued

Characteristics	Notes
Diagnosis	The presence of heart failure symptoms, and characteristic features of cardiac amyloidosis on echocardiography or CMR imaging and one of the following: – Direct endomyocardial biopsy proof of ATTR deposits – Cardiac uptake on bone scintigraphy and non-cardiac histology demonstrating ATTR deposits – Non-biopsy criteria: grade 2–3 cardiac uptake on bone scintigraphy and the absence of a biochemical evidence of a plasma cell dyscrasia in the plasma or urine

*Certain forms of ATTRv-CM produce disproportionately low cardiac uptake on bone scintigraphy such as p.(Ser97Tyr), p.(Phe84Leu) and p.(Tyr134Cys).
ATTR = transthyretin amyloidosis; CMR = cardiac magnetic resonance; v = variant; wt = wild type.

The UK National Amyloidosis Centre (NAC) has been commissioned for the diagnosis and monitoring of amyloidosis. Data from the centre have demonstrated a dramatic increase in the number of ATTR-CM diagnoses over the last 20 years, from 35 cases between 2002 and 2006, to 968 cases between 2017 and 2021.²¹ A similar observation has been documented in Sweden, where the prevalence of ATTR-CM has increased from 1 per 100,000 to 5 per 100,000 over a 10-year period.²² However, the true prevalence of ATTR-CM remains unknown. With postmortem examinations revealing ATTR amyloid deposits in one-quarter of cardiac histological samples in elderly patients,²³ and large population studies demonstrating certain *TTR* gene variants to be endemic in specific populations, the true prevalence is likely to be significantly higher than that reported in the medical literature.²⁴

Before the availability of specific disease-modifying medicines, patients with p.(Val50Met) ATTRv-PN were successfully treated through liver transplantation. Following orthotopic liver transplantation, variant TTR is rapidly cleared from the systemic circulation due to its short plasma half-life, and replaced by wild-type TTR since there is no extra-hepatic source of circulating TTR. The halting of hepatic variant TTR production stops ATTRv fibril formation and the subsequent accumulation within the nervous system, and thus slows or prevents further deterioration of neuropathic symptoms. Success following liver transplantation supported the premise that reducing amyloidogenic TTR production could stabilize the disease process, and prevent further deterioration.²⁵

The last decade has seen the development of multiple pharmacological therapeutic agents that can be used to treat ATTR amyloidosis. Initially, these agents were designed to induce targeted stabilization of the TTR tetramer, to prevent it from dissociating into amyloidogenic monomers or being cleaved into amyloidogenic fragments. This resulted in the development of tafamidis, a small molecule TTR stabilizer that was shown to reduce all-cause mortality in the seminal ATTR-ACT trial, and was subsequently licensed as the only available treatment of ATTR-CM.²⁶ More recently, medicines have been developed with the aim of suppressing TTR production by specifically targeting and suppressing hepatic TTR synthesis.⁸ It is noteworthy that in all types of systemic amyloidosis in which reduction of the circulating APP (e.g. serum amyloid A protein in AA amyloidosis and monoclonal immunoglobulin light chain protein in AL amyloidosis) is achievable, reduction of the circulating APP

has been associated with improved patient outcomes. Indeed, there is a strong correlation between the magnitude of 'knockdown' of the circulating APP and clinical outcomes.²⁷⁻²⁹ Studies with serial serum amyloid P scintigraphy,³⁰ (a quantitative nuclear medicine technique that visualizes visceral amyloid deposits), and with serial ECV measurement by CMR,³¹ have shown that a substantial reduction of circulating APP concentration often leads to gradual amyloid regression from both the viscera and the heart. It is thus anticipated that deep reductions in circulating TTR will be associated with regression of amyloid and better outcomes in patients with ATTR amyloidosis. This treatment paradigm led to the development of patisiran, a first-generation small interfering RNA (siRNA) that targets and degrades the mRNA that codes for the TTR protein.^{32,33} This review will explore the use of patisiran for the treatment of ATTR-CM, and will also provide insights in future perspectives.

Patisiran

Mechanism of action and pharmacokinetics

Patisiran is the original siRNA that was specifically developed to treat patients with ATTR amyloidosis. siRNAs comprise double-stranded RNA molecules that bind to complementary mRNA molecules and cause degradation, hence interfering with protein synthesis. Following administration, siRNAs must be transported into the intracellular cytoplasm of the intended cells while evading breakdown from phagocytes and nucleases in the circulation, and also avoiding excretion.³⁴⁻³⁶ Patisiran is formulated as an encapsulated lipid nanoparticle that protects the siRNA molecule. The lipid nanoparticle is coated in apolipoprotein E, which binds to the low-density lipoprotein on the hepatocyte membrane to

ensure targeted delivery. Once released into the hepatocyte intracellular cytoplasm, the double-stranded siRNA molecule divides into two single-stranded RNA molecules, which bind to a genetically preserved sequence in the 3' untranslated portion of the complementary wild-type or variant TTR mRNA. The binding process triggers Argonaute slicer protein activation, which subsequently degrades the mRNA, thereby inhibiting TTR synthesis.^{32,33}

Patisiran is administered as an intravenous infusion of 0.3 mg/kg every 3 weeks, with a single administration achieving a maximum reduction in serum TTR concentration of 88%, and a steady plasma level being achieved by 24 weeks.³⁷ Patisiran is metabolized into nucleotides and has an elimination half-life of 3 ± 2 days, with less than 1% being excreted unchanged in the urine. Mild or moderate renal impairment (chronic kidney disease stage 1-3) and mild hepatic impairment do not affect the pharmacokinetics of patisiran or its ability to induce TTR knockdown, and patisiran does not interfere with cytochrome P450 activity, which is responsible for the metabolism of many small molecule drugs (Table 2).³²

Clinical trials

Following a successful phase I clinical trial,³⁷ a phase II clinical trial of 29 patients with ATTRv-PN demonstrated that after two doses of patisiran the mean reduction in serum TTR from baseline was 85%, and the maximum reduction was 96%.³⁸ In a 24-month open-label extension of 27 patients, 11 of whom had concomitant cardiac involvement, patisiran treatment halted the progression of neurological disease and stabilized

Table 2: Summary of the characteristics of patisiran

Characteristics	Notes
Mechanism of action	Small interfering ribonucleic acid that causes degradation of the TTR mRNA
Dose	80 min intravenous infusion every 3 weeks. Dosage is based on bodyweight: <100 kg=0.3 mg/kg; >100 kg=30 mg
Premedication	Dexamethasone, paracetamol, ranitidine and antihistamine
Pharmacokinetics	Systemic exposure increases in a linear and dose-proportional manner Greater than 95% of circulating patisiran is associated with the lipid complex A steady state is reached by 24 weeks Patisiran is metabolized into nucleotides of various lengths Half-life is 3 ± 2 days Less than 1% is excreted unchanged in the urine Mild-to-moderate renal dysfunction and mild hepatic impairment do not affect the pharmacokinetics
Pharmacodynamics	Mean serum TTR reduction of approximately 80% within 10-14 days after single dose Maximum reduction of serum TTR after a single dose of 88% Mean reduction of serum TTR at 12 months of 87% Similar reductions occur regardless of mutation, age, sex or race Mean reductions of serum retinol binding protein of 45% and serum vitamin A of 62% occur at 18 months
Neurological trial outcomes	APOLLO: - Reduced mNIS+7 - Reduced Norfolk QOL - Reduced COMPASS-31 - Increased gait speed
Cardiology trial outcomes	APOLLO prespecified cardiac population: - Reduced serum NT-proBNP - Increased gait speed - Reduced left ventricular wall thickness - Increased left ventricular end diastolic volume APOLLO-B: - Increased 6-min walk test - Increased KCCQ-OS - Improved longitudinal strain
Potential adverse events	Infusion-related reactions including but not limited to back pain, nausea, abdominal pain, dyspnoea, chills, flushing and headache Upper respiratory tract infections Vitamin A deficiency Peripheral oedema

KCCQ-OS = Kansas City Cardiomyopathy Questionnaire Overall Summary Score; mNIS+7 = modified Neuropathy Impairment Score +7 neurophysiologic tests; NT proBNP = N-terminal pro B-type natriuretic peptide; QOL = quality of life; TTR = transthyretin.

cardiac disease, with there being no significant changes in serum cardiac enzymes or echocardiographic parameters.³⁹

The APOLLO phase III trial was a double-blind, placebo-controlled, randomized study of 225 patients with ATTRv-PN, and was designed to evaluate the safety and efficacy of patisiran.²⁹ After 18 months of treatment, there was a significant improvement from baseline in the modified Neuropathy Impairment Score +7 neurological tests (mNIS+7), Norfolk Quality of Life Questionnaire-Diabetic Neuropathy (Norfolk QOL-DN) score and gait speed in the group treated with patisiran, compared with the placebo group.²⁹ Patients treated with patisiran demonstrated a significant improvement compared with those on placebo across all components of the Composite Autonomic Symptom Scale 31, which is designed to assess the burden of autonomic neuropathy.⁴⁰ Following the success of the APOLLO trial, patisiran was approved for the treatment of ATTRv-PN by both the European Commission and the United States Food and Drug Administration in 2018.^{32,33}

Cardiac outcomes

To assess the efficacy of patisiran in patients with ATTR-CM accompanying ATTR-PN (i.e. ATTR-mixed), a *post-hoc* analysis was carried out on a subset of 126 patients enrolled in the APOLLO trial, who were considered to have cardiac involvement based on prespecified criteria of a left ventricular wall thickness ≥ 13 mm in the absence of hypertension or significant aortic valve disease.⁴¹ Treatment with patisiran was associated with a reduced mean left ventricular wall thickness and relative wall thickness at 18 months compared with placebo. Patisiran treatment also resulted in an increased left ventricular end diastolic volume and improved global longitudinal strain and cardiac output. The patisiran group had a significant reduction in serum N-terminal pro B-type natriuretic peptide (NT-proBNP) and a significant increase in 10-metre walk test gait speed when compared with patients in the placebo group. The favourable changes in both cardiac structure and function were associated with a lower combined event rate of all-cause hospitalization and mortality in the treatment group compared with the placebo group. However, this *post-hoc* analysis does have significant limitations. The prespecified definition of cardiac involvement does not adhere with published diagnostic recommendations, and despite being sensitive, it lacks specificity. A relatively small cohort of patients were included, with only 36 patients in the placebo arm, and due to the *post-hoc* design, the analysis was unblinded. Lastly, despite a significantly lower all-cause hospitalization and mortality rate in the treatment group, there was no significant difference in cardiovascular hospitalizations and mortality, which raises the possibility that observed differences could be due to treatment of the underlying polyneuropathy rather than cardiomyopathy. Nevertheless, this analysis was the first to suggest that patisiran may halt the progression of cardiomyopathy in ATTR amyloidosis; however, the findings require confirmation in a randomized controlled trial in patients with ATTR-CM.⁴¹

The observations above were reinforced by a small but important study in 16 patients with ATTR-mixed, treated with patisiran and diflunisal.⁴² Treatment was well tolerated and achieved >80% knockdown in serum TTR in 82% of cases, which was associated in some patients with a significant reduction in CMR-derived ECV and NT-proBNP, and an increase in 6-minute walk test (6MWT) distance following 1 year of treatment. Baseline and follow-up bone scintigraphy revealed a reduction in cardiac uptake following patisiran treatment. However, although the reduction in cardiac uptake on bone scintigraphy undeniably demonstrated a favourable biological effect of patisiran, the kinetics and dynamics of radiotracers binding to the myocardium, bones and soft tissues may

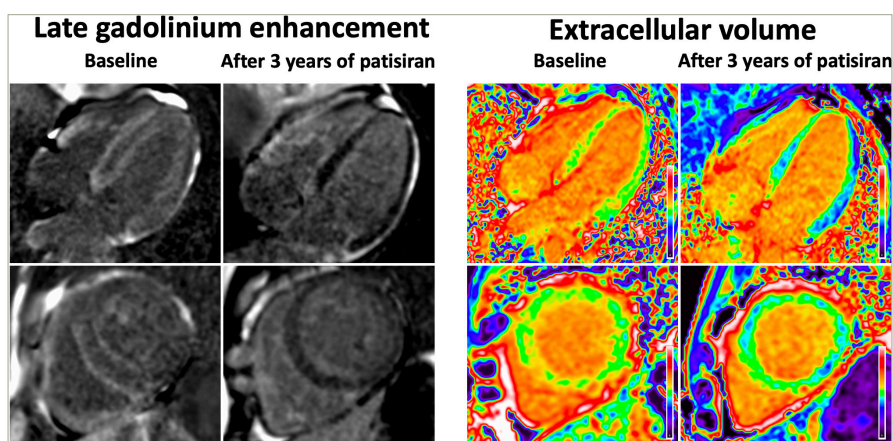
fluctuate, and therefore variations in any of these organs will influence both the visual appearance and mathematical calculation of proportionate myocardial radiotracer uptake. Therefore, reduced myocardial uptake on bone scintigraphy should always be supported by improvements in other measures of cardiac function, such as either serum cardiac enzymes or alternative cardiac imaging modalities, before the observed changes are attributed exclusively to a reduction in the burden of cardiac amyloid.⁴²

The APOLLO-B trial is a phase III randomized placebo-controlled, double-blind study that enrolled 360 patients to evaluate the efficacy and safety of patisiran treatment in patients with ATTR-CM.^{43,44} The APOLLO-B trial enrolled patients with both wild-type and variant ATTR-CM who had clinical evidence of heart failure and an elevated NT-proBNP between 300 ng/L and 8,500 ng/L. Patients were randomized 1:1 to either patisiran or placebo. Patisiran treatment resulted in sustained reductions in serum TTR, with a mean knockdown of 87% at 12 months. Patisiran demonstrated significant clinical benefit in functional capacity as measured by the change in 6MWT results at 12 months compared with placebo, with the decline in 6MWT in the patisiran group being similar to a typical age-related decline seen in healthy adults. A prespecified sensitivity analysis using a mixed-effects model for repeated measures confirmed the robustness of these findings and demonstrated a significant mean difference in 6MWT distance at 12 months of 18 metres between the patisiran and placebo groups. Patisiran treatment resulted in a significant and favourable difference in the change from baseline in Kansas City Cardiomyopathy Questionnaire Overall Summary score (KCCQ-OS) at 12 months compared with placebo. However, there was no difference in the time to first event (all-cause hospitalization, urgent heart failure visits or death). Despite there being no statistically significant differences in mortality between the two groups, which may in part reflect the short study duration, the data were numerically in favour of patisiran (4 patients [2%] versus 10 patients [6%]). The efficacy and safety of patisiran treatment in patients with ATTR-CM will continue to be assessed during the open-label extension. It is noteworthy that although the APOLLO-B results have been presented at international conferences, the full manuscript is yet to be published, and therefore more detail is required before formal conclusions can be drawn.^{43,44}

Safety

Patisiran is prescribed with premedication consisting of an antihistamine, a corticosteroid, paracetamol and ranitidine to reduce the risk of patients developing infusion-related reactions (Table 2). During the phase I trial of patisiran, 21% of participants had mild or moderate infusion-related reactions. All mild reactions resolved spontaneously, and moderate reactions resolved after temporarily stopping the infusion and then continuing the infusion at a slower rate.³⁷ Continued use of patisiran for over 18 months was associated with a 62% reduction in serum vitamin A levels, which reflects the physiological function of TTR as a carrier for retinol-binding protein that, in turn, transports vitamin A. Therefore, all patients prescribed patisiran are also routinely prescribed oral vitamin A supplementation (2,500 IU per day) as prophylaxis.³² In the APOLLO phase III trial there were no significant differences in the frequency of adverse events between patients on patisiran treatment and those in the placebo group, and importantly, there were no reports of eye complications. Infusion-related reactions and peripheral oedema occurred more commonly in the patisiran group, but there was a low incidence of serious adverse events. There were seven deaths in the patisiran group, none of which were related to treatment as all were thought to be consistent with the natural progression of ATTRv amyloidosis.²⁹ In the APOLLO-B trial, patisiran was well tolerated and the vast majority of adverse events were either mild or moderate in severity. Infusion-related reactions,

Figure 3: Cardiac magnetic resonance images demonstrating a reduction in the amount of late gadolinium enhancement and a reduction in the extracellular volume, following 3 years of treatment with patisiran



arthralgia and muscle spasms were more common in patients treated with patisiran than in the placebo group. There were four deaths in the patisiran group, none of which were deemed to be related to treatment.⁴⁴

Comparison between patisiran and tafamidis

Tafamidis remains the only licensed treatment for ATTR-CM, and was approved following the ATTR-ACT trial that demonstrated a reduction in the composite hierarchical primary endpoint of all-cause mortality and cardiovascular hospitalizations, as well as a lower rate of decline in 6MWT distance and KCCQ-OS score compared with placebo.²⁶ Despite patisiran treatment resulting in favourable changes across a range of metrics, it has not yet been shown to influence cardiovascular outcomes. Although it is possible that these disparities relate to different drug mechanisms, they are also likely influenced by the differences in study populations and study design. APOLLO-B was a 12-month study and the primary endpoint was change in 6MWT, rather than cardiovascular events. ATTR-ACT was a 30-month study and the primary endpoint was a hierarchical composite of all-cause mortality followed by cardiovascular hospitalizations. Baseline patient characteristics indicate more advanced cardiac disease among ATTR-ACT study participants than those in the APOLLO-B trial, and consequently the event rate in ATTR-ACT was higher. A larger population would have been required in APOLLO-B to ensure adequate power to demonstrate a difference in cardiac events. These data also raise questions regarding the efficacy of individual treatments at different stages of the disease course, and more data are needed to clarify the relative treatment benefits in different disease stages.²¹

Tafamidis and patisiran differ in their route of administration. Tafamidis is administered orally and is thus convenient; patisiran is an intravenous infusion that requires premedication and co-prescription of prophylactic vitamin A. Both have a good safety profile, although a smaller proportion of patients in the treatment arm of ATTR-ACT reported adverse events than in APOLLO and APOLLO-B, where the majority of events were infusion-related reactions. However, in the absence of any head-to-head trials, comparisons between these different treatments are, by definition, flawed.^{26,29,43,44}

Patisiran is able to achieve >80% serum TTR knockdown in the majority of patients.⁴⁵ However, this leaves a significant proportion of circulating TTR that could misfold into ATTR fibrils. It is conceivable that simultaneously reducing TTR production and inducing TTR stabilization could be synergistic and further improve patient outcomes. However, large-scale

trials would be needed to assess whether combination therapy has any added benefit.⁴⁵

Monitoring the cardiac response to patisiran

Following promising trial results there has been an increasing interest in the use of patisiran to treat ATTR-CM, and at present there is an unmet clinical need to develop standardized measures of the cardiac response to treatment. Advancements in cardiac imaging, combined with increased awareness among clinicians, has resulted in patients being diagnosed earlier in the disease process. This is evident by a shorter duration of heart failure and neuropathic symptoms prior to diagnosis, and a milder NAC disease stage at the time of diagnosis.²¹ This has translated into improved survival and a reduced event rate in the ATTR-CM population, which will invariably have an influence on the design of future clinical trials, with a greater number of patients being recruited and for longer follow-up durations in order to ensure adequate power.²¹ Such changes will substantially increase the cost of clinical trials, and the question remains as to whether cardiac biomarkers or imaging measures can be leveraged as surrogates to facilitate a safe but more cost-effective assessment of novel medicines.

NT-proBNP has long been utilized in the heart failure population to assess the response to heart failure medications, and also in AL amyloidosis to monitor treatment response.⁴⁶ However, NT-proBNP fluctuations represent the final common pathway of multiple interlinked mechanisms such as ventricular remodelling, renal dysfunction, fluid status and neurohormonal activation,⁴⁷ hence, these changes do not necessarily reflect the change in cardiac amyloid burden.⁴⁸ High-sensitivity troponins are widely used in the assessment of multiple acute cardiac conditions,⁴⁹ and contribute to risk stratification in cardiac AL amyloidosis.⁵⁰ Due to their high sensitivity, even small fluctuations reflect changes in disease activity.⁴⁹ However, their use in monitoring treatment response in ATTR-CM requires further exploration and validation.

The search for a clinical biomarker that can easily measure the cardiac response to patisiran has led to increasing interest in the use of multimodality cardiac imaging. Improvements in various echocardiographic parameters have been reported following treatment with patisiran.⁴¹ However, echocardiographic measures are subject to high levels of intra- and inter-observer variability, which represents a significant limitation when only small changes in echocardiographic parameters are expected.⁵¹ The emergence of data science has

Table 3: Different serum biomarkers and imaging modalities used to monitor the cardiac response to treatment in transthyretin amyloidosis cardiomyopathy

	NT-proBNP	Transthoracic echocardiogram	Cardiac magnetic resonance	Bone scintigraphy	Positron emission tomography
Accessibility	Easily accessible	Easily accessible	Only at specialist centres	Only at specialist centres	Not clinically approved in ATTR-CM
Ability to track patisiran treatment response	Serum NT-proBNP reduces following patisiran treatment	Improved longitudinal strain, reduced wall thickness and increased LVEDV has been observed in response to patisiran treatment	Reduced ECV in response to patisiran treatment indicates amyloid regression	Unable to reliably track treatment response because changes in cardiac uptake are affected by changes in dynamics and kinetics of bone tracers	At present there are no data to support the ability to track treatment response
Time	5 min	20–30 min	40–60 min	Scan takes place 3 h after tracer injection and each scan takes 30 min	40–60 min
Advantages	<ul style="list-style-type: none"> – Cheap – Fast 	<ul style="list-style-type: none"> – Can be used in pregnancy – No vascular access needed – Does not use ionizing radiation 	<ul style="list-style-type: none"> – Not affected by body habitus – Does not require ionizing radiation 	<ul style="list-style-type: none"> – Not affected by body habitus – Not operator dependant 	<ul style="list-style-type: none"> – Not affected by body habitus – Not operator dependant
Disadvantages	<ul style="list-style-type: none"> – Influenced by multiple non-cardiac factors – It is unknown if reductions in response to treatment correlate with improved prognosis in ATTR-CM – Vascular access is needed 	<ul style="list-style-type: none"> – Image quality varies depending on acoustic windows – Extremely operator dependant – High intra- and inter-observer variability when measuring parameters 	<ul style="list-style-type: none"> – Image quality is affected by arrhythmias and breathing – Gadolinium contrast is needed – Not possible in patients with non-MRI safe metalwork – Unsafe in pregnancy – Vascular access is needed 	<ul style="list-style-type: none"> – Unsafe in pregnancy and breastfeeding – Requires exposure to ionizing radiation – Vascular access is needed 	<ul style="list-style-type: none"> – Unsafe in pregnancy and breastfeeding – Requires exposure to ionizing radiation – Vascular access is needed

ATTR-CM = transthyretin amyloidosis cardiomyopathy; ECV = extracellular volume; LVEDV = left ventricular end-diastolic volume; MRI = magnetic resonance imaging; NT-proBNP = N-terminal pro B-type natriuretic peptide.

the potential to significantly improve precision and overcome these obstacles.⁸ Various studies have utilized convolutional neural networks in multiple different modalities of cardiovascular imaging, and to date, all have yielded encouraging results.^{52,53} The automation of measurements is associated with a significant improvement in precision, and may facilitate a more accurate assessment of the cardiac response to treatment with patisiran.^{52,54}

CMR with multi-parametric mapping has emerged as an essential tool for the assessment of ATTR-CM. Amyloidosis is the exemplar interstitial disease, with amyloid accumulation resulting in expansion of the extracellular matrix. Therefore, myocardial ECV quantification acts as a powerful surrogate measure of the cardiac amyloid burden.^{4,55,56} In patients with cardiac AL amyloidosis, changes in ECV following treatment predate any change in structural or functional parameters and accurately predict survival, even after adjusting for traditional predictors, such as change in NT-proBNP and longitudinal strain.⁵⁷ At present, only one small study of patients with ATTR-CM has demonstrated ECV regression following treatment with patisiran, but if these results were to be reproduced on a larger scale, ECV mapping could become more widely utilized to assess the cardiac response to patisiran (Figure 3).^{42,45}

Although reduced cardiac uptake on bone scintigraphy has been reported following treatment with patisiran, changes in myocardial radiotracer uptake are also heavily influenced by changes in the dynamics and kinetics of bone tracers, and therefore bone scintigraphy alone cannot be used as a reliable measure of the cardiac response at present.⁴² The use

of positron emission tomography and various novel tracers has shown diagnostic potential in ATTR-CM, but at present there is a lack of robust data supporting their use in tracking treatment response (Table 3).^{58–64}

Long-term safety of patisiran

Although short- to medium-term patisiran-induced TTR knockdown appears safe, studies with prolonged follow-up are required to establish whether there are any long-term side effects. The physiological role of the TTR protein was previously thought to be limited to the transportation of thyroxine and vitamin A. However, various *in vitro* and *in vivo* studies suggest that TTR may have additional roles within the central nervous system. Animal studies have demonstrated that 5-month-old mice with complete TTR knockdown developed significant memory impairment compared with age-matched mice,⁶⁵ and TTR deficiency in rats lead to accelerated age-related decline in cognitive performance.⁶⁶ These findings have fuelled the hypothesis that the TTR protein may have a role in delaying Alzheimer's-related neurodegeneration, a disease process characterized by the accumulation of amyloid- β plaques within the brain. *In vitro* studies demonstrated that TTR sequesters amyloid- β when added to cerebrospinal fluid,⁶⁷ and mouse models have demonstrated hippocampal upregulation of TTR in response to the formation of hippocampal amyloid- β plaques, suggesting a possible neuroprotective response.⁶⁸ Subsequent anti-TTR antibody infusion led to augmented amyloid- β plaque development, loss of neurones and neuronal apoptosis.⁶⁹ In mouse models, surgical occlusion of the middle cerebral artery led to a significantly larger infarct area and greater degree of cerebral oedema in those with complete TTR depletion,⁷⁰ while

subsequent incubation of the hippocampal neurones with recombinant TTR was associated with improved neurite growth.⁷¹ The possible neuroprotective effect of TTR in cerebrovascular ischaemia has also been observed in humans, with a large observational cohort study of patients with cerebral infarction demonstrating that serum TTR levels represented an independent predictor of good outcomes.⁷²

Importantly, there has been no evidence to suggest cognitive decline or abnormality in patients receiving patisiran treatment continuously for over 5 years.⁴⁵ Furthermore, patisiran is unable to cross the blood–brain barrier and therefore does not interfere directly with TTR synthesis in the choroid plexus and retinal pigment epithelium, which are responsible for the production of TTR within the cerebrospinal fluid.⁷³

Future perspectives

Advances in siRNA conjugate delivery platforms assisted the development of vutrisiran, which is a 3-monthly subcutaneous injection that is administered without the need for predication. The HELIOS-A trial randomized patients with ATTRv-PN to vutrisiran or patisiran, and compared outcomes with an external placebo group from the APOLLO trial.⁷⁴ Vutrisiran treatment achieved similar serum TTR knockdown and was non-inferior to patisiran, resulting in improved mNIS+7 and

Norfolk QOL-DN scores when compared with placebo. It has since been approved for the treatment of ATTRv-PN.^{74,75} The ongoing HELIOS-B trial (ClinicalTrials.gov identifier: NCT04153149) aims to assess the efficacy of vutrisiran for the treatment of ATTR-CM, and if successful will potentially offer a convenient alternative to patisiran.⁷⁶

Conclusion

ATTR-CM remains a progressive and ultimately fatal disease. Reduction of the respective circulating APP in all types of amyloidosis in which it is possible, has long been known to be associated with improved patient outcomes. Similarly, recent studies have demonstrated that reducing the circulating TTR concentration with patisiran results in improvement in a wide range of cardiac and neurological disease measures, including cardiac enzymes, functional capacity, multiple cardiac imaging-based parameters, neurological scores and quality of life. These exciting results will potentially result in expansion of the patisiran license to include ATTR-CM, and increase the armamentarium of disease-modifying treatments available for this aggressive, but treatable, cardiomyopathy. While there have been no deleterious clinical consequences in the short to medium term of patisiran-induced TTR depletion, long-term effects remain to be determined. □

- Wechalekar AD, Gillmore JD, Hawkins PN. Systemic amyloidosis. *Lancet*. 2016;387:2641–54. DOI: 10.1016/S0140-6736(15)01274-X
- Lachmann HJ, Hawkins PN. Systemic amyloidosis. *Curr Opin Pharmacol*. 2006;6:214–20. DOI: 10.1016/j.coph.2005.10.005
- Martinez-Naharro A, Hawkins PN, Fontana M. Cardiac amyloidosis. *Clin Med (Lond)*. 2018;18:s30–5. DOI: 10.7861/clinmedicine.18-2-s30
- Fontana M, Čorović A, Scully P, Moon JC. Myocardial amyloidosis: The exemplar interstitial disease. *JACC Cardiovasc Imaging*. 2019;12:2345–56. DOI: 10.1016/j.jcmg.2019.06.023
- Koike H, Katsuno M. Transthyretin amyloidosis: Update on the clinical spectrum, pathogenesis, and disease-modifying therapies. *Neurol Ther*. 2020;9:317–33. DOI: 10.1007/s40120-020-00210-7
- Porcari A, Fontana M, Gillmore JD. Transthyretin cardiac amyloidosis. *Cardiovasc Res*. 2022;118:3517–35. DOI: 10.1093/cvr/cvab119
- Patel RK, Ioannou A, Razvi Y, et al. Sex differences among patients with transthyretin amyloid cardiomyopathy from diagnosis to prognosis. *Eur J Heart Fail*. 2022;24:2355–63. DOI: 10.1002/ejhf.2646
- Ioannou A, Patel R, Gillmore JD, Fontana M. Imaging-guided treatment for cardiac amyloidosis. *Curr Cardiol Rep*. 2022;24:839–50. DOI: 10.1007/s11886-022-01703-7
- Ioannou A, Patel RK, Razvi Y, et al. Multi-imaging characterization of cardiac phenotype in different types of amyloidosis. *JACC Cardiovasc Imaging*. 2022;16:464–77. DOI: 10.1016/j.jcmg.2022.07.008
- Martinez-Naharro A, Treibel TA, Abdel-Gadir A, et al. Magnetic resonance in transthyretin cardiac amyloidosis. *J Am Coll Cardiol*. 2017;70:466–77. DOI: 10.1016/j.jacc.2017.05.053
- Martinez-Naharro A, Gonzalez-Lopez E, Corovic A, et al. High prevalence of intracardiac thrombi in cardiac amyloidosis. *J Am Coll Cardiol*. 2019;73:1733–4. DOI: 10.1016/j.jacc.2019.01.035
- Carr AS, Pelayo-Negro AL, Evans MRB, et al. A study of the neuropathy associated with transthyretin amyloidosis (ATTR) in the UK. *J Neurol Neurosurg Psychiatry*. 2016;87:620–7. DOI: 10.1136/jnnp-2015-310907
- Yanagisawa A, Ueda M, Sueyoshi T, et al. Amyloid deposits derived from transthyretin in the ligamentum flavum as related to lumbar spinal canal stenosis. *Mod Pathol*. 2015;28:201–7. DOI: 10.1038/modpathol.2014.102
- Geller H, Singh A, Alexander KM, et al. Association between ruptured distal biceps tendon and wild-type transthyretin cardiac amyloidosis. *JAMA*. 2017;318:962–3. DOI: 10.1001/jama.2017.9236
- Koike H, Okumura T, Murohara T, Katsuno M. Multidisciplinary approaches for transthyretin amyloidosis. *Cardiol Ther*. 2021;10:289–311. DOI: 10.1007/s40119-021-00222-w
- Arruda-Olson AM, Zeldenrust SR, Dispenzieri A, et al. Genotype, echocardiography, and survival in familial transthyretin amyloidosis. *Amyloid*. 2013;20:263–8. DOI: 10.3109/13506129.2013.845745
- Porcari A, Razvi Y, Masi A, et al. Prevalence, characteristics and outcomes of older patients with hereditary versus wild-type transthyretin amyloid cardiomyopathy. *Eur J Heart Fail*. 2023;25:515–24. DOI: 10.1002/ejhf.2776
- Gillmore JD, Maurer MS, Falk RH, et al. Nonbiopsy diagnosis of cardiac transthyretin amyloidosis. *Circulation*. 2016;133:2404–12. DOI: 10.1161/CIRCULATIONAHA.116.021612
- González-López E, Gallego-Delgado M, Guzzo-Merello G, et al. Wild-type Transthyretin Amyloidosis as a cause of heart failure with preserved ejection fraction. *Eur Heart J*. 2015;36:2585–94. DOI: 10.1093/eurheartj/ehv338
- Rauf MJ, Hawkins PN, Cappelli F, et al. Tc-99m labelled bone scintigraphy in suspected cardiac amyloidosis. *Eur Heart J*. 2023;ehad139. DOI: 10.1093/eurheartj/ehad139
- Ioannou A, Patel RK, Razvi Y, et al. Impact of earlier diagnosis in cardiac ATTR amyloidosis over the course of 20 years. *Circulation*. 2022;146:1657–70. DOI: 10.1161/CIRCULATIONAHA.122.060852
- Lauppe RE, Liseth Hansen J, Gerdesköld C, et al. Nationwide prevalence and characteristics of transthyretin amyloid cardiomyopathy in Sweden. *Open Heart*. 2021;8:e001755. DOI: 10.1136/openhrt-2021-001755
- Tanskanen M, Peuralinna T, Polvikoski T, et al. Senile systemic amyloidosis affects 25% of the very aged and associates with genetic variation in alpha2-macroglobulin and tau: A population-based autopsy study. *Ann Med*. 2008;40:232–9. DOI: 10.1080/07853890701842988
- Adams D, Algalarrondo V, Polydefkis M, et al. Expert opinion on monitoring symptomatic hereditary transthyretin-mediated amyloidosis and assessment of disease progression. *Orphanet J Rare Dis*. 2021;16:411. DOI: 10.1186/s13023-021-01960-9
- Carvalho A, Rocha A, Lobato L. Liver transplantation in transthyretin amyloidosis: Issues and challenges. *Liver Transpl*. 2015;21:282–92. DOI: 10.1002/lt.24058
- Maurer MS, Schwartz JH, Gundapaneni B, et al. Tafamidis treatment for patients with transthyretin amyloid cardiomyopathy. *N Engl J Med*. 2018;379:1007–16. DOI: 10.1056/NEJMoa1805689
- Lachmann HJ, Goodman HJB, Gilbertson JA, et al. Natural history and outcome in systemic AA amyloidosis. *N Engl J Med*. 2007;356:2361–71. DOI: 10.1056/NEJMoa070265
- Palladini G, Dispenzieri A, Gertz MA, et al. New criteria for response to treatment in immunoglobulin light chain amyloidosis based on free light chain measurement and cardiac biomarkers: Impact on survival outcomes. *J Clin Oncol*. 2012;30:4541–9. DOI: 10.1200/JCO.2011.37.7614
- Adams D, Gonzalez-Duarte A, O'Riordan WD, et al. Patisiran, an RNAi therapeutic, for hereditary transthyretin amyloidosis. *N Engl J Med*. 2018;379:11–21. DOI: 10.1056/NEJMoa1716153
- Hawkins PN, Lavender JP, Pepys MB. Evaluation of systemic amyloidosis by scintigraphy with 123I-labeled serum amyloid P component. *N Engl J Med*. 1990;323:508–13. DOI: 10.1056/NEJM199008233230803
- Martinez-Naharro A, Patel R, Kotecha T, et al. Cardiovascular magnetic resonance in light-chain amyloidosis to guide treatment. *Eur Heart J*. 2022;43:4722–35. DOI: 10.1093/eurheartj/ehac363
- Uris I, Swanson D, Sweet MC, et al. A review of patisiran (ONPATTRO®) for the treatment of polyneuropathy in people with hereditary transthyretin amyloidosis. *Neurol Ther*. 2020;9:301–15. DOI: 10.1007/s40120-020-00208-1
- Setten RL, Rossi JJ, Han S-P. The current state and future directions of RNAi-based therapeutics. *Nat Rev Drug Discov*. 2019;18:421–46. DOI: 10.1038/s41573-019-0017-4
- Hu B, Zhong L, Weng Y, et al. Therapeutic siRNA: State of the art. *Signal Transduct Target Ther*. 2020;5:101. DOI: 10.1038/s41392-020-0207-x
- Caplen NJ, Mousseis S. Short interfering RNA (siRNA)-mediated RNA interference (RNAi) in human cells. *Ann N Y Acad Sci*. 2003;1002:56–62. DOI: 10.1196/annals.1281.007
- Friedrich M, Aigner A. Therapeutic siRNA: State-of-the-art and future perspectives. *BioDrugs*. 2022;36:549–71. DOI: 10.1007/s40259-022-00549-3
- Coelho T, Adams D, Silva A, et al. Safety and efficacy of RNAi therapy for transthyretin amyloidosis. *N Engl J Med*. 2013;369:819–29. DOI: 10.1056/NEJMoa1208760
- Suhr OB, Coelho T, Buares J, et al. Efficacy and safety of patisiran for familial amyloidotic polyneuropathy: A phase II multi-dose study. *Orphanet J Rare Dis*. 2015;10:109. DOI: 10.1186/s13023-015-0326-6
- Coelho T, Adams D, Conceição I, et al. A phase II, open-label, extension study of long-term patisiran treatment in patients with hereditary transthyretin-mediated (hATTR) amyloidosis. *Orphanet J Rare Dis*. 2020;15:179. DOI: 10.1186/s13023-020-01399-4
- González-Duarte A, Berk JL, Quan D, et al. Analysis of autonomic outcomes in APOLLO, a phase III trial of the RNAi therapeutic patisiran in patients with hereditary transthyretin-mediated amyloidosis. *J Neurol*. 2020;267:713–4. DOI: 10.1007/s00415-020-09715-5
- Solomon SD, Adams D, Kristen A, et al. Effects of patisiran, an RNA interference therapeutic, on cardiac parameters in patients with hereditary transthyretin-mediated amyloidosis. *Circulation*. 2019;139:431–43. DOI: 10.1161/CIRCULATIONAHA.118.035831
- Fontana M, Martinez-Naharro A, Chacko L, et al. Reduction in CMR derived extracellular volume with patisiran indicates cardiac amyloid regression. *JACC Cardiovasc Imaging*. 2021;14:189–99. DOI: 10.1016/j.jcmg.2020.07.043
- Alnylam Pharmaceuticals, Inc. Topline results from APOLLO-B phase 3 study of Patisiran. 2022. Available at: <https://alnylampharmaceuticalsinc.gcs-web.com/static-files/d6c1b882-9346-4394-9f5c-dd32272742b> (Date last accessed: 6 June 2023).
- Maurer MS, Fontana M, Berk J, et al. Primary results from APOLLO-B, a phase 3 study of patisiran in patients with transthyretin-mediated amyloidosis with cardiomyopathy. *Journal of Cardiac Failure*. 2023;29:550. DOI: 10.1016/j.cardfail.2022.10.013
- Ioannou A, Fontana M, Gillmore JD. RNA targeting and gene editing strategies for transthyretin amyloidosis. *BioDrugs*. 2023;37:127–42. DOI: 10.1007/s40259-023-00577-7
- Merlini G, Lousada I, Ando Y, et al. Rationale, application and clinical qualification for NT-proBNP as a surrogate end point in pivotal clinical trials in patients with AL amyloidosis. *Leukemia*. 2016;30:1979–86. DOI: 10.1038/leu.2016.191
- Erdin M, Passino C, Prontera C, et al. Cardiac natriuretic hormones, neuro-hormones, thyroid hormones and cytokines in normal subjects and patients with heart failure. *Clin Chem Lab Med*. 2004;42:627–36. DOI: 10.1151/CCML.2004.108
- Banyersad SM, Sado DM, Flett AS, et al. Quantification of myocardial extracellular volume fraction in systemic AL amyloidosis: An equilibrium contrast cardiovascular magnetic resonance study. *Circ Cardiovasc Imaging*. 2013;6:34–9. DOI: 10.1161/CIRCIMAGING.112.978627
- Passino C, Aimo A, Masotti S, et al. Cardiac troponins as biomarkers for cardiac disease. *Biomark Med*. 2019;13:325–30. DOI: 10.2217/bmm-2019-0039

50. Dispenzieri A, Gertz MA, Kumar SK, et al. High sensitivity cardiac troponin T in patients with immunoglobulin light chain amyloidosis. *Heart*. 2014;100:383–8. DOI: 10.1136/heartjnl-2013-304957
51. Chacko L, Karia N, Venneri L, et al. Progression of echocardiographic parameters and prognosis in transthyretin cardiac amyloidosis. *Eur J Heart Fail*. 2022;24:1700–12. DOI: 10.1002/ejhf.2606
52. Dey D, Slomka PJ, Leeson P, et al. Artificial intelligence in cardiovascular imaging. *J Am Coll Cardiol*. 2019;73:1317–35. DOI: 10.1016/j.jacc.2018.12.054
53. Tromp J, Seekings PJ, Hung C-L, et al. Automated interpretation of systolic and diastolic function on the echocardiogram: A multicohort study. *Lancet Digit Health*. 2022;4:e46–54. DOI: 10.1016/S2589-7500(21)00235-1
54. Howard JP, Francis DP. Machine learning with convolutional neural networks for clinical cardiologists. *Heart*. 2021;108:973–81. DOI: 10.1136/heartjnl-2020-318686
55. Fontana M, Banyersad SM, Treibel TA, et al. Native T1 mapping in transthyretin amyloidosis. *JACC Cardiovasc Imaging*. 2014;7:157–65. DOI: 10.1016/j.jcmg.2013.10.008
56. Karamitsos TD, Piechnik SK, Banyersad SM, et al. Noncontrast T1 mapping for the diagnosis of cardiac amyloidosis. *JACC Cardiovasc Imaging*. 2013;6:488–97. DOI: 10.1016/j.jcmg.2012.11.013
57. Ioannou A, Patel RK, Martinez-Naharro A, et al. Tracking Multiorgan treatment response in systemic AL-Amyloidosis with cardiac magnetic resonance derived extracellular volume mapping. *JACC Cardiovascular imaging*. 2023;S1936-878X(23)00116-X. DOI: 10.1016/j.jcmg.2023.02.019
58. Dorbala S, Vangala D, Semer J, et al. Imaging cardiac amyloidosis: A pilot study using ¹⁸F-florbetapir positron emission tomography. *Eur J Nucl Med Mol Imaging*. 2014;41:1652–62. DOI: 10.1007/s00259-014-2787-6
59. Dietemann S, Nkoulou R. Amyloid PET imaging in cardiac amyloidosis: A pilot study using ¹⁸F-flutemetamol positron emission tomography. *Ann Nucl Med*. 2019;33:624–8. DOI: 10.1007/s12149-019-01372-7
60. Antoni G, Lubberink M, Estrada S, et al. In vivo visualization of amyloid deposits in the heart with 11C-PIB and PET. *J Nucl Med*. 2013;54:213–20. DOI: 10.2967/jnumed.111.102053
61. Genovesi D, Vergaro G, Giorgetti A, et al. [¹⁸F]-florbetaben PET/CT for differential diagnosis among cardiac immunoglobulin light chain, transthyretin amyloidosis, and mimicking conditions. *JACC Cardiovasc Imaging*. 2021;14:246–55. DOI: 10.1016/j.jcmg.2020.05.031
62. Kircher M, Ihne S, Brumberg J, et al. Detection of cardiac amyloidosis with ¹⁸F-florbetaben-PET/CT in comparison to echocardiography, cardiac MRI and DPD-scintigraphy. *Eur J Nucl Med Mol Imaging*. 2019;46:1407–16. DOI: 10.1007/s00259-019-04290-y
63. Lee SP, Suh HY, Park S, et al. Pittsburgh B compound positron emission tomography in patients with AL cardiac amyloidosis. *J Am Coll Cardiol*. 2020;75:380–90. DOI: 10.1016/j.jacc.2019.11.037
64. Kim YJ, Ha S, Kim Y-I. Cardiac amyloidosis imaging with amyloid positron emission tomography: A systematic review and meta-analysis. *J Nucl Cardiol*. 2020;27:123–32. DOI: 10.1007/s12350-018-1365-x
65. Sousa JC, Marques F, Dias-Ferreira E, et al. Transthyretin influences spatial reference memory. *Neurobiol Learn Mem*. 2007;88:381–5. DOI: 10.1016/j.nlm.2007.07.006
66. Brouillette J, Quirion R. Transthyretin: A key gene involved in the maintenance of memory capacities during aging. *Neurobiol Aging*. 2008;29:1721–32. DOI: 10.1016/j.neurobiolaging.2007.04.007
67. Schwarzman AL, Gregori L, Vitek MP, et al. Transthyretin sequesters amyloid beta protein and prevents amyloid formation. *Proc Natl Acad Sci U S A*. 1994;91:8368–72. DOI: 10.1073/pnas.91.18.8368
68. Stein TD, Johnson JA. Lack of neurodegeneration in transgenic mice overexpressing mutant amyloid precursor protein is associated with increased levels of transthyretin and the activation of cell survival pathways. *J Neurosci*. 2002;22:7380–8. DOI: 10.1523/JNEUROSCI.22-17-07380.2002
69. Stein TD, Anders NJ, DeCarli C, et al. Neutralization of transthyretin reverses the neuroprotective effects of secreted amyloid precursor protein (APP) in APPSW mice resulting in tau phosphorylation and loss of hippocampal neurons: Support for the amyloid hypothesis. *J Neurosci*. 2004;24:7707–17. DOI: 10.1523/JNEUROSCI.2211-04.2004
70. Santos SD, Lambertsen KL, Clausen BH, et al. CSF transthyretin neuroprotection in a mouse model of brain ischemia. *J Neurochem*. 2010;115:1434–44. DOI: 10.1111/j.1471-4159.2010.07047.x
71. Gomes JR, Nogueira RS, Vieira M, et al. Transthyretin provides trophic support via megalin by promoting neurite outgrowth and neuroprotection in cerebral ischemia. *Cell Death Differ*. 2016;23:1749–64. DOI: 10.1038/cdd.2016.64
72. Gao C, Zhang B, Zhang W, et al. Serum prealbumin (transthyretin) predict good outcome in young patients with cerebral infarction. *Clin Exp Med*. 2011;11:49–54. DOI: 10.1007/s10238-010-0103-8
73. Luigetti M, Servidei S. Patisiran in hereditary transthyretin-mediated amyloidosis. *Lancet Neurol*. 2021;20:21–3. DOI: 10.1016/S1474-4422(20)30397-5
74. Adams D, Tournev IL, Taylor MS, et al. Efficacy and safety of vutrisiran for patients with hereditary transthyretin-mediated amyloidosis with polyneuropathy: A randomized clinical trial. *Amyloid*. 2022;30:1–9. DOI: 10.1080/13506129.2022.2091985
75. Kearn SJ. Vutrisiran: First approval. *Drugs*. 2022;82:1419–25. DOI: 10.1007/s40265-022-01765-5
76. ClinicalTrials.gov. HELIOS-B: A Study to Evaluate Vutrisiran in Patients With Transthyretin Amyloidosis With Cardiomyopathy. ClinicalTrials.gov Identifier: NCT04153149. Available at: www.clinicaltrials.gov/ct2/show/NCT04153149 (Date last accessed: 12 September 2022).