

## Intra-articular apatite crystal deposition

H. RALPH SCHUMACHER,<sup>1</sup> P. VERGHESE CHERIAN,<sup>1</sup> ANTONIO J. REGINATO,<sup>1</sup> THOMAS BARDIN,<sup>2</sup> SUSAN ROTHFUSS<sup>1</sup>

From the <sup>1</sup>University of Pennsylvania School of Medicine, Philadelphia, USA and <sup>2</sup>Clinique Rheumatologique, Hospital Lariboisière, Paris, France

### Introduction

The role of apatite crystals in calcific peri-arthritis is well recognised.<sup>1-5</sup> For many years, however, intra-articular apatites were not thought to play any part in joint disease. They were identified in only a small percentage of menisci examined grossly and by x-ray diffraction by McCarty *et al.* in 1966.<sup>6</sup> In 1975-7 we<sup>7,8</sup> and Dieppe *et al.*<sup>9</sup> using electron microscopy and elemental analysis on joint fluids found apatite crystals in various situations including acute otherwise unexplained arthritis. We review our findings since that time.

### Methods for crystal identification

Techniques used to identify apatite crystals in synovial fluids have varied in different series and may affect the importance of the findings. Sensitivity

and specificity of most techniques have not been fully defined. Regular light microscopy may allow visualisation of larger clumps of apatite crystals as glossy, slightly irregular globules from 2-10  $\mu\text{m}$  in diameter (Fig. 1). Only a few of such aggregates are birefringent.<sup>8</sup> Stains for calcium and phosphorus such as Von Kossa's and alizarin red stains can help further identify these globules.<sup>9</sup> We have examined the sensitivity of the alizarin red stain and find that it can detect 0.005  $\mu\text{g}$  of synthetic apatite in 1 ml of synovial fluid.<sup>9</sup> The technique is still not totally specific and is used only as a screening test.

Scanning electron microscopy (SEM) can also identify clumps of the same shape<sup>10</sup> and allows electron probe elemental analysis, which shows not only whether calcium and phosphorus are present but also whether their approximate ratios are

close to the 1.67:1 expected with well crystallised apatite.

Transmission electron microscopy allows identification of the tiny thin 50-250 $\text{\AA}$  diameter needles within the clumps that are typical of apatite.<sup>8</sup> This technique may be used on small amounts of fluid and also on either thin sections or synovial fluid dried onto formvar coated grids.<sup>11</sup> Used on synovial fluid the technique detects down to at least 0.002 mg/ml of apatite and avoids possible artefacts of chemical fixation. Examination of thin sections also allows demonstration of whether and by which cells crystal clumps are phagocytised. This may obviously be important for the pathogenic significance of the apatite. Elements may also be analysed as with SEM. Electron diffraction patterns can also be made for comparison with known standards, but the problems and value of this have not yet been worked out.

When large amounts of suspected apatite are present x-ray diffraction is generally accepted as the definitive method of analysis, although small amounts of certain crystals may be missed when mixed with other predominant crystals. A semi-quantitative screening technique for apatite using <sup>14</sup>C disodium etidronate binding is also being studied.<sup>12</sup> Intracellular crystals might be missed with this method. Infrared spectrophotometry has been used to supplement findings with other techniques<sup>10</sup> and with the use of Fournier transform may allow detection of small amounts of crystals mixed in with other predominant ones.

### Apatite in joints

Apatite has been described in knees, shoulders, hips, wrists, first carpometacarpal joints, metacarpophalangeal, proximal and distal interphalangeal joints, and

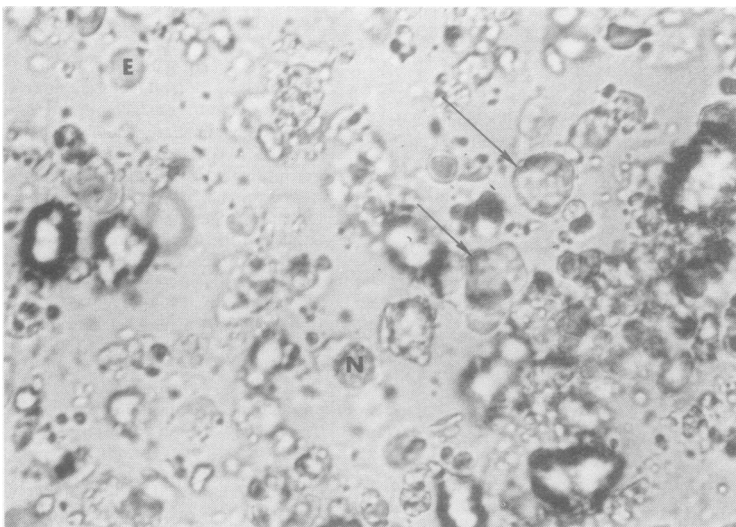


Fig. 1 Light microscopical view of irregular clumps of apatite crystals (arrows) in synovial fluid. Note erythrocytes (E) and neutrophils (N) for size comparison.

metatarsophalangeal joints including the 1st.<sup>5,9,13</sup> We have studied a total of 104 patients in whom apatite was found by transmission electron microscopy and find a similar distribution of joints containing these crystals. Cases reported have generally been from studies of specific diseases or selected by referral so the incidence of identifiable apatite in the general population remains unclear.

Women seem to be affected more often than men,<sup>5,9</sup> and we know of no reports in children except in association with collagen disease. Our study included 58 women and 46 men; there was a high incidence of elderly patients because we included 44 patients from a study of osteoarthritis, the youngest patient was 36 years old.

#### CLINICAL PRESENTATIONS

Otherwise unexplained acute inflammatory arthritis with joint effusions containing apatite has been reported by Fam *et al.*, Dieppe *et al.*, and our group at knees, wrists, hips, proximal interphalangeal joints, metacarpophalangeal joints, and first metatarsophalangeal joints<sup>5,9</sup> and may well occasionally occur at any joints where crystals can deposit. Some patients have had multiple attacks and have also occasionally had calcific peri-arthritis. Attacks may resolve without treatment; some progress to chronic erosive arthritis.<sup>13</sup> Synovial fluid leucocyte counts in clinically acutely inflamed joints have ranged from  $1.8-84 \times 10^9/l$ .<sup>5,9</sup> Neutrophils have ranged from 27% to 90% with a predominance in acute cases. Crystals may be seen to be phagocytised by synovial fluid neutrophils and mononuclear cells (Fig. 2).<sup>8</sup>

Most recent studies have also identified apatite crystals in some joint effusions without any dramatic evidence of inflammation.<sup>9,10,14,15</sup> Many such joints have had osteoarthritis, but the real incidence of apatite deposition in osteoarthritis and how often it occurs early in still grossly normal cartilage is not yet known. We found apatite in 44 of 100 osteoarthritic effusions after examining just one grid on each by transmission EM.<sup>15</sup> Dieppe *et al.* found apatite in 9 out of 34 unselected osteoarthritic fluids with scanning electron microscopy (SEM).<sup>16</sup> Using

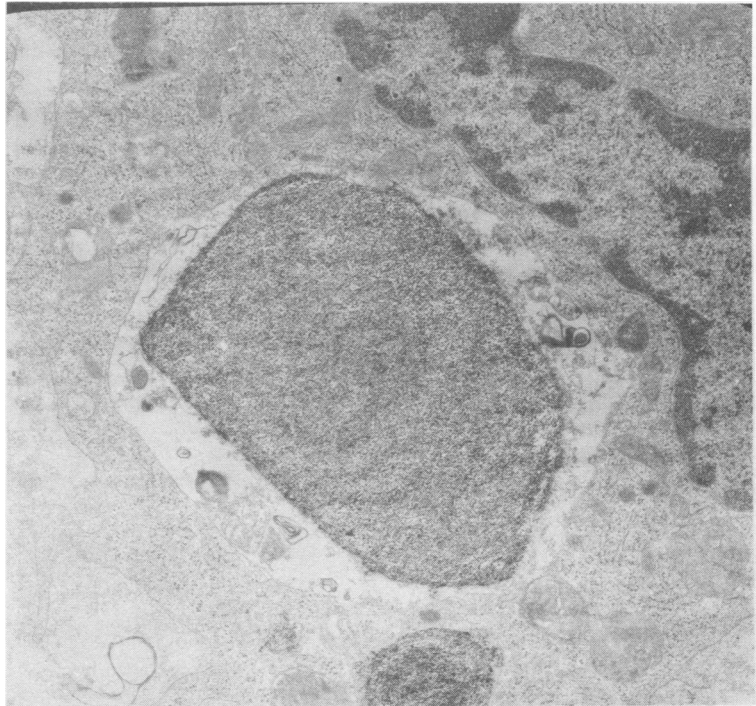


Fig. 2 A clump of tiny crystals proved to be apatite by elemental analysis lie in a vacuole of a synovial fluid mononuclear cell. Electron micrograph  $\times 20\ 000$  (original magnification).

TEM Ali found apatite more often in osteoarthritic than other cartilages but did not describe incidence.<sup>17</sup> Even in osteoarthritis with 'non-inflammatory' joint effusions apatite has been phagocytised by synovial lining cells that might release proteases and collagenase and be a major factor in progressive joint damage.<sup>13,18</sup>

#### RADIOGRAPHIC FINDINGS

Joints with acute or subacute apatite-associated arthritis may show calcification in the synovial space (Fig. 3).<sup>8</sup> The linear cartilage or meniscal calcification seen with CPPD is not expected. Some x-ray films show no calcification despite later demonstration of large amounts of apatite. In fact, only 21 of our 104 patients had obvious x-ray evidence of calcification. Patients may also have periarticular calcifications at the symptomatic site or elsewhere. Erosive arthritis may develop<sup>13,18</sup> and changes of osteoarthritis may be present.<sup>14,15</sup>

In patients with clinical osteoarthritis the severity of radiographic changes of osteoarthritis tends to correlate with the incidence of apatite deposition.

#### Apatite associated with other diseases

Apatite crystals have been found in a high percentage of specimens of synovial fluid or cartilage from patients known also to have CPPD deposition.<sup>14,20-22</sup> Either or both crystals may be phagocytosed; in our still limited experience CPPD seems more often to be intracellular.

Other diseases that have been associated with clinically significant apatite arthritis include scleroderma, dermatomyositis, and systemic lupus erythematosus<sup>23-25</sup>; renal failure treated by haemodialysis;<sup>9,19</sup> and possibly high dose vitamin D treatment.<sup>26</sup> Apatite also occurs in other joint diseases, presumably as a secondary complication. We found apatite in 8 out of 32 effusions from joints with

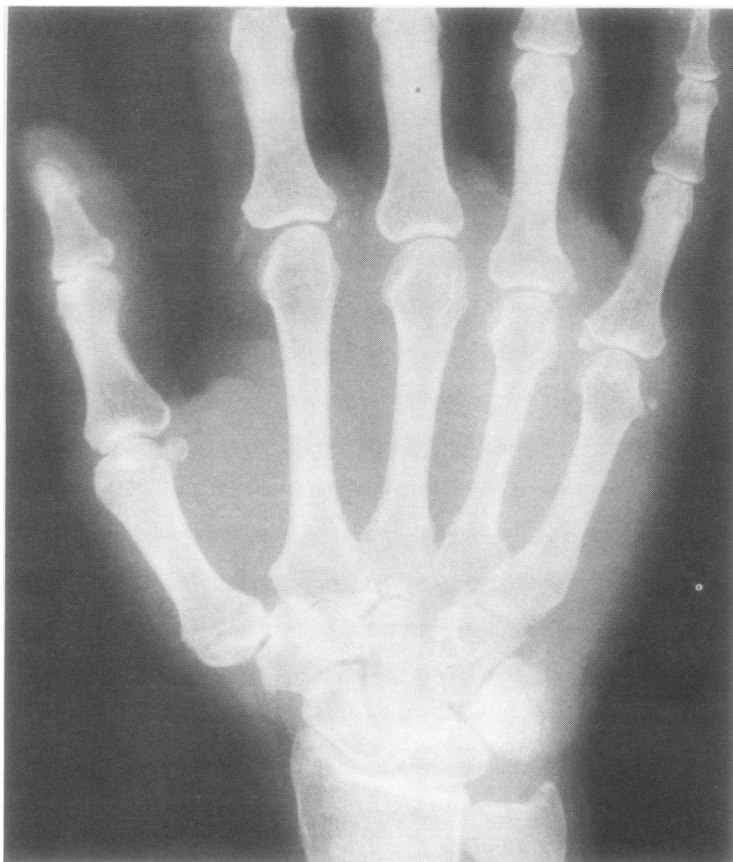

Fig. 3 X-ray films of hand, showing apatite deposits best in the joint space of the fifth metacarpophalangeal joint and the capsule of the second metacarpophalangeal joint. This patient had a history of recurrent acute arthritis that evolved into erosive arthritis.

rheumatoid arthritis; the crystals correlated with the severity of secondary osteoarthritis.<sup>27</sup> In certain cases acute dramatic inflammation in a single joint may be induced by crystals

rather than by the underlying rheumatoid arthritis. Table 1 shows diagnoses other than osteoarthritis in our 104 patients with apatite deposition.

Table 1 Associated diseases other than osteoarthritis in 104 patients with intra-articular apatite crystals

Diseases	No of patients
Dermatomyositis, scleroderma	6
Renal failure on dialysis	10
Oxalate deposition	1
Hypothyroidism	3
Haemochromatosis	3
Osteochondromatosis	1
Acromegaly	2
CPPD deposition	22
Gout	5
Rheumatoid or psoriatic arthritis	10
Temporal arteritis with aseptic necrosis	1

### Characteristics of crystals

It is impressive that there is tremendous morphological variation among apparent apatites we have found in joints. Crystals may be almost punctate, (Fig. 2), rods or thicker 'boat-like' structures, (Fig. 4) or long needles (Fig. 5); they may be densely or loosely packed, and larger crystals may have the suggestion of an internal structure at high magnification. Crystals may be rare or profuse enough to make the fluid milky. Rare clumps may obviously have different clinical significance than massive amounts. Crystals are frequently phagocytosed (Fig. 6) but seem most often to be ingested by mononuclear cells rather than polymorphonuclear neutrophils. Elemental analysis also shows some variation with some apparent apatite having Ca:P ratios well below the expected 1.67:1, suggesting the presence of some amorphous or poorly crystallised salts. Substitution of chloride and carbonate in apatite also varies. As yet we know of no good correlation of elemental analysis findings with crystal morphology.

Apatite was most often detected in synovial fluid because of its accessibility and from knees rather than other joints for the same reason. Arms, including finger joints, wrists, elbows, and shoulders seemed involved more often than the legs in patients with collagen-vascular disease or those undergoing renal dialysis. Apatite was seen in surgical specimens of cartilage either as round clumps near to chondrocytes (but not clearly in matrix vesicles) or as irregular masses on the surface or in the interstitium. Apatite in synovium was frequently phagocytosed or engulfed by synovial cell processes.

### Mechanisms involved in apatite deposition disease

The ability of apatite to induce acute inflammation in joints has been shown by intra-articular injection into the knees of dogs using the same model as that used for urate and CPPD crystals.<sup>8</sup> Apatite has also produced inflammation at other sites—for example, the pleural space and subcutaneous tissue<sup>10</sup>—after experimental injection. Apatite is not

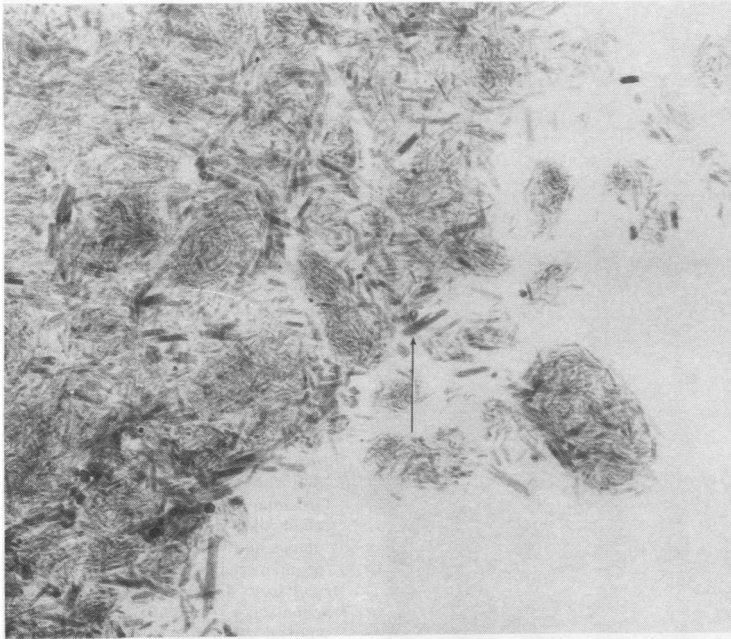


Fig. 4 Rod and 'boat-like' apatite crystals. Some foamy internal structure can be seen at high magnification. Electron micrograph  $\times 125\ 000$  (original magnification).



Fig. 5 Long needle-like apatite crystals from joint fluid stained with ferritin conjugated antibody to IgG demonstrating binding of this immunoglobulin labelled by ferritin particles (arrows) to clump. Electron micrograph  $\times 80\ 000$  (original magnification).

always associated with detectable inflammation (the same is true of urate and CPPD<sup>28, 29</sup>) and the reasons for this require study.

In TEM sections finely granular material is generally associated with the synovial fluid crystals (Fig. 6)<sup>8</sup> and

with most clumps of crystals embedded in synovium or superficial cartilage. Preliminary immunoelectron microscopical studies in our laboratory show that immunoglobulins are at least one component of this granular material (Fig. 5). The

possibility that other materials, including fibronectin, osteonectin enzymes, and complement, are present should also be considered. As previously suggested with urate crystals,<sup>28</sup> substances adhering to crystals could encourage or inhibit inflammation. Effects could even vary depending on other cellular and humoral aspects of the joint. Complement may be activated by apatite as well as by other crystals.<sup>30</sup>

Apatite almost certainly appears in joints by different mechanisms. In some cases (as with CPPD) it is thought to be a result of degenerative changes in cartilage and to deposit first in cartilage.<sup>17</sup> In other examples, especially when associated with migratory calcific periarthritis at other sites, it probably deposits outside cartilage due to the still unknown systemic factors that seem to cause most such calcific periarthritis. Phosphate excess or other features of renal failure and haemodialysis seem to contribute to some cases.<sup>19</sup> Serum and synovial fluid calcium and phosphate concentrations have been normal in most cases. Occasionally apatite is seen to have risen from fragments of bone released into severely destroyed joints.

Apatite deposition in articular cartilage occurs spontaneously in aging rabbits or after administration of vitamin D; synovial calcification with apatite can be induced by intra-articular calciphylaxis.<sup>31</sup> In neither of these established types of experimental apatite calcification has acute inflammation occurred. Long term studies are still needed to determine if osteoarthritis evolves or if various modifications can produce attacks of acute arthritis.

#### Treatment

Acute inflammation associated with apatite deposition generally seems to respond to treatment with indomethacin, other non-steroidal agents, or colchicine.<sup>8</sup> Aspirin has been ineffective in some cases. Intra-articular depot corticosteroids have also appeared to be helpful.<sup>8</sup> We have no personal experience with measures to prevent or decrease apatite deposition. Disodium etidronate has been reported to decrease calcinosis but with chronic use may also effect bone mineralisation.<sup>32</sup> In patients with

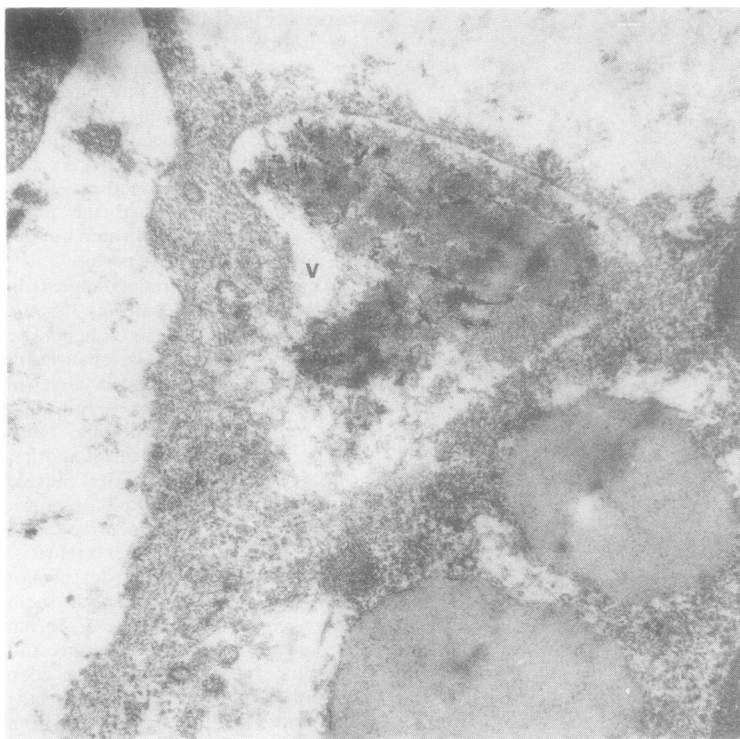


Fig. 6 Apatite crystals embedded in electron dense material in a vacuole of a synovial fluid mononuclear cell. Electron micrograph  $\times 32\ 000$  (original magnification).

abnormal calcium or phosphorus metabolism as, for example, occurs in many of those with renal failure, better control of phosphorus concentrations may decrease apatite deposits. Some calcinosis in or around joints has also been reported to resolve spontaneously. In one patient of ours with a scleroderma-like disease apatite deposits in finger joints resolved when joints gradually stiffened with progressive skin disease.<sup>23</sup> Indomethacin was thought to decrease para-articular ectopic ossification in three cases after total hip arthroplasty.<sup>33</sup> Neither this nor other possible ways of decreasing calcinosis have been adequately and systematically evaluated.

#### Other calcium-containing crystals

Other calcium-containing crystals have been described in intra-articular sites. Brushite ( $\text{CaHPO}_4 \cdot 2\text{H}_2\text{O}$ ) has been reported in small amounts of uncertain clinical importance and

usually in association with CPPD.<sup>34,35</sup> Whitlockite and octacalcium phosphate may also occur in diseased joints along with apatite.<sup>36</sup>

Recently, we have found calcium oxalate crystals in synovial effusions in three patients undergoing haemodialysis for chronic renal failure.<sup>37</sup> In one patient x-ray films showed finger calcifications similar to those seen with apatite and knee chondrocalcinosis like that seen with CPPD deposition. Detailed analyses at necropsy revealed massive oxalate deposits and no CPPD. The list of crystals identifiable in joints is almost certainly not yet complete. We and others have seen other unidentified birefringent or electron dense material that is still under evaluation.

Supported in part by grants from the Veterans Administration, National Institutes of Health (1-R21-AG 02815-01), McCabe Foundation, and Barsumian Fund.

We thank Miss Gilda Clayburne, Miss Marie Sieck, and Mrs Susan Rothfuss for excellent technical help on the work from

our laboratory and appreciate the careful typing of Miss Mary Ellen Maguire.

#### References

- 1 Codman E A. *The shoulder*. Boston: Thomas Todd, 1934.
- 2 Pinals R S, Short C L. Calcific periarthritis involving multiple sites. *Arthritis Rheum* 1966; **9**: 566-74.
- 3 McCarty D J, Gatter R A. Recurrent acute inflammation associated with focal apatite crystal deposition. *Arthritis Rheum* 1966; **9**: 804-19.
- 4 Amor B, Cherot A, Delbarre F. Le rhumatisme a hydroxyapatite. *Rev Rhum Mal Osteoartic* 1977; **44**: 301-8.
- 5 Fam A G, Pritzker K P H, Stein J L, Houpt J B, Little A H. Apatite associated arthropathy: a clinical study of 14 cases and 2 patients with calcific bursitis. *J Rheumatol* 1979; **6**: 461-71.
- 6 McCarty D J, Hogan J M, Gatter R A, Grossman M. Studies on pathological calcifications in human cartilage. I. Prevalence and types of crystal deposits in the menisci of 215 cadavers. *J Bone Joint Surg [Am]* 1966; **48**: 309-25.
- 7 Schumacher H R. Pathology of the synovial membrane in gout. Light and electron microscopic studies. Interpretation of crystals in electron micrographs. *Arthritis Rheum* 1975; **18**: 771-82.
- 8 Schumacher H R, Somlyo A P, Tse R L, Maurer K. Arthritis associated with apatite crystals. *Ann Intern Med* 1977; **87**: 411-6.
- 9 Paul H, Reginato A J, Schumacher H R. Alizarin red S-staining as a screening test to detect calcium compounds in synovial fluid. *Arthritis Rheum* (in press).
- 10 Dieppe P A, Crocker P, Huskisson E C, Willoughby D A. Apatite deposition disease. A new arthropathy. *Lancet* 1976; **i**: 266-9.
- 11 Paul H, Reginato A J, Schumacher H R. Morphological characteristics of monosodium urate: a transmission electron microscopic study of intact natural and synthetic crystals. *Ann Rheum Dis* (in press).
- 12 Halverson P B, McCarty D J. Identification of hydroxyapatite crystals in synovial fluid. *Arthritis Rheum* 1979; **22**: 389-95.
- 13 Schumacher H R, Miller J L, Ludvico C, Jessar R A. Erosive arthritis associated with apatite crystal deposition. *Arthritis Rheum* 1981; **24**: 31-7.
- 14 Schumacher H R, Gibilisco P, Reginato A J, Cherian V, Gordon G V. Implications of crystal deposition in osteoarthritis. *J Rheumatol* (in press).
- 15 Schumacher H R, Gordon G, Paul H, Reginato A, Villanueva T, Cherian V, Gibilisco P. Osteoarthritis, crystal deposition and inflammation. *Semin Arthritis Rheum* 1981; **11**: 116-9.

- 16 Dieppe P A, Crocker P R, Corke C F, Doyle D V, Huskisson E C, Willoughby D A. Synovial fluid crystals. *Q J Med* 1979; **48**: 533-53.
- 17 Ali S Y. Matrix vesicles and apatite nodules in arthritic cartilage. In: Willoughby D A, Giroud J P, Velo G P, eds. *Perspectives in inflammation*. Baltimore, MD: University Park Press, 1977: 211-23.
- 18 Halverson P B, Cheung H S, McCarty D J, Garancis J C, Mandel N. "Milwaukee Shoulder". Association of microspheroids containing hydroxyapatite crystals, active collagenase and neutral protease with rotator cuff defects. II. Synovial fluid studies. *Arthritis Rheum* 1981; **24**: 474-83.
- 19 Moskowitz R W, Vertes V, Schwartz A, Marshall G, Friedman B. Crystal induced inflammation associated with chronic renal failure and hemodialysis. *Am J Med* 1969; **47**: 450-60.
- 20 Doyle D V, Dieppe P A, Crocker P R, Ibe K, Willoughby D A. Mixed crystal deposition in an osteoarthritic joint. *J Pathol* 1977; **123**: 1-4.
- 21 Schumacher H R. Articular cartilage in the degenerative arthropathy of hemochromatosis. *Arthritis Rheum* (in press).
- 22 Martel W, McCarter D K, Solsky M A, et al. Further observations on the arthropathy of calcium pyrophosphate crystal deposition disease. *Radiology* 1981; **141**: 1-15.
- 23 Reginato A, Schumacher H R. Synovial calcification in a patient with collagen vascular disease: light and electron microscopic studies. *J Rheumatol* 1977; **4**: 261-7.
- 24 Brandt K D, Krey P R. Chalky joint effusion. The result of massive synovial deposition of calcium apatite in progressive systemic sclerosis. *Arthritis Rheum* 1977; **20**: 792-6.
- 25 Schumacher H R, Schimmer B, Gordon G V, et al. Articular manifestations of polymyositis and dermatomyositis. *Am J Med* 1979; **67**: 287-92.
- 26 Kieff E D, McCarty D J. Hypertrophic pulmonary osteoarthropathy with arthritis and synovial calcification in a patient with alcoholic cirrhosis. *Arthritis Rheum* 1969; **12**: 261-71.
- 27 Reginato A J, Paul H, Schumacher H R. Hydroxyapatite crystals in rheumatoid arthritis synovial fluid. *Clinical Research* 1982; **30**: 662A.
- 28 Agudelo C A, Weinberger A, Schumacher H R, Turner R, Molina J. Definitive diagnosis of gout by identification of urate crystals in asymptomatic metatarsophalangeal joints. *Arthritis Rheum* 1979; **22**: 559-60.
- 29 Schumacher H R. Pathogenesis of crystal-induced arthritis. *Clinics in Rheumatic Diseases* 1977; **3**: 105-31.
- 30 Hasselbacher P. C3 activation by monosodium urate monohydrate and other crystalline material. *Arthritis Rheum* 1979; **22**: 571-8.
- 31 Reginato A J, Schumacher H R, Brighton C T. Experimental hydroxyapatite synovial and articular cartilage calcification. Light and electron microscopic studies. *Arthritis Rheum* (in press).
- 32 Weinstein R S. Focal mineralization defect during disodium etidronate treatment of calcinosis. *Calif Tissue Int* 1982; **34**: 224-8.
- 33 Ritter M A, Gioe T J. The effect of indomethacin on para-articular ectopic ossification following total hip arthroplasty. *Clin Orthop* 1982; **167**: 113-7.
- 34 Moskowitz R W, Harris B K, Schwartz A, et al. Chronic synovitis as a manifestation of calcium crystal deposition disease. *Arthritis Rheum* 1971; **14**: 109-16.
- 35 Gaucher A, Faure G, Netter P, et al. Identification des cristaux observes dans les arthropathies destructrices de la chondrocalcinose. *Rev Rhum Mal Osteoartic* 1977; **44**: 407-14.
- 36 McCarty D J, Lehr J R, Halverson P B. Crystal populations in human synovial fluid. Identification of apatite, octacalcium phosphate and tricalcium phosphate [Abstract]. *Clinical Research* 1982; **30**: 807.
- 37 Hoffman G, Schumacher H R, Paul H, et al. Calcium oxalate microcrystalline associated arthritis in end stage renal disease. *Ann Intern Med* 1982; **97**: 36-42.