

# Demodex Blepharitis: A Comprehensive Review of the Disease, Current Management, and Emerging Therapies

Michelle K. Rhee, M.D., Elizabeth Yeu, M.D., Melissa Barnett, O.D., FAAO, FSLs, FBCLA, Christopher J. Rapuano, M.D., Deepinder K. Dhaliwal, M.D., Kelly K. Nichols, O.D., M.P.H., Ph.D., Paul Karpecki, O.D., Francis S. Mah, M.D., Arthur Chan, Ph.D., James Mun, Ph.D., and Ian Benjamin Gaddie, O.D.

**Abstract:** *Demodex* blepharitis is a common disease of the eyelid, affecting approximately 25 million Americans. This article reviews what is known about the mechanisms and impact of *Demodex* blepharitis, risk factors, signs and symptoms, diagnostic techniques, current management options, and emerging treatments. *Demodex* mites contribute to blepharitis in several ways: direct mechanical damage, as a vector for bacteria, and by inducing hypersensitivity and inflammation. Risk factors for *Demodex* blepharitis include increasing age, rosacea, and diabetes. The costs, symptom burden, and psychosocial effects of *Demodex* blepharitis are considerable. The presence of collarettes is pathognomonic for *Demodex* blepharitis. Redness, dryness, discomfort, foreign body sensation, lash anomalies, and itching are also hallmarks of the disease. Although a number of oral, topical, eyelid hygiene and device-based options have been used clinically and evaluated in studies for the management of *Demodex* blepharitis, none have been FDA approved to treat the disease. Recent randomized controlled clinical trials suggest that lotilaner ophthalmic solution, 0.25%, is a topical treatment with the potential to eradicate *Demodex* mites and eliminate collarettes and eyelid redness for an extended period.

**Key Words:** Demodex—Blepharitis—Ocular surface disease.

(*Eye & Contact Lens* 2023;49: 311–318)

From the Department of Ophthalmology (M.K.R.), Icahn School of Medicine, Mt. Sinai, NY; Virginia Eye Consultants (E.Y.), Norfolk, VA; University of California (M.B.), Davis Eye Center, Sacramento, CA; Sidney Kimmel Medical College at Thomas Jefferson University (C.J.R.), Philadelphia, PA; University of Pittsburgh School of Medicine (D.K.D.), Pittsburgh, PA; University of Alabama at Birmingham School of Optometry (K.K.N.), Birmingham, AL; Kentucky College of Optometry (P.K.), University of Pikeville, Pikeville, KY; Kentucky Eye Institute (P.K.), Lexington, KY; Scripps Clinic Medical Group (F.S.M.), La Jolla, CA; Tarsus Pharmaceuticals (A.C., J.M.), Irvine, CA; and Gaddie Eye Centers (I.B.G.), Louisville, KY.

M. Barnett, D. K. Dhaliwal, I. B. Gaddie, P. Karpecki, K. K. Nichols, C. J. Rapuano, and E. Yeu are consultants for Tarsus Pharmaceuticals. P. Karpecki is also a consultant for Azura, BioTissue, Bruder, Oasis Medical, OCuSOFT, Scope, and Thea. K. K. Nichols is also a consultant for Bruder and Thea. A. Chan, P. Karpecki, J. Mun, and E. Yeu have equity interests in Tarsus Pharmaceuticals. A. Chan and J. Mun are employees of Tarsus Pharmaceuticals. F. S. Mah and M. K. Rhee report no conflicts of interest related to the content of this article.

Address correspondence to Elizabeth Yeu, M.D., Virginia Eye Consultants, 241 Corporate Boulevard, Suite 210, Norfolk, VA 23502; e-mail: eyeulin@gmail.com

Accepted April 11, 2023.

Copyright © 2023 The Author(s). Published by Wolters Kluwer Health, Inc. on behalf of the CLAO. This is an open access article distributed under the terms of the Creative Commons Attribution-Non Commercial-No Derivatives License 4.0 (CCBY-NC-ND), where it is permissible to download and share the work provided it is properly cited. The work cannot be changed in any way or used commercially without permission from the journal.

DOI: 10.1097/ICL.0000000000001003

Blepharitis is a chronic inflammation of the eyelid margin characterized by erythema, ocular irritation and discomfort, discharge and debris on the eyelids and lashes, and eyelash anomalies.<sup>1,2</sup> In more advanced stages, there may be corneal involvement, such as punctate epithelial erosions, infiltrates, epithelial defects, or keratitis.

Although blepharitis can have various etiologies, including allergic, staphylococcal, and seborrheic, one of the most common etiologies is *Demodex* mite infestation.<sup>3,4</sup> The presence of *Demodex* mites in eyelid tissue was first reported in 1876, and its association with blepharitis was established in 1967, but the number of published articles on *Demodex* blepharitis has increased dramatically in the past 5 years.<sup>5</sup>

This literature review presents the available evidence and knowledge about *Demodex* blepharitis. We review what is known about the epidemiology, mechanisms and impact of the disease, risk factors, signs and symptoms, diagnostic techniques, current management options, and emerging treatments.

## EPIDEMIOLOGY

It has long been accepted that the prevalence of *Demodex* increases with age, affecting more than 80% of those older than 60 years and 100% of those older than 70 years.<sup>6</sup> Among younger, university-based populations, *Demodex* prevalence has been reported as consistently low, between 2% and 27%.<sup>7–9</sup>

Researchers who have studied patient populations with clinical signs and symptoms of blepharitis find high rates of *Demodex* infestation, with prevalence ranging from 29% to 90%.<sup>4</sup> Most authors in the past 5 years report that *Demodex* blepharitis accounts for ≥60% of those with blepharitis.<sup>3,10–13</sup>

Recently, two studies independently reported similar rates of *Demodex* blepharitis among patients of all ages visiting US eye care clinics.<sup>14,15</sup> The Titan study, a multicenter retrospective chart review, found that 58% of 1,032 consecutive patients (and 69% of those with a blepharitis diagnosis) presented with collarettes—waxy, cylindrical debris at the base of the lashes that are the pathognomonic sign of *Demodex* blepharitis.<sup>14</sup> Similarly, Teo et al.<sup>15</sup> found that 55% of all patients and 62% of blepharitis patients examined in two tertiary care clinics presented with *Demodex* based on lash epilation.

*Demodex* blepharitis is equally prevalent in both sexes.<sup>10,14</sup> Among older Americans referred to a Veterans Administration (VA) Medical Center dry eye clinic, the rate of *Demodex* infestation was similar regardless of ethnicity, with 72% of white patients, 65% of black patients, and 69% of Hispanic patients affected.<sup>3</sup>

## MECHANISMS OF DISEASE

*Demodex* mites, the most common ectoparasite on humans, have been implicated in blepharitis. Two species, *Demodex folliculorum* and *Demodex brevis*, are found in human skin, especially the cheeks, nose, and eyelids. Both species are translucent, elongated microscopic mites with four pairs of short, clawed legs. *Demodex folliculorum* (Fig. 1) is approximately 0.3 to 0.4 mm in length and can be found in clusters around the lash root and lash follicle, where *D. folliculorum* feeds on sebum and follicular epithelial cells.<sup>16</sup> *Demodex brevis* is shorter, more solitary, and prefers sebaceous glands.<sup>16</sup> Although *Demodex* mites are found on healthy, asymptomatic individuals of all ages,<sup>10</sup> it has been suggested that the mites may play a pathogenic role at higher density, when the mites reach a state of demodicosis.<sup>16</sup>

*Demodex folliculorum* is believed to be more active and therefore more implicated in type 1 allergic reactions.<sup>17</sup> Researchers have surmised that male and female mites mate outside the follicles or glands, after which the female mites lay their eggs inside the hair follicles or sebaceous glands.<sup>18</sup>

*Demodex* mites secrete digestive enzymes onto nearby tissues to break down the epithelial cells to consume as food.<sup>16</sup> Although it has previously been reported that digested material is retained in the gut and spilled onto surrounding tissues at the end of the life cycle,<sup>17</sup> a recent microbiology report suggests that is not the case and that digested material may be excreted.<sup>19</sup> The full life cycle of a mite is estimated to be from 14 to 23 days, progressing from egg to larva to nymph and finally to the adult stage.<sup>18,20</sup>

There are several plausible mechanisms by which *Demodex* contribute to blepharitis, including direct damage, acting as a vector for bacteria, and inducing hypersensitivity and inflammation.<sup>17,21,22</sup>

### Direct Damage

As *Demodex* mites consume epithelial cells at the hair follicle, their sharp claws cause microabrasions, inducing epithelial hyperplasia.<sup>4,16,21</sup> The presence of *D. folliculorum* is strongly associated with hair follicle duct dilatation and hyperkeratinization and peri-

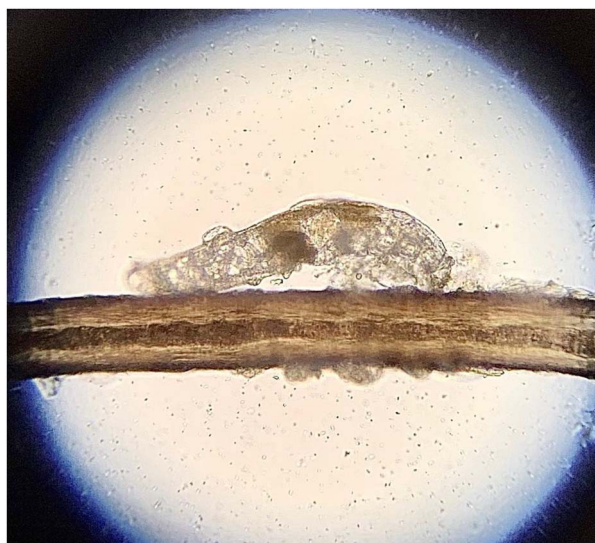

FIG. 1. *Demodex folliculorum* is found in human skin, especially the cheeks, nose, and eyelids. Image courtesy of Patrick Vollmer, OD.

follicular nongranulomatous inflammation.<sup>23</sup> Additionally, as the mites clump and lay their eggs at the base of the lashes, the follicles become distended.<sup>16</sup> Higher numbers of mites in the lash follicles are associated with reactive conjunctivitis and keratitis.<sup>24</sup> As *Demodex* infestation affects the structure of the hair follicles, lashes may be lost or become misdirected.<sup>17</sup>

Mites deposit debris consisting of digestive enzymes, epithelial cells, keratin, and eggs onto human host tissue. Proteases and lipases present in this debris may cause direct surface irritation and inflammation, a type 1 allergic response.<sup>16,17</sup>

*Demodex brevis* has been implicated in meibomian gland disease (MGD), including meibomian gland loss.<sup>4,25</sup> The build-up of decomposing mite remains, including their chitinous exoskeletons, is believed to contribute to physical blockage of the meibomian glands,<sup>4</sup> possibly leading to changes in gland architecture over time.<sup>4,25</sup> Changes in meibum secretion or lipid composition in MGD may promote the cycle by making the ocular environment more favorable for *Demodex*.<sup>4,26</sup>

### Bacterial Dysbiosis

The relationships among *Demodex* mites and the skin, gut, and ocular microbiota are complex. Historically, anterior blepharitis has often been believed to have a primarily bacterial origin. Eyelashes of patients with blepharitis have significantly higher microbial counts than healthy control subjects.<sup>13</sup> Fu et al.<sup>27</sup> recently reported that *Demodex* infestation may reduce the diversity of the microbiome in the conjunctival sac, thereby destabilizing it.

Bacterial biofilms have been implicated in blepharitis, and it has been proposed that lash deposits in blepharitis may be composed of these biofilms.<sup>28</sup> *Demodex* may also take advantage of the barrier defense “shield” provided by the biofilm to infiltrate the lash follicles and meibomian glands.<sup>29</sup> *Demodex* mites carry concomitant bacteria such as *Streptococcus* and *Staphylococcus* species on their surface, and *Bacillus oleronius* inside their abdomen, producing antigens and inducing an immune response.<sup>17,20–22</sup> In particular, studies have shown a positive correlation between *Staphylococcus epidermidis* and *Demodex* mite density.<sup>30</sup> The mites may act as a vector for other skin and environmental microbes when patients rub their eyes to relieve blepharitis-related itching and discomfort.<sup>30</sup>

### Delayed Hypersensitivity Response

In rosacea, *Demodex* proliferation seems to exist on a continuum, with mites triggering an inflammatory cascade, which then creates conditions for increasing mite proliferation and worsening disease.<sup>31</sup>

In *Demodex* blepharitis, digestive enzymes, chitin, and other mite byproducts may also trigger an inflammatory cascade by the toll-like receptor (TLR2) innate immunity pathway.<sup>11,16,18,21</sup> There is an increase in the number of CD4<sup>+</sup> T cells, macrophages, and Langerhans cells in patients with *Demodex*.<sup>16</sup> *Demodex* infestation is associated with upregulation of pro-inflammatory cytokines, particularly IL-1 $\beta$  and IL-17,<sup>17,18,24</sup> tear film alterations,<sup>24</sup> and upregulation of matrix metalloproteinase-9 (MMP-9).<sup>20</sup> Tarkowski et al.<sup>32</sup> hypothesized that biological debris from *Demodex* mites may disrupt the epithelial barrier and lead to chronic inflammation and degeneration of conjunctival tissue, contributing to the development of pterygium. Activation of IL-17/MMP-9 signaling may also exacerbate corneal epithelial barrier dysfunction.<sup>33</sup>

## RISK FACTORS AND ASSOCIATED CO-MORBIDITIES

Blepharitis, rosacea, diabetes, and increasing age are risk factors for *Demodex* blepharitis.<sup>21</sup> Other factors that may predispose people to *Demodex* blepharitis include local or systemic immunosuppression, stress, higher alcohol intake, greater sun exposure, and smoking.<sup>3,20,21</sup>

### Rosacea

*Demodex* mites have been implicated in rosacea and there are close associations between *Demodex* skin infestation and ocular *Demodex*.<sup>34,35</sup> It is believed that once facial demodicosis develops, *Demodex* mites migrate and flourish around the eyes as well, contributing to ocular rosacea and/or *Demodex* blepharitis. Ocular rosacea is characterized by telangiectasia, lid margin irregularity, and meibomian gland dysfunction; ocular rosacea can lead to severe ocular surface disease, including cicatrizing conjunctivitis and corneal perforation.<sup>36</sup> Patients with rosacea are more likely to have blepharitis and higher *Demodex* mite densities.<sup>37</sup> Mites likely trigger an inflammatory cascade that worsens both skin and ocular conditions.<sup>31</sup> The dermatology literature suggests that *Demodex* may also be associated with a multitude of skin conditions beyond rosacea, including acne vulgaris, seborrheic dermatitis, and basal cell and sebaceous carcinoma.<sup>16,38</sup>

### Dry Eye Disease (DED)

In recent reports, 60% to 70% of patients with dry eye also presented with *Demodex* blepharitis.<sup>3,14</sup> There is significant overlap in symptoms between *Demodex* blepharitis and dry eye disease. However, ocular signs associated with DED, such as staining, rapid tear break-up time, and reduced Schirmer score, do not correlate with *Demodex* blepharitis.<sup>17,29</sup>

A tear film compromised by DED could make conditions more hospitable for *Demodex* mites. Demodicosis, particularly when unrecognized or untreated, can complicate ocular surface diseases, leading to more severe symptoms.<sup>39</sup> Patients using lifitegrast and cyclosporine were just as likely to have signs of *Demodex* blepharitis (60% had collarettes) as those not using topical immunomodulators, suggesting that dry eye treatments are unlikely to mitigate *Demodex* blepharitis.<sup>14</sup>

### Meibomian Gland Dysfunction

Several authors have reported associations between *Demodex* infestation and MGD. Flores de Venecia et al.<sup>40</sup> reported an 85% incidence of *Demodex* in patients with MGD compared with 34% in healthy control subjects (without any lid margin disease). In a similar study, Bhandari et al. reported a 60% incidence in patients with MGD compared with 18% in control subjects.<sup>41</sup> *Demodex*-positive MGD patients have been shown to have statistically significantly more damage to the size and morphology of the meibomian glands, their openings, and the degree of adjacent fibrosis than *Demodex*-negative MGD patients.<sup>25</sup> The intensity of *Demodex* infestation has been associated with the severity of MG damage: The greater the number of *Demodex* mites, the more serious the structural damage to the meibomian glands.<sup>25</sup> Additionally, patients with *Demodex* blepharitis have been shown to have low-quality meibum<sup>24</sup> and higher concentrations of (O-acyl)- $\omega$ -hydroxy fatty acids (OAHFAs) in their meibum,<sup>26</sup> potentially exacerbating MGD and contributing to tear film instability.

## Chalazia, Hordeola, and Pterygia

Significant associations have been reported between ocular *Demodex* infestation and chalazia<sup>23,42</sup> and pterygium.<sup>32</sup> Two recent articles have noted, in particular, the strong association between *Demodex* infestation and pediatric chalazia and suggested that children with recurrent chalazia should be evaluated for *Demodex* and that *Demodex* should be considered a risk factor for development of chalazia in children.<sup>43,44</sup> It has been hypothesized that a local granulomatous reaction provoked by chitin from decomposing *Demodex* mites may lead to hordeolum or chalazion.<sup>4</sup>

## DIAGNOSIS OF DEMODEX BLEPHARITIS

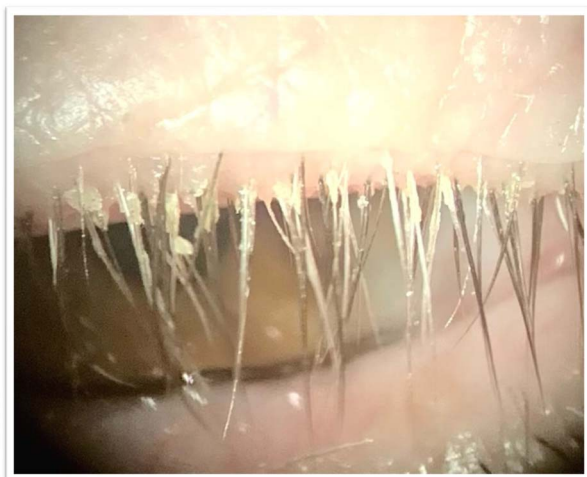
### Clinical Signs

Collarettes—solidified exudative excretions that form a cylindrical collar around the base of the eyelash follicle—are the pathognomonic sign of *Demodex* blepharitis.<sup>18,21,24,35,39,45–49</sup> Several robust studies have shown that all eyes with collarettes (100%) are positive for *Demodex* mites, identified by microscopy<sup>48</sup> or by polymerase chain reaction genetic testing for the mite DNA.<sup>12</sup>

Often referred to in the literature as cylindrical dandruff (CD), collarettes have also been called sleeves, cuffs, crusting, or lash debris. We find the term “collarette” to be the most aptly descriptive. Collarettes are waxy in texture and composed of accumulated undigested material, keratinized cells, dead or living mites, and eggs and egg casings of mites.<sup>4,20,48</sup> Collarettes remain at the base of the lash, differentiating the collarettes from bacterial debris that clings to the shaft of the lash as it grows.<sup>17</sup> Not only is the presence of collarettes indicative of *Demodex* mites, but having a high number of collarettes has been associated with more severe mite infestation.<sup>3,46,48,50</sup> Collarettes can be easily identified at the slitlamp by instructing patients to look down or close the eyelids, so that there is a clear view of the base of the upper lash margin (Fig. 2).<sup>14,16,21,48</sup>

An epilated eyelash sample viewed under a microscope can enable further confirmation of the presence of *Demodex*. However, there is no universally accepted method for sampling lashes and quantifying *Demodex* mite density, making accurate comparisons difficult.<sup>51</sup> In the two recent prevalence studies discussed at the beginning of this review, US researchers found nearly identical rates of demodicosis, regardless of whether the researchers defined demodicosis by the presence of collarette<sup>14</sup> or by lash epilation with mite counts.<sup>15</sup> Outside of clinical trials, lash epilation and microscopy are often impractical. In our experience, observing the presence of collarettes at the slitlamp can be the sole diagnostic indicator for *Demodex* blepharitis in clinical practice because the collarettes are pathognomonic. Furthermore, Zhang et al.<sup>4</sup> recently concluded that positive identification of collarettes (CD), along with eyelash manipulation at the slitlamp (without epilation), may be the most suitable method for diagnosis of *Demodex* blepharitis in clinical settings and that collarettes alone should alert the practitioner to the high likelihood of ocular demodicosis.

Lash anomalies are another important clinical sign of *Demodex* blepharitis. Trichiasis, or eyelash misdirection, is common.<sup>17,20</sup> Madarosis, or eyelash loss, occurs in more advanced cases<sup>20,35</sup> and is predictive of *Demodex* blepharitis. Sędzikowska et al.<sup>52</sup> found a 4.30 odds ratio that patients complaining of eyelash loss would have *Demodex*. Nicholls et al.<sup>20</sup> have also described a less common finding, in which the lash thickness abruptly changes,



**FIG. 2.** Collarettes, the pathognomonic sign of *Demodex* blepharitis, can be readily identified at the base of the upper lash margin on downward gaze at the slitlamp. Image courtesy of Patrick Vollmer, OD.

with a terminal thinning and twisted or split ends, which attribute to the consumption of lash cortex by *Demodex* mites. Given that the purpose of the eyelashes is to protect the ocular surface and direct airflow away from it, mite-induced follicular damage that results in lash misdirection or loss may make patients more symptomatic or negatively impact ocular surface health.<sup>14</sup>

Eyelid margin erythema and telangiectasia are also commonly seen in *Demodex* blepharitis<sup>22,49,53</sup> and may contribute to patients' perception of a negative cosmetic appearance.<sup>53</sup>

## Symptoms

Ocular itching is the symptom most commonly associated with *Demodex* blepharitis,<sup>11,35,50–53</sup> and evidence suggests that patients consider ocular itching to be one of the most bothersome symptoms associated with the disease.<sup>53</sup> *Demodex*-related itching may be more likely to occur at night or early morning after periods of mite activity,<sup>5,35</sup> distinguishing it from daytime, allergy-related itching. Dry eye or blepharitis patients with *Demodex* are significantly more likely to report itching than those without *Demodex*,<sup>3,11</sup> and the frequency of itching complaints increases with higher *Demodex* density.<sup>3,10</sup> Individuals who report itching have a 2.6-fold higher risk of having *Demodex*.<sup>52</sup> *Demodex*-related ocular itching may be propagated through nonhistamine itching pathways.<sup>3</sup>

In addition to itching, those with *Demodex* blepharitis often present with a range of other symptoms, including dryness, discharge, eye redness, burning, tearing, foreign body sensation, pain, and blurred (or fluctuating) vision (Fig. 3).<sup>53</sup>

## Impact of *Demodex* Blepharitis

The symptom burden and psychosocial effects of *Demodex* blepharitis are considerable, according to a recent study of 311 patients with confirmed *Demodex* blepharitis.<sup>53</sup> One-third of the patients reported making multiple visits to a doctor to resolve their symptoms and more than half of the patients reported being bothered by symptoms “frequently” or “all of the time.”<sup>53</sup> Approximately half (51%) of the patients had been experiencing symptoms

for at least four years, and more than half (58%) of the patients had not previously received a correct diagnosis.<sup>53</sup> Eighty percent of the patients said that blepharitis had negatively affected daily life, with impacts on driving at night, daily hygiene routines, contact lens discomfort and, for women, difficulty wearing makeup or artificial lashes.<sup>53</sup> It has previously been reported that patients with blepharitis have a 67% higher risk of anxiety and 52% higher risk of depression compared with those without blepharitis.<sup>54</sup>

Clinicians may want to have a heightened suspicion of *Demodex* blepharitis in specific patient populations. Contact lens wear, by altering the ocular surface microbiome, may increase susceptibility to *Demodex*.<sup>55</sup> Perhaps more importantly for clinical practice, however, *Demodex* may be a significant factor in contact lens intolerance and dropout. Approximately half (51%) of contact lens wearers have *Demodex*.<sup>14</sup> In a study of Asian female contact lens wearers examined by confocal microscopy, *Demodex* was found in 90% of lens wearers compared with 65% of nonwearers ( $P=0.06$ ).<sup>56</sup> Symptomatic lens wearers have been shown to have higher *Demodex* mite density.<sup>57</sup> Tarkowski et al.<sup>58</sup> found that a high percentage of contact lens-intolerant subjects (93%) had *Demodex* infestation compared with only 6% of asymptomatic wearers. Given the positive correlation between the presence of *Demodex* and intolerance to soft contact lenses, *Demodex* mites may exacerbate symptoms of contact lens discomfort.

*Demodex* blepharitis is common in the cataract surgery age population. Using light microscopy, researchers in Poland evaluated the eyelashes of 73 consecutive patients presenting for cataract surgery and found *Demodex* infestation in nearly half of the patients; those patients had lower Schirmer scores and faster tear break-up times.<sup>59</sup> The Titan study also found that 56% of cataract patients demonstrated *Demodex* blepharitis.<sup>14</sup> A healthy ocular surface is critical for successful intraocular lens (IOL) power calculation and good visual outcomes and satisfaction after cataract or refractive surgery, so it is important to screen preoperative patients for ocular surface and lid disease, including *Demodex* blepharitis.

## DISEASE MANAGEMENT

There are currently no FDA-approved treatments for *Demodex* blepharitis. Although a number of over-the-counter and office-based device options have been used clinically and evaluated in relatively small studies, none has yet been established as clearly effective at eradicating mites and eliminating signs of *Demodex* blepharitis.<sup>4,60</sup> Side effects and tolerability should be taken into consideration because successful management of this disease is dependent on patient convenience and compliance, neither of which are ideal with current options. A recent multicenter, randomized controlled study has demonstrated that lotilaner ophthalmic solution, 0.25% (TP-03, Tarsus Pharmaceuticals, Irvine, CA), shows significant improvements in mite eradication, collarette elimination, and eyelid erythema reduction compared with vehicle.<sup>61</sup>

## Current Management Approaches

In the decades since *Demodex* blepharitis was first identified, many agents have been evaluated to better manage the disease, including selenium, antiparasitics, topical and oral antibiotics, and many naturally derived products.<sup>5,18</sup> The most well-studied approaches are described below and in Table 1.

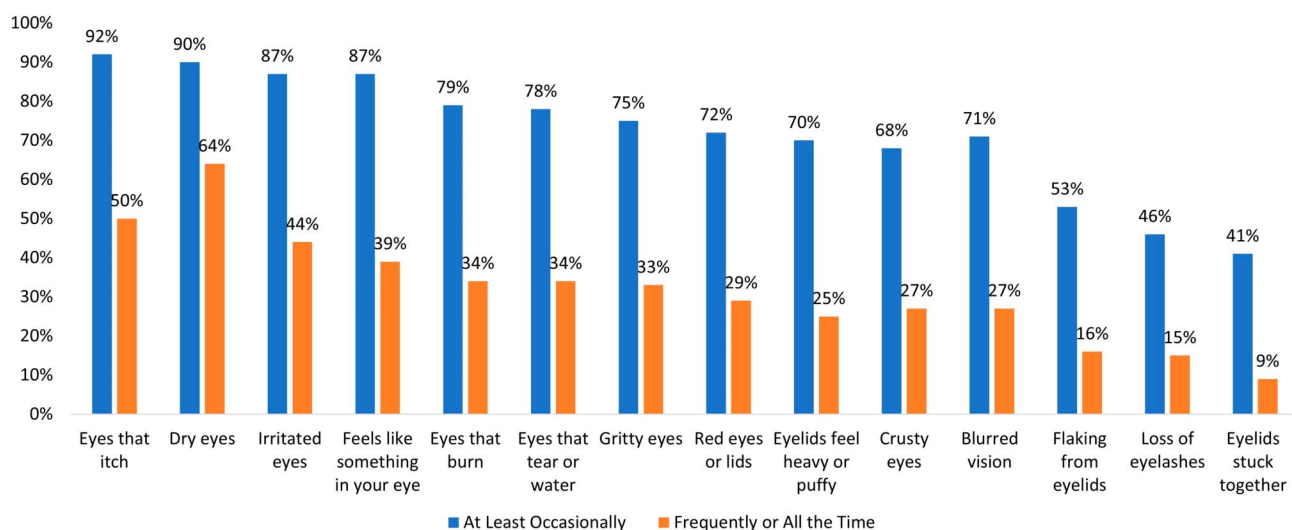


FIG. 3. Symptoms reported by patients with confirmed *Demodex* blepharitis ( N=301).<sup>53</sup>

**Ivermectin and Metronidazole**

Ivermectin and metronidazole have long been used safely by dermatologists to treat *Demodex*-related skin conditions. In a recent meta-analysis, Martinez-Pulgarin et al.<sup>62</sup> reported that the combination of systemic and topical ivermectin and metronidazole had been shown to reduce mite counts in *Demodex* blepharitis, as well. In-office application of topical ivermectin-

metronidazole gel therapy has also recently been tested,<sup>45</sup> but larger studies are needed. Ivermectin is known to have an acaricidal effect,<sup>63</sup> and metronidazole has a broad anti-inflammatory effect through neutrophil-mediated reduction of reactive oxygen species and T lymphocytes.<sup>64</sup> However, the effects of these agents may only temporarily alleviate *Demodex* infestation, and side effects are possible.<sup>5,62,65</sup>

TABLE 1. Current and Emerging Management Approaches to *Demodex* Blepharitis

Agent or Procedure	Form and Dosing	Demonstrated Effects in <i>Demodex</i> Blepharitis	Limitations
Ivermectin <sup>2,45,62,63,65</sup>	Acaricide Oral or topical	Improves signs and symptoms	Hypersensitivity reactions and drug interactions
	Established dermatological treatment	Reduces mite density	More severe side effects with oral use
Metronidazole <sup>45,62,64,65</sup>	Broad anti-inflammatory and antiparasitic Oral or topical	Improves signs and symptoms	Hypersensitivity reactions and drug interactions
	Established dermatological treatment	Reduces mite density	More severe side effects with oral use
Tea tree oil (TTO) and derivatives, especially terpinene 4-ol (T4O) <sup>2,16,18,21,46,47,60,62,66-71</sup>	Over-the-counter and prescription formulations (3% to 100%) available in gel, shampoo, ointment, lid wipe or scrub, and other Broad-spectrum antimicrobial and acaricide	Improves signs and symptoms	Contact dermatitis, ocular irritation, allergic reactions, epithelial cell toxicity
		Some formulations achieve modest levels of mite eradication	
Intense pulsed light (IPL) <sup>72-75</sup>	In-office treatment	Reduces mean <i>Demodex</i> mite density Improves ocular surface parameters	Contraindicated in Fitzpatrick V and VI skin tones, cost
Microblepharoexfoliation (MBE) <sup>2,29,76</sup>	In-office treatment to remove lid and lash debris	Helpful adjunct to at-home lid hygiene Improves symptoms Reduces mite density but does not eradicate mites	Mild discomfort, irritation, or redness
Lotilaner ophthalmic solution, 0.25% <sup>61,78-83</sup>	Investigational drug (0.25%) Topical acaricide 2 drops per day dosing for 6 weeks	High rates of mite eradication, collarette cure, and erythema cure	Mild instillation site pain was the most commonly reported adverse event

Other agents that have been evaluated but for which there is limited evidence in the literature include selenium, topical and oral antibiotics, permethrin cream, manuka honey, okra-derived compounds, mugwort volatile oil, and castor oil.

## Tea Tree Oil and Other Natural Products

Tea tree oil (TTO) and its derivatives (including terpinen 4-ol or T4O) exhibit broad-spectrum antimicrobial activity against bacteria and fungi through the disruption of the cytoplasmic membrane and have demonstrated acaricidal properties, although the exact mechanism of action against *Demodex* viability has not been identified.<sup>66</sup> Products containing various concentrations of TTO (from 3% to 100%) in the form of a gel, shampoo, ointment, face wash, or lid wipe have been shown to be effective in improving signs and symptoms of blepharitis.<sup>18,60,67,68</sup> However, their efficacy for mite eradication remains uncertain.<sup>47</sup> Higher concentrations of TTO (50%+) are more effective<sup>66</sup> but are not considered safe for home use and must be applied in the clinic.

In a stratified meta-analysis, there were no significant subgroup differences between TTO-derived and non-TTO-derived products in mite counts, total eradication, or CD score reduction.<sup>62</sup> Koo et al.<sup>69</sup> reported an overall *Demodex* mite eradication rate of 23.6% in patients using TTO for 1 month. However, in this study, patients underwent a relatively arduous regimen of weekly in-office eyelid scrubs with high-concentration TTO in addition to twice-daily, at-home eyelid scrubs. Researchers have acknowledged that alternative treatments with improved side-effect profiles and less toxicity would be desirable.<sup>21</sup>

The primary side effects associated with TTO and T4O use are contact dermatitis, ocular irritation, and allergic reactions.<sup>16,46,47,70</sup> Until recently, T4O was believed to be less irritating than TTO. However, an in vitro study found that even very low 0.1% and 0.01% concentrations of T4O are toxic to human meibomian gland epithelial cells.<sup>71</sup>

Other natural products that have been proposed for topical use to address *Demodex* blepharitis include Manuka honey, okra-derived compounds, mugwort volatile oil, and castor oil, but robust studies on their effectiveness are lacking.

## In-Office Procedures

Intense pulsed light (IPL) has been proposed as an adjunctive procedure for managing demodicosis. The heat transfer may be beneficial in killing the *Demodex* mites and for MGD, softening meibum, and reducing inflammatory mediators.<sup>72,73</sup> Two recent reports have shown that a series of IPL treatments can reduce mean mite counts and improve ocular surface parameters but the effect on *Demodex* mite density seems to be variable.<sup>74,75</sup> Some limitations of IPL include cost and the fact that IPL cannot be performed on patients with darker skin tones (Fitzpatrick V or VI).

Microblepharoexfoliation (MBE) removes debris on the surface of the eyelids and lashes and has been used in combination with daily at-home eyelid hygiene. Although results were better than eyelid hygiene alone, the results were not clinically meaningful at eliminating *Demodex*.<sup>29,76</sup> An effective treatment for *Demodex* blepharitis would likely decrease the need for mechanical intervention such as MBE or lid scrubs.<sup>77</sup>

## Measures of Efficacy

Various measures have been proposed for evaluating treatment efficacy. Luo et al.<sup>51</sup> proposed that a reduction of 1 mite per lash should be considered the clinical standard for treatment efficacy but there is no global consensus on the number of mites that constitutes infestation or treatment success.<sup>4,17</sup> Recently, an expert panel concluded that patients with more than 10 collarettes should

TABLE 2. Collarette Grading Scale<sup>62</sup>

0	0–2 lashes with collarettes
1	3–10 lashes with collarettes
2	>10 but less than one third of lashes with collarettes
3	One third of lashes or more but less than two thirds of lashes with collarettes
4	Two thirds or more of lashes with collarettes

be treated, irrespective of symptoms, with reductions in collarettes used to evaluate treatment efficacy.<sup>77</sup>

A few studies have used collarette or CD scoring or classification systems to evaluate treatment efficacy. Karakurt et al.,<sup>67</sup> for example, graded CD qualitatively as none (0), light (1), moderate (2), or severe (3). In a recent phase 2b/3 randomized controlled clinical trial of lotilaner ophthalmic solution, 0.25%, for *Demodex* blepharitis, collarettes were graded separately for the upper and lower eyelids according to the quantitative scale shown in Table 2.<sup>61</sup> Grade 2 (>10 collarettes) or higher on this scale for the upper eyelid was required for inclusion in the study. Grade 0, or “collarette cure,” was considered the primary outcome measure, whereas a reduction in collarettes to 10 lashes or less (grade 0 or 1) was considered clinically meaningful because this level of change in collarettes had previously been associated with reduced mite density.<sup>48</sup>

## Emerging Treatments

Lotilaner ophthalmic solution, 0.25% (TP-03), an acaricide of the isoxazoline parasiticide class, has completed late-stage clinical trials. Lotilaner is a veterinary medication approved for use in several countries, including the United States and European Union, for the treatment of ticks and fleas in pets. Lotilaner is lipophilic, making lotilaner well-suited to reach the oily lash follicles where mites reside. Ectoparasites exposed to isoxazolines exhibit a spastic paralysis leading to their starvation and death.<sup>78</sup>

In four phase 2 studies, this eye drop was found to be effective in reducing collarettes and *Demodex* density and well tolerated.<sup>79–82</sup> The Mars single-arm pilot study evaluated 28 days of twice-daily dosing through 90 days of follow-up in participants with confirmed *Demodex* blepharitis.<sup>79</sup> These results were confirmed in a randomized controlled trial, the Jupiter study, which found statistically significant decreases in collarettes and mite density in the lotilaner-treated group compared with vehicle.<sup>80</sup> The Io and Europa studies, in which TP-03 dosing was extended to 6 weeks, demonstrated high rates of collarette cure and mite eradication, again with statistically significant differences compared with a vehicle control group.<sup>81,82</sup>

Most recently, in the pivotal phase 2b/3 Saturn-1 trial, the group treated with TP-03 achieved a statistically significantly higher proportion of patients with clinically meaningful reduction in collarettes to 10 or less (81.3% vs. 23.0%;  $P < 0.0001$ ), collarette cure (44.0% vs. 7.4%;  $P < 0.0001$ , primary endpoint), mite eradication (67.9% vs. 17.6%;  $P < 0.0001$ ), and erythema cure (19.1% vs. 6.9%;  $P = 0.0001$ ) compared with the vehicle control group.<sup>61</sup> This randomized, controlled, double-masked trial enrolled 421 patients with *Demodex* blepharitis; results were confirmed in a second phase 3 study with an additional 412 patients.<sup>83</sup> All patients in both studies presented with *Demodex* blepharitis confirmed by lash epilation and mite count and were required to have collarettes and eyelid erythema to be included in the trial.<sup>61,83</sup> Nearly 92.0% of Saturn-1 patients rated the study drop as neutral to comfortable. All ocular adverse events in the study group were mild, with the most common being instillation site pain.<sup>61</sup>

## CONCLUSION

*Demodex* blepharitis has the potential to impair visual quality and ocular comfort and have a substantial impact on quality of life. The symptoms negatively affect patients, prompting many visits to healthcare practitioners and unsuccessful attempts at relief. Additionally, *Demodex* contributes to ocular surface disorders that may blur vision and may lead to corneal damage, suboptimal surgical outcomes, or contact lens intolerance. *Demodex* blepharitis is likely an underdiagnosed significant public health burden; additional studies are needed to accurately assess its socioeconomic impact.

Current options for the management of *Demodex* blepharitis are burdensome, inconvenient, and may be ineffective and/or toxic to ocular tissues. Recent randomized controlled trials suggest that lotilaner ophthalmic solution, 0.25%, is a topical treatment with the potential to significantly reduce or eliminate *Demodex* mites and collarettes, the pathognomonic sign of *Demodex* blepharitis. The development of a more effective, tolerable, safe, convenient, and regulatory body–approved treatment for *Demodex* blepharitis would benefit patients and provide practitioners with the first targeted tool to combat this prevalent disease.

## ACKNOWLEDGMENTS

The authors thank J. Beiting of Wordsmith Consulting who provided professional medical writing support funded by Tarsus Pharmaceuticals.

## REFERENCES

- Putnam CM. Diagnosis and management of blepharitis: An optometrist's perspective. *Clin Optim (Auckl)* 2016;8:71–78.
- Amescua G, Akpek EK, Farid M, et al. Blepharitis preferred practice Pattern®. *Ophthalmology* 2019;126:PP56–93.
- Cheng AM, Hwang J, Dermer H, et al. Prevalence of ocular demodicosis in an older population and its association with symptoms and signs of dry eye. *Cornea* 2021;40:995–1001.
- Zhang AC, Muntz A, Wang MTM, et al. Ocular demodex: A systematic review of the clinical literature. *Ophthalmic Physiol Opt* 2020;40:389–432.
- Shah PP, Stein RL, Perry HD. Update on the management of demodex blepharitis. *Cornea* 2022;41:934–939.
- Cheng AMS, Sheha H, Tseng SCG. Recent advances on ocular *Demodex* infestation. *Curr Opin Ophthalmol* 2015;26:295–300.
- Correa Font J, Mena Oliva M, Pérez Campos C, et al. Prevalence of *Demodex* spp. in eyelashes of a university's population in Santiago, Chile. *Archivos de la Sociedad Española de Oftalmología (English Edition)* 2020;95:159–163.
- Murphy O, O'Dwyer V, Lloyd-McKernan A. The effect of lid hygiene on the tear film and ocular surface, and the prevalence of *Demodex* blepharitis in university students. *Cont Lens Anterior Eye* 2020;43:159–168.
- Vargas-ARzola J, Segura-Salvador A, Torres-Aguilar H, et al. Prevalence and risk factors to *Demodex* folliculorum infection in eyelash follicles from a university population of Mexico. *Acta Microbiologica et Immunologica Hungarica* 2020;67:156–160.
- Biernat MM, Rusiecka-Ziółkowska J, Piątkowska E, et al. Occurrence of demodex species in patients with blepharitis and in healthy individuals: A 10-year observational study. *Jpn J Ophthalmol* 2018;62:628–633.
- Kabatas N, Dogan AS, Kabatas EU, et al. The effect of *Demodex* infestation on blepharitis and the ocular symptoms. *Eye Contact Lens* 2017;43:64–67.
- Kasetsuwan N, Kositphipat K, Busayarat M, et al. Prevalence of ocular demodicosis among patients at tertiary care center, Bangkok, Thailand. *Int J Ophthalmol* 2017;10:122–127.
- Zhu M, Cheng C, Yi H, et al. Quantitative analysis of the bacteria in blepharitis with *Demodex* infestation. *Front Microbiol* 2018;9:1719.
- Trattler W, Karpecki P, Rapoport Y, et al. The prevalence of *Demodex* blepharitis in US eye care clinic patients as determined by collarettes, a pathognomonic sign. *Clin Ophthalmol* 2022;16:1153–1164.
- Teo A, Rosenberg E, Jacobson A. Prevalence of *Demodex* colonization in patients presenting to an outpatient clinic. *Invest Ophthalmol Vis Sci* 2021;62:1236.
- Fromstein SR, Harthan JS, Patel J, et al. *Demodex* blepharitis: Clinical perspectives. *Clin Optim (Auckl)* 2018;10:57–63.
- Bitton E, Aumond S. *Demodex* and eye disease: A review. *Clin Exp Optom* 2021;104:285–294.
- Lam NSK, Long XX, Li X, et al. Comparison of the efficacy of tea tree (*Melaleuca alternifolia*) oil with other current pharmacological management in human demodicosis: A systematic review. *Parasitology* 2020;147:1587–1613.
- Smith G, Manzano-Marín A, Reyes-Prieto M, et al. Human follicular mites: Ectoparasites becoming symbionts. *Mol Biol Evol* 2022;39:msac125.
- Nicholls SG, Oakley CL, Tan A, et al. *Demodex* species in human ocular disease: New clinicopathological aspects. *Int Ophthalmol* 2017;37:303–312.
- Luo X, Li J, Chen C, et al. Ocular demodicosis as a potential cause of ocular surface inflammation. *Cornea* 2017;36:S9–S14.
- Liu J, Sheha H, Tseng SC. Pathogenic role of *Demodex* mites in blepharitis. *Curr Opin Allergy Clin Immunol* 2010;10:505–510.
- Scheer MJ, Milman T, Steiner T, et al. The association of demodex with chalazia: A histopathologic study of the eyelid. *Ophthalmic Plast Reconstr Surg* 2016;32:275–278.
- Rabensteiner DF, Aminfar H, Boldin I, et al. *Demodex* mite infestation and its associations with tear film and ocular surface parameters in patients with ocular discomfort. *Am J Ophthalmol* 2019;204:7–12.
- Cheng S, Zhang M, Chen H, et al. The correlation between the microstructure of meibomian glands and ocular demodex infestation: A retrospective case-control study in a Chinese population. *Medicine (Baltimore)* 2019;98:e15595.
- Gao H, Chen H, Xie HT, et al. Changes in meibum lipid composition with ocular *Demodex* infestation. *Transl Vis Sci Technol* 2021;10:6.
- Fu Y, Wu J, Wang D, et al. Metagenomic profiling of ocular surface microbiome changes in *Demodex* blepharitis patients. *Front Cell Infect Microbiol* 2022;12:922753.
- Rynerson JM, Perry HD. DEBS &dash; a unification theory for dry eye and blepharitis. *Clin Ophthalmol* 2016;10:2455–2467.
- Epstein IJ, Rosenberg E, Stuber R, et al. Double-masked and unmasked prospective study of terpinen-4-ol lid scrubs with microblepharoexfoliation for the treatment of *Demodex* blepharitis. *Cornea* 2020;39:408–416.
- Yan Y, Yao Q, Lu Y, et al. Association between *Demodex* infestation and ocular surface microbiota in patients with *Demodex* blepharitis. *Front Med (Lausanne)* 2020;7:592759.
- Forton FMN. The pathogenic role of demodex mites in rosacea: A potential therapeutic target already in erythematotelangiectatic rosacea? *Dermatol Ther (Heidelberg)* 2020;10:1229–1253.
- Tarkowski W, Moneta-Wielgoś J, Młocicki D. Do *Demodex* mites play a role in pterygium development? *Med Hypotheses* 2017;98:6–10.
- Zhang XB, Ding YH, He W. The association between demodex infestation and ocular surface manifestations in meibomian gland dysfunction. *Int J Ophthalmol* 2018;11:589–592.
- Gonzalez-Hinojosa D, Jaime-Villalonga A, Aguilar-Montes G, et al. *Demodex* and rosacea: Is there a relationship? *Indian J Ophthalmol* 2018;66:36–38.
- Ayres BD, Donnenfeld E, Farid M, et al. Clinical diagnosis and management of *Demodex* blepharitis: The *Demodex* expert panel on treatment and eyelid health (DEPTH). *Eye (Lond)* 2023; Online ahead of print.
- Karamursel Akpek E, Merchant A, Pinar V, et al. Ocular rosacea: Patient characteristics and follow-up. *Ophthalmology* 1997;104:1863–1867.
- Sarac G, Cankaya C, Ozcan KN, et al. Increased frequency of *Demodex* blepharitis in rosacea and facial demodicosis patients. *J Cosmet Dermatol* 2020;19:1260–1265.
- Aktaş Karabay E, Aksu Çerman A. *Demodex* folliculorum infestations in common facial dermatoses: Acne vulgaris, rosacea, seborrheic dermatitis. *Anais Brasileiros de Dermatologia* 2020;95:187–193.
- Ziaja-Softys M, Kołodziejczyk M, Rymgayło-Jankowska B, et al. Massive demodicosis of the eyes in a patient with Sjögren syndrome: A case report. *Acta Parasitologica* 2021;66:677–681.
- Flores de Venecia AB III, Siong RLB. *Demodex* sp. Infestation in anterior blepharitis, meibomian-gland dysfunction, and mixed blepharitis. *Philipp J Ophthalmol* 2011;36:15–22.
- Bhandari V, Reddy JK. Blepharitis: Always remember demodex. *Middle East Afr J Ophthalmol* 2014;21:317–320.
- Liang L, Ding X, Tseng SCG. High prevalence of demodex brevis infestation in chalazia. *Am J Ophthalmol* 2014;157:342–348.
- Huang J, Guo MX, Xiang DM, et al. The association of demodex infestation with pediatric chalazia. *BMC Ophthalmol* 2022;22:124.

44. Xiao Y, Gao L, Shen L, et al. High load of Demodex in young children with chalazia. *J Pediatr Ophthalmol Strabismus* 2022;1–7. Online ahead of print.
45. Avila MY, Martinez-Pulgarin DF, Rizo Madrid C. Topical ivermectin-metronidazole gel therapy in the treatment of blepharitis caused by demodex spp.: A randomized clinical trial. *Contact Lens and Anterior Eye* 2021;44:101326.
46. Messaoud R, El Fekih L, Mahmoud A, et al. Improvement in ocular symptoms and signs in patients with Demodex anterior blepharitis using a novel terpinen-4-ol (2.5%) and hyaluronic acid (0.2%) cleansing wipe. *Clin Ophthalmol* 2019;13:1043–1054.
47. Savla K, Le JT, Pucker AD. Tea tree oil for Demodex blepharitis. *Cochrane Database Syst Rev* 2020;6:CD013333.
48. Gao YY, Di Pascual MA, Li W, et al. High prevalence of Demodex in eyelashes with cylindrical dandruff. *Invest Ophthalmol Vis Sci* 2005; 46:3089–3094.
49. Randon M, Liang H, El Hamdaoui M, et al. In vivo confocal microscopy as a novel and reliable tool for the diagnosis of Demodex eyelid infestation. *Br J Ophthalmol* 2015;99:336–341.
50. Aumond S, Bitton E. Palpebral and facial skin infestation by Demodex folliculorum. *Cont Lens Anterior Eye* 2020;43:115–122.
51. Luo KS, Xie A, Yang JJ, et al. Critical value of Demodex count per lash for symptomatic and clinical improvement of Demodex blepharitis. *Eye (Lond)* 2021;36:663–665, online ahead of print.
52. Sedzikowska A, Osęka M, Grytner-Zięcina B. Ocular symptoms reported by patients infested with Demodex mites. *Acta Parasitol* 2016;61:808–814.
53. O'Dell L, Dierker DS, Devries DK, et al. Psychosocial impact of Demodex blepharitis. *Clin Ophthalmol* 2022;16:2979–2987.
54. Chiang CC, Lin CL, Tsai YY, et al. Patients with blepharitis are at elevated risk of anxiety and depression. *PLoS One* 2013;8:e83335.
55. Ozkan J, Willcox MD. The ocular microbiome: Molecular characterisation of a unique and low microbial environment. *Curr Eye Res* 2019;44:685–694.
56. Jalbert I, Rejab S. Increased numbers of Demodex in contact lens wearers. *Optom Vis Sci* 2015;92:671–678.
57. Siddireddy JS, Vijay AK, Tan J, et al. The eyelids and tear film in contact lens discomfort. *Cont Lens Anterior Eye* 2018;41:144–153.
58. Tarkowski W, Moneta-Wielgoś J, Młocicki D. Demodex sp. as a potential cause of the abandonment of soft contact lenses by their existing users. *Biomed Res Int* 2015;2015: 1–7.
59. Nowomiejska K, Lukasik P, Brzozowska A, et al. Prevalence of ocular demodicosis and ocular surface conditions in patients selected for cataract surgery. *J Clin Med* 2020;9:3069.
60. Hirsch-Hoffmann S, Kaufmann C, Banninger PB, et al. Treatment options for demodex blepharitis: Patient choice and efficacy. *Klin Monbl Augenheilkd* 2015;232:384–387.
61. Yeu E, Wirta DL, Karpecki P, et al. Lotilaner ophthalmic solution, 0.25% for the treatment of Demodex blepharitis: Results of a prospective, randomized, vehicle-controlled, double-masked, pivotal trial (Saturn-1). *Cornea* 2023;42:435–443.
62. Martinez-Pulgarin DF, Avila MY, Rodriguez-Morales AJ. Interventions for demodex blepharitis and their effectiveness: A systematic review and meta-analysis. *Cont Lens Anterior Eye* 2021;44:101453.
63. Holzchuh FG, Hida RY, Moscovici BK, et al. Clinical treatment of ocular Demodex folliculorum by systemic ivermectin. *Am J Ophthalmol* 2011; 151:1030–1034.
64. Persi A, Rebora A. Metronidazole and demodex folliculorum. *Acta Derm Venereol* 1981;61:182–183.
65. Navel V, Mulliez A, Benoist d'Azy C, et al. Efficacy of treatments for demodex blepharitis: A systematic review and meta-analysis. *Ocul Surf* 2019;17:655–669.
66. Cheung IM, Xue AL, Kim A, et al. In vitro anti-demodectic effects and terpinen-4-ol content of commercial eyelid cleansers. *Cont Lens Anterior Eye* 2018; 41:513–517.
67. Karakurt Y, Zeytun E. Evaluation of the efficacy of tea tree oil on the density of demodex mites (acari: Demodicidae) and ocular symptoms in patients with demodectic blepharitis. *J Parasitol* 2018;104:473–478.
68. Ergun SB, Saribas GS, Yarayici S, et al. Comparison of efficacy and safety of two tea tree oil-based formulations in patients with chronic blepharitis: A double-blinded randomized clinical trial. *Ocul Immunol Inflamm* 2020;28:888–897.
69. Koo H, Kim TH, Kim KW, et al. Ocular surface discomfort and demodex: Effect of tea tree oil eyelid scrub in demodex blepharitis. *J Korean Med Sci* 2012; 27:1574–1579.
70. Ngo W, Jones L, Bitton E. Short-term comfort responses associated with the use of eyelid cleansing products to manage Demodex folliculorum. *Eye Contact Lens* 2018;44:S87–S92.
71. Chen D, Wang J, Sullivan DA, et al. Effects of terpinen-4-ol on meibomian gland epithelial cells in vitro. *Cornea* 2020;39:1541–1546.
72. Huang X, Qin Q, Wang L, et al. Clinical results of intraductal meibomian gland probing combined with intense pulsed light in treating patients with refractory obstructive meibomian gland dysfunction: A randomized controlled trial. *BMC Ophthalmol* 2019;19:211.
73. Craig JP, Chen YH, Turnbull PRK. Prospective trial of intense pulsed light for the treatment of meibomian gland dysfunction. *Invest Ophthalmol Vis Sci* 2015;56:1965–1970.
74. Cheng SN, Jiang FG, Chen H, et al. Intense pulsed light therapy for patients with meibomian gland dysfunction and ocular Demodex infestation. *Curr Med Sci* 2019;39:800–809.
75. Zhang X, Song N, Gong L. Therapeutic effect of intense pulsed light on ocular demodicosis. *Curr Eye Res* 2019;44:250–256.
76. Murphy O, O'Dwyer V, Lloyd-McKernan A. The efficacy of tea tree face wash, 1,2-octanediol and microblepharoxfoliation in treating Demodex folliculorum blepharitis. *Cont Lens Anterior Eye* 2018;41:77–82.
77. Farid M, Ayres BD, Donnenfeld E, et al. Delphi panel consensus regarding current clinical practice management options for Demodex blepharitis. *Clin Ophthalmol* 2023;17:667–679.
78. Toutain CE, Seewald W, Jung M. The intravenous and oral pharmacokinetics of lotilaner in dogs. *Parasit Vectors* 2017;10:522–529.
79. Gonzalez-Salinas R, Yeu E, Holdbrook M, et al. Safety and efficacy of topical lotilaner ophthalmic solution 0.25% for the treatment of demodex blepharitis: A pilot study. *J Ophthalmol* 2021;2021:3862684.
80. Gonzalez-Salinas R, Karpecki P, Yeu E, et al. Safety and efficacy of lotilaner ophthalmic solution, 0.25% for the treatment of blepharitis due to demodex infestation: A randomized, controlled, double-masked clinical trial. *Cont Lens Anterior Eye* 2022;45:101492.
81. Gonzalez-Salinas R, Yeu E, Holdbrook M, et al. Collarette elimination and demodex mite eradication with topical lotilaner ophthalmic solution, 0.25%. *J Ocul Pharmacol Ther* 2021;37:479–484.
82. Gonzalez-Salinas R, Yeu E, Quiroz-Mercado H, et al. Safety and efficacy of lotilaner ophthalmic solution 0.25% for the treatment of Demodex blepharitis: The EUROPA Study. *Invest Ophthalmol Vis Sci* 2021; 62:1332.
83. Yeu E, Berdy G, Peterson J, et al. *Safety and Efficacy of Lotilaner Ophthalmic Solution, 0.25% in Treating Demodex Blepharitis: Results of the Saturn-2, Pivotal, Phase III Trial*. 2022. Chicago: IL: American Academy of Ophthalmology.