

# Hypersensitivity pneumonitis presenting as sarcoidosis

Linda S Forst, Jerrold Abraham

Pulmonary sarcoidosis and hypersensitivity pneumonitis are two disease entities that may have similar clinical, laboratory, and pathological features. A low index of suspicion for hypersensitivity pneumonitis combined with the overlapping features contribute to the difficulty of distinguishing the two diseases. Indeed, two case series suggest that four of 51 and two of 46 subjects originally diagnosed as having sarcoidosis showed clinical and histological characteristics more consistent with hypersensitivity pneumonitis.<sup>1,2</sup> Because early recognition of hypersensitivity pneumonitis can lead to complete reversal of disease in many cases, it is important to make this diagnosis as early as possible. We present a case that was most likely misdiagnosed and resulted in continued workplace exposure, considerable morbidity, and unwarranted discharge from employment due to a probable work related illness.

## Case report

SM is a 30 year old black man who worked as a spraypainter. He had been denied workers' compensation for a case based on an alleged occupational aetiology for "pulmonary sarcoidosis". He was referred to a private occupational health centre by an attorney requesting advice as to whether the case should be pursued in civil court.

This previously healthy patient had been employed as a spraypainter in a company producing plastic and metal parts, beginning in 1979 at the age of 18. His job entailed mixing a solvent, a paint, and a catalyst containing toluene diisocyanate in a bucket. This then was poured into a quart size spray tank. Clean shaven, he donned a rubber respirator fitted with a dual cartridge and sprayed small plastic and metal parts. He stated that on many occasions he coughed out paint pig-

ment, despite the use of the respirator. In 1984 he began to experience episodes of acute dyspnoea while spraypainting, causing him to remove the respirator and leave the 12 foot × 12 foot plastic sheeting enclosed area to run outside for fresh air. He noted a choking sensation and chest tightness that recurred every time he painted and then subsided, only to recur several hours after leaving work. Initially, the symptoms completely resolved during weekends, but after several weeks he experienced symptoms all the time. A pulmonary function test at that time reportedly showed moderate restrictive lung disease with a decreased diffusing capacity. A chest radiograph showed interstitial infiltrates and bilateral hilar adenopathy. The patient was admitted to hospital in 1985 for a transbronchial biopsy, which showed "a few non-caseating granulomata associated with moderate fibrosis suggestive of sarcoidosis". Fungal and mycobacterial stains were negative. A gallium scan showed increased uptake in the bilateral hilar regions with a patchy increase in uptake in both lungs, especially in the upper lobes. The patient was restricted from spraypainting by his physician and was consequently laid off by the company in January of 1986. The patient was prescribed oral prednisone in 1985 and continued to take it until December 1988.

A second review of the transbronchial biopsy (by JA) revealed well formed, non-caseating, interstitial granulomata with no histological features that favoured sarcoidosis over hypersensitivity pneumonitis (figure). Quantitative electron probe microanalysis of the lung tissue using standardised methods<sup>3</sup> showed a total concentration of  $118 \times 10^6$  exogenous particles/ml tissue, comprised of silica ( $3 \times 10^6$ ), aluminium silicates ( $28 \times 10^6$ ), and metal particles ( $68.5 \times 10^6$ ). Further analysis of the specific elements in the metal particles showed iron ( $37.4 \times 10^6$ ), titanium ( $34.2 \times 10^6$ ), aluminium ( $9.3 \times 10^6$ ), Zinc ( $6.2 \times 10^6$ ), barium ( $3.1 \times 10^6$ ), and Zirconium ( $3.1 \times 10^6$ ).

Comparison of these results with similar analyses in over 400 cases comprising a pneumoconiosis database<sup>4</sup> confirmed that the total particulate concentration was above background (usually less than  $10 \times 10^6$  particles/ml lung in the population with-

---

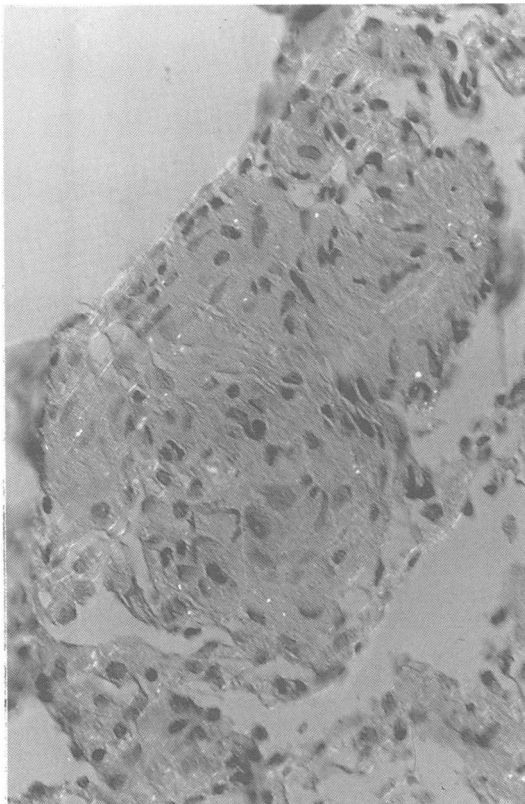
University of Illinois at Chicago, Section of Environmental and Occupational Medicine, PO Box 6998, M/C 678, Chicago, Illinois 60680, USA

LS Forst

State University of New York, Syracuse, New York, USA

J Abraham

---



*Haematoxylin and eosin stained section of transbronchial biopsy; partially polarised light micrograph showing small interstitial granuloma and contiguous parenchyma. Note several tiny birefringent particles; these were opaque in bright field illumination, properties typical of titanium dioxide particles. Magnification 200 $\times$ .*

out unusual occupational or environmental exposure). The concentrations of silica and aluminium silicates were not in the ranges seen in silicosis or silicate pneumoconiosis. The most unusual finding was that of the raised titanium concentration. This ranks in the upper 12% of 494 analyses currently tabulated in the database (titanium concentration, median  $45.0 \times 10^6$ , range zero to  $650 \times 10^6$  particles/ml lung). Although somewhat higher than normal, the other metallic elements detected were not raised to the ranges in other cases of disease associated with, for example, exposure to aluminium or zirconium.<sup>5,6</sup>

### Discussion

The diagnosis of sarcoidosis was most likely made in this patient because he is black, in his twenties, had hilar adenopathy, exhibited restrictive lung disease on pulmonary function testing, and had a transbronchial biopsy showing non-caseating gran-

ulomata. In the United States, sarcoidosis is 10 times more common in black than white people with the onset of disease occurring before the age of 40 in 74%; intrathoracic disease occurs in more than 80% of cases.<sup>7</sup>

### CLINICAL PRESENTATION

The patient's history is suggestive of hypersensitivity pneumonitis caused by exposure to toluene diisocyanate in his workplace. The development of hypersensitivity pneumonitis secondary to exposure to diisocyanate was first described in 1976.<sup>8</sup> In 1989, a well documented case of hypersensitivity pneumonitis caused by toluene diisocyanate was reported from Japan.<sup>9</sup> Classically, the clinical features of hypersensitivity pneumonitis include cough, dyspnoea, and fever that may occur four to six hours after exposure and tend to resolve when away from the offending agent; with antigen challenge in the clinical setting, patients may also show an immediate IgE response by a fall in forced expiratory volume in one second (FEV<sub>1</sub>). There are insidious cases associated with long term exposure leading to chronic dyspnoea, malaise, weakness, and weight loss. Pulmonary sarcoidosis tends to be insidious in onset, with gradual development of dyspnoea that is worse with exercise; it may also entail constitutional symptoms such as fever and weight loss. In both hypersensitivity pneumonitis and sarcoidosis pulmonary function testing shows restrictive disease with a decreased diffusing capacity. In both entities, the chest radiograph may be completely clear or show interstitial infiltrates; bilateral hilar adenopathy is seen in 80% to 90% of cases of sarcoidosis;<sup>10</sup> it is not a feature described in hypersensitivity pneumonitis.<sup>10</sup> In hypersensitivity pneumonitis symptoms, pulmonary function and chest x ray film abnormalities may wax and wane with exposure; in sarcoidosis, these abnormalities tend to appear and subside gradually. Both diseases can lead to irreversible pulmonary fibrosis.<sup>11</sup> This patient had respiratory exposure to toluene diisocyanate at work despite his use of a respirator, as shown by his reports of coughing out paint pigment, and by the presence of titanium particles in his lung tissue; titanium is a common component of paint but is not a typical contaminant of lung tissue. Initially, he had symptoms while working, with later development of a second bout of dyspnoea and chest tightness several hours after work. He had hilar adenopathy and interstitial fibrosis on chest x ray film. His pulmonary function showed restrictive disease and a decreased diffusing capacity. His gallium uptake was increased in the hilar regions, with a patchy increase in parenchymal uptake. The pattern of symptomatology is more consistent with hypersensitivity pneumonitis; hilar adenopathy is more consistent with sarcoidosis,

although it may be an incidental finding; the interstitial fibrosis and abnormal pulmonary function testing cannot distinguish between the two entities.

#### HISTOLOGY

Hogg describes the histology of hypersensitivity pneumonitis and features that distinguish it from sarcoidosis.<sup>12</sup> Alveolitis, which is common in hypersensitivity pneumonitis, is less so in sarcoidosis. Bronchiolitis obliterans is rare in sarcoidosis and present in about 50% of hypersensitivity pneumonitis specimens; foreign particles believed to be involved in initiating the immunological reaction leading to lung disease are sometimes seen in hypersensitivity pneumonitis. Granulomata in sarcoidosis tend to be well formed and are located along the lymphatics; therefore, they are more prominent at the periphery of the lobule. In hypersensitivity pneumonitis cellular infiltrates containing lymphs, plasma cells, and eosinophils, as well as the generally more ragged granulomata are centrilobular in position, which Hogg attributes to the site of deposition of the offending antigenic stimulus. He points out, however, that an intermediate position of the granuloma and cellular infiltrate makes a distinction between the two entities difficult. In this patient, granulomata were not characteristic of either disease to the exclusion of the other. The limited sampling of a transbronchial biopsy makes it less useful in examining distributions of lesions than an open lung biopsy.

#### LABORATORY TESTS

Support for a diagnosis of sarcoidosis comes from findings of anergy to skin tests;<sup>13</sup> an increase in angiotensin converting enzyme—an enzyme produced by the sarcoid granuloma; hypercalcaemia; hypercalciuria; a positive Kveim-Siltzbach test which ranges in sensitivity from 30% to 90% depending on the clinical presentation<sup>13</sup>; and an increased number of activated T cells in bronchoalveolar lavage that have been shown to be almost exclusively of the OKT4+ helper phenotype.<sup>14</sup> Hypersensitivity pneumonitis also shows an increase in activated T cells in bronchoalveolar lavage fluid; however, OKT8+ suppressor T cells are the most prominent with a helper:suppressor ratio of 1:1 (*v* 4-13:1 in sarcoidosis). In hypersensitivity pneumonitis, IgG serum precipitins to the offending antigen, an Arthus skin reaction, and *in vitro* lymphocyte transformation and lymphokine production may help in diagnosis. In this patient, none of these tests were carried out during the exposure or active phase of the disease.

#### Conclusion

A diagnosis of pulmonary sarcoidosis is generally

made on the grounds of clinical presentation, epidemiological considerations, and histological investigation. It is possible that sarcoidosis may represent a spectrum of disease with diverse aetiologies, as well as its diverse clinical presentations, and *x* ray film and laboratory findings. Because it is suspected more readily by clinicians and because of its similarities to hypersensitivity pneumonitis, sarcoidosis may be misdiagnosed in persons whose work histories are not obtained. As there are no findings pathognomonic of sarcoidosis, it is necessarily a diagnosis of exclusion. This patient had exposure to toluene diisocyanate, a substance known to cause hypersensitivity pneumonitis; his respiratory symptoms were temporally related to work; after five years of exposure to toluene diisocyanate he developed respiratory symptoms that were initially present in the workplace and several hours after work, and then became constant; he had a chest *x* ray film showing interstitial fibrosis and hilar adenopathy; pulmonary function testing showed restrictive disease and a decreased diffusing capacity; a lung biopsy specimen showed non-caseating granulomata. Microanalysis of the lung biopsy specimen documented a raised concentration of titanium particles, confirming an occupational exposure to at least the pigment portion of the paint. Although a case report has been published showing an increased lymphocyte proliferative response in a patient with granulomatous lung disease who was challenged with titanium, an aetiological role has yet to be proved.<sup>15</sup> Toluene diisocyanate leaves no detectable residue in the lungs. Antibody testing for toluene diisocyanate in peripheral blood was not done and would not likely have given meaningful results, especially two years after cessation of exposure. Toluene diisocyanate challenge may have clarified the aetiology of disease but was not clinically indicated. Objective testing could not absolutely distinguish between the two diseases in this case; however, the clinical presentation, work history, and pathological documentation of exposure make hypersensitivity pneumonitis the more likely cause of morbidity in this patient.

#### Epilogue

SM was last evaluated in June of 1990 at the age of 29. At that time he had no abnormal respiratory symptoms at rest and reported an increase in exercise tolerance. Physical examination was completely within normal limits. Pulmonary function testing showed a forced vital capacity (FVC) of 3.97 (79% predicted, with race correction), FEV<sub>1</sub> of 3.30 (81% predicted), FEV<sub>1</sub>/FVC of 0.83 (predicted), and a total lung capacity of 5.21 (64% predicted). Exercise O<sub>2</sub> saturation was 93% after 10 minutes of treadmill exercise. Chest radiography showed

chronic interstitial scarring that was unchanged from a 1987 film, but improved from a 1985 film. SM was taking steps to re-enter the workforce.

This patient was evaluated at the Greater Cincinnati Occupational Health Centre in Cincinnati, Ohio.

- 1 Burke GW, Gaensler E, Carrington C, Gupta R, Fitzgerald M. Hypersensitivity pneumonitis or sarcoidosis? *Chest* 1976;70:421.
- 2 Konig G, Baur X, Fruhmarm G. Sarcoidosis or extrinsic allergic alveolitis? *Respiration* 1981;42:150-4.
- 3 Abraham JL, Burnett BR. Quantitative in situ analysis of inorganic particulate burden in tissues - an update. In: Ingram P, Shelburne JD, Roggli VL, eds. *Microprobe analysis in medicine*. New York: Hemisphere Publishing 1989:111-31.
- 4 Abraham JL, Burnett BR, Hunt A. Development and use of a pneumoconiosis database of human pulmonary inorganic particulate burden in over 400 lungs. *Scanning Microscopy* 1991;5:95-108.
- 5 Herbert A, Sterling C, Abraham JL, Corrin B. Desquamative interstitial pneumonia in an aluminium welder. *Human Pathol* 1982;13:694-9.
- 6 Bartter T, Irwin RS, Abraham JL, Dascal A, Nash G, Himmelstein JS, Jederling RJ. Zirconium compound induced pulmonary fibrosis. *Arch Intern Med* 1991;151:1197-201.
- 7 James DG, Neville E, Siltzbach LE, et al. A worldwide review of sarcoidosis. *Ann NY Acad Sci* 1976;278:321-8.
- 8 Charles J, Bernstein A, Jones B, Jones DF, Edwards JH, Seal R, Seaton A. Hypersensitivity pneumonitis after exposure to isocyanates. *Thorax* 1976;31:127-36.
- 9 Yoshizawa Y, Ohtsuka M, Noguchi K, Uchida Y, Suko M, Hasegawa S. Hypersensitivity pneumonitis induced by toluene diisocyanate: sequelae of continuous exposure. *Ann Intern Med* 1989;110:31-4.
- 10 Rockoff SD, Rohatgi P. Analysis of unusual thoracic manifestations of sarcoidosis: a review of radiographic features. In: Grassi C, Rizatto G, Pozzi E, eds. *Sarcoidosis and other granulomatous diseases* (11th Congress). New York: Excerpta Medica, Elsevier Science Publishing, 1988.
- 11 Fink JN. Hypersensitivity pneumonitis. *J Allergy Clin Immunol* 1984;74:1-9.
- 12 Hogg JC. Extrinsic allergic alveolitis and occupational asthma. In: Churg A and Green F, eds. *Pathology of occupational lung disease* New York: Igaku-Shoin 1988:331-49.
- 13 Mitchell DN, Scadding JG. Sarcoidosis. *Am Rev Respir Dis* 1974;110:774-802.
- 14 Costabel U, Bross K, Ruhle K, Lohr G, Matthys H. Ia-like antigens on T cells and their sub-populations in pulmonary sarcoidosis and hypersensitivity pneumonitis. *Am Rev Respir Dis* 1985;131:337-42.
- 15 Redline S, Barna BP, Tomaszefski JF, Abraham JL. Granulomatous Disease Associated with titanium pulmonary deposition. *Br J Ind Med* 1986;43:652-6.

## Vancouver style

All manuscripts submitted to the *Br J Ind Med* should conform to the uniform requirements for manuscripts submitted to biomedical journals (known as the Vancouver style).

The *Br J Ind Med*, together with many other international biomedical journals, has agreed to accept articles prepared in accordance with the Vancouver style. The style (described in full in *Br Med J*, 24 February 1979, p 532) is intended to standardise requirements for authors.

References should be numbered consecutively in the order in which they are first mentioned in the text by Arabic numerals above the line on each occasion the reference is cited (Manson<sup>1</sup> confirmed other reports<sup>2-5</sup> . . .). In future references to papers submitted to the *Br J Ind Med* should include: the

names of all authors if there are six or less or, if there are more, the first three followed by *et al*; the title of journal articles or book chapters; the titles of journals abbreviated according to the style of *Index Medicus*; and the first and final page numbers of the article or chapter.

Examples of common forms of references are:

- 1 International Steering Committee of Medical Editors. Uniform requirements for manuscripts submitted to biomedical journals. *Br Med J* 1979;1:532-5.
- 2 Soter NA, Wasserman SI, Austen KF. Cold urticaria: release into the circulation of histamine and eosino-phil chemotactic factor of anaphylaxis during cold challenge. *N Engl J Med* 1976;294:687-90.
- 3 Weinstein L, Swartz MN. Pathogenic properties of invading micro-organisms. In: Sodeman WA Jr, Sodeman WA, eds. *Pathologic physiology: mechanisms of disease*. Philadelphia: W B Saunders, 1974:457-72.