

ARGYRO-SIDEROSIS OF THE LUNGS IN SILVER FINISHERS

BY

H. J. BARRIE and H. E. HARDING

Pathology Department, University of Sheffield

(RECEIVED FOR PUBLICATION, NOVEMBER 29, 1946)

McLaughlin and others (1945) described the clinical and radiological findings in four men who had been silver finishers for many years, and the results of an autopsy on one of them. They found that the iron oxide and silver dust to which these men were exposed in the course of their work had been inhaled into their lungs causing stippled or reticulated shadows in radiographs of the chest, but that this was not associated with obvious physical disability. In the case coming to necropsy there was emphysema but no fibrosis of the lungs; the iron pigment formed intra-cellular masses distributed throughout the course of the lymphatics, and the silver had produced intra-vitam staining of the elastica in the arterial and alveolar walls.

Three further silver finishers have since come to necropsy, and a brief description of the findings will serve to show that the changes in the lung are remarkably uniform. A summary of the original case is placed first in the list.

Iron oxide is opaque and relatively insoluble; it therefore does not give a visible blue coloration with ferrocyanide and hydrochloric acid, and in ordinary hæmatoxylin and eosin preparation it is indistinguishable from carbon and other opaque particulate matter. McLaughlin and others (1945) identified it by incinerating the sections and then examining them by reflected light. In the present study we found it better to mount the unstained sections on thin slides and examine them by dark-ground illumination. By this method the iron oxide appears bright orange-red. The silver deposits on the elastica were identified by bleaching with 1/1,000 KCN solution as described in the original paper. By reflected light the silver showed as bright glittering particles but was not thus distinguishable from other

particulate matter. The results of analysis of the iron and silver content of some of the organs of these four cases are considered separately from the other necropsy findings.

Case Histories

Case 1.—A. B., aged 60, had been a silver finisher for 46 years. He had a slight cough for 16 years, and coughed up copious reddish-black sputum but made no complaint of dyspnoea. On clinical examination six years before death he was thought to have emphysema, and a radiograph of the chest showed generalized stippling or reticulation of both lung fields. Nine weeks before death he developed continuous and increasing epigastric pain from a gastric ulcer, and he died of peritonitis and bronchopneumonia shortly after a partial gastrectomy.

Necropsy Report.—Necropsy examination showed argyro-siderosis of the lungs and chronic emphysema. The patient had had a partial gastrectomy for peptic ulcer, and the gastric suture line was ruptured. The signs of general peritonitis and bronchopneumonia were present. There was bullous emphysema of the anterior borders, and generalized spongy emphysema of the rest of the lungs, but no visible fibrosis.

Microscopical Findings.—The lungs showed extensive acute bronchopneumonia and well-marked emphysema. The subpleural and perivascular connective tissue contained aggregates of phagocytes laden with opaque granules of iron oxide which appeared black in transmitted light, and in incinerated sections viewed by reflected light were seen to be reddish brown. On the elastic fibrils in the alveolar walls and the internal elastic laminae of the smaller blood vessels was a very fine brownish black deposit of silver granules (fig. 1), which could be removed by treating the sections with 1/1,000 KCN, and which was probably silver. Iron pigment stainable with ferrocyanide and HCl was present in small amounts in intra-alveolar phagocytes.

There was moderate central lobular congestion of the liver, and in sections treated with ferrocyanide and HCl there were abundant blue granules in the liver cells and in some of the Kupffer cells. The reticulo-endothelial cells of the splenic pulp were closely packed and hyperplastic and contained masses of hæmosiderin.

Case 2.—C. W., a male aged 64 years, had been a silver finisher for 39 years and had complained of severe cough for many years. He was admitted on May 1, 1944, with intestinal obstruction due to carcinoma of the pelvic colon. A cæcostomy was performed under spinal anaesthesia and the patient had a stormy post-operative course marked by extreme tachycardia. He began to recover, but then suddenly relapsed and died on May 18, 1944.

Necropsy Report.—Necropsy examination revealed argyrosiderosis of the lungs, chronic emphysema, and carcinoma of the pelvic colon, suppurating infarct of the left lung, and hæmoptysis and hæmothorax. Laparotomy and cæcostomy had been performed. The body was of a very thin old man. There was no pigmentation of the skin, doubtful grey pigmentation of sclerotics, frothy bloody fluid throughout the trachea and bronchi, fibrinous pleurisy of both lower lobes, and 15 oz. of blood in the left pleural cavity. There was a collapsed cavity 6 cm. in diameter in the left lower lobe, communicating by a small aperture with the pleural cavity. There was an old, adherent ante-mortem thrombus in the lower branch of the left pulmonary artery, marked general emphysema, and œdema of the lungs, with bullous emphysema of the apices and anterior borders. A cut surface was uniformly dark grey. There was no enlargement of the hilar nodes. The weight of the left lung was 1 lb. 6½ oz. and of the right lung 15 oz. The small, firm liver and the kidneys showed marked chronic venous congestion. There was fusiform carcinoma of the sigmoid colon without visible secondary deposits. A cortical lipid adenoma 1.2 cm. in diameter was present in each of the adrenals. The heart was of normal size and weighed 10½ oz. There was gross patchy calcification of the femoral arteries.

Microscopical Findings.—The lung showed severe œdema and emphysema, with an old infected infarct in the left lower lobe and abundant intracellular aggregates of iron oxide distributed fairly evenly along the course of the lymphatics. No stainable iron was found in the lungs or hilar nodes. Many of the alveolar walls were outlined by thin double lines of silver impregnation. The internal elastic lamina of most small arteries and veins was heavily impregnated with silver (fig. 2), and there was occasional focal impregnation of the external elastic lamina, but no impregnation of either the internal or external elastic lamina of larger arteries or veins.

Pituitary.—There were small areas of fibrosis in the anterior lobe adjacent to the pars nervosa.

Testis.—There was slight senile fibrillar thickening of the basement membranes of the tubules.

Liver.—There was moderate fat vacuolation at the periphery of the lobules, and granular bile pigment in

the central cells. Sparse aggregates of stainable iron were seen in the liver cells.

Spleen.—There was cellular hyperplasia of the pulp, no stainable iron, and moderate atrophy of the Malpighian bodies.

Other Findings.—There was brown atrophy of the myocardium and muscular wall of the stomach and small gut. The colon showed well differentiated, ulcerated carcinoma with abscess formation in the wall. There were lipoid adenomata in the adrenals, and nothing of note in the pancreas, skin, aorta, or in representative sections throughout the brain.

Case 3.—S. O., a male aged 55 years, had worked as a silver finisher for 26 years. He had occasional attacks of indigestion but no habitual cough. He collapsed suddenly in a tram and died four hours later.

Necropsy Report.—Necropsy showed argyrosiderosis of the lungs, severe emphysema, hypertension, and pontine hæmorrhage. The body was of a well-built man, and there was no wasting and no pigmentation of skin or sclerotics. There were pink gelatinous thymic bodies, each lobe measuring 6 × 2 × 2 cm. The thyroid was moderately enlarged, with pinhead colloid acini. There were no pleural adhesions. The visceral pleura were mottled white and black; both lungs were bulky, with generalized emphysema, especially marked in the anterior borders and in the apices, where bullæ measured 2.5 cm. diameter. The cut surface was a uniform rusty red, and dripped with fluid. The hilar nodes were not enlarged. There was hypertrophy of the left ventricle (2 cm. thick), and slight hypertrophy of the right ventricle (0.6 cm. thick). The rather brown liver had a faint lobular pattern. The convolutions of the brain were slightly flattened. There was dark red gelatinous blood clot in fourth ventricle, maceration of ventral half of pons by recent hæmorrhage, and slight patchy atheroma of cerebral vessels.

Microscopical Findings.—The lungs (fig. 3) showed moderate œdema, severe generalized emphysema, no bronchitis, and no fibrosis. There were rather sparse intracellular iron oxide aggregates in the course of small lymphatics, but more numerous round the large arteries. There were many intra-alveolar phagocytes laden with iron oxide, but no stainable iron. The alveolar walls and internal elastic lamina of the smaller arteries and veins showed abundant linear silver impregnation, but there was no impregnation of the external elastic lamina or of the internal lamina of the larger arteries. The external elastic lamina in one big artery in the hilum was calcified. There were abundant iron oxide deposits, without fibrosis, in the hilar nodes, together with some stainable hæmosiderin.

There was considerable plasma cell, polymorph, and lymphocyte infiltration in the wall of the trachea, and a moderate amount of lymphoid tissue in the thymus.

Some thyroid acini were distended with colloid, but the majority were collapsed, with desquamated lining.

The liver and kidney showed slight arteriolar hypertrophy and there was considerable capillary congestion of the liver. Stainable iron was rare in the liver cells, and absent in the spleen and kidney. The lymphoid tissue in the spleen was atrophied. Tubules in the testis showed early focal arteriolar hyalinization and slight thickening of basement membranes. Sections of the heart, coronary arteries, carotid vessels, aorta, mucous membrane of the cheek, salivary gland, prostate, ureter, pancreas, adrenal, stomach, duodenum, and ileum, all showed nothing of note.

Case 4.—J. C., aged 65, worked as a silver finisher for 50 years and retired six months before his death. He was found dead in bed and had probably been dead for two days. He had never complained of cough or shortness of breath.

Necropsy Report.—Necropsy showed argyrosiderosis of the lungs, moderate diffuse emphysema, and hæmorrhagic pneumonia. The body was of a thin man, but there was no wasting. There was considerable muco-pus in the bronchi and lower part of the trachea, and half a pint of clear fluid in the right pleural cavity. The pleura over both lungs was bluish-black, with scattered small reddish-black plaques, especially posteriorly. There was moderate emphysema of the anterior borders of both lungs, which were markedly congested. The right lower lobe was solid, heavy, and dark red. The right ventricle of the heart was dilatated without hypertrophy. The spleen

TABLE 1

IRON CONTENT OF DRY TISSUES IN GRAMMES OF IRON IN ONE HUNDRED GRAMMES DRY TISSUE *

	Lung	Liver	Spleen	Kidney	Heart	Aorta	Pancreas	Brain
Silver finishers : Case 1 ..	0.72	—	—	—	—	—	—	—
Case 2 ..	0.69	0.11	—	0.16	0.08	—	—	—
Case 3 ..	1.85	0.14	0.14	0.056	0.027	—	0.047	0.046
Case 4 ..	0.71	0.19	0.23	0.12	0.074	0.17	—	—
Normal : Sheldon (1935)	0.22	—	—	—	—	—	—	—
Brückmann and Zondek (1939)	—	Range, 0.07– 0.157 ; mean, 0.108	—	Range, 0.029– 0.054 ; mean, 0.041	—	—	—	—
Cancer Cases : (mean figures) Buchwald and Hudson (1944)	0.102	0.119	0.25	0.037	0.032	—	—	—
Coal miner with pulmon- ary disease Cummins and Slad- den (1930)	High- est, 0.74 ; mean, 0.44	—	—	—	—	—	—	—

* Where there are no entries, no measurements were made.

TABLE 2

SILVER CONTENT OF DRY TISSUES IN GRAMMES OF SILVER IN ONE HUNDRED GRAMMES DRY TISSUE*

	Lung	Liver	Spleen	Heart	Aorta	Kidney
Silver finishers : Case 1 ..	0.06	—	—	—	—	—
Case 2 ..	0.009	0	—	0.0008	0	0
Case 3 ..	0.0013	0.0004	0.021	0	—	—
Case 4 ..	0.06	—	—	—	—	—

* Where there are no entries, no measurements were made.

was about twice the normal size, very soft, and with prominent Malpighian bodies. There was slight venous congestion of the liver.

Microscopical Findings.—The lungs (figs. 4 and 5) showed considerable emphysema, extreme œdema (often hæmorrhagic), but no fibrosis. There were relatively scanty iron oxide aggregates in the course of the smaller lymphatics, and more numerous ones round the large vessels, but no stainable iron. There was widespread silver impregnation of the alveolar walls, patchy impregnation of the internal elastic lamina of the smaller vessels, and considerable thickening of the intima of the pulmonary arterioles.

The heart showed brown atrophy. The splenic pulp was a mass of fused autolysed red cells with a few small granules of stainable iron. There was severe venous congestion of the kidney, with moderate atheroma of the renal vessels and slight patchy cortical ischæmia. Many of the Kupffer cells in the liver were hypertrophied and contained fine black particles. There was considerable golden-brown bile pigment in the liver cells towards the centre of the lobules, and a slight amount of stainable iron along the free borders of many of the liver columns. By dark-ground illumination the black particles in the Kupffer cells appeared shining white.

The iron and silver content of several of the organs of these cases was analysed. The silver was estimated with the use of p-dimethylamino-benzol-rhodanine (B.D.H., 1941). The results are shown in Tables 1 and 2.

Discussion

The uniformity of these four cases establishes the pattern of histological findings in the lungs after inhalation of iron oxide and silver dust. The iron oxide is inert and produces no interstitial fibrosis when taken by phagocytes into the lymphatic system. Case 3 was the only one where the man was exposed to the dust right up to the day of his death. It is significant that the iron content of his lungs was more than double that of the other three, and that his lungs were the only ones that contained great numbers of intra-alveolar phagocytes loaded with iron (fig. 3). His spleen, liver, and kidneys contained no increased iron content, and it seems likely,

therefore, that most of the inhaled iron dust is taken up by phagocytes and eliminated via the sputum. McLaughlin and others (1945) thought that the excess of stainable iron in the liver and spleen of Case 1 might have been derived from the deposits in the lungs, but in the other three cases neither the stainable iron nor the total iron content of the liver and spleen was significantly increased. The only evidence for systemic absorption of the pulmonary iron deposits was the raised iron content of the kidneys in Cases 2 and 4.

Inhaled silver dust obviously has a great affinity for the elastica of the alveolar walls and the smaller pulmonary vessels, and the large amount of the elastic tissue in the lungs probably explains why the silver does not readily gain access to skin and kidneys, which are the usual sites of deposition when argyrosis occurs from ingestion of silver.

All the cases described in this paper had considerable emphysema. The relationship of this to the silver impregnation of the alveolar walls is speculative, for in our experience most Sheffield workmen

have well-marked emphysema at the age of 60. Unfortunately no radiographs were taken of these men's chests during life, but we have little doubt that they would have been similar to those described by McLaughlin and others (1945). Except that one man complained of cough for several years, there was no history of any respiratory disability in these cases.

Summary

Changes in the lungs are described in three new necropsies on silver finishers. The findings were similar to those in the one case previously recorded.

The photographs were taken by Mr. A. W. Collins and Mr. F. B. Battersby. The micro-sections were prepared by Mr. D. Bradey.

REFERENCES

- B.D.H. Book of Organic Reagents (1941). London.
 Brückmann, G., and Zondek, S. G. (1939). *Biochem. J.*, 33, 1845.
 Buchwald, K. W., and Hudson, L. (1944). *Cancer Res.*, 4, 645.
 Cummins, S. L., and Sladden, A. F. (1930). *J. Path. Bact.*, 33, 1095.
 McLaughlin, A. I. G., Barrie, H. J., Grout, J. L. A., and Harding, H. E. (1945). *Lancet*, 1, 337.
 Sheldon, J. H. "Hæmochromatosis" (1935). Oxford University Press, London. Pp. 211.

For Illustrations of this Article, see opposite page

Legends to Illustrations

- FIG. 1.—Section of lung ($\times 36$). Silver impregnation of elastica in artery
- FIG. 2.—Section of lung ($\times 130$). Oedema and emphysema; silver impregnation of elastica of an artery
- FIG. 3.—Section of lung ($\times 130$). Intra-alveolar phagocytes laden with iron oxide; silver impregnation of the elastica of an artery and of alveolar walls
- FIG. 4.—Section of lung ($\times 130$). Emphysema and oedema; silver impregnation of elastica of artery and of alveolar wall; iron oxide limited to interstitial phagocytes
- FIG. 5.—Detail from fig. 4 ($\times 250$)

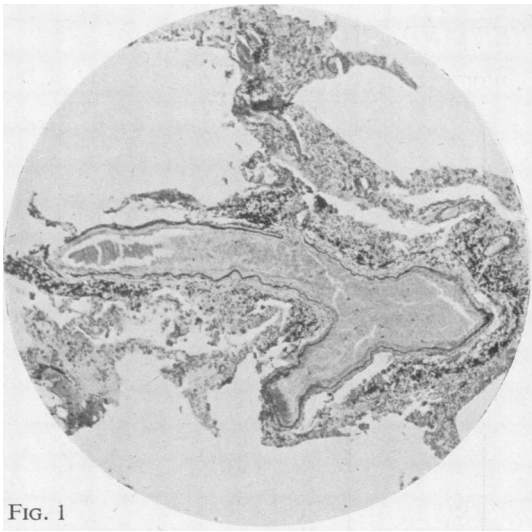


FIG. 1

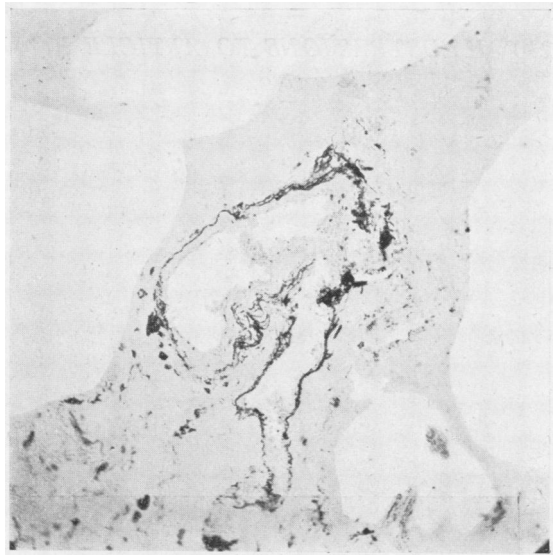


FIG. 2

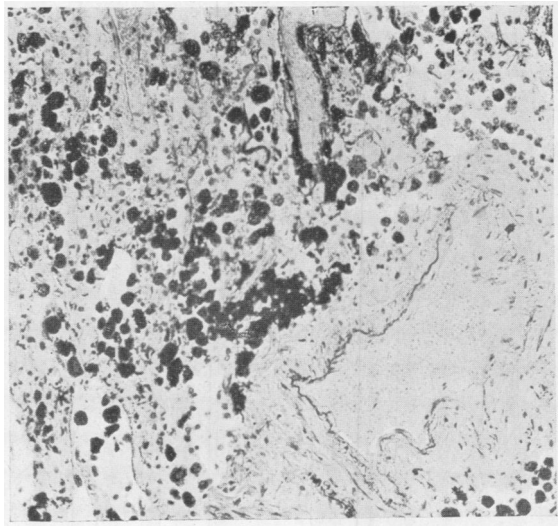


FIG. 4

FIG. 3

FIG. 5

