

ERYTHRO-LEUKÆMIC MYELOSIS IN BENZENE POISONING*

BY

B. GALAVOTTI and F. M. TROISI
Ferrara *Bologna*

(RECEIVED FOR PUBLICATION JANUARY 27, 1950)

The work reported in this paper was an attempt to elucidate the pathology of a case of acute leukæmia in a workman engaged in an operation which exposed him to a notable inhalation of benzene vapour.

Chronic intoxication with benzene is classically regarded as a cause of aplastic anæmia, but the fact that atypical cases arise referable to the same cause has made it necessary to extend the toxicological picture of benzene poisoning and to include in it other forms which differ widely from the example given. Penati and Vigliani (1938) in a study presented at the Eighth International Congress for Industrial Accidents and Occupational Disease at Frankfurt reviewed all the toxicological literature up to that time, and divided the blood findings which appear in workers exposed chronically to the action of benzene into four groups: (1) Cases clinically, hæmatologically, and pathologically typical of aplastic anæmia; (2) cases clinically typical of aplastic anæmia, but showing active hæmopoiesis, especially in the bone marrow, with numerous undifferentiated cells (pseudo-aplastic anæmia); (3) atypical cases of aplastic anæmia with pathological evidence of myeloid hyperplasia or metaplasia resembling leukæmia especially in the spleen and in the liver; and (4) cases of indubitable chronic or acute leukæmia not infrequently of a leukæmic type.

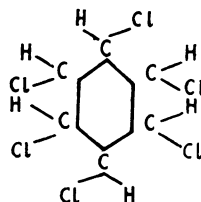
These varieties of myelopathy, of which the leukæmia-like hyperplastic pictures have been experimentally reproduced in several species of animal by means of suitable administration of benzene (Lignac, 1928, 1930, 1932, 1933; Hess, 1935), lead us to attribute to this compound not only the appearance of abnormal blood-cells characterized by regressive changes, but also a hyperplastic action on the hæmopoietic organs which, in constitutionally predisposed subjects, may lead to the development of true leukæmia.

Cases have been described in the literature which present both clinically and pathologically the various aspects of leukæmia: chronic myeloid and lymphatic leukæmia, acute leukæmia, and acute leucopenic-

leukæmia, among which were forms characterized by a blood-picture more or less resembling erythræmia.

The Industrial Background

The disease occurred in a man of 43 years, engaged in a works manufacturing a chemical product, hexachloro-cyclohexane, the γ -isomer of which is a potent agricultural insecticide. Hexachloro-cyclohexane is a derivative of the alicyclic series of hydrocarbons, with the following structure, the γ -isomer being the active one.



The mechanism of its potent insecticidal action is not well understood and three hypotheses, none fully verified, have been put forward. The first attributes the action to the similarity of the structure of the γ -isomer to that of mesoinositol, which is thought to interfere with the inositol metabolism of the insects. (Inositol is hexahydrocyclohexane.) The second view is that the compound decomposes in the insect body yielding HCl. The third theory attributes the potent action to the strong electric moment of its molecule (Slade, 1945; Melander, 1946).

The manufacturing process is carried out in a large plant consisting of a closed circuit. Benzene and chlorine are passed into vessels called "photo-chlorinators", in which, under the action of light, chlorine is added to the benzene molecule with the production of hexachloro-cyclohexane. This compound is then pumped and dried until it emerges from a mill-hopper as a red-brown powder, and is collected in suitable receptacles.

In normal conditions of work there is no possibility of toxic gases emerging into the ambient air: at the point of discharge of the product a special local exhaust conveys the residual gases, mainly benzene, which may still be present, to the external air.

* English translation by M. W. Goldblatt.

Hexachloro-cyclohexane has the property of breaking up into a very fine, impalpable dust which disperses into the working environment with great facility, giving off a characteristic musty odour which sticks persistently to the workers' clothes.

Hazards of the Process

The industrial product is impure and possesses considerable irritant effects on the mucosæ and on the moist skin, probably due to the action of hydrochloric acid still enclosed in the product or developed on contact with sweat or other liquid secretions and also to the action of chloro-benzene (mono-, di-, tri-) always present in significant concentrations (2% to 15%).

This process presented serious health hazards during the period of experimental production and the "teething troubles" of the plant. In that period of four and a half months, the plant personnel, some 15 technicians and workers, were often subjected to the inhalation of benzene and chlorine which could not be avoided because of their unforeseeable, frequent, and easy dispersion, and in spite of all possible preventive measures and the use of appropriate respirators.

Several employers, during that time, drew attention to symptoms of unwellness attributable to protracted exposure to benzene vapour: for example, gastric upsets, migrainous headache, muscular weakness, and not infrequently a condition resembling alcoholic drunkenness following the accidental inhalation of high concentrations of vapour.

Case Report

Among these 15 employees was the worker who died from acute leukaemia. The other workers in the team have also presented signs of blood disorders pointing to a toxic action in the hæmopoietic system produced by benzene, e.g., hyperchromic anæmia, leucopenia with neutropenia, and, in some cases, relative lymphocytosis accompanied by some young cells of the granulocytic series.

The worker in question was highly skilled and had been on the plant from the start, including the four-and-a-half month period of plant improvement. He remained in the department after the process had been brought into normal function. Thus, during the experimental period, he was subject, as were his work mates, to frequent inhalations of benzene and chlorine and later, when the process had become established, he continued to work for about a month in an environment where benzene vapour was present although now in small quantity. He therefore had had five and a half months in greater or less contact with benzene vapour. He developed aggravated symptoms: asthenia, headache, vertigo, gingivitis, and progressive loss of weight, which he had to a lesser degree already experienced for some time. He was removed from his job, but his condition grew rapidly

worse and he took to bed with fever; about a week later he was admitted to hospital.

Clinical Features.—His family and personal history was of no significance. Objective examination showed a fair state of nutrition, a pale-pink complexion, pallid skin, simple gingivitis, pale oro-pharynx, normal tonsils, a marked fœter from the mouth, and slight polyadenitis of lymph glands. A slight blowing systolic murmur was found in the heart. The abdomen appeared swollen; the liver was enlarged and tender extending two finger-breadths below the costal margin. The spleen was also enlarged and markedly tender, two and a half finger-breadths below the costal margin. Other organs showed no points of interest. Faint albuminuria was noted. Wassermann and Widal-Wright reactions were negative.

Blood findings were as follows:

Hb.: 45%.

R.B.C.: 3,600,000 (2% basophil erythroblasts; 1% polychromatophils; 3% orthochromic cells).

W.B.C.: 34,200 (19% neutrophils; 2% eosinophils; 1% basophils; 14% lymphocytes; 1% monocytes; 6% polymorphocytes; 2% monoblasts; 14% metamyelocytes; 2% promyelocytes; 3% myeloblasts; 26% hæmocytoblasts; 1% plasma cells; 1% Rieder cells; 8% endothelial cells.).

The temperature remained at about 100.4° but showed slight morning remissions and reached above 102.2° in the evenings. The patient went progressively downhill, treatment being of no avail, and, on the twentieth day after entering hospital, he died.

Three days before death the following data were obtained: Serum protein level, 4.60%; MacLagan test, negative; Takata-Hara test, negative; serum bilirubin level, 4.5 mg. % (direct 1.97—indirect 2.53); non-protein nitrogen level, 130 mg. %.

The urine showed traces of albumin, abundant urobilin, urea (0.64%), an occasional red cell, and fairly numerous leucocytes in the sediment.

Bleeding time was 32 minutes and coagulation time 10 minutes. The loop test, moderately positive (+ + - -) showed deficient clot retraction.

Blood examination carried out four days before death showed:

R.B.C.: 1,870,000 (18% basophil erythroblasts, 2% in mitosis; 34% polychromatophils; 24% orthochromic cells; 9% proerythroblasts).

W.B.C.: 175,000 (17% hæmocytoblasts, and a smallish number of immature elements of myeloid series).

Hb.: 32%. C.I.: 0.86.

Such findings pointed to the need for a sternal puncture which gave the following results from a count of 500 cells:

| | | | |
|----------------|-----|------------------------|-----|
| Lymphocytes | 7 | Hæmocytoblasts | 6 |
| Granulocytes | 5.5 | Türk cells | 0.5 |
| Monocytes | 1 | Endothelial cells | 2 |
| Lymphoblasts | 0.5 | Basophil erythroblasts | 22 |
| Metamyelocytes | 4.5 | Polychromatophils | 30 |
| Myelocytes | 4.5 | Orthochromic cells | 6 |
| Promyelocytes | 0.5 | Proerythroblasts | 4.5 |
| Myeloblasts | 0.5 | Mitosing erythroblasts | 5 |

White series
Red series = 0.33

At necropsy the naked eye findings were as follows :

Liver.—Enlarged (4,670 g.). The viscus was harder than normal, the capsule smooth, and the cut surface showed lobular markings; the colour was reddish-yellow and turbid.

Spleen.—Much enlarged (1,250 g.). The viscus was harder than normal, the capsule somewhat thickened and red-grey in colour; on the convex surface a few small infarcts. On section the organ appeared uniformly compact, rather dry, and with evident hyperplasia of the follicles, the pulp, and the reticulum.

Lymphatic Glands.—Some lymph glands were somewhat enlarged. The cut surface appeared pink in colour, homogeneous, somewhat soft, and a little juicy.

Bone-marrow.—Bone-marrow of diaphysis of the femur was abundant, reddish in colour, compact, and rather dry.

Lungs.—Broncho-pneumonia at right base, and fatty infiltration of heart and nephrosis were also found.

Microscopic examination of the liver, spleen, lymph glands, and bone marrow showed marked myelo-erythropoietic activity.

Discussion

On the basis of the clinical, laboratory, and pathological findings there can be no doubt that this case must be classified as an erythro-leukæmic type of anæmia.

Here the initial blood picture was that of a leukæmia of hæmocytoblastic character later to assume the morphological characters of a mixed-type anæmia in which primitive cellular types were accompanied, on the one hand, by a moderate number of immature elements of the myeloid series, and on the other, by a considerable proportion of immature elements of the red series, until a leuco-erythrocytic ratio of 0.33 was reached. Regarded then as a mixed type, it would seem from its particular characteristics of special importance from the ætiological and pathogenetic points of view. Thus, it does not appear easy to escape an ætiological relation between the work in which the patient was engaged and the blood disease which led to his death. Such a view is supported by the finding that a short exposure to benzene vapour, for example, in the case reported by Loeper, Fabre, and Boreau, 1946, which was in contact with benzene for only six months, a period approximately the same as that in our case, can be the determining factor in such a type of anæmia. Moreover, the time of action of the agent, regarded as the toxic cause of the disease, must be assessed with great care (unless the period was extremely short), bearing

in mind the fundamental fact, admitted by all writers on the subject, that the lighting up of such types of blood disorder requires a particular constitutional predisposition.

Since, in addition to the inhalation of benzene vapour, the process renders possible that of chlorine and of the finely divided, powdered hexachloro-cyclohexane, these also might be suspected in the ætiology of the disease. But hexachloro-cyclohexane has up till now not been found to be toxic to man and the syndrome of chronic poisoning is manifestly of an entirely different kind from that described. Only benzene can be seriously considered as the possible ætiological factor, and its marked toxic effects are well demonstrated not only in the fatal case described but also in the symptoms experienced by the other workers on the process and their hæmatological pictures.

As benzene is recognized as a toxic cause of leukæmia the proposed attribution to benzene of the form of blood disorder manifested in the present case appears to be reasonable in view of its erythro-leukæmic character. Examination of cases reported in the literature after that observed by Delore and Borgomano (1928) leads to the view that benzene leukæmia shows diverse clinical aspects and the reactive manifestations of the hæmopoietic tissues are very variable. Careful evaluation, however, of the lesions of the hæmopoietic organs produced by benzene suggests that, starting from the typical picture of aplastic anæmia, a whole series of intermediate blood abnormalities leading ultimately to leukæmia is found. Thus from the varied blood pictures emanating from the toxic action of benzene, the erythro-leukæmic myelosis of our case may be held to result from it and to have developed a particular aspect as a consequence. What may be the cause of the diversity of toxic effects produced by benzene, possibly provocative of aplasia or a proliferative process in the bone marrow, and what constitutes its mode of action are entirely matters of opinion and may give rise to many hypotheses but facts are not yet available.

REFERENCES

- Delore, P., and Borgomano, C. (1928). *J. Med. Lyon*, 9, 227.
 Hess, W. (1935). *Frankf. Z. Pathol.*, 47, 522.
 Lignac, G. O. E. (1933). *Klin. Wschr.*, 12, 109.
 — (1928). "Krankheitsforschung", 6, 97; (1930), 8, 391; (1932), 9, 403.
 Loeper, M., Fabre, R., and Boreau (Mme.) (1946). *Bull. Acad. Méd., Paris*, 130, 706.
 Melander, B. (1946). *Svensk. kem. Tidskr.*, 58, 231.
 Penati, F., and Vigliani, E. C. (1938). VIII Congr. Internaz. per gli Infortuni e le Malattie del Lavoro, in "Rassegna di Medicina Industriale", 9, 345.
 Slade, R. E. (1945). *Endeavour*, 4, 148.