

## Images in Infectious Diseases

# Rare Combination of Pneumothorax, Pneumomediastinum and Pneumopericardium and a Bronchopleural Fistula in Covid-19

Ewe Jin Koh<sup>[1]</sup> and Ming Lee Chin<sup>[2]</sup>

[1]. Hospital Taiping, Department of Internal Medicine, Malaysia.

[2]. Hospital Taiping, Department of Medicine-Paediatrics, Malaysia.

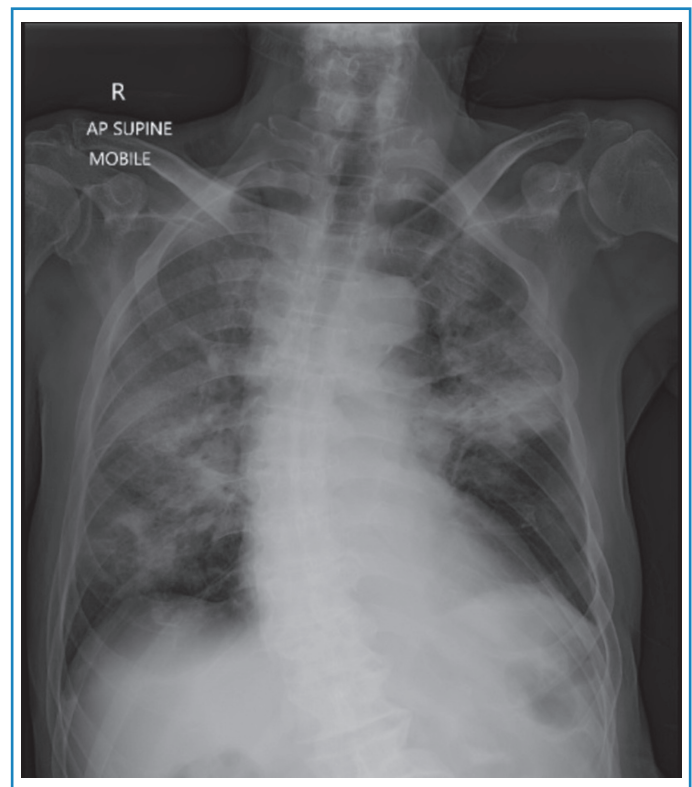
A 78-year-old man presented with a one-week history of worsening shortness of breath and cough. On examination, he had obvious respiratory distress and was profoundly hypoxic, requiring high-flow oxygen. Chest radiography revealed severe consolidation in both lung fields (**Figure 1**).

Covid-19 was confirmed by SARS-CoV-2 detection in nasopharyngeal and oropharyngeal swab samples using RT-PCR. Intravenous corticosteroids, immune modulators, and therapeutic anticoagulants were initiated. However, the patient required ongoing high-flow oxygen to maintain oxygen saturation.

Computed tomography (CT) of the thorax revealed ground-glass opacities in both lung fields with a right pneumothorax, pneumopericardium, and pneumomediastinum, and a bronchopleural fistula (**Figures 2 and 3**). The patient was treated conservatively owing to his frailty. He was discharged from hospital to palliative care.

Bronchopleural fistulas, which cause spontaneous pneumothorax, pneumomediastinum, and pneumopericardium, are rare complications of Covid-19. They can occur because of the overwhelming cytokine storm leading to alveolar rupture and air dissects through the peribronchial vascular sheath into the mediastinum and pericardium<sup>1</sup>.

The patient developed a spontaneous pneumothorax, pneumomediastinum, and pneumopericardium, despite not receiving positive pressure ventilation. To our knowledge this triple combination has not been reported previously in Covid-19.



**FIGURE 1:** Chest radiograph on admission showing bilateral diffuse ground-glass opacities.

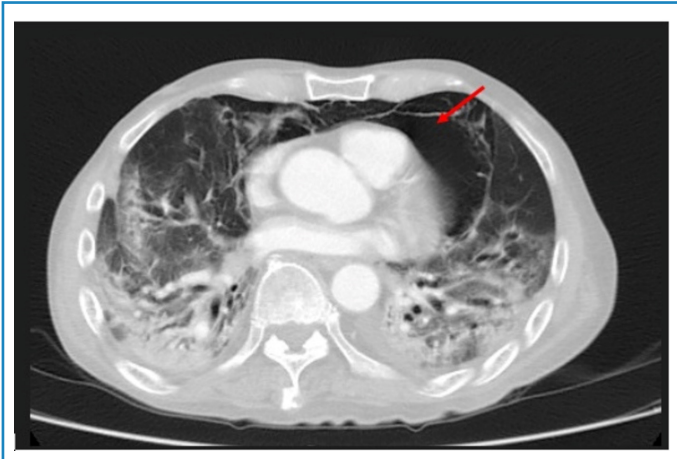**Corresponding author:** Dr. Ewe Jin Koh. **e-mail:** ewejinkoh@gmail.com

**Authors' contribution:** EJK: Conception and design of the study, Acquisition of data EJK, MLC; Conception and design of the study, Analysis and interpretation of data, Final approval of the version to be submitted; EJK, MLC: Conception and design of the study, Acquisition of data, Drafting the article, Final approval of the version to be submitted

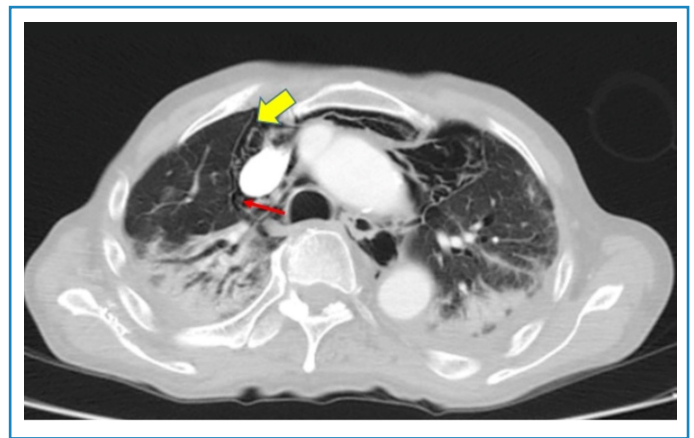
**Conflict of Interest:** None.

**Financial Support:** None declared.

**Received** 20 April 2023 • **Accepted** 31 May 2023



**FIGURE 2:** Computed tomography (CT) of the thorax with pneumomediastinum and pneumopericardium shown by the red arrow.



**FIGURE 3:** Computed tomography (CT) of the thorax with a small right apical pneumothorax, shown by a yellow arrow. The red arrow shows a bronchopleural fistula.

It is important to recognize that they may occur in the absence of positive pressure ventilation.

Currently, there are no official guidelines for managing these complications in the context of Covid-19. Several patients have been treated conservatively with good outcomes<sup>2</sup>; however some patients require surgical intervention<sup>3</sup>. Further reports are required to obtain further evidence on the management of these complications.

#### ACKNOWLEDGMENTS

We express our deepest gratitude to the Radiologists of Taiping Hospital who were involved in the reporting of the CT images. We would also like to thank Dr Chee Yik Chang, Infectious Diseases Fellow from Monash Medical Centre, Melbourne on providing expertise and for the final proof-reading of this article.

#### REFERENCES

1. Menter T, Haslbauer JD, Nienhold R, Savic S, Hopfer H, Deigendesch N, et al. Postmortem examination of COVID-19 patients reveals diffuse alveolar damage with severe capillary congestion and variegated findings in lungs and other organs suggesting vascular dysfunction. *Histopathology*. 2020;77(2):198–209. Available from: <http://dx.doi.org/10.1111/his.14134>
2. Chang CY. Pneumomediastinum in a patient with severe Covid-19 pneumonia. *Rev Soc Bras Med Trop*. 2021;54:e03962021. Available from: <http://dx.doi.org/10.1590/0037-8682-0396-2021>
3. Talon A, Arif MZ, Mohamed H, Khokar A, Saeed AI. Bronchopleural fistula as a complication in a COVID-19 patient managed with endobronchial valves. *J Investig Med High Impact Case Rep*. 2021;9:23247096211013215. Available from: <http://dx.doi.org/10.1177/23247096211013215>