

Effect of preoperative posture and binocular occlusion on retinal detachment

J. S. LEAN, M. MAHMOOD, R. MANNA, AND A. H. CHIGNELL

From the Department of Ophthalmology, St Thomas's Hospital, London SE1 7EH

SUMMARY In an unselected series of retinal detachments a 24-hour period of binocular occlusion and posture with a retinal hole dependent produces some resolution of subretinal fluid in 13% of cases. If only patients with acute, freely mobile detachments and retinal holes above the horizontal meridian were selected the proportion of detachments showing some resolution rose to 30%. In 8% of cases a paradoxical response occurred, the detachment increasing in depth or extending to involve an additional area of retina.

The use of a period of preoperative posture and binocular occlusion is widely practised in retinal detachment surgery, but the exact indications and expectations for this manoeuvre are not well defined. Binocular occlusion decreases the frequency and amplitude of eye movements (Adams, *et al.*, 1973), and by this effect in combination with posture with the retinal hole dependent it is hoped to reduce the size of the detachment or at least prevent its further spread.

If this is possible, it may be helpful in the following ways: prevent macular detachment in cases where there is only peripheral detachment; enable more accurate localisation of a retinal hole by reducing the distance between the hole and the pigment epithelium; reveal a retinal hole hidden behind folds of ballooned retinal detachment; provide a view of the optic disc concealed by folds of detached retina; and settle a vitreous haemorrhage by allowing blood diffusely distributed in the retrohyaloid space to sediment inferiorly.

The resolution of subretinal fluid (SRF) that may occur after a period of bed rest is almost certainly not true reabsorption of SRF. Posture with the retinal hole dependent allows the retina to settle under the effects of gravity through the retrovitreal fluid, so that fluid which was initially subretinal becomes preretinal by transfer through the retinal hole (Foulds, 1975) (Fig. 1).

Apart from a recent review of the role of posture and binocular occlusion in the treatment of acute vitreous haemorrhage (Lincoff *et al.*, 1976) there have been a few recent studies of this form of

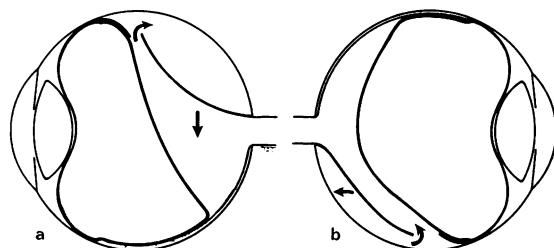


Fig. 1 (a) During the development of a ballooned superior retinal detachment the retina descends through the retrovitreal fluid. This fluid redistributes through the retinal tear from a preretinal to a postretinal position. (b) Posture of the patient with the retinal hole dependent allows reposition of the retina and transfer of fluid in the reverse direction

management in the context of current clinical practice. By means of fixation sutures in the medial and inferior recti it is possible to obtain some retinal flattening in 85% of patients (Alvarez and Rosengren, 1977). Longer periods of rest and posture have a similarly high rate of success (Hoffman and Hanselmayer, 1973). However, such extensive preoperative preparation is rarely used in Great Britain, and this paper reports a prospective series of retinal detachments managed with a short period of preoperative posture. We undertook the study to assess the potential usefulness of this manoeuvre and formulate prognostic indicators for its successful application.

Materials and methods

A total of 100 patients were entered in this study. They were essentially consecutive, patients only

Correspondence to Mr J. S. Lean, FRCS, Moorfields Eye Hospital, City Road, London EC1V 2PD.

being exempted if an increased risk of thromboembolism precluded a period of immobility. For each patient the period of posture and binocular occlusion comprised the 24 hours immediately prior to surgery. The detachment was documented at the start of the period of bed rest and again just before operation. At the first examination 3 assessments were made: the topography of the detachment was documented and the depth of subretinal fluid was estimated in each retinal quadrant by scleral indentation and binocular indirect ophthalmoscopy. The depth of subretinal fluid was graded as; 0=flat; 1=neuroepithelium and pigment epithelium easily opposed by gentle scleral pressure with scleral indentation; 2=just appposable with scleral indentation; 3=unappposable despite scleral indentation. Thirdly the retinal mobility was assessed according to criteria previously described (Chignell, 1977). The patient was then positioned with the retinal hole dependent. If there were multiple and widely separated retinal holes, an attempt was made to decide the primary tear on the basis of the rules of fluid distribution (Lincoff and Gieser, 1971), and the patient was positioned appropriately. Both eyes of the patient were padded and treated with mydriatics and cycloplegics. The topography of the detachment and the depth of subretinal fluid in each retinal quadrant was then reassessed before starting surgery.

Results

CHANGE IN SRF

After 24 hours of posture and binocular occlusion 21 patients showed an apparent change in either the volume or distribution of SRF (Table 1).

In 13 patients the retina appeared to flatten. In another 4 patients the volume of subretinal fluid appeared unchanged but the topography of the detachment altered, so that an additional area of retina became detached. In 4 patients the volume of subretinal fluid appeared to increase and the detachment became more bullous. In 79 patients there was no detectable change. The type of retinal

Table 1 *Change in SRF in 100 cases of retinal detachment managed with 24 hours of posture and binocular occlusion*

Resolution	13
Redistribution	4
Increase	4
No change	79
Total	100

Table 2 *The behaviour of SRF related to the type of retinal hole in the 100 patients in this series*

	<i>Alteration in volume of SRF</i>	<i>No alteration in volume of SRF</i>	<i>Total</i>
U-tear/round hole	15	64	79
Dialysis	—	13	13
Giant tear	1	—	1
Macula hole	—	1	1
No tear found	1	5	6
Total	17	83	100

Table 3 *The behaviour of SRF related to the position of the retinal hole in 79 patients with identified equatorial retinal holes*

	<i>Alteration in volume of SRF</i>	<i>No alteration in volume of SRF</i>	<i>Total</i>
Upper 2 quadrants	13	32	45
Lower 2 quadrants	1	25	26
Both quadrants	1	7	8
Total	15	64	79

hole and its position were then analysed, as it seemed probable that these would influence the response to occlusion and posture.

TYPE OF RETINAL HOLE

In 17 patients there was an apparent alteration in the volume of the subretinal fluid. The distribution of types of retinal hole in the total series is given in Table 2.

Apart from 1 detachment in which no hole could be found, clinically detectable change in the volume of SRF occurred only in the presence of a definable equatorial or pre-equatorial retinal hole. The period of posture had no effect on any of the 13 detachments in this series owing to dialyses.

POSITION OF RETINAL HOLE

The position of the retinal hole was found to be crucial in predicting the behaviour of the detachment. Apart from those detachments caused by a dialysis, a giant tear, or those in which no hole could be found, there were 79 detachments with identified equatorial retinal holes. The response of detachments with superior tears is compared to those with inferior tears in Table 3.

Thirteen (29%) of patients with a superior retinal hole showed an alteration in the volume of subretinal fluid. Eleven (25%) patients showed a

decrease, and 2 showed an increase in the volume of SRF. An alteration in SRF, in both cases an increase in volume, occurred in only 1 case with an inferior hole and similarly 1 case with both superior and inferior holes. The 45 detachments with definable holes in the upper half of the retina therefore form the group in which change in SRF, either an increase or a decrease, can be expected. Three further factors were then analysed in this group alone:

Nature of retinal hole. We considered that a round hole where vitreous traction had been completely relieved by detachment of the operculum might be expected to settle more readily than a horseshoe tear where continuing though reduced traction on the operculum might limit its ability to gravitate through the retrovitreal fluid.

Refraction. We expected that the state of the vitreous gel and the size of the potential retrohyaloid space would affect the response.

Retinal mobility. We considered that the freedom of the retina to gravitate through the retrovitreal fluid would be adversely affected by retinal immobility.

NATURE OF RETINAL HOLE

The behaviour of detachments caused by horseshoe tears is compared to those which are due to round holes in Table 4. Five (56%) of those detachments caused by round holes showed an alteration in the volume of subretinal fluid, whereas 7 (27%) of those due to horseshoe tears showed an alteration in the volume of subretinal fluid. The total numbers are small, and this difference is not statistically significant ($0.10 > P > 0.05$), but it suggests that residual continuing traction on the retinal hole does not materially influence the volume of subretinal fluid.

REFRACTION

The distribution of refractive states within the group is given in Table 5. The difference in response of the myopic group 7 (29%) compared to the

Table 4 *The behaviour of SRF related to the type of retinal hole in 45 patients with retinal holes in the upper 2 quadrants of the retina*

	Alteration in volume of SRF	No alteration in volume of SRF	Total
Round holes	5	4	9
Horseshoe tears	7	21	28
Mixed	1	7	8
Total	13	32	45

Table 5 *The behaviour of SRF related to the refractive status in 45 patients with retinal holes in the upper 2 quadrants of the retina*

	Alteration in volume of SRF	No alteration in volume of SRF	Total
Emmetropia	2	10	12
Myopia	7	17	24
Hypermetropia	3	5	8
Aphakia	1	0	1
Total	13	32	45

Table 6 *The behaviour of SRF related to the retinal mobility in 45 patients with retinal holes in the upper 2 quadrants of the retina*

	Alteration in volume of SRF	No alteration in volume of SRF	Total
Mobile	13	24	37
Some mobility	—	7	7
Immobile	—	1	1
Total	13	32	45

combined emmetropic and hypermetropic group 5 (25%) is not significant ($P > 0.1$). Therefore refraction appeared not to be important, though the state of aphakia could not be assessed properly.

RETINAL MOBILITY

The presence of a freely mobile retina was found to be crucial to the response of posture (Table 6). Thus, all the detachments in which an alteration in the volume of SRF took place were freely mobile, but even with this favourable prognostic factor only 13 (35%) responded; 11 (30%) showed resolution.

INCREASED AREA OF DETACHMENT

Four of the 100 detachments in this series showed no apparent change in volume of subretinal fluid, but during the period of preoperative posture an increased area of the retina became detached. These 4 patients formed a heterogeneous group, but 3 of the 4 patients had upper-half retinal holes with freely mobile retinæ. In the remaining patient no hole was detected, but the retina appeared to be freely mobile.

Discussion

In 13 cases of this unselected series of 100 retinal detachments a 24-hour period of preoperative posture and binocular occlusion induced some

resolution of the subretinal fluid. In all these cases this facilitated localisation of the retinal holes at the time of surgery. In 1 case judged preoperatively suitable for surgical treatment involving drainage of subretinal fluid the reduction of SRF was sufficient to allow the optic disc to be viewed at surgery, and a nondrainage operation was performed. In 4 patients the detachment increased in area, and in an additional 4 patients an increase in the volume of subretinal fluid was found, but in none of these cases did this materially affect the outcome.

The disappointingly low number of positive responses to treatment in this series reflects the unselected nature of the detachments. The favourable prognostic factors which we have noted are a retinal hole above the horizontal meridian and a freely mobile detachment. If only detachments with these characteristics are compared, the proportion of patients showing resolution increases to 30%. No correlation was found with the type of retinal hole, and this suggests that continuing residual vitreous traction is not a major factor preventing resolution of SRF. However, larger numbers of patients are needed to confirm or refute this.

The failure of both inferior holes and dialyses to respond to preoperative bed rest suggests that the flattening of a detachment when it occurs is due to a gravitational settling of the retina and not true reabsorption of SRF. With inferior holes the detachment has already developed despite the effect of gravity tending to reposition the retina. In a dialysis the vitreous base remains attached to the posterior edge of the retinal hole (Scott, 1977); no passage exists for transfer of fluid from the subretinal to the preretinal space, and the retina is thus unable to gravitate through the retrovitreal fluid by displacing fluid from one compartment to another. Perhaps this explains the universally poor prognosis for bed rest with this type of retinal hole.

The results of this study crystallise the day-to-day impression of retinal surgeons that acute, freely mobile retinal detachments with holes above the horizontal meridian have the most favourable prognosis for response to preoperative posture. Furthermore it is important to recognise that in this group a small proportion will increase in depth. In a further small proportion of cases,

although the volume of subretinal fluid appears unchanged, a larger area of retina becomes detached. The explanation of this paradoxical increase in either the depth of subretinal fluid or area of detachment is not clear. It probably represents a failure of the patient to maintain correct posture and confirms the labile nature of this type of detachment. Clinically it cautions against assuming axiomatically that a retinal detachment will not extend once the patient is put to bed.

However, even with these favourable prognostic indications only 30% of detachments were improved. Confirmation of this proportion has been obtained in a further group of patients. Using the criteria derived from this study we have continued to advise bed rest only for those patients with freely mobile upper-half detachments. Thirty-one of the subsequent 150 detachments fulfilled these requirements, of which 8 (26%) responded to a short period of bed rest.

We thank Mr T. Tarrant of the Audio-Visual Department, Institute of Ophthalmology, Judd Street, London, for preparing the illustration, and Mrs Margaret Grice, Miss Sue Paterson, and Miss Denise Bryant for secretarial assistance, in part supplied by the Prevention of Blindness Fund.

References

- Adams, G. L., Yeer, D., Hahn, P. M., and Pearlman, J. T. (1973). Effect of binocular and monocular patching on eye movements. *Archives of Ophthalmology*, **90**, 117-120.
- Algere, P., and Rosengren, B. (1977). Active immobilisation of the eye in retinal detachment. *Modern Problems in Ophthalmology*, **18**, 286-291.
- Chignell, A. H. (1977). Retinal mobility and retinal detachment surgery. *British Journal of Ophthalmology*, **61**, 446-449.
- Foulds, W. S. (1975). Aetiology of retinal detachment. *Transactions of the Ophthalmological Societies of the United Kingdom*, **95**, 118-127.
- Hoffman, H., and Hanselmayer, H. (1973). Retinal detachment—extent and frequency of re-attachment through pre-operative immobilisation. *Klinische Monatsblätter für Augenheilkunde*, **162**, 178-185.
- Lincoff, H. A., and Gieser, R. (1971). Finding the retinal hole. *Archives of Ophthalmology*, **85**, 565-569.
- Lincoff, H. A., Kreissig, I., and Wolkstein, M. (1976). Acute vitreous haemorrhage: a Clinical Report. *British Journal of Ophthalmology*, **60**, 454-458.
- Scott, J. D. (1977). Retinal dialysis. *Transactions of the Ophthalmological Societies of the United Kingdom*, **97**, 33-35.