

Autosomal dominant exudative vitreoretinopathy

R. R. OBER, A. C. BIRD, A. M. HAMILTON, AND K. SEHMI

From the Institute of Ophthalmology, Moorfields Eye Hospital, City Road, London

SUMMARY Twelve affected members from 3 families with autosomal dominant exudative vitreoretinopathy were examined, and the following conclusions were drawn: (1) There is great variability in the phenotypic expression of the abnormal gene, such that many patients have very mild disease which can be detected with certainty only by fluorescein angiography. (2) Gene penetrance is close to 100%. (3) Progress of fundus changes and visual threat is rare after 20 years of age.

Familial exudative vitreoretinopathy was first reported by Criswick and Schepens¹ in several members of 2 families with abnormalities of the retina and vitreous which closely simulated retrolental fibroplasia, but in whom there was no history of prematurity or oxygen administration during the neonatal period. The disease was described as bilateral and slowly progressive, with a familial incidence, but of uncertain inheritance pattern. Gow and Oliver² expanded the original observations, identified autosomal dominant inheritance, and divided the clinical course into 3 stages. The fluorescein angiographic findings in familial exudative vitreoretinopathy were first described by Canny and Oliver.³ They demonstrated closure of the peripheral retinal vasculature associated with elevated, temporal fibrovascular masses, and stressed again the similarity between this entity and retrolental fibroplasia.

This report describes the fundus and fluorescein angiographic findings in 12 affected members of 3 families with autosomal dominant exudative vitreoretinopathy. In contrast to the impression given by previous reports, the disease may be asymptomatic and nonprogressive, and the clinical abnormalities difficult to identify.

Case reports

PEDIGREE 1 (Fig. 1)

Case 1 (pedigree 1, II-2). A 12-year-old Chinese female was the product of a normal gestation and delivery, and received no oxygen therapy. At 2 years of age extensive peripheral traction retinal

Correspondence to Richard R. Ober, MD, Department of Ophthalmology, University of Southern California, Estelle Doheny Eye Foundation, 1355 San Pablo Street, Los Angeles, California 90033, USA.

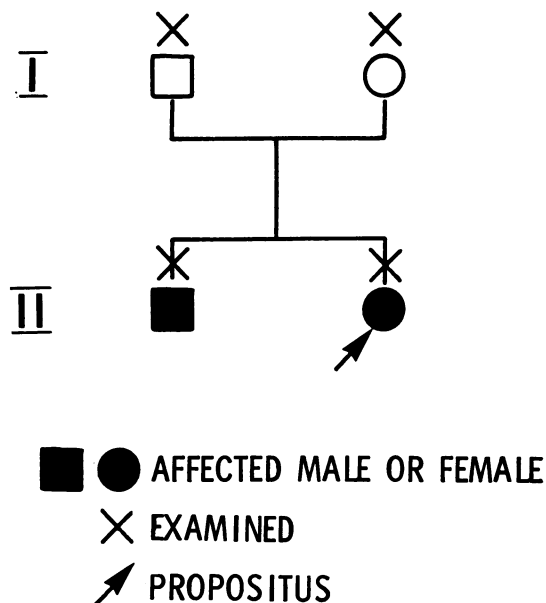


Fig. 1 Pedigree 1.

detachment was observed in the left eye. Exudates, microaneurysms, and 'abnormal vessels' were identified in the temporal periphery of the right eye, and a diagnosis of bilateral congenital retinal vascular malformations was made. The right eye remained stable until the age of 3½ years, when reduction of vision was noted. Macular exudates were associated with an angiomatous lesion and traction retinal detachment in the temporal retinal periphery. Surgery was undertaken in Australia (G. Crock), and after the procedure the retina became reattached, and vision with the right eye improved and has subsequently remained unchanged.

The patient was first seen at Moorfields Eye

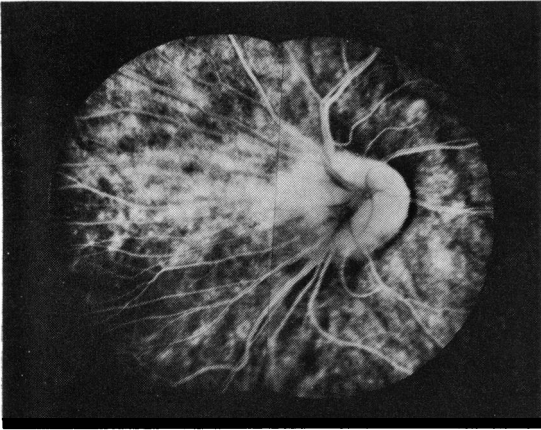


Fig. 2 Fluorescein angiogram of case 1, showing distortion of the right eye central retinal vessels and leakage into the macula area.

Hospital on 10 October 1977. Visual acuity was 6/9 (20/30) with the right eye and no light perception with the left. The left eye was soft and shrunken, with a cataract and band keratopathy preventing a view of the fundus. The right anterior segment was normal. Fundus examination of the right eye revealed temporal dragging of the posterior retina, chorioretinal scarring and pigmentation in the area of the previous retinal surgery, and retinal vessel closure anterior to the equator in all quadrants with exudates nasally. Fluorescein angiography of the right eye revealed leakage of dye from the distorted

retinal vessels in the posterior pole and at the temporal margin of the optic disc (Fig. 2). In the pre-equatorial retina the retinal vessels were increased in number, straight, and radial, and the retinal vessels ceased abruptly anterior to the equator. There was dye leakage from these vessels.

Case 2 (pedigree 1, II-1). The 17-year-old brother of case 1 was born at term and received no oxygen therapy. He was myopic, but had no other ocular symptoms and was otherwise healthy. Visual acuity was 6/5 (20/15) with the right eye (-5.25 d.sph. -3.50 d.cyl. axis 175°), and 6/5 (20/15) with the left eye (-5.00 d.sph. -2.00 d.cyl. axis 05°). The anterior segments of both eyes were normal. Fundus examination of the right eye showed moderate temporal dragging of the optic disc and macula. The peripheral vessels in all quadrants were more numerous than normal, straight, and radially orientated. The vessels ended abruptly in the pre-equatorial region with retinal nonperfusion anterior to this zone. At 10 o'clock, at the margin of vessel closure, forward vessels were associated with whitish exudates and subretinal fibrosis. The changes in the left eye were similar but less severe. Fluorescein angiography of the right eye showed an increase in the number and calibre of retinal vessels anterior to the equator; the vessels were straightened and ceased abruptly forming a scalloped border. Diffuse dye leakage occurred from the vessels posterior to the marginal closure, and prominent leakage of dye occurred from the neovascularisation in the temporal periphery (Fig. 3). The left eye

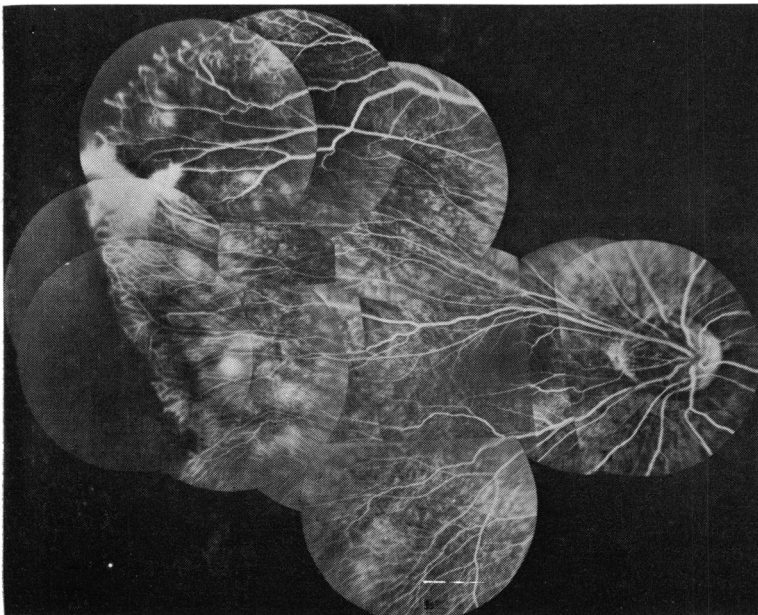


Fig. 3 Fluorescein angiogram of the right eye of case 2, showing distortion of the retinal vessels and peripheral vessel closure, with diffuse leakage from the peripheral retinal vessels and from the forward vessels.

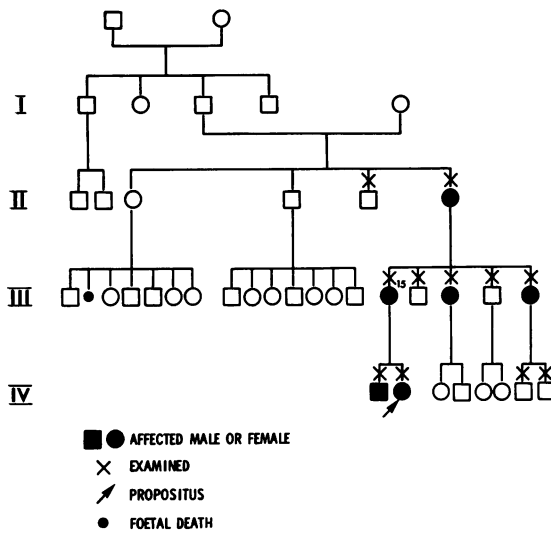


Fig. 4 Pedigree 2.

showed similar but milder changes in the peripheral retinal vasculature.

One eye of both parents was examined and no abnormalities were identified, but fluorescein angiography was not undertaken.

PEDIGREE 2 (Fig. 4)

Case 3 (pedigree 2, IV-2). A 17-year-old white female was first seen at the age of 3 years with a 3-week history of right exotropia. The patient was born at term at home and weighed 3409 g ($7\frac{1}{2}$ lb). She was otherwise healthy. Initial examination revealed widespread peripheral traction retinal detachment, with vitreous fibrosis in the right eye and glial tissue on the left optic disc. A congenital vascular malformation or endophthalmitis was considered a possible cause for these changes. Two and a half years later progression of the changes in the left eye was recorded; at that time vision was finger counting with the left eye, and there were dense organised vitreous bands with extensive retinal detachment. Vision was 6/60 (20/200) with the right eye, and the fundus findings were unchanged. The patient was last examined on 3 April 1978, and the visual acuity was 6/60 (20/200) with the right eye ($-200+1.50$ axis 100°), and no light perception with the left. The right anterior segment was normal. The right vitreous base was organised, giving rise to circumferential traction and detachment of the peripheral retina. The fibrous tissue was inserted into the optic disc with forward traction on the central retinal vessels. The left eye was soft and shrunken, and the fundus was not seen. Fluorescein angiography was not performed.

There was no family history of eye disease, but 10 other members of the family were examined; all were born at term with normal birth weight, and none was given oxygen in the neonatal period. Unless otherwise stated, none had ocular symptoms, abnormalities were limited to the fundi, and the visual acuity was 6/6 (20/20) or better with each eye.

Case 4 (pedigree 2, IV-1; 22-year-old brother of the propositus). The fundi appeared normal except for an area in the left temporal periphery, where the retinal vessels appeared more numerous and straightened. Fluorescein angiography of the left eye in the temporal periphery showed an increased number of straight, parallel vessels that ended abruptly anterior to the equator in a scalloped border; fluorescein leakage occurred from a few of those vessels. Similar vascular changes were seen in the temporal retina of the right eye.

Case 5 (pedigree 2, III-15; 40-year-old mother of the propositus). The posterior retinal vessels in the right eye showed mild temporal dragging (Fig. 5b). In the temporal periphery of the right eye, the vessels were straightened, and several were sheathed. In this zone the vessels were not perfused, and there were pigmentary changes and minimal yellowish, retinal exudates. The left fundus appeared normal. Fluorescein angiography of the right eye temporal periphery showed the retinal vessels to be more numerous and increased in calibre, and leakage occurred from these vessels (Fig. 5a). No perfusion occurred anterior to the equator. In the left eye, despite the normal appearance of the vessels, there was leakage into the posterior retina during angiography (Fig. 5c). The periphery showed similar vascular changes to those in the right eye, and temporally there was reduplication of the line of leaking blood vessels (Fig. 5d).

Case 6 (pedigree 2, III-17; 32-year-old maternal aunt of the propositus). The posterior pole in each eye was normal. The retinal blood vessels were straightened and more numerous than normal in the temporal periphery of both eyes. Fluorescein angiography showed peripheral nonperfusion, and the vessels ended in arteriovenous anastomoses without an intervening capillary network. Central to the margin of perfused and nonperfused retina the capillaries were dilated and there was diffuse leakage of dye.

Case 7 (pedigree 2, III-19; 28-year-old aunt of the propositus). The fundi of each eye were apparently normal, but fluorescein angiography showed peripheral retinal vessel closure in the temporal periphery of each eye, with dye leakage from the vessels at the border of closure.

Case 8 (pedigree 2, II-6; 60-year-old maternal grandmother of propositus). Other than mild adult

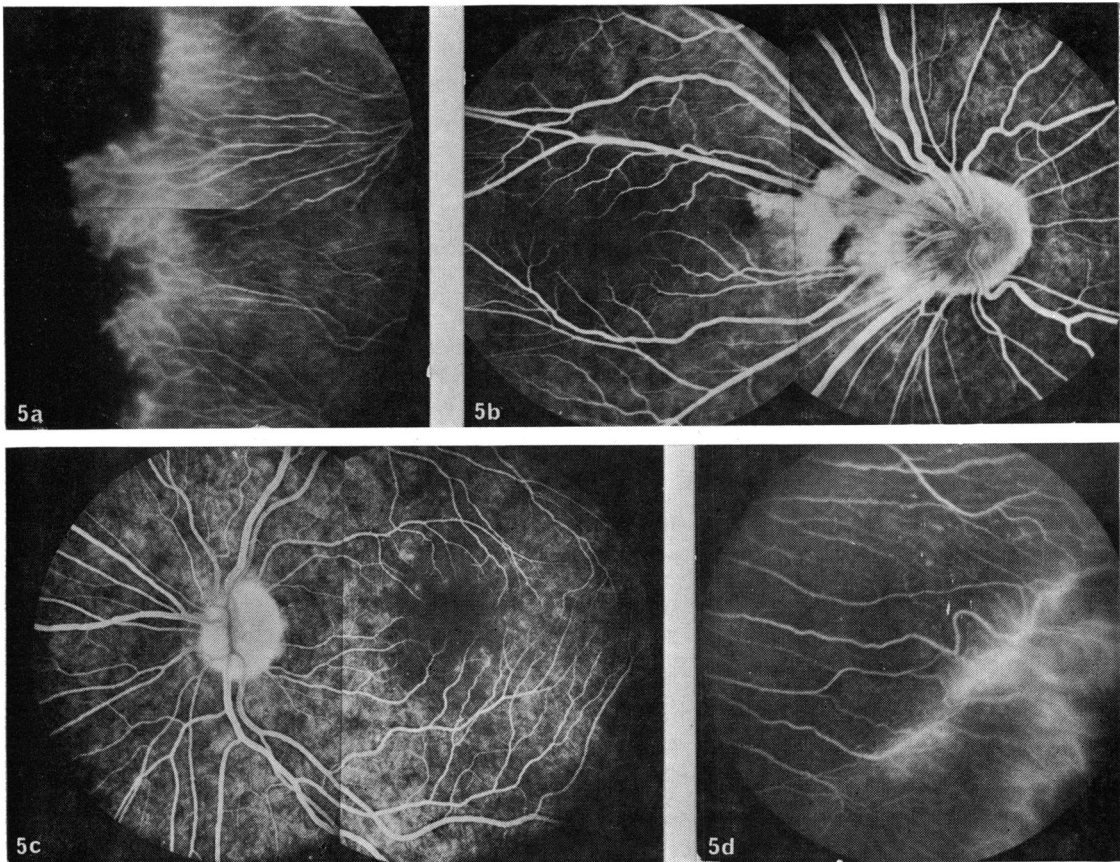


Fig. 5 Fluorescein angiogram in case 5, showing distortion of the central retinal vessels in the right eye only (5b), peripheral retinal vessel closure with leakage (5a, d) and leakage from the paramacular vessels in the left posterior pole (5c).

onset diabetes she was healthy, but had noticed recent mild blurring of vision. Visual acuity was 6/12 (20/40) in the right eye and 6/18 (20/60) in the left eye. The anterior segments showed bilateral mild nuclear sclerosis. Intraretinal haemorrhages and exudates were located in the posterior pole of each eye, and the peripheral fundus appeared normal. Fluorescein angiography revealed multifocal retinal vascular disease consistent with background diabetic maculopathy. The temporal periphery of each eye showed sharply demarcated retinal vessel nonperfusion with leakage of dye, and areas of capillary nonperfusion.

Five other members of this family were examined (IV-7, IV-8, III-16, III-18, and II-5) and fluorescein angiography undertaken on 3. They were all asymptomatic, with no history of ocular or systemic disease. Visual acuities were normal, and no ocular abnormalities were found.

PEDIGREE 3 (Fig. 6)

Case 9 (pedigree 3, III-11). A healthy 15-year-old Iranian female with decreased vision in the right eye since childhood was seen on 17 July 1978. She was born at term and was given no oxygen in the neonatal period. Visual acuity was 6/60 (20/200) with the right eye, and 6/9 (20/30) with the left eye. Except for a 30 prism dioptre right esotropia, external and anterior segment examination of each eye showed no abnormality. In the right fundus there was severe temporal dragging of the posterior retina (Fig. 7a), with circumferential traction of the temporal peripheral retina. The vitreous base was dense and organised temporally, preretinal vitreous bands were located inferiorly, 'white without pressure' was present in all quadrants, and retinal exudates were located temporally. The left eye had similar but slightly less severe changes. Several large neovascular fronds resembling 'sea-fans'

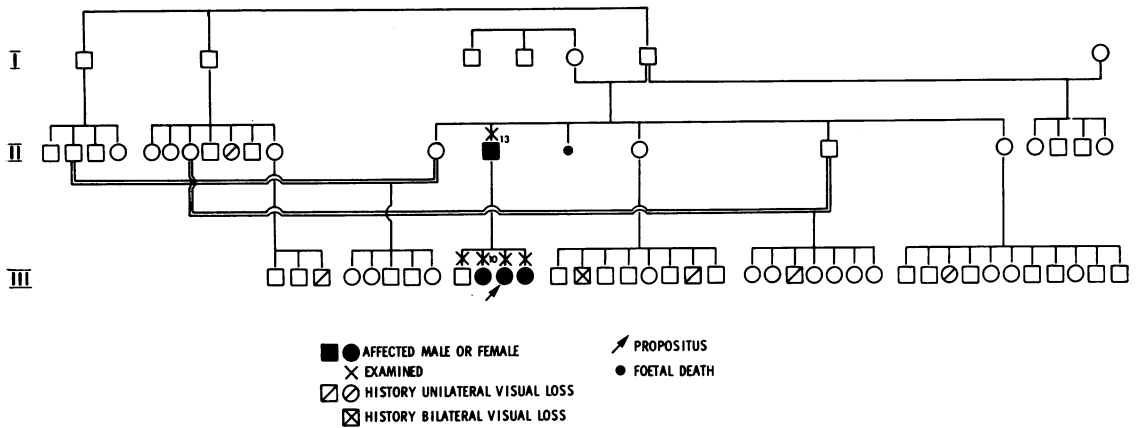


Fig. 6 Pedigree 3.

with feeder vessels were located in the temporal periphery.

Fluorescein angiography of the right eye showed diffuse leakage of dye in the posterior pole (Fig. 7a), and confirmed the large areas of peripheral non-perfusion. The left eye showed leakage of dye at the disc and macula, and similar peripheral non-perfusion in all quadrants. The forward neovascularisation was located at the posterior margin of the zone of peripheral closure in the temporal periphery, and leaked dye profusely (Figs. 7b, c).

Case 10 (pedigree 3, III-10; 7-year-old sister of the propositus). She had poor vision since infancy but no systemic disease. Visual acuity was 2/60 (6/200) with the right eye (-3.00 d.sph. +0.50 d.cyl. axis 90°), and 1/60 (3/200) with the left eye (-2.50 d.sph. +0.50 d.cyl. axis 110°). External examination showed 'searching' nystagmus and a large variable esotropia with no fixation preference; the anterior segment was normal in each eye. The left eye showed severe temporal dragging of the posterior retina, many vitreous membranes, and a temporal fibrous mass in the peripheral retina and vitreous base which extended anteriorly to involve the ciliary body. The inner layers of the temporal retina were highly elevated by traction with several large peripheral retinal holes present. The right eye had similar but slightly milder involvement. Fluorescein angiography was not performed.

Case 11 (pedigree 3, III-12; 22-year-old sister of the propositus). The right eye was enucleated in infancy because of a possible intraocular malignancy. Correct visual acuity was 6/18 (20/60) with the left eye (-6.50 d.sph. -2.00 d.cyl. axis 165°). The left anterior segment was normal. The vitreous showed mild degeneration, snowflake vitreous opacities, and preretinal vitreous membranes inferiorly. The retina

showed moderate temporal dragging of the disc and macula, temporal retinal neovascularisation and exudates, peripheral 'white without pressure', and retinal vessel nonperfusion in all quadrants. Fluorescein angiography demonstrated the mild dragging of the posterior retinal vessels with dye leakage; there was also focal venous leakage above and nasal to the optic disc (Fig. 8a). Angiography also confirmed peripheral nonperfusion and profuse leakage from the peripheral vessels (Fig. 8b) and at the posterior pole.

Case 12 (pedigree 3, II-13; 55-year-old father of the propositus). Visual acuity was 6/6 (20/20) in each eye. The anterior segments were normal. The fundi were normal except for mild retinal exudates and peripheral vessel closure in the temporal periphery of the right eye. Fluorescein angiograms were poor, but were adequate to confirm peripheral retinal vessel closure.

The 25-year-old brother of case 8 was healthy and without ocular symptoms. Ocular examinations and fluorescein angiography were normal.

Five relatives had poor vision with 1 eye and 1 with both. The cause of visual loss was unknown, and there was no opportunity to see the other family members.

Discussion

Criswick and Schepens¹ described in detail the vitreoretinal changes in 6 cases of autosomal dominant exudative vitreoretinopathy, and Gow and Oliver² described 3 clinical stages. Stage 1 showed vitreoretinal interface changes, vitreous bands and membranes, and peripheral retinal degeneration; stage 2 the occurrence of neovascularisation, retinal exudates, elevated fibrovascular

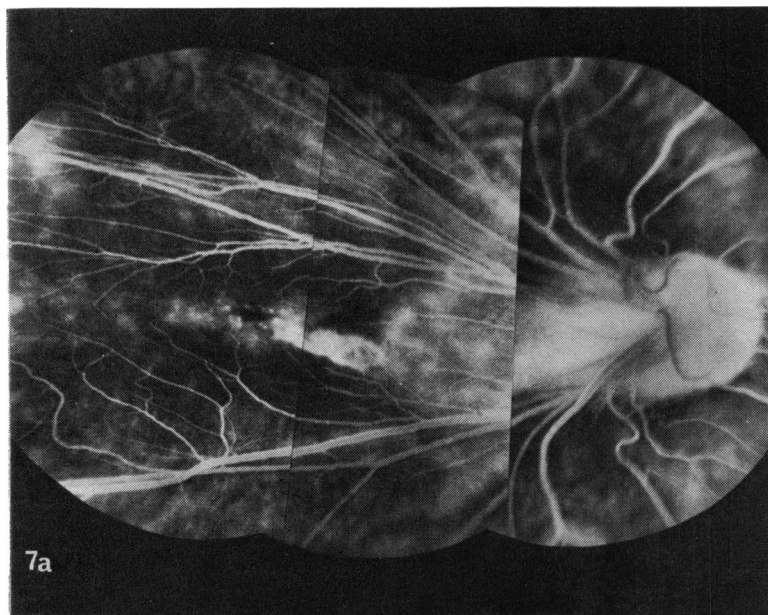
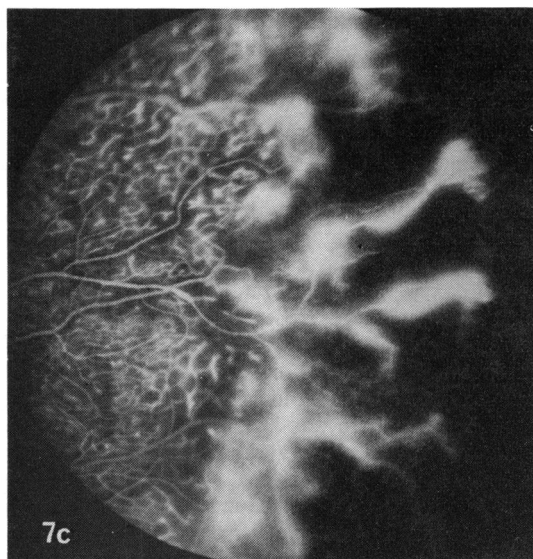
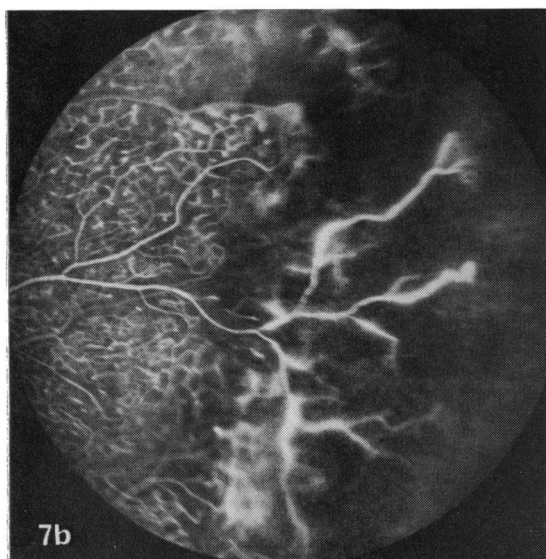


Fig. 7 Fluorescein angiogram of the right eye of case 9, showing distortion of the central retinal vessels (a). Peripheral retinal vessel closure was associated with forward new vessels (b, c).

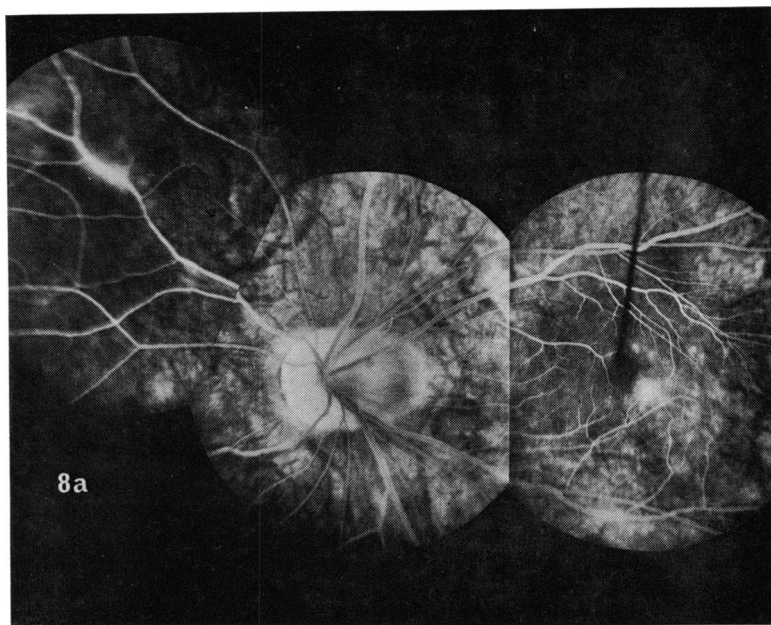


masses in the temporal periphery, localised retinal detachment, and dragging of the disc and macula; stage 3 total retinal detachment, associated with anterior segment changes comprising cataract formation, iris atrophy, neovascular glaucoma, band keratopathy, and eventual blindness.

Seven of our 12 patients had no ocular symptoms and were mildly affected by the disease (Table 1). None of these patients had 'white with pressure', 'white without pressure', or vitreous bands and

membranes, as described in stage 1 of the disease,² and only 2 of these patients had dragging of the disc and macula in one or both eyes (cases 2 and 5). In 3 of these 7 patients (cases 4, 6, and 8) the only ophthalmoscopic finding was an excess of straight vessels in the periphery, which were radial. However, all of the 7 patients had pre-equatorial nonperfusion of retinal vessels, indicating the abnormal genotype. The peripheral straight vessels and peripheral nonperfusion, which were difficult to detect ophthal-

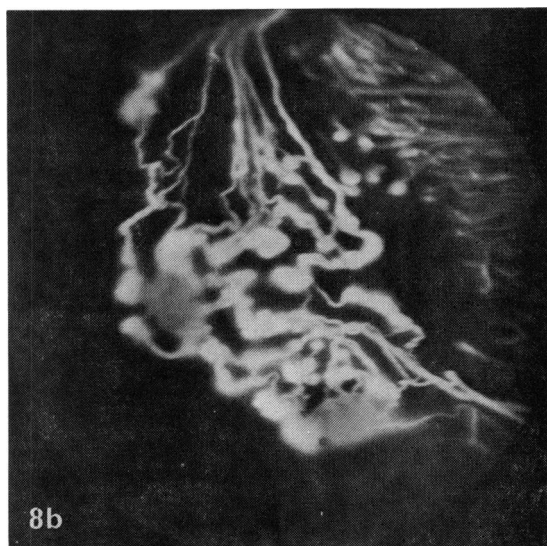
Fig. 8 Fluorescein angiogram of case 11, showing distortion of the central retinal vessels with leakage and dye in the macular region and from a nasal retinal vein (a). Peripheral nonperfusion was associated with retinal telangiectasis (b).



microscopically, were easily demonstrated by fluorescein angiography. Abnormality of the vitreous, as described in the first reported cases, was not a prominent feature in many of our cases and does not appear to be essential in making the diagnosis. We conclude that, if the stated criteria of Gow and Oliver² had been adhered to, some of these cases might not have been identified.

Understandably, most emphasis has been placed on the peripheral retinal vascular changes. The pattern of peripheral closure and forward proliferation of new vessels has been well described,^{3,4} but the retinal vessel abnormalities appear to be more widespread. In several cases fluorescein leakage occurred over a wide band of postequatorial retina, and in 3 cases there was leakage from the macular capillaries even in the absence of gross traction (Fig. 5c).

Progressive traction causing retinal detachment and vitreous haemorrhage from forward retinal blood vessels may be construed as the major threat to vision in these patients. Criswick and Schepens¹ judged the chances of complete arrest of the condition to be small, and Gow and Oliver² also emphasised the progressive nature of the condition. Photocoagulation or cryotherapy have been recommended if progress is identified.^{1,2} In each case it was implied that therapy should be directed to the proliferating peripheral new vessel complexes. If the object of this treatment was to reduce the incidence of vitreous haemorrhage, there is little evidence to justify this. Vitreous haemorrhage has



been recorded in only 1 patient.¹ This patient had a horseshoe tear, and no evidence was presented to indicate that the forward vessels were the source of haemorrhage.

Contrary to the impression given by these earlier papers,^{1,2} but in accord with the reservations of Gitter and co-workers,⁴ our findings suggest that the disease does not necessarily progress relentlessly during life, and in this respect differs from the recorded behaviour of Wagner's hyaloretinopathy.⁵ In our pedigrees, and in those already published, no

Table 1 Ocular involvement in affected members of 3 families with autosomal dominant vitreoretinopathy

Age	Sex	Vision	Symptoms	Dragged disc/ macula	Peripheral exudates/ fibrosis	Peripheral non-perfusion	Neo-vascularisation	Traction detachment	Vitreous bands/ membranes	
<i>Pedigree 1</i>										
Case 1 (II-2)	12	F	OD 6/9 (20/30) OS NLP	Yes	+++ No fundus view	+	Yes	No	-	-
Case 2 (II-1)	17	M	OD 6/5 (20/15) OS 6/5 (20/15)	No	++ +	+	Yes Yes	Yes No	- -	- -
<i>Pedigree 2</i>										
Case 3 (IV-2)	17	F	OD 6/60 (20/200) OS NLP	Yes	+++ No fundus view	+++	Yes	No	+++	+++
Case 4 (IV-1)	22	M	OD 6/5 (20/15) OS 6/6 (20/20)	No	-	-	Yes Yes	No No	-	-
Case 5 (III-15)	40	F	OD 6/6 (20/20) OS 6/6 (20/20)	No	+	+	Yes Yes	No No	-	-
Case 6 (III-17)	32	F	OD 6/6 (20/20) OS 6/5 (20/15)	No	-	-	Yes Yes	No No	-	-
Case 7 (III-19)	28	F	OD 6/5 (20/15) OS 6/5 (20/15)	No	-	-	Yes Yes	No No	-	-
Case 8 (II-6)	60	F	OD 6/12 (20/40)* OS 6/18 (20/60)	No	-	-	Yes Yes	No No	-	-
<i>Pedigree 3</i>										
Case 9 (III-11)	15	F	OD 6/60 (20/200) OS 6/9 (20/30)	Yes	+++ ++	+++ ++	Yes Yes	No Yes	+++ ++	++ ++
Case 10 (III-10)	7	F	OD 2/60 (6/200) OS 1/60 (3/200)	Yes	+++ +++	+++ +++	Not determined	No No	++ +++	++ +++
Case 11 (III-12)	22	F	OD Prosthesis OS 6/18 (20/60)	Yes	++	++	Yes	Yes	-	+
Case 12 (II-13)	55	M	OD 6/6 (20/20) OS 6/6 (20/20)	No	-	+	+	No No	-	-

+++ = Severe. ++ = Moderate. + = Mild. - = Not present.

*Decreased vision caused by diabetic maculopathy.

member has been reported as suffering from loss of vision after the age of 20 years, and the disease was not obviously more advanced in older than in younger patients with the abnormal gene. It is perhaps significant that those workers who undertook treatment as a result of documented progression did so in patients under the age of 18 years. However, even in the young progression is not inevitable. Case 3 was remarkable in that there was traction detachment of the whole pre-equatorial retina of the right eye at the age of 2½ years which did not progress during the following 14 years. The only case in this series who was treated had retinal detachment with loss of central vision (case 1), and vision has remained good during the subsequent 8½ years.

If our observations are representative of the disease as a whole, and our interpretation of pre-

vious reports is correct, doubt is cast on the need for any type of prophylactic measure, even in the presence of marked abnormality. It is possible that treatment should be limited to those patients in whom there is visual loss. Furthermore, the lack of progression indicates that no visual threat to the patient is implied by making the diagnosis in an adult during family survey.

Gow and Oliver² described an autosomal dominant pattern of inheritance with reduced penetrance, because family members with the abnormal gene were found to have normal fundi (patients V-29 and V-30); we assume fluorescein angiography was not performed in these cases. In our second pedigree there were 3 affected members out of 6 relatives at 50% risk of inheriting the abnormal gene, which suggests that the penetrance is close to 100%, and the apparent reduction in penetrance is due to

variable expressivity. Because of possible mild involvement we doubt whether an eye can be considered normal without careful indirect ophthalmoscopy, 3-mirror contact lens examination, and fluorescein angiography. It is likely that the phenotypic expression of the abnormal gene would have been detected in one parent of the propositus in the 2 families studied by Criswick and Schepens¹ and in the other eye of the reported unilateral cases² if fluorescein angiography had been performed. One eye of each parent in pedigree 1 was dilated and found to be normal, but careful 3-mirror contact lens examination and fluorescein angiography were not done.

The variable expressivity of autosomal dominant exudative vitreoretinopathy has further implications for the identification of heritable disease and genetic counselling. A negative family history of poor vision does not exclude the diagnosis of this genetically determined disease. Furthermore, individuals at risk of having the abnormal gene and seeking genetic advice require a careful examination of the retinal periphery and fluorescein angiography before accurate genetic counselling can be given. The variable expressivity also casts doubt on the diagnosis of retrolental fibroplasia in the absence of prematurity⁶ and neonatal administration of oxygen, unless other members of the family have been fully assessed.

The pathogenesis of autosomal dominant exudative vitreoretinopathy is unknown. The sharply demarcated zone of peripheral retinal blood vessel closure and the pattern of arteriovenous anastomoses are remarkably similar to retrolental fibroplasia.⁷⁻⁹ The 2 conditions appear to be morphologically indistinguishable, and it is possible that there

are similarities in the pathological mechanisms between them. Observations of the fundus of patients at risk of inheriting the abnormal gene during the neonatal period may help to explain the morphology of the lesion, and the finding that the visual prognosis appears to be determined in the first 2 decades of life.

Dr Richard R. Ober was supported by the Francis and Renee Hock Fellowship. We thank Miss J. Bramley and Mrs E. Barrera for secretarial assistance and are grateful to Professor G. Crock and Mr A. S. M. Lim for allowing us to publish case 1.

References

- ¹Criswick VG, Schepens CL. Familial exudative vitreoretinopathy. *Am J Ophthalmol* 1969;**68**: 578-594.
- ²Gow J, Oliver GL. Familial exudative vitreoretinopathy. *Arch Ophthalmol* 1971; **86**:150-155.
- ³Canny CLB, Oliver GL. Fluorescein angiographic findings in familial exudative vitreoretinopathy. *Arch Ophthalmol* 1976; **94**:1114-1120.
- ⁴Gitter KA, Rothschild H, Waltman DD, Scott B, Azar P. Dominantly inherited peripheral retinal neovascularisation. *Arch Ophthalmol* 1978; **96**:1601-1605.
- ⁵Hirose T, Lee KY, Schepens CL. Wagner's hereditary vitreoretinal degeneration and retinal detachment. *Arch Ophthalmol* 1973; **89**:176-185.
- ⁶Cohen J, Alfano JE, Boshes LD, Palmgren C. Clinical evaluation of school-age children with retrolental fibroplasia. *Am J Ophthalmol* 1964; **57**:41-57.
- ⁷Flynn JT, O'Grady GE, Herrera J, Kushner BJ, Cantolino S, Milam W. Retrolental fibroplasia: I. Clinical observations. *Arch Ophthalmol* 1977; **95**:217-223.
- ⁸Cantolino SJ, O'Grady GE, Herrera JA, Israel C, Justice J Jr, Flynn JT. Ophthalmoscopic monitoring of oxygen therapy in premature infants. *Am J Ophthalmol* 1971; **72**: 322-331.
- ⁹O'Grady GE, Flynn JT, Clarkson J, Clark RD. Retrolental fibroplasia: Clinical, fluorescein angiographic and pathological correlation. *Mod Probl Ophthalmol* 1974; **12**: 144-151.