

Tamoxifen retinopathy

CRAIG A. MCKEOWN,¹ MANO SWARTZ,¹ JOHANNES BLOM,²
AND JOHN M. MAGGIANO³

From the ¹Ophthalmology Service and the ²Oncology Service, Walter Reed Army Medical Center, Washington, DC, and the ³Department of Ophthalmology, University of California, Irvine, USA

SUMMARY A 63-year-old female on long-term, high-dose tamoxifen treatment for metastatic breast cancer developed bilateral intraretinal refractile opacities, lesions at the level of the retinal pigment epithelium, and cystoid macular oedema.

Tamoxifen is a nonsteroidal antioestrogen used in the treatment of breast cancer. The drug has been relatively free of serious side effects, though ocular toxicity has been reported in 4 patients on high-dose therapy.^{1,2} We are reporting a patient who developed retinopathy while receiving halotestin and high doses of tamoxifen.

Case report

In October 1977 a 63-year-old white female was examined at the Walter Reed Army Medical Center with a complaint of a 1-year history of progressive, painless visual loss in both eyes. Twenty-one years previously the patient underwent a left radical mastectomy for carcinoma of the breast with positive left axillary lymph nodes. She received postoperative radiation followed by a hysterectomy plus a bilateral salpingo-oophorectomy. Approximately 14 years later she had 3 left ribs resected for a recurrence of tumour and 1 year later (1971) underwent a right simple mastectomy for carcinoma of the breast and again received postoperative radiation. She did not receive methoxyfluorane as an anaesthetic agent. Shortly thereafter she developed skin nodules on the right anterior chest and was put on weekly 5-fluorouracil from 1971 until

March 1973, when she developed a left pleural effusion. She was subsequently treated with a variety of chemotherapeutic agents which included cytoxan, methotrexate, 5-fluorouracil, prednisone, diethylstilboestrol, and a short trial of L-PAM. In May 1975 she was started on tamoxifen, 90 mg (60 mg/m²) twice daily, and halotestin, 10 mg (7 mg/m²) twice daily as a participant in a randomised trial to study the effect of increasing doses of tamoxifen with or without halotestin. Currently accepted tamoxifen doses vary from 10 to 20 mg twice daily.

The patient noted the onset of decreasing vision in about October 1976 after 17 months of treatment with tamoxifen and halotestin. The total dose of tamoxifen at that time was slightly greater than 90 g. A previous ocular examination in May 1976 showed a visual acuity of RE 6/9 (20/30) and LE 6/7.5 (20/25). The fundus examination was recorded as normal. Ophthalmological examination in October 1977 revealed a best corrected visual acuity of 6/15 (20/50) in each eye. Visual field testing with the IV4e and I4e white targets on the Goldmann perimeter showed peripheral constriction and central scotomas. The conjunctivae, corneae, and intraocular pressures were normal. Mild nuclear sclerosis and a few cortical spoke-like opacities were present on both lenses. Fundus examination (Fig. 1) revealed a myriad of tiny, refractile, intraretinal lesions at all levels of the sensory retina. These lesions were concentrated in both maculae but extended to the ora serrata. At the level of the retinal pigment epithelium there were 250 to 400 µm diameter yellow-white granular areas which were most prominent posterior to the equator but were noted in the far peripheral retina as well. Cystoid macular oedema was present bilaterally. The optic discs were normal and the retinal arterioles appeared

*This paper was read in part before the Macula Society on 12 January 1979.

The opinions or assertions contained herein are the private views of the authors and are not to be construed as official or as reflecting the views of the Department of the Army or the Department of Defense.

Correspondence to Mano Swartz, MD, Division of Ophthalmology, University Medical Center, 50 N. Medical Drive, Salt Lake City, Utah 84132, USA.

mildly narrowed. A fluorescein angiogram showed that the deep granular areas were hypofluorescent, with no evidence of leakage, though many showed border and central hyperfluorescent areas (Fig. 2). Cystoid macular oedema was prominent in the late phase of the angiogram (Fig. 3).

Tamoxifen and halotestin were discontinued in March 1978 after a total of 158 g of tamoxifen.

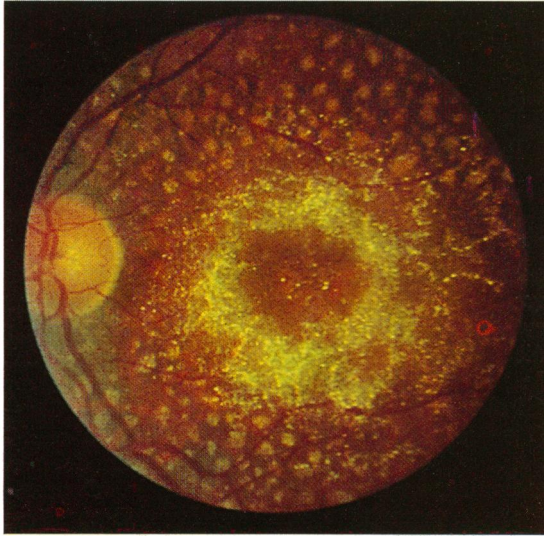


Fig. 1 Fundus of left eye with multiple tiny, refractile, intraretinal lesions and larger, granular areas at the level of the retinal pigment epithelium.

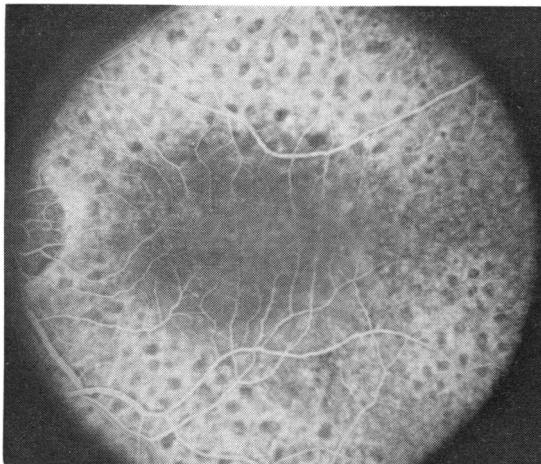


Fig. 2 Fluorescein angiogram of left eye in the arteriovenous phase showing hypofluorescence of lesions at the level of the retinal pigment epithelium. Many of these lesions show central and border hyperfluorescence. Early macular oedema is evident.

Examination in January 1979 revealed a visual acuity of RE 6/90 (20/300) and LE 6/24 (20/80). The anterior segments, including the cornea, were unchanged. The fundi had an increased number of intraretinal refractile bodies with no apparent change in the cystoid macular oedema. A fluorescein angiogram was performed in August 1978 and was unchanged. The electroretinogram was normal, though there were slightly decreased photopic and scotopic A and B wave amplitudes. Further electrophysiological investigation was deferred because of failing health.

Discussion

Kaiser-Kupfer and Lippman² reported 4 patients who had received 108 to 230 g of tamoxifen over 17 to 27 months. These patients were participants in the previously mentioned randomised trial for the treatment of metastatic breast cancer using increasing doses of tamoxifen with or without halotestin. All their 4 patients had fine, white, refractile, sensory retinal opacities, 3 had bilateral, superficial, corneal whorl opacities; 3 had cystoid macular oedema, and 1 had punctate areas of retinal pigment epithelial depigmentation. In each case the patient was receiving only tamoxifen when the ocular disease was discovered, and 1 patient had received no other chemotherapeutic agents. Our patient became aware of a painless reduction in visual acuity after approximately 16 months of treatment with tamoxifen 90 mg twice daily and halotestin

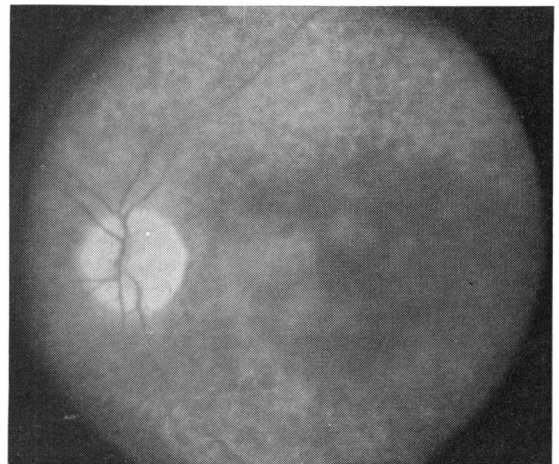


Fig. 3 The late phase of the fluorescein angiogram reveals cystoid macular oedema and fading of the hyperfluorescence associated with the borders and centres of the lesions at the level of the retinal pigment epithelium.

10 mg twice daily. Her total dose of tamoxifen at the time of onset of symptoms was about 90 g. Other causes of crystalline retinopathy were investigated in our patient. There was no evidence to support Bietti's crystalline dystrophy,^{3,4} oxalosis,⁵ cystinosis,⁶ Sjögren-Larsson syndrome,⁷ Christmas tree vasculitis,⁸ or calcified drusen as the diagnosis.

Tamoxifen is a nonsteroidal antioestrogen which binds to oestrogen-receptor proteins in the cytoplasm.¹ It is used in the treatment of metastatic breast cancer, particularly in postmenopausal patients with soft-tissue metastases. In the recommended dosage of 10–20 mg twice daily it has not been shown to cause ocular abnormalities.⁹

It is structurally similar to a group of drugs with cationic amphiphilic properties. These compounds, which include triparanol (MER-29), chloroquine, chlorpromazine (Thorazine), thioridazine (Mellaril), and amiodarone, are characterised by a hydrophobic moiety and a positively charged hydrophilic side chain on the same molecule.^{10–12} Some of these compounds have been shown in vitro to form tight but reversible bonds with polar lipids, resulting in vivo in the accumulation of drug-polar lipid complexes in lysosomes.^{10,11} Whether this is the underlying mechanism in the ocular toxicity of these drugs and of tamoxifen awaits further study.

We are grateful for the assistance and guidance provided by Dr Paul Whitmore, Dr Denton Wirtz, Dr Muriel Kaiser-Kupfer, Ellen Foer, Rebecca Olson, and Sidney Waters.

References

- 1 Heel RC, Brogden RN, Speight TM, Avery GS. Tamoxifen: a review of its pharmacological properties and therapeutic use in the treatment of breast cancer. *Drugs* 1978; **16**: 1–24.
- 2 Kaiser-Kupfer MI, Lippman ME. Tamoxifen retinopathy. *Cancer Treat Rep* 1978; **62**: 315–20.
- 3 Bietti G. Über familiares Vorkommen von 'Retinitis punctata albescens' (verbunden mit 'Dystrophia marginalis cristalinae cornea'): Glitzern, des Glaskörpers und anderen degenerativen Augenveränderungen. *Klin Monatsbl Augenheilkd* 1937; **99**: 737–56.
- 4 Bagolini B, Ioli-Spada G. Bietti's tapetoretinal degeneration with marginal corneal dystrophy. *Am J Ophthalmol* 1968; **65**: 53–60.
- 5 Bullock JD, Albert DM. Flecked retina: appearance secondary to oxalate crystals from methoxyflurane anaesthesia. *Arch Ophthalmol* 1975; **93**: 26–30.
- 6 Read J, Goldberg MF, Fishman G. Nephropathic cystinosis. *Am J Ophthalmol* 1973; **76**: 791–6.
- 7 Gilbert WR Jr, Smith JL, Nyhan WL. The Sjögren-Larsson Syndrome. *Arch Ophthalmol* 1968; **80**: 308–16.
- 8 Universal Christmas tree vasculitis in meningeal syndrome. *Ophthalmology Times* 1977; **2**: 1.
- 9 Tamoxifen for breast cancer. *Med Lett Drugs Ther* 1978; **20**: 41–2.
- 10 Lullman H, Lullmann-Rauch R, Wassermann O. Drug-induced phospholipidoses. *CRC Crit Rev Toxicol* 1975; **4**: 185–218.
- 11 Drenckhahn D, Lullmann-Rauch R. Drug-induced retinal lipidosis: differential susceptibilities of pigment epithelium and neuroretina toward several amphiphilic cationic drugs. *Exp Mol Pathol* 1978; **28**: 360–71.
- 12 Bockhardt H, Drenckhahn D, Lullmann-Rauch R. Amiodarone-induced lipidosis-like alterations in ocular tissues of rats. *Albrecht von Graefes Arch Klin Ophthalmol* 1978; **207**: 91 (English abstract).