

Bilateral herpetic keratitis

K. R. WILHELMUS, M. G. FALCON, AND B. R. JONES

From the Department of Clinical Ophthalmology, Institute of Ophthalmology, Moorfields Eye Hospital, London

SUMMARY Thirty patients with bilateral herpetic keratitis were evaluated, 40% of whom were atopic. Stromal keratitis occurred in 40% of the eyes and recurrent ulceration in 68%. Four patients (5 eyes) developed secondary microbial keratitis. Visual acuity decreased to 6/60 or less because of corneal opacification in 17% of the eyes.

Keratitis due to human herpesvirus is one of the commonest causes of unilateral corneal opacification; the incidence in the general population is estimated at 1 in 1652.¹ Involvement of both eyes is unusual but may be particularly disabling. We have therefore reviewed the characteristics and outcome of bilateral herpetic keratitis in 30 of our patients.

Patients and methods

Patients with herpetic keratitis were examined in the Virus Clinic, Moorfields Eye Hospital. After anamnesis and ocular examination, the clinical findings were summarised by a standardised coding system.² The diagnosis of bilateral herpetic keratitis was based upon the recognition of a characteristic dendritic or geographic epithelial ulceration. Cytological or immunofluorescent examination of prepared smears and viral isolation were performed for diagnostic confirmation of selected patients. Atopy was considered to be present if the patient had a previous history of allergic rhinitis, eczema, asthma, or vernal keratoconjunctivitis.

Management was based upon the individual manifestations of herpetic eye disease. A topical antiviral medication with or without wiping debridement was utilised for treatment of ulcerative herpetic keratitis. Progressive stromal or uveal inflammation was controlled with a topical corticosteroid according to a schedule that links the severity of the disease to the intensity of treatment.³ Keratoplasty was considered in those patients with corneal opacity, stromal loss, or

refractory inflammation. Secondary microbial infection was investigated with corneal scrapings for smears and culture.

Results

Thirty patients with bilateral herpetic keratitis were identified in a population of approximately 1000 patients with corneal disease due to human herpesvirus. Twenty-one (70%) of the patients were male and 9 (30%) were female (Fig. 1). The average age at the time of the initial episode of corneal disease was 28 ± 15 years (range 5 to 60 years). Immediately preceding the initial episode of keratitis 4 patients had a systemic illness, namely, malaria, pulmonary tuber-

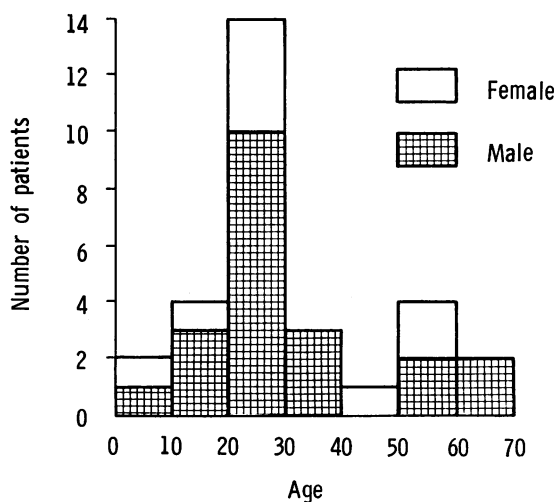


Fig. 1 Histogram of age and sex of 30 patients with bilateral herpetic keratitis showing age at first episode of dendritic keratitis.

Correspondence to Dr K. R. Wilhelmus, Professorial Unit, Moorfields Eye Hospital, City Road, London EC1V 2PD.

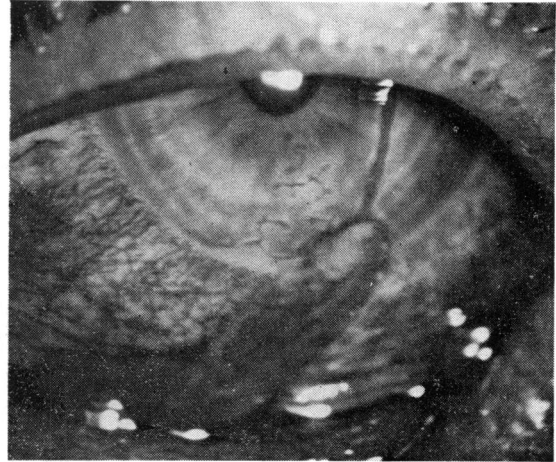
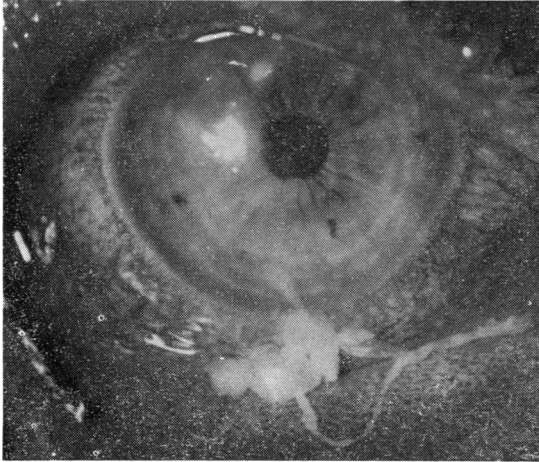


Fig. 2 Bilateral herpetic keratitis occurring in an atopic 28-year-old male. Papillary and follicular conjunctivitis with mucopurulent discharge are present in both eyes. Dendritic ulceration is noted in the left eye and coarse punctate epithelial lesions in the right eye.

culosis, lumbar herpes zoster, and gastric carcinoma. Atopy was present in 12 (40%) of the patients. One patient was receiving a topical corticosteroid when she developed simultaneous herpetic keratitis of both eyes.

The initial episode of keratitis occurred simultaneously in 17 (57%) of the patients and on different occasions in 13 (43%) (Table 1). Six patients had cutaneous vesicles of the mouth, lips, or nose; one 5-year-old boy had vesicles of both lower eyelids for 2 weeks prior to corneal involvement. A papillary and follicular conjunctivitis with mucopurulent exudate (Fig. 2) and preauricular lymphadenopathy were present in 6 (20%) of the patients.

The incidence of recurrent keratitis was evaluated following the initial epithelial ulceration: recurrent ulcerative keratitis developed in 41 eyes; stromal disciform keratitis occurred in 24 eyes; anterior uveitis occurred in 10 eyes; ocular hypertension developed in 4 eyes; and corneal vascularisation occurred in 24 eyes. Other complications which occurred included 1 case each of herpetic canaliculitis, scleritis, trichiasis, and Kaposi's varicelliform eruption (Table 2).

Table 1 Clinical features of 30 patients with bilateral herpetic keratitis

Characteristic	No. (%)
Atopy	12(40%)
Simultaneous occurrence	17(57%)
Cutaneous vesicles (lid, nose, lip)	7(23%)
Follicular conjunctivitis	6(20%)

Table 2 Complications of 30 patients (60 eyes) with bilateral herpetic keratitis*

Complication	Neither eye	One eye	Both eyes
Recurrent dendritic ulceration	6	7	17
Disciform stromal keratitis	14	8	8
Anterior uveitis	20	5	5
Ocular hypertension	28	0	2
Corneal vascularisation	13	10	7
Corneal opacification	4	9	17
Bacterial or fungal keratitis	26	3	1
Penetrating keratoplasty†	19	9	2
Visual acuity 6/60 or worse	22	6	2

*Other complications include one case each of herpetic canaliculitis, scleritis, trichiasis, and Kaposi's varicelliform eruption. †Six eyes had a second penetrating keratoplasty following failure of the first transplant.

After resolution of the ocular inflammation a corneal opacity was noted in 43 eyes (26 patients). Keratoplasty was performed in 11 patients, 2 of whom had surgery to both eyes. Six eyes had a repeat keratoplasty because of graft failure due to either rejection or herpetic recurrence.

The visual acuity following the last episode of ocular inflammation was 6/12 or better in 46 eyes, 6/18 to 6/36 in 4 eyes, and 6/60 or worse in 10 eyes. Two patients had a vision or 6/60 or worse in both eyes.

Four atopic patients developed secondary microbial keratitis. One patient had bilateral suppurative keratitis due to *Staphylococcus aureus*. Of the remaining 3 one was due to *S. aureus*, 1 to *Pseudomonas aeruginosa*, and 1 to *Candida albicans*.

Discussion

Herpetic eye disease is characteristically unilateral. After a primary ocular infection the trigeminal⁴ or autonomic⁵ ganglia may be infected, where the virus remains in a latent or slowly replicating state. In response to various endogenous or exogenous stimuli recurrent herpetic keratitis may occur in the same eye via ipsilateral transneuronal spread.

Compared with the incidence of approximately 3% in this series, previous reports of patients with herpetic keratitis have shown incidences of bilateral disease of 1%⁶ and 2%.⁷⁻⁸ Others, however, have found up to 10%⁹⁻¹⁰ bilateral involvement in referred patients, and 16%¹¹ of patients with herpetic keratitis undergoing keratoplasty.

When compared with patients with unilateral herpetic keratitis patients with bilateral disease tend to be younger⁹ and to be atopic.¹² Atopy was particularly common in those patients developing a bilateral primary blepharoconjunctivitis. Simultaneous bilateral primary infection occurred in 1 patient in this series in association with lid vesicles and in 6 patients in association with follicular conjunctivitis. Ulcerative keratitis occurred in each of these patients during the blepharoconjunctivitis. A susceptibility to exogenous viral infection thus appeared to be present in these patients.

Herpetic keratitis occurred in each eye on separate occasions in 13 patients. In these patients viral shedding may have occurred at different times following a prior bilateral primary infection. Alternatively, immunity to herpesvirus may not have developed from the initial exposure of one eye, so that reinfection of the contralateral eye was possible. Ocular infection with 2 different variants of the virus may also offer an explanation.¹³

Either because of greater virulence of the virus or because of altered host susceptibility patients with bilateral herpetic eye disease have a high proportion of subsequent complications. In this series recurrent ulcerative keratitis occurred in 68% of the eyes and subsequent disciform stromal keratitis in 40%. In addition, secondary microbial keratitis developed in 8%, each in an atopic patient. Those factors which are associated with bilateral herpetic eye disease

also apparently predispose to progressive corneal inflammation and opacification.

Because the unilaterality of herpetic keratitis offers a very important point in the differential diagnosis,⁶ other causes of bilateral keratitis must be considered unless typical corneal lesions are identified. Virological evaluation should be considered for those cases of bilateral keratitis which do not fall into any other diagnostic category.¹⁴

Mr H. P. Williams, FRCS, participated in the clinical evaluation. Dr Wilhelmus is a recipient of a fellowship from the Friends of Moorfields Eye Hospital.

References

- 1 Colin J, Renard G, Chastel C, Saleun JP. HLA-types and herpes simplex ocular infections. Presented at the Herpetische Augenerkrankungen Internationales Symposium, Freiburg, W. Germany, 12 April 1980.
- 2 McKinnon J, McGill J, Jones BR. Summary code for ocular herpes simplex. *Br J Ophthalmol* 1975; **59**:539-44.
- 3 Williams HP, Falcon MG, Jones BR. Corticosteroids in the management of herpetic eye disease. *Trans Ophthalmol Soc UK* 1977; **97**:341-4.
- 4 Baringer J, Swoveland P. Recovery of herpes simplex virus from human trigeminal ganglion. *N Engl J Med* 1973; **288**:648-50.
- 5 Warren RG, Brown SM, Wroblewska Z, Gilden D, Koprowski H, Subak-Sharpe J. Isolation of latent herpes simplex virus from the superior cervical and vagus ganglions of human being. *N Engl J Med* 1978; **298**: 1068-9.
- 6 Gundersen T. Herpes corneae, with special reference to its treatment with strong solution of iodine. *Arch Ophthalmol* 1936; **15**:225-49.
- 7 Laibson PR, Leopold IH. An evaluation of double-blind IDU therapy in 100 cases of herpetic keratitis. *Trans Am Acad Ophthalmol Otolaryngol* 1964; **68**:22-34.
- 8 Sood NN, Marmion VJ. Superficial herpetic keratitis treated with 5-iodo-2'-deoxyuridine. *Br J Ophthalmol* 1964; **48**:609-14.
- 9 Norn MS. Dendritic (herpetic) keratitis. I. Incidence, seasonal variations, recurrence rate, visual impairment, therapy. *Acta Ophthalmol (KGh)* 1970; **48**:91-107.
- 10 Thygeson P, Kimura SJ, Hogan MJ. Observations on herpetic keratitis and keratoconjunctivitis. *Arch Ophthalmol* 1956; **64**:375-88.
- 11 Cobo LM, Coster DJ, Rice NSC, Jones BR. Prognosis and management of corneal transplantation for herpetic keratitis. *Arch Ophthalmol* 1980; **98**: 1755-9.
- 12 Easty D, Entwistle C, Funk A, Witcher J. Herpes simplex keratitis and keratoconus in the atopic patient. A clinical and immunological study. *Trans Ophthalmol Soc UK* 1975; **95**:267-76.
- 13 Terni M, Roizman B. Variability of herpes simplex virus: isolation of two variants from simultaneous eruptions at different sites. *J Infect Dis* 1970; **121**:212-6.
- 14 Miglior M, Su di un caso di cheratite erpetica bilaterale contemporanea. *Boll Oculist* 1954; **33**: 491-4.