

# Quantitative trabeculectomy

ROBERT DAVID AND URIEL SACHS

*From the Department of Ophthalmology, Soroka Medical Center, Faculty of Health Sciences, Ben-Gurion University of the Negev, Beer-Sheba, Israel*

**SUMMARY** The technique and results of a trabeculectomy are presented where the desired final intraocular pressure (IOP) is obtained by means of adjusting the thickness of sclerocorneal tissue removed to the initial pressure. The procedure was used in 35 eyes with all types of glaucoma and pre-operative pressures of up to 50 mmHg. In 78.3% of cases one operation was sufficient to control the IOP without additional medication. Two eyes had to be reoperated on, and 7 more needed additional pressure-lowering medication. The overall success rate, therefore, rose to 97.3%. The only failure occurred in an eye with irreducible acute angle-closure glaucoma where malignant glaucoma complicated the trabeculectomy. Complications included hyphaema (3), shallow anterior chamber (7)—with or without choroidal detachment—and transient rise in the IOP. All complications subsided with conservative therapy.

In their search for a safe antiglaucoma procedure surgeons all over the world adopted trabeculectomy rapidly after its introduction by Cairns in 1968.<sup>1</sup> Several modifications to the original technique have since been described,<sup>2–6</sup> but it seems that the common aim of all is the production of an optimal subconjunctival filtration, avoiding the potentially dangerous cystic blebs which used to accompany the successful 'classical' filtration procedures.

In the present study the technique and results of trabeculectomy are presented, where the thickness of the scleral flap was premeditatedly 'tailored' according to the height of the untreated, preoperative IOP and a desired decrease in pressure aimed for.

## **Patients and methods**

Thirty-one patients (35 eyes) were subjected to trabeculectomy. All patients were treated conservatively for prolonged periods of time prior to surgery and only after the various regimens had failed to control the IOP and the patients were continuously losing visual function was surgery performed.

## **TECHNIQUE**

The operations were performed under retrobulbar anaesthesia and the Zeiss OP-MI 6 microscope was used throughout. The technique is based on the modified trabeculectomy described by Watson,<sup>2</sup> and

as a first choice the upper nasal quadrant is preferred as the site for surgery.

A subconjunctival injection of 0.3 ml of saline makes dissection of the limbal based, 6 mm high, conjunctival flap much easier. The now swollen Tenon's capsule is raised as a second layer and carefully undermined. In young patients and those of pigmented races the Tenon's capsule is removed from the entire surgical area. A 4×4 mm scleral area is demarcated by cautery and consequently the scleral flap of this size is raised. In accordance with the preoperative IOP the thickness of the flap is chosen between 1/2 and 1/5 of the sclera (see Fig. 1), under high magnification. The flap is dissected forward into clear cornea. A 3×3 mm inner layer is then dissected from the underlying ciliary body and iris root and removed by cutting the anterior hinge with curved, pointed Vannas scissors. The iridectomy performed is basal, 2–3 mm wide, coinciding with the area of the trabeculectomy.

The scleral flap is replaced and loosely sutured with two 10:0 nylon sutures at the scleral corners. When the anterior chamber is flat, it is refilled by injecting saline via the lateral or medial scleral opening. Before the conjunctiva is closed, reflux of aqueous is ascertained by a gentle depression of all 3 scleral edges of the wound. The conjunctiva and Tenon's capsule (when not removed) are sutured with running, continuous 7:0 silk. Gentamicin 15 mg and betamethasone 2 mg are injected subconjunctivally, and the eye is padded.

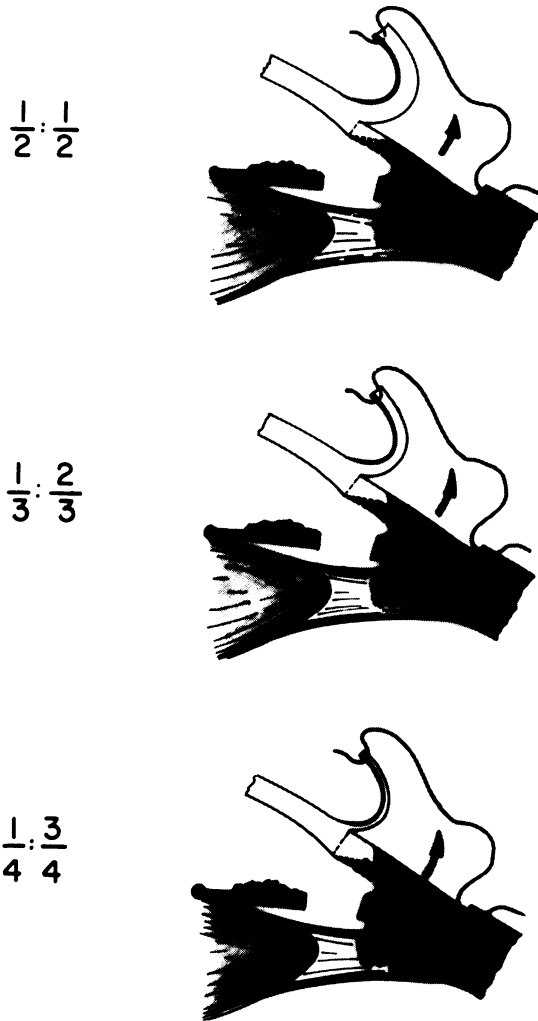


Fig. 1 The difference in thickness of the scleral flap.

Postoperative care is atropine (twice daily) and a steroid antibiotic compound (4 times daily); the conjunctival suture is removed on the patient's discharge, usually after 7 days.

Unless the anterior chamber is very shallow, gentle massage of the globe is performed twice a day. This is done under direct slit-lamp control, with the upper lid raised and pressure directed by the examiner's finger on the globe at the 6 o'clock area. As a rule the bleb rises promptly. While in hospital the patient is taught to perform the massage correctly and instructed to continue it for a few weeks after discharge.

Patients are seen weekly for the first month and monthly thereafter for the next 5 months. The topical medication is discontinued after 3 months. In the

present study patients were followed up for 7 months to 2 years (average 14.8 months).

The preoperative IOP varied from 23 to 51 mmHg. The different types of glaucoma operated on are listed in Table 1.

**Results**

Trabeculectomy was performed on 35 eyes of 31 patients. The thickness of the deep scleral layer removed depended on the initial IOP (see Table 2).

Thirty-two operations were successful and resulted in a constantly reduced IOP to less than 21 mmHg, with or without additional medication (91.4%). Of these, 19 eyes have a shallow, diffuse filtration bleb under the conjunctiva, and the pressure is controlled without medical therapy. Of the remaining 13 eyes without bleb 7 need additional medication, while the other 6 have normal pressure without visible subconjunctival filtration and no therapy.

Two eyes—one with chronic angle-closure glaucoma and another after an irreducible attack of acute angle closure—needed reoperation 4 and 6 months after the initial trabeculectomy, the second operation successfully controlling the pressure. If one adds these 2 cases to the 32 eyes in which the first operation was successful, good pressure control was obtained by quantitative trabeculectomy in 34 out of 35 eyes operated upon (97.1%).

**COMPLICATIONS**

In one eye following an acute attack of angle-closure glaucoma, treated by a peripheral iridectomy, pressure remained between 40 and 50 mmHg and the angle did not reopen. As the pressure was refractory to any medication, a trabeculectomy was performed, and it was complicated by malignant glaucoma.

Table 1 The types of glaucoma operated on

Open-angle glaucoma	19
Chronic angle-closure glaucoma	5
Acute (irreducible) angle-closure glaucoma	3
Developmental glaucoma	3
Congenital glaucoma	2
Aphakic glaucoma	2
Contusion glaucoma	1
Total	35

Table 2 Thickness of sclerocornea removed under the flap adjusted to the IOP

Preoperative IOP	Thickness of tissue removed	Eyes
Less than 26 mmHg	1/2	2
26-30 mmHg	2/3	5
31-40 mmHg	3/4	17
More than 40 mmHg	4/5	11

In 3 eyes there was a transient hyphaema which cleared up in 3 to 6 days. In 7 other eyes there was a shallow or flat anterior chamber on the first or second postoperative day, and in 4 of these a choroidal detachment was visible. In all cases the chamber reformed under conservative treatment within 4 to 8 days. In 1 eye, however, it took 12 days (!) for the chamber to reform properly and the choroidal detachment to resorb. This patient has now been followed up for 15 months and has a good filtration bleb and a pressure of 16 mmHg.

In 16 eyes a transient rise in the IOP followed surgery. This occurred between the first and the sixth weeks after the operation. In most cases it was treated by massaging the globe as described above and the pressure decreased gradually, usually with bleb formation. In a few of these cases, especially with poor visual field, medication was given in addition to the massage. This succeeded in reducing the pressure, and the drugs could be withdrawn after 3–5 weeks, when they became unnecessary.

No cataracts have developed throughout the follow-up period in any of the operated eyes.

## Discussion

When trabeculectomy was introduced, it was stated that it acted by enabling passage of aqueous through the cut ends of Schlemm's canal. This was questioned later when histological examinations<sup>7</sup> and fluorescein studies<sup>8</sup> found Schlemm's canal impenetrable after successful surgery.

As experience was gained throughout the years it was noted that the rate of success coincided roughly with the presence of a subconjunctival filtration.<sup>9–11</sup> Some authors soon concluded that trabeculectomy is just another filtration procedure, but much safer owing to the protective scleral shield.<sup>9 11 12</sup> Because of this restricted filtration it has been stated that the decrease in IOP following trabeculectomy is less than that obtained with the 'classical' filtration procedures.<sup>13 14</sup>

Today it is accepted that trabeculectomy works in more than one way<sup>8</sup> (and J. E. Cairns, personal communication), but the presence of a diffuse, shallow, subconjunctival filtration proves that percolation of aqueous through the scleral flap is playing a major role in the success of this operation. Furthermore in experimental work on cadaver eyes Shields *et al.*<sup>15</sup> reported that the increased outflow after trabeculectomy is inversely related to the thickness of the scleral flap. Therefore leaving a thinner flap reduces the resistance to aqueous flow, and by carefully adjusting

its thickness the desired reduction in the IOP can be obtained.

The relatively low rate of complications and the fact that no cataracts developed in these patients suggest that the procedure can still be classified among the well-guarded filtrations, as all the other trabeculectomies are. In this respect the results presented here do not confirm the complication rate found by other authors.<sup>6 16</sup> Not only does the operation aim to provide filtration, but one can plan ahead for a desired final postoperative pressure, which obviously should differ from patient to patient.

Quantitative trabeculectomy was performed on all types of glaucoma, and it included 5 eyes which underwent other filtering procedures in the past which had failed. Therefore it can be stated that it is a safe, universally employable procedure, the only prerequisite being the mastering of microsurgical techniques under high magnification.

## References

- Cairns JE. Trabeculectomy. Preliminary report of a new method. *Am J Ophthalmol* 1968; **66**: 673–9.
- Watson PG. Trabeculectomy. A modified ab externo technique. *Ann Ophthalmol* 1970; **2**: 199–206.
- Jackson AH. Lamellar limboscleral trephination in the surgical treatment of glaucoma. *Ann Ophthalmol* 1973; **5**: 1137–40.
- Krasnov MM. A modified trabeculectomy. *Ann Ophthalmol* 1974; **6**: 178–82.
- Dellaporta A. Experiences with trepano-trabeculectomy. *Trans Am Acad Ophthalmol Otolaryngol* 1975; **79**: 362–71.
- Shimek RA, Williamson RW. Trabeculectomy with cautery. *Ophthalmic Surg* 1977; **8**: 35–9.
- Rich AM, McPherson SD. Trabeculectomy in the owl monkey. *Ann Ophthalmol* 1973; **5**: 1082–5.
- Benedikt O. The mode of action of trabeculectomy. *Klin Monatsbl Augenheilkd* 1975; **167**: 679–85.
- D'Ermo F, Bonomi L, Doro D. A critical analysis of the long-term results of trabeculectomy. *Am J Ophthalmol* 1979; **88**: 829–35.
- Gloor B, Niederer W, Daicker B. Trabeculectomy; technique, results and indications. *Klin Monatsbl Augenheilkd* 1977; **170**: 241–8.
- Thyer HW, Wilson P. Trabeculectomy. *Br J Ophthalmol* 1972; **56**: 37–40.
- Galin MA, Boniuk V, Robbins RM. Surgical landmarks in trabeculectomy. *Am J Ophthalmol* 1975; **80**: 696–701.
- Spaeth GL, Joseph NH, Fernand E. Trabeculectomy: re-evaluation after three years and a comparison with Scheie's procedure. *Trans Am Acad Ophthalmol Otolaryngol* 1975; **79**: 349–61.
- Luntz MH. Indications for different filtering operations in glaucoma surgery. *S Afr Arch Ophthalmol* 1976; **3**: 177–9.
- Shields MB, Bradbury MJ, Shelburne JD, Bell SW. The permeability of the outer layers of limbus and anterior sclera. *Invert Ophthalmol Visual Sci* 1977; **16**: 866–9.
- McPherson SD Jr, Cline JW, McCurdy D. Recent advances in glaucoma surgery, trabeculectomy and trabeculotomy.