

Sorsby's pseudoinflammatory macular dystrophy

A. HOSKIN, K. SEHMI, AND A. C. BIRD

From the Department of Clinical Ophthalmology, Institute of Ophthalmology, Moorfields Eye Hospital, City Road, London EC1V 2PD

SUMMARY Forty-three additional members of a family described originally by Sorsby and Mason have been examined in order to typify pseudoinflammatory macular dystrophy more accurately. Six new affected members were identified by history alone and a further 7 were examined. Vision is lost from disciform macular degeneration generally during the 5th decade of life. Thereafter peripheral degeneration occurs in some affected members. Before loss of vision the fundus changes include fine drusen-like deposits at the level of Bruch's membrane, angioid streaks, and plaque-like deposits of yellow subretinal material in the macular region. These changes are different from those seen in dominant drusen.

In 1949 Sorsby and Mason¹ described 5 families with dominantly inherited macular dystrophy in which affected members suffered bilateral central visual loss in the fifth decade of life. Duke-Elder and Perkins² referred to the condition as pseudoinflammatory macular dystrophy. The maculae showed subretinal haemorrhage, accumulation of fibrous tissue under the retina, and choroidal atrophy. These changes were very suggestive of disciform degeneration, and fluorescein fundus angiography has demonstrated the presence of subretinal vascular tissue arising from the choroid.³ Sorsby and Mason¹ also described progressive atrophy of the peripheral choroid and the retinal pigment epithelium in later life causing severe visual disability.

A histological study⁴ was performed on 2 affected members of one of the families reported by Sorsby and Mason.¹ Unfortunately, conclusive evidence of dominant inheritance was not available in this family. The histological changes demonstrated were thickening of Bruch's membrane, which was ruptured in several places, and fibrovascular invasion of the subpigment epithelial space from the choroid. Drusen were also shown in one case. Despite the clinical appearance of profound choroidal atrophy, the histological study showed atrophy of the choriocapillaris only, with relative preservation of the larger choroidal vessels. It was considered that the atrophy of the choroid was no greater than was commonly seen in the eyes of old people who showed no associated

changes in Bruch's membrane or subretinal new-vessel formation and that choroidal vascular closure was not the primary cause of the disorder.

The predisposing changes in the posterior pole have yet to be accurately defined. Younger members of these families have been reported to have pigment epithelial atrophy⁵ and colloid bodies.⁶ Deuteranomaly has also been described in young members as a dominant trait⁷ and this may well represent the functional correlate of these predisposing changes.

Doubt has been expressed whether the high incidence of disciform degeneration and the presence of peripheral choroidal degeneration indicate that the disease process described was fundamentally different from dominant drusen or whether these families had been selected on the basis of severity alone.⁸ Recently additional members of a family described in the original paper by Sorsby and Mason¹ (Ewbank family) have been examined and are described in this paper.

Patients and methods

Forty-three members of one family were examined (Fig. 1): 41 were descendants of I/1 by his first marriage and the remainder by his second. Sorsby was aware of the first marriage but had no details of the descendants except that 'there were children'.

In addition to a full clinical examination colour vision was assessed by Panel D-15, fundi were photographed, most had fluorescein angiography, and electro-oculography (EOG), electroretinography (ERG), and macular ERG⁹ were undertaken in

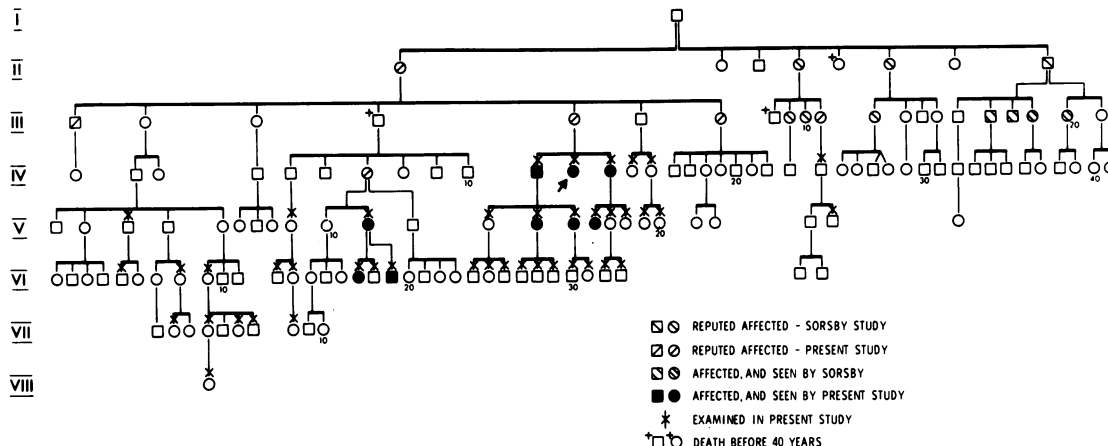


Fig. 1 Extension of the Ewbank family pedigree, originally described by Sorsby and Mason.¹

selected patients who had normal vision but were at risk of having the abnormal gene.

Results (See Table 1)

Six new affected members were identified by history alone: II/1 and III/1 both lost reading vision in their early 40s and had progressive loss of peripheral vision during the sixth decade of life such that they could not navigate alone by the age of 70. III/5 died at the age of 52, by which time she could not read. III/7 lost reading vision before the age of 40 but subsequently her vision remained stable. III/12 could not read after 54 years and was not independently mobile after 70 years. IV/7 had loss of RE visual acuity at 43 years followed a year later by loss of LE central vision; no further loss has occurred since.

Seven members were seen who had suffered loss of vision: IV/11 and IV/13 both lost central vision in their early 40s and thereafter had progressive loss of peripheral field. At the time of the study neither

could walk unguided; each had large fibrous disciform lesions bilaterally and widespread peripheral atrophy of the retina and choroid. IV/12 lost central vision in the fifth decade of life but vision had subsequently remained stable. She had bilateral old disciform lesions and densely packed fine drusen between 20-25° and from the fovea (Fig. 2). V/11 was first seen with distortion of the left eye vision at the age of 39 years. On examination there appeared to be a confluent deposition of yellow debris beneath the macular neuroretina which was within or just deep to the retinal pigment epithelium bilaterally (Fig. 3a) and a small disciform lesion inferonasal to the left fovea. On fluorescein angiography the yellow material corresponded with choroidal hypofluorescence during the early stages of the study, becoming slightly hyperfluorescent within 10 minutes of initial dye entry (Fig. 3b-d). The major choroidal blood vessels could be seen within the lesion. The left eye showed an identical change in the appearance of the choroid and the subretinal blood vessels (Fig. 3e). The subretinal

Table 1 Summary of findings in those patients with phenotypic expression of the abnormal gene

Patient	Year of birth	Age at visual loss		VA		Fundus changes
		RE	LE	RE	LE	
IV/11	1907	43	41	PL	CF	Bilateral disciform lesions Widespread peripheral atrophy
IV/12	1910		'In 40s'	CF	CF	Bilateral disciform lesions
IV/13	1913	49	39	CF	CF	Bilateral disciform lesions Widespread peripheral atrophy
V/11	1933		45	6/9	CF	RE: Yellow subretinal deposit at macula LE: Yellow subretinal deposit and disciform lesion
V/14	1932	38	38	6/60	CF	Bilateral disciform lesions and angioid streaks
V/15	1936			6/6	6/12	Bilateral angioid streaks and drusen
V/16	1937	37	38	6/60	6/60	Bilateral disciform lesions and drusen
VI/17	1955			6/6	6/6	Bilateral fine drusen
VI/19	1965			6/6	6/6	Accumulation of yellow subretinal material at maculae

VA=visual acuity. RE=right eye. LE=left eye.

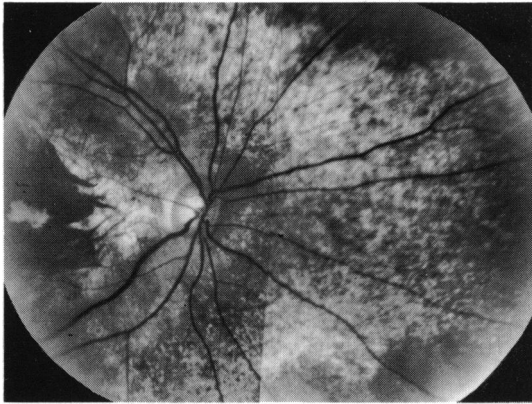

Fig. 2 Right fundus of IV/12 showing densely packed fine drusen around the optic disc.

neovascular tissue grew despite photocoagulation with consequent loss of visual acuity (Fig. 3f,g). V/14 lost visual acuity of both eyes within a 9-month period due to disciform macular lesions. Examination showed large fibrous subretinal lesions; elsewhere in the posterior poles there were densely packed fine drusen and angioid streaks radiating from the optic

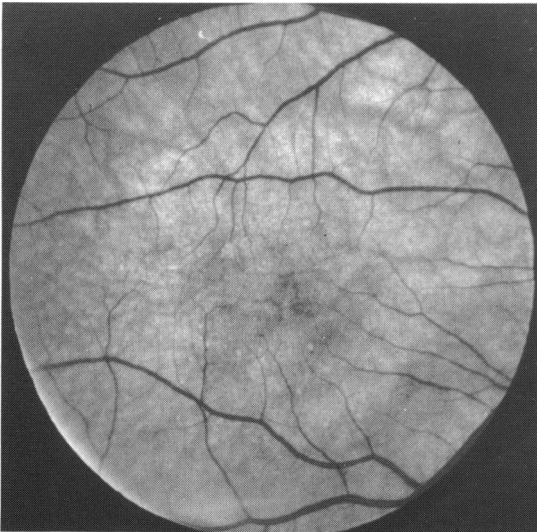


Fig. 3a

discs (Fig. 4). V/16 had lost visual acuity at 38 and 39 years. She had large fibrous disciform lesions at both maculae but the fundi were otherwise normal, apart from minor retinal pigment epithelial irregularities (Fig. 5).
A further 8 subjects were seen who were at 50% risk of having the abnormal gene, had normal vision, but were under the age of 45. Of these, 3 had fundus abnormalities: V/15 and V/17 had fine drusen-like deposits at the level of Bruch's membrane, and one, V/15, had angioid streaks (Fig. 6a,b). The other (VI/8), had an even yellow deposit beneath the retina

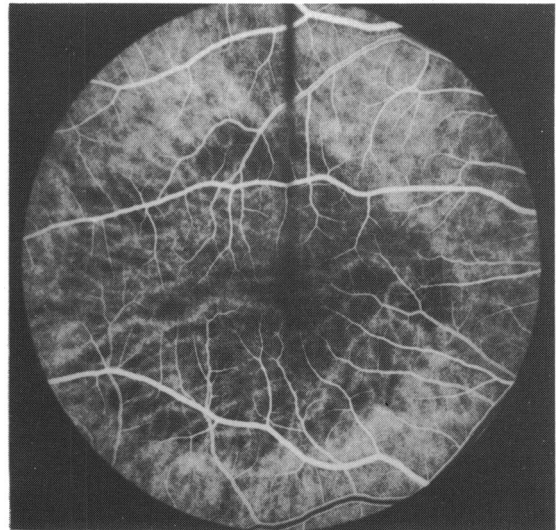


Fig. 3b

discs (Fig. 4). V/16 had lost visual acuity at 38 and 39 years. She had large fibrous disciform lesions at both maculae but the fundi were otherwise normal, apart from minor retinal pigment epithelial irregularities (Fig. 5).

A further 8 subjects were seen who were at 50% risk of having the abnormal gene, had normal vision, but were under the age of 45. Of these, 3 had fundus abnormalities: V/15 and V/17 had fine drusen-like deposits at the level of Bruch's membrane, and one, V/15, had angioid streaks (Fig. 6a,b). The other (VI/8), had an even yellow deposit beneath the retina

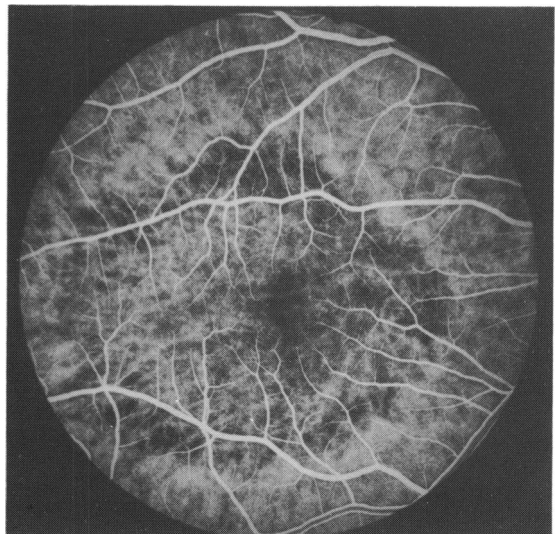


Fig 3c

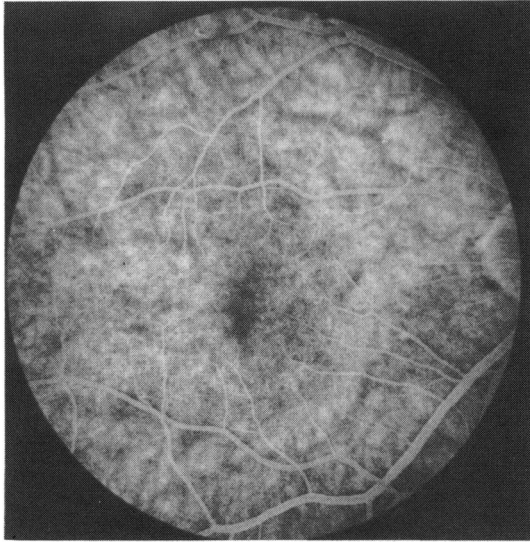


Fig. 3d

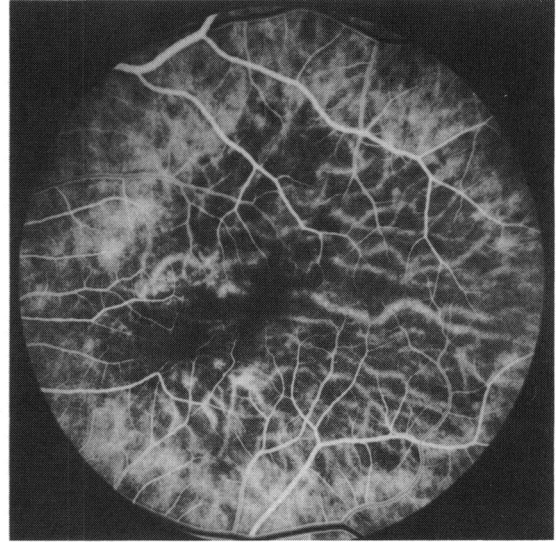


Fig. 3f

which obscured choroidal fluorescence during the early part of fluorescein angiography but not in the later stages. This change was similar to that seen in his mother (V/11). None had abnormalities of EOG light induced rise in ocular potential, mass ERG, or macular ERG. Colour vision was also normal in all as tested on the Panel D-15.

Discussion

As a result of this study several conclusions can be

drawn. The pattern of visual loss is identical to that described by Sorsby and Mason¹ and subsequent papers^{2,3,5-8} with loss of central vision due to disciform lesions occurring in the fifth decade of life. The earliest visual loss identified in this family was 37 years (V/16), and good visual acuity was maintained in one patient into the sixth decade of life (III/11). The interval between visual loss in the 2 eyes varied from 9 months to 10 years.

The subsequent progressive peripheral chorio-retinal atrophy causing loss of peripheral field is well

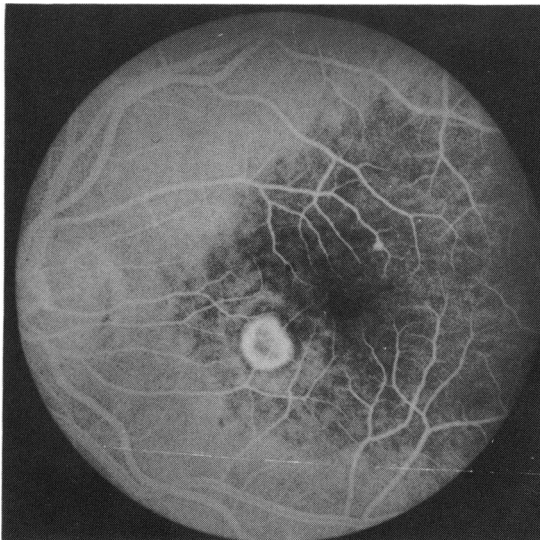


Fig. 3e

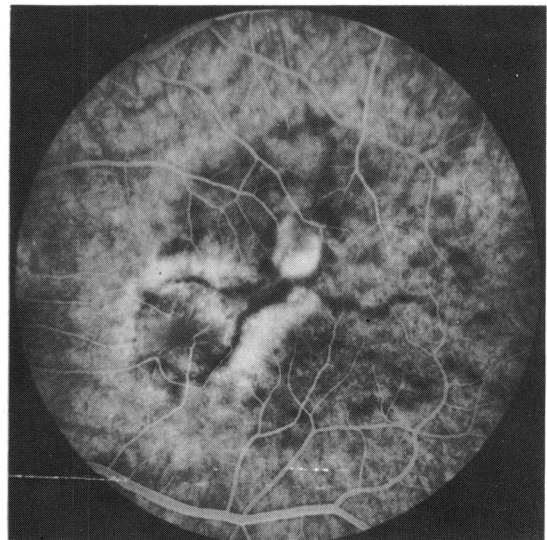


Fig. 3g

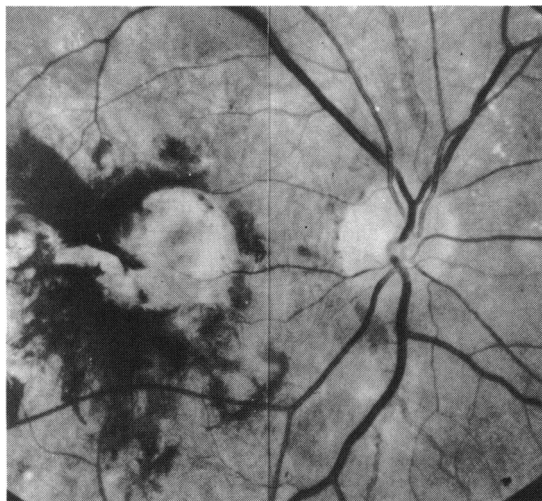


Fig. 4 Right eye of V/13 with a large disciform lesion and angioid streaks radiating from the optic disc.

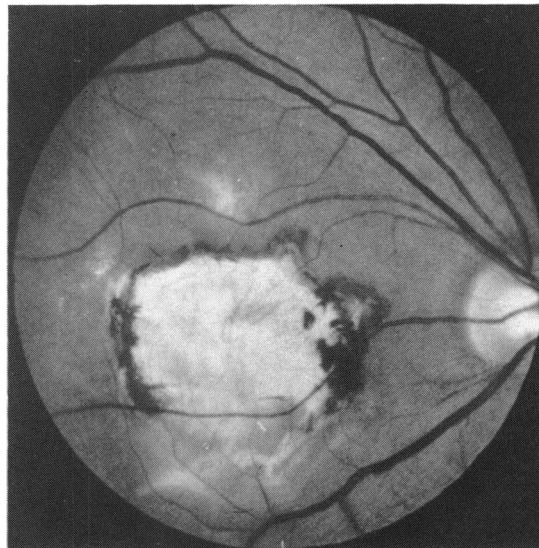


Fig. 5 V/16 showing a disciform lesion at the posterior pole, but the fundus otherwise appears relatively normal.

described by Sorsby and Mason¹ but has received little emphasis since that time. This was identified in 5 (3 by history) out of 8 affected patients reaching the age of 70 years and caused social blindness in each.

Ashton and Sorsby⁴ discuss the significance of this atrophy and conclude that choroidal vascular closure is unlikely to be the primary event in this order. The alternative explanation is that this atrophy is second-

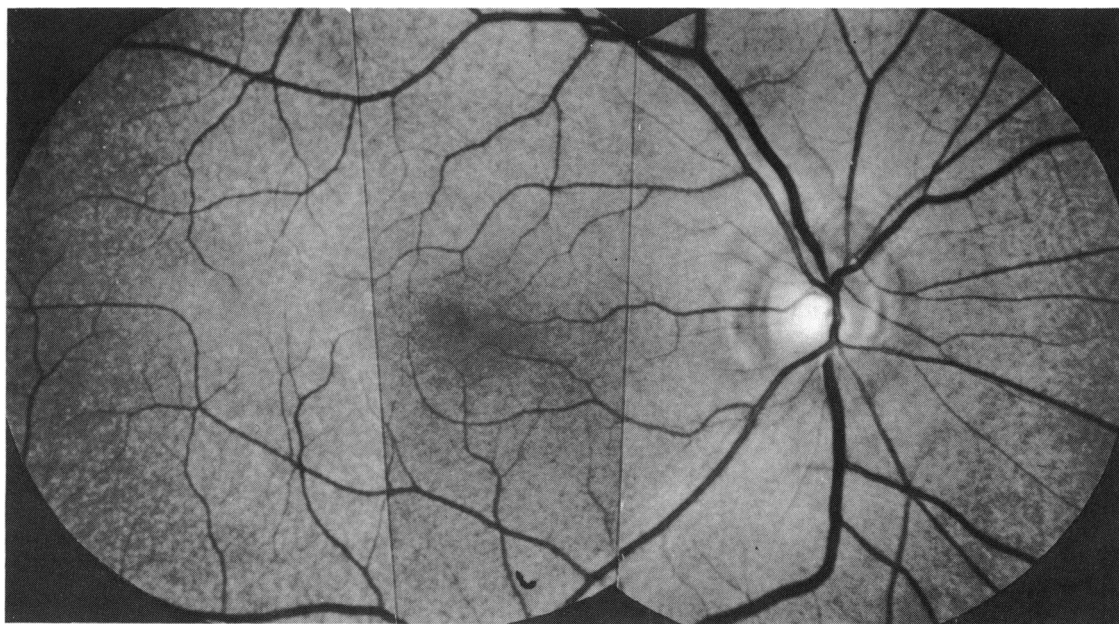


Fig. 6a

Fig. 6 Red-free (a) and fluorescein angiogram (b) of the right eye of V/16 showing diffuse, fine drusen-like deposits and angioid streaks radiating from the optic disc.

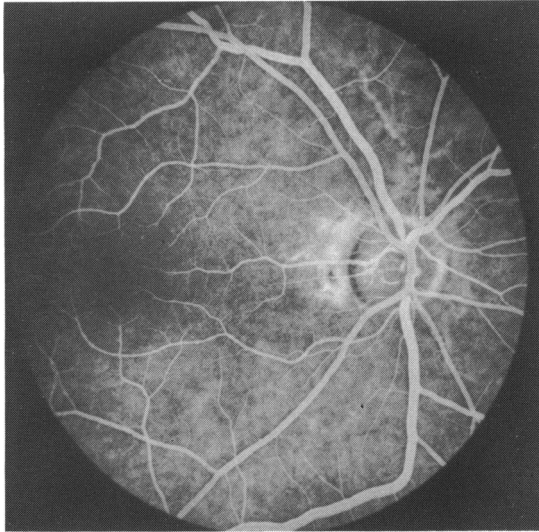


Fig. 6b

ary to loss of retinal pigment epithelium and outer retina.

The fundus changes identified in those at risk of visual loss and in one eye of a patient with a unilateral involvement imply accumulation of abnormal subretinal material. In 3 this took the form of diffuse fine drusen-like deposits, evenly distributed over the whole of the posterior fundus. Similar changes were seen outside the area of the disciform lesion in older affected members of this family. In 2 patients the abnormal deposit consisted of a large confluent yellowish plaque centered at the fovea which caused obscuration of choroidal fluorescence during the dye transit on fluorescein angiography but which later fluoresced normally. The free access of dye into this material suggests that it is in Bruch's membrane or alternatively in retinal pigment epithelial cells which themselves are incompetent of dye. The visibility of large choroidal blood vessels within this area indicates that obscuration does not fully explain the choroidal hypofluorescence. Abnormal perfusion of the choriocapillaris in this area of the fundus is implied, and the later hyperfluorescence shows that choroidal filling is delayed rather than absent.

In its 2 clinical forms this material is markedly different from that seen in dominantly inherited drusen, in which large discrete elevated deposits occur beneath the retinal pigment epithelium.⁹⁻¹²

Sarks¹³ has described 2 distinct patterns of deposition of abnormal subretinal material in age related disease. Drusen occur beneath the basement membrane of the retinal pigment epithelium and may be related to a disorder of clearing phagosomal products from the pigment epithelial cells. The basal linear

deposits seen later in the process occur at the level of the pigment epithelial basement membrane and probably consist of basement membrane material. Clinical evidence suggests that the process in this family differs from that in dominant drusen, though it is possible that the basic defect in each represents an alteration in processing of phagosomal products and in production of retinal pigment epithelial basement membrane. The choroidal changes seen in the early stage of the disorder in 2 patients in this family does not necessarily imply that the choroid is the primary site of disease, since it is recognised that deposition of abnormal material at the level of Bruch's membrane causes secondary changes in the choriocapillaris.

The accumulation of debris appears to be the initial clinical abnormality and was seen consistently in affected patients. It is likely that this is an integral part of the disorder rather than a nonspecific sign of degeneration as was suggested by Ashton and Sorsby.⁴ That drusen were not seen at the late stage of disease in one of their cases in which there was widespread receptor loss is not surprising in view of the resolution of drusen described by Gass.¹⁴

Angioid streaks which were seen in 2 members (V/14, 15) have not been previously recorded clinically in this condition but their presence was implied by the histopathological studies of Ashton and Sorsby.⁴

Visual loss was due to a disciform lesion in each affected member seen and the rapid loss of vision in older relatives implies a similar process. No patient has yet been recorded in whom central visual loss was due to geographic atrophy. The disciform lesions were always large, which contrasts with many other conditions causing disciform lesions in the young. This may be a reflection of diffuse rather than multifocal disease at the level of Bruch's membrane in this disorder.

The evidence in this family suggests that pseudo-inflammatory macular dystrophy as described by Sorsby and Mason is a specific autosomal dominant disease distinct from dominant drusen and from other autosomal dominant fundus dystrophies.

This work was supported in part by MRC grant no. G976/618. A.H. was aided by the A. E. Baker grant (Canadian National Institute for the Blind).

References

- 1 Sorsby A, Mason MEJ. A fundus dystrophy with unusual features. *Br J Ophthalmol* 1949; 33: 67-97.
- 2 Duke-Elder S, Perkins ES. Diseases of the uveal tract. *System of Ophthalmology*. London: Kimpton, 1966; 9: 715-9.
- 3 Rosen ES, Leighton D. Fluorescein photography of generalised dominant fundus dystrophy. *Br J Ophthalmol* 1968; 52: 828-32.
- 4 Ashton N, Sorsby A. Fundus dystrophy with unusual features. a histological study. *Br J Ophthalmol* 1951; 35: 751-64.

- 5 Sorsby A, Davey JB. Dominant macular dystrophies. *Br J Ophthalmol* 1955; **39**: 385-97.
- 6 Burn RA. Further cases of fundus dystrophy with unusual features. *Br J Ophthalmol* 1950; **34**: 393-403.
- 7 Fraser HB, Wallace DC. Sorsby's familial pseudoinflammatory macular dystrophy. *Am J Ophthalmol* 1971; **71**: 1216-20.
- 8 Bird AC. Bruch's membrane degenerations I. Disciform macular degeneration. *Hereditary Retinal and Choroidal Disease*. Harper and Row, 1977; chapter 17: 825-45.
- 9 Arden GB, Carter RM, Hogg C, Siegel IM, Margolis S. A gold foil electrode. Extending the horizons for clinical electroretinography. *Invest Ophthalmol Visual Sci* 1979; **18**: 421-6.
- 10 Doyne RW. Peculiar condition of choroiditis occurring in several members of the same family. *Trans Ophthalmol Soc UK* 1910; **30**: 93-5.
- 11 Pearce WG. Hereditary macular dystrophy. A clinical and genetic study of two specific forms. *Can J Ophthalmol* 1975; **10**: 319-25.
- 12 Deutman AF, Jansen LMAA. Dominantly inherited drusen of Bruch's membrane. *Br J Ophthalmol* 1970; **54**: 373-83.
- 13 Sarks S. Drusen and their relationship to senile macular degeneration. *Aust J Ophthalmol* 1980; **8**: 117-30.
- 14 Gass JD. Drusen and disciform macular detachment and degeneration. *Arch Ophthalmol* 1973; **90**: 206-17.