

Prostatic carcinoma metastatic to choroid

J. PAUL DIECKERT¹ AND BRIAN B. BERGER²

From the ¹Scott and White Memorial Hospital, Scott, Sherwood and Brindley Foundation, and the ²Division of Ophthalmology, Scott and White Clinic, Texas A & M University College of Medicine, Temple, Texas 76508, USA

SUMMARY Metastatic prostatic carcinoma of the choroid became clinically undetectable after orchidectomy and oestrogen administration. The choroidal tumour rapidly regressed over a 2-month period and clinically disappeared, with restoration of 6/6 vision from 6/60 and return of visual field. This dramatic response and lack of complications make hormonal manipulation the preferred mode of initial therapy in prostatic carcinoma metastatic to the choroid.

In 1872 Perls reported the first case of carcinoma metastatic to the choroid.¹ Since that time well over 400 cases have been reported.^{2,3} The predominant sources of metastatic carcinoma to the choroid have been lung in men and breast in women.² There have been at least 7 reported cases of prostatic carcinoma metastatic to the choroid.^{2,4–9}

This report describes a case of prostatic carcinoma metastatic to the choroid in which hormonal therapy caused complete clinical regression of the metastasis and full return of visual function. To our knowledge this response has not been previously reported with a choroidal metastasis from prostatic carcinoma.

Case report

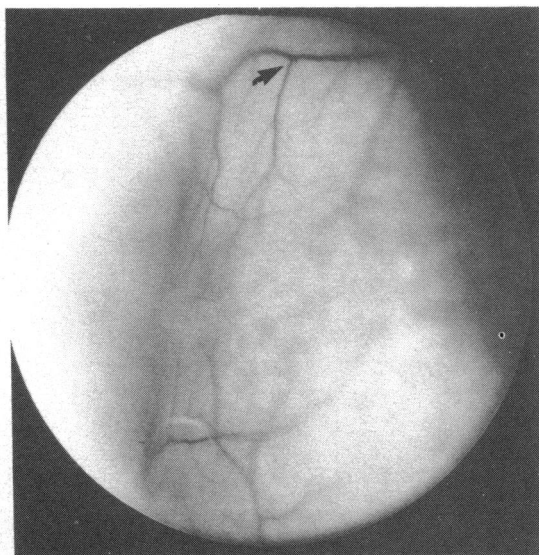
A 54-year-old white male was referred to the Scott and White Clinic for evaluation of decreased vision in his left eye of 4 months' duration. His past medical history consisted of diabetes mellitus for two years treated with 10 units of insulin per day and chronic hypertension treated with a combination of reserpine, hydralazine, and hydrochlorothiazide. Review of systems revealed impotence, sacral pain, and urinary frequency.

Eye examination revealed a best corrected visual acuity of 6/6 right eye and 6/60 left eye. The positive physical findings were confined to the left fundus. A nonpigmented choroidal tumor was present temporally extending into the fovea and approxi-

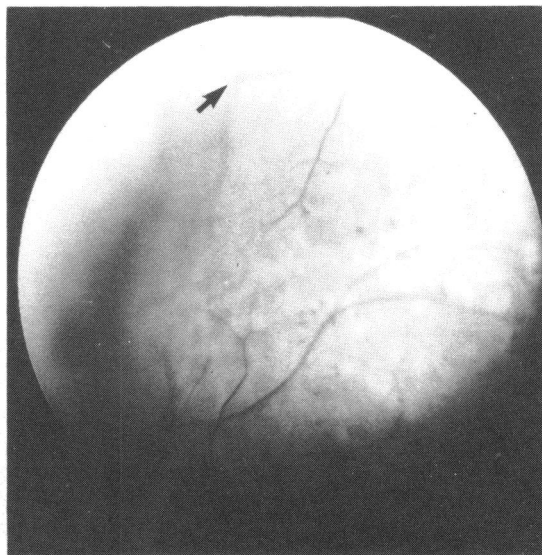
mately 9 mm vertically by 6 mm horizontally (Fig. 1A). Very minimal subretinal fluid was associated with it. B scan ultrasonography showed a choroidal tumour with moderate internal reflectivity, no choroidal excavation, and about 5 mm in thickness (Fig. 2). Fluorescein angiography showed widespread hyperfluorescence due to defects of the retinal pigment epithelium but no distinct tumour circulation (Fig. 3A). Goldmann perimetry demonstrated an absolute visual field defect nasally in the left eye (Fig. 4A).

General physical examination was unremarkable with the exception of an enlarged, nodular prostate. On laboratory testing an acid phosphatase level of 21 IU/l (normal 0–6) and a prostatic fraction of 13 IU/l (normal 0–6) was noted. Chest x-rays revealed numerous nodular densities compatible with metastatic lesions. Prostatic needle biopsy confirmed grade 3 moderately well differentiated adenocarcinoma of the prostate (Fig. 5). No lesions were demonstrable on computerised axial tomography of the head. Bone scan revealed abnormal uptake in the axial skeleton, ribs, and entire left orbit (Fig. 6).

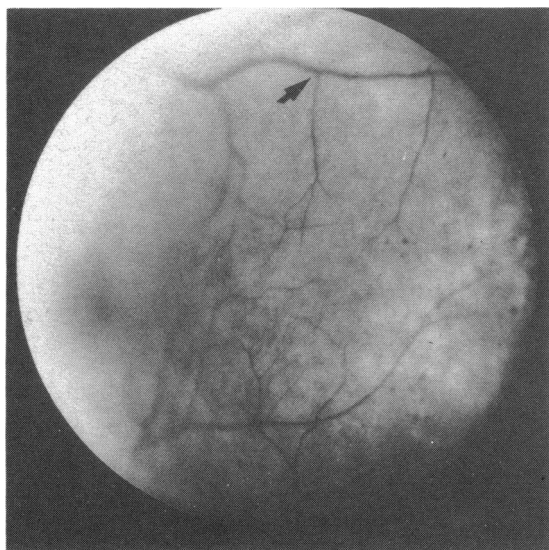
Over a period of a week the patient was treated with palliative cobalt-60 irradiation to painful bony lesions, transurethral resection of the prostate, and bilateral orchidectomy. In addition he was started on diethylstilboesterol 3 mg per day. Within 2 weeks the choroidal tumour had decreased to one-half its original size (Fig. 1B) and vision had improved to 6/15. In 4 weeks visual acuity improved to 6/6, and within 2 months the tumour was not clinically apparent (Fig. 1C). The visual field became almost



1A



1B



1C

Fig. 1 (A) Tumour at left fundus at time of presentation. (B) After 2 weeks of hormone therapy. (C) After 2 months of therapy. (Arrow indicates same vascular landmark in each figure.)

full (Fig. 4B) and the acid phosphatase level normal. The only evidence of the previous tumour was atrophy of the retinal pigment epithelium, which was prominent on fluorescein angiography (Fig. 3B). After 12 months of follow-up he is free of any ocular recurrence.

Discussion

Greenwood and Southard reported the first case of prostatic carcinoma metastatic to the choroid in

1903.¹⁰ Since then at least 4 cases have been reported in the American and 3 in the European literature.^{2,4-9} Several large series of metastatic choroidal tumours from various sites have included previously reported cases.^{2,7,8}

The usual presenting symptom is decreasing visual acuity secondary to serous retinal detachment from choroidal metastasis; however, concurrent choroidal and optic nerve involvement has been reported.⁹ Some of the reported cases received enucleation for relief of pain or diagnostic purposes. Others died

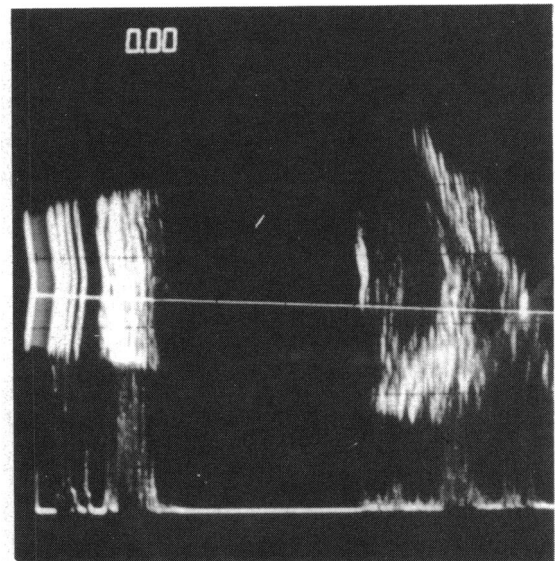
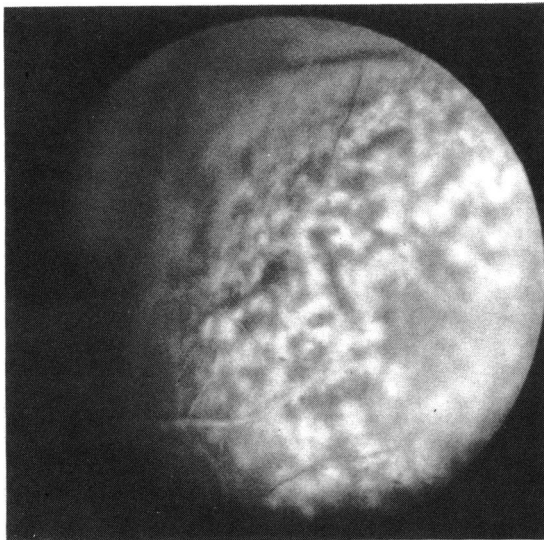
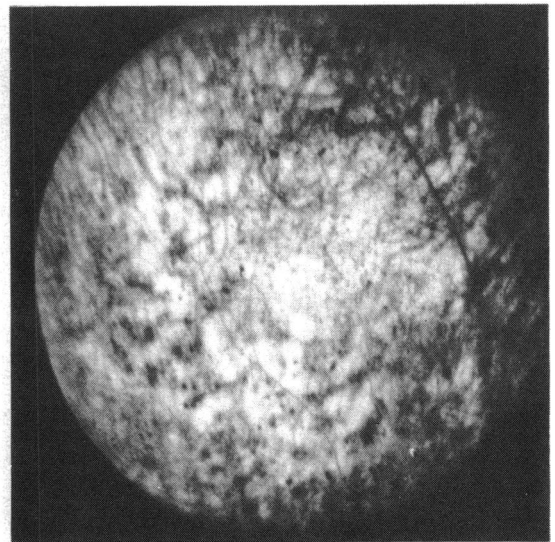


Fig. 2 Combined A and B ultrasonogram showing tumour 5 mm in thickness with moderate internal reflectivity.



3A



3B

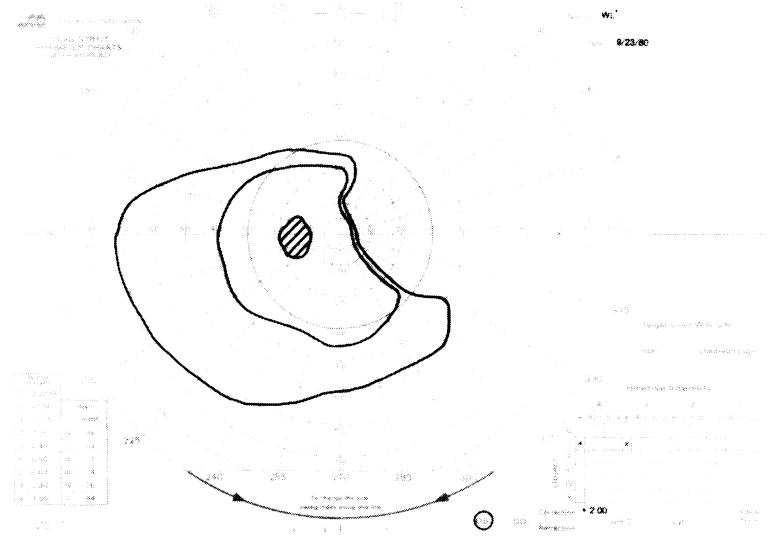
Fig. 3 (A) Fluorescein angiography showing hyperfluorescence due to window defects prior to treatment. (B) More extensive atrophy of the retinal pigment epithelium after tumour regression.

before any ocular therapy was attempted. None of the reported cases were managed with hormonal manipulation.

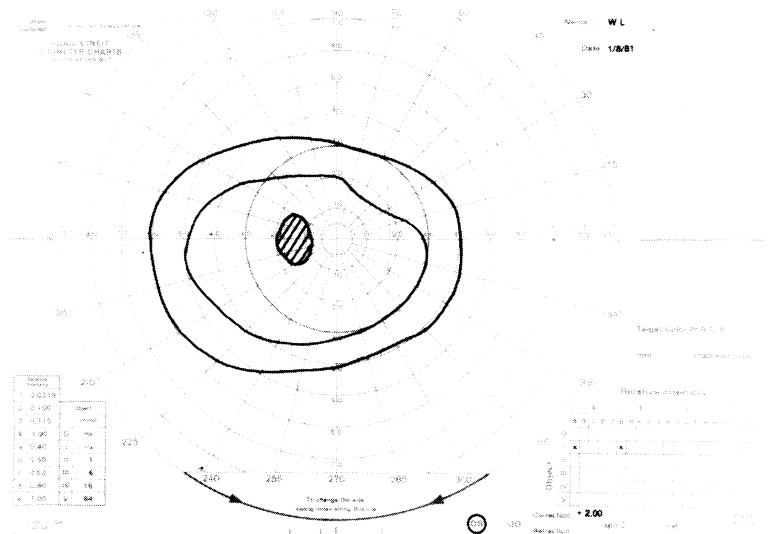
Prostatic carcinoma metastatic to the choroid accounts for only 1.7% of all choroidal metastases in the series by Hart.⁸ The incidence of choroidal metastases of all types is unknown, since no prospective studies have been done to answer this

question.^{11 12} In a retrospective study¹³ only 6 patients with choroidal metastases were found out of 8712 patients with neoplasms of all types.

The percentage of ocular metastases in those patients with prostatic carcinoma is also small. Many series do not even mention ocular metastases. One early series¹⁴ of 100 necropsies of patients with metastatic carcinoma of prostatic origin included only



4A



4B

Fig. 4 (A) Goldmann visual field of left eye at time of presentation. (B) After 4 months of therapy.

one case of ocular involvement, the same case as Greenwood and Southard reported.¹⁰

Prostatic carcinoma can metastasise to the choroid by at least 2 routes. In those individuals with metastases in the lungs, as in our case, tumour emboli pass via the pulmonary circulation into the heart and aorta. They subsequently travel up the carotid arteries to the ophthalmic artery and into the ciliary vessels and uveal tract.

If no pulmonary lesions are present, prostatic or vertebral lesions may seed into Batson's plexus. In

this way tumour emboli can bypass the pulmonary circulation and reach the cranial venous sinuses. From the cranial venous sinuses the emboli can reach the ophthalmic veins and vortex veins. Batson's plexus is valveless, and many reversals of flow are said to occur with changes in venous pressure secondary to changes in body posture and Valsalva manoeuvres.¹⁵

This case is unique in that all the patient's ocular symptoms and signs resolved with hormonal therapy. The physiological basis for hormonal therapy of metastatic prostatic tumours is well outlined by

Fig. 6 *Technetium-99 bone scan showing increased uptake in right globe (arrow), ribs, and pelvis at time of presentation.*

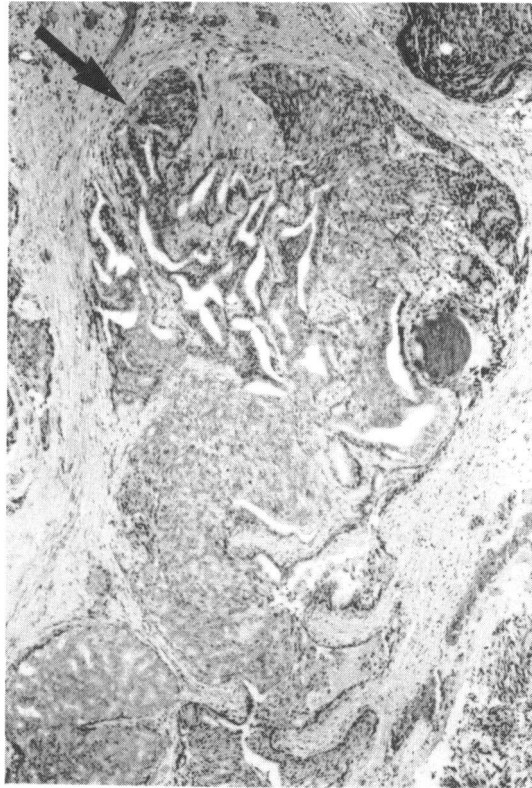


Fig. 5 *Needle biopsy of prostate showing grade 3 adenocarcinoma (arrow) ($\times 70$).*



Walsh and is beyond the scope of this report.¹⁶ Choroidal tumours derived from breast carcinoma have been shown to be responsive to hormonal manipulation.^{17,18} The time course of resolution of ocular lesions was 2 to 3 months in these cases. A similar time course was noted in our case. Exophthalmos secondary to prostatic carcinoma to the orbit has also been shown to resolve with hormonal manipulation over a similar time course.¹⁹⁻²¹

According to Reese the goals of treating metastatic tumours to the choroid are preservation of vision and prevention of pain.²²⁻²⁴ Carcinoma metastatic to the choroid has a poor prognosis, with life expectancy measured in months.^{2,24} Radiotherapy has been the treatment of choice, since it may cause tumour regression and restoration of vision over 4 to 8 weeks.^{3,25,26} Since hormonal manipulation is commonly used to treat widespread metastases from prostatic carcinoma, the effect of this form of therapy on choroidal metastases from the prostate should be observed before recommending radiation therapy.

References

- 1 Perls M. Beitrage zur Geschwulstlehre. *Virchows Archiv (Pathol Anat)* 1872; **56**: 437-67.
- 2 Ferry AP. Metastatic carcinoma of the eye and ocular adnexa. *Int Ophthalmol Clin* 1967; **7**: 615.
- 3 Stephens RF, Shields JA. Diagnosis and management of cancer metastatic to uvea. A study of 70 cases. *Ophthalmology* 1979; **86**: 1336-49.
- 4 Ask F. Bilateral metastases of choroid from prostate. *Hospitalid* 1914; **7**: 475-7.
- 5 Fehr O. Fundus picture in metastatic carcinoma of the choroid. *Klin Monatsbl Augenheilkd* 1918; **60**: 741.
- 6 Stallard HB. Cases of metastatic carcinoma of the choroid. *Proc R Soc Med* 1933; **26**: 1042.
- 7 Kulvin MM. Metastatic carcinoma of the choroid with primary focus in the prostate gland. *Am J Ophthalmol* 1940; **23**: 892-9.
- 8 Hart WM. Metastatic carcinoma to the eye and orbit. *Int Ophthalmol Clin* 1962; **2**: 465-82.
- 9 Zappia RJ, Smith ME, Andrew JG. Prostatic carcinoma metastatic to optic nerve and choroid. *Arch Ophthalmol* 1972; **87**: 642-5.
- 10 Greenwood A, Southard CF. Carcinoma of the choroid metastatic from prostate. *Boston Med Surg J* 1903; **149**: 286-9.
- 11 Albert DM, Zimmerman AW Jr. Tumor metastasis to the eye. The fate of circulating tumor cells to the eye. *Am J Ophthalmol* 1967; **63**: 733.

- 12 Bloch RS, Gartner S. The incidence of ocular metastatic carcinoma. *Arch Ophthalmol* 1971; **85**: 673–5.
- 13 Godtfredsen E. On the frequency of secondary carcinoma in the choroid. *Acta Ophthalmol (Kbh)* 1944; **22**: 394–400.
- 14 Mintz ER, Smith GG. Autopsy findings in 100 cases of prostate cancer. *N Engl J Med* 1934; **211**: 479–87.
- 15 Batson OV. The function of the vertebral veins and their role in the spread of metastasis. *Ann Surg* 1940; **112**: 138–49.
- 16 Walsh PC. Physiologic basis for hormonal treatment in carcinoma of the prostate. *Urol Clin North Am* 1975; **2**: 125.
- 17 Ellis R, Scheie H. Regression of metastatic lesion of breast carcinoma following sterilization. *Am J Ophthalmol* 1952; **35**: 1829–30.
- 18 Cogan DG, Kuwabara T. Metastatic carcinoma to eye from breast: effect of endocrine therapy. *Arch Ophthalmol* 1954; **52**: 240–9.
- 19 Bard LA, Schulze RR. Unilateral proptosis as the presenting sign of metastatic carcinoma of the prostate. *Am J Ophthalmol* 1964; **58**: 107–10.
- 20 Usui T, Ishibe T, Nihira H. Orbital metastasis from prostatic carcinoma. *Br J Urol* 1975; **47**: 458.
- 21 Harper JM, Huber WA. Unilateral exophthalmos secondary to metastatic carcinoma of the prostate: case report and review of the literature. *J Urol* 1963; **89**: 75–7.
- 22 Simpson GV. Metastatic tumor of the posterior ocular segment. *Trans Am Ophthalmol Soc* 1961; **59**: 161.
- 23 Cordes FC. Bilateral metastatic carcinoma of the choroid with x-ray therapy to one eye. *Am J Ophthalmol* 1944; **27**: 1355–70.
- 24 Reese AB. *Tumors of the Eye*. 3rd ed. New York: Harper and Row, 1976: 424–8.
- 25 Lemoine AN, McLeod J. Bilateral metastatic carcinoma of the choroid; successful roentgen treatment of one eye. *Arch Ophthalmol* 1936; **16**: 804–21.
- 26 François J, Hanssen H, Verbraken H. Intraocular metastasis as first sign of generalized carcinomatosis. *Ann Ophthalmol* 1976; **8**: 405–19.