

Subretinal neovascularisation in ocular toxoplasmosis

ARTHUR M. COTLIAR AND ALAN H. FRIEDMAN

From the Departments of Ophthalmology, Lenox Hill Hospital, and the Mount Sinai School of Medicine, New York, New York

SUMMARY Subretinal neovascularisation, a common clinical pathological entity, is seen in a variety of ocular disorders. Though inflammation is associated with the development of subretinal neovascularisation, toxoplasmosis is an unusual causative agent. Two teenagers developed a disciform lesion in the macular area due to toxoplasmosis. Clinical studies revealed subretinal neovascularisation.

Toxoplasmosis is a common ophthalmic disorder and is said to cause a considerable number of cases of posterior ocular inflammation. Different investigators have considered toxoplasmosis to be the cause of 16–70% of cases of posterior uveitis.^{1,2}

Subretinal neovascularisation is a clinical finding. It is seen in a variety of eye diseases, with the list of associated ocular disorders growing as fluorescein angiography has become more of a routine procedure for examining the posterior pole. In 1969 Friedmann and Knox³ described an uncommon form of toxoplasmosis associated with macular subretinal fluid or blood. Recently 3 cases of toxoplasmosis have been reported with associated subretinal neovascularisation.⁴ We wish to add to the relatively small number of these cases 2 well documented instances of ocular toxoplasmosis with subretinal neovascularisation.

Case reports

CASE 1

This was a 9-year-old girl first seen in April 1980. She had been referred by another ophthalmologist for evaluation of decreased vision in her left eye for the past 5 months. The exact time of onset of this symptom was unclear, it having first been noticed on a routine school screening. The patient was in good health, on no medications, and with no history of ophthalmic or general disease.

On initial examination her best corrected visual acuity was 20/20 OD, 20/400 OS, near vision J2 OD, J12 OS. Motility examination revealed a small left exotropia. The right pupil was normal, while the left

eye had a mild amaurotic pupillary reaction. Slit-lamp examination showed a normal anterior segment bilaterally.

Fundus examination of the right eye revealed 5 discrete hypopigmented lesions with bordering pigment epithelial hyperplasia, superotemporal to the disc. The posterior pole was otherwise normal. In the left fundus a normal optic disc and vasculature were noted. The macula had a large area of retinal oedema, with a yellow-white elevated lesion, and an inferotemporal subretinal haemorrhage (Fig. 1).

Pertinent laboratory studies included a positive toxoplasmosis IFA titre of 1:256, positive adenovirus titre of 1:16, negative ascaris ELISA (enzyme-linked immunosorbent assay) and negative toxocara ELISA (CDC, Atlanta, Ga.)

A fluorescein angiogram was performed one week after initial presentation. The initial vascular phase of the left eye revealed normal major vessel filling. Most of the capillary-free zone was obscured by macular exudate. During the early arteriovenous stage at least 2 areas of lacy irregular hyperfluorescence were visible in the foveal region. With time this hyperfluorescence increased markedly. The area of haemorrhage blocked the inferotemporal aspect of the fluorescence. The lesions in the right eye appeared mildly hyperfluorescent, with surrounding blocked fluorescence—corresponding to each of the chorioretinal scars superotemporal to the disc (Figs. 2 A–D). This fluorescein angiogram was interpreted as consistent with old chorioretinal scars in the right eye and active neovascularisation with subretinal haemorrhage in the left eye.

Follow-up examination performed 8 months later showed organisation of the macular exudate, with formation of a subretinal disciform scar.

Correspondence to Dr Alan Friedman, Mount Sinai School of Medicine, One Gustave L. Levy Place, New York, New York 10029, USA.

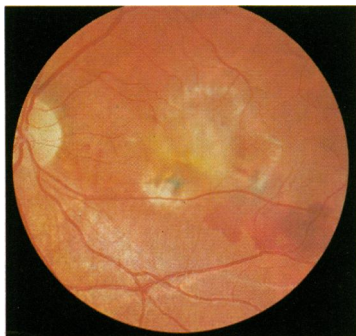


Fig. 1

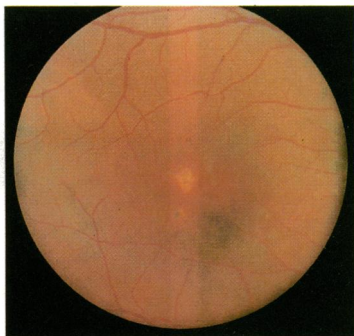


Fig. 3

Fig. 1 Fundus photograph case 1 showing a healed pigmented scar inferiorly with subretinal haemorrhage. There are 2 foci of subretinal exudation with overlying detachment of the sensory retina.

Fig. 3 Fundus photograph case 2 reveals a focus of exudation superior to fovea, with an area of pigmentation inferiorly.

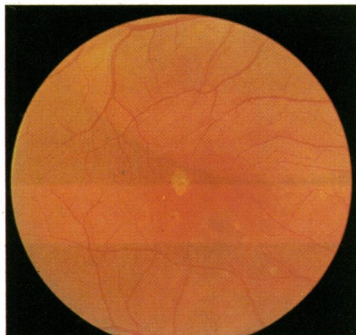


Fig. 5

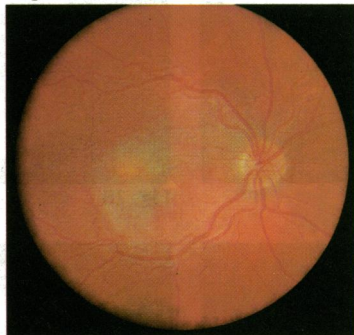

Fig. 6

Fig. 5 Fundus photograph demonstrates the 2 lesions noted in Fig. 4, with a new exudative lesion inferior and nasal to the macula.

Fig. 6 Fundus photograph shows the macular area with a prominence of the new focus of exudation inferior and nasal with subretinal organisation.

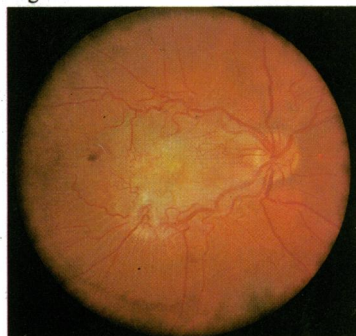


Fig. 7 Fundus photograph demonstrates inward displacement of the inferior and superior arcades, subretinal haemorrhages, gross detachment of the sensory retina, and subretinal fibrosis.

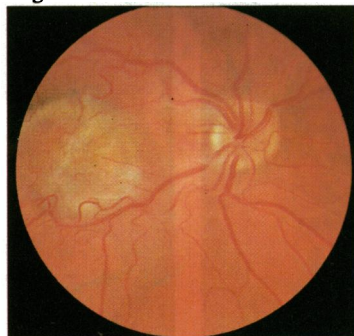


Fig. 8 Fundus photograph shows fully developed disciform lesion.

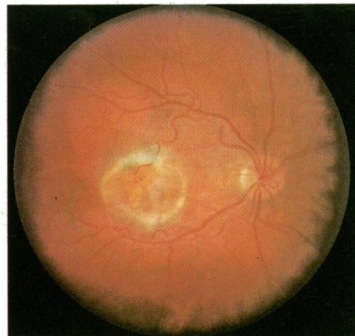


Fig. 10 Fundus photograph reveals end-stage disciform scar.

CASE 2

This was a 20-year-old male first seen in December 1978 by an ophthalmologist for evaluation of black spots and distorted vision in his right eye of 2 weeks' duration. He had had similar complaints 9 months earlier, which resolved spontaneously. His past medical, ophthalmological, social, and family

histories all were negative except for a respiratory tract infection several months earlier.

On examination in December 1978 his best corrected visual acuity was OD 20/30, OS 20/40. The right macula was abnormal, with an area of deep linear exudation in the superior foveal region, and adjacent to this were circumscribed areas of atrophic

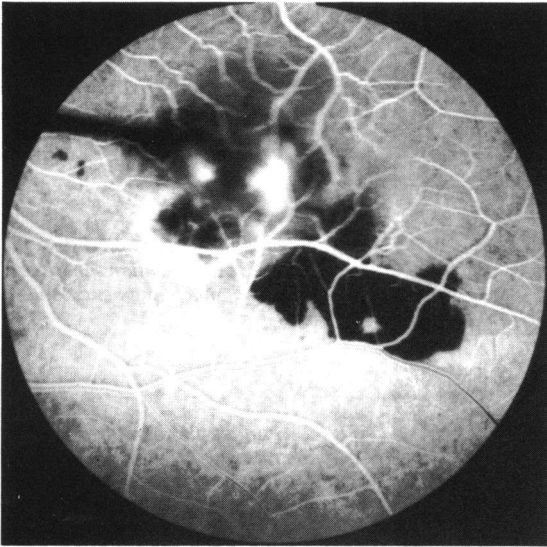


Fig. 2A

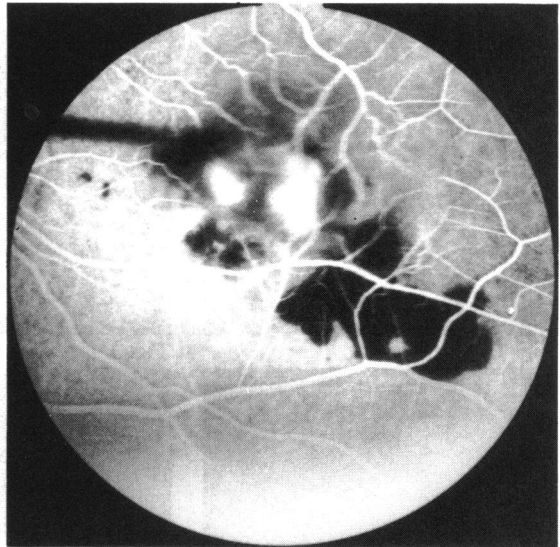


Fig. 2B

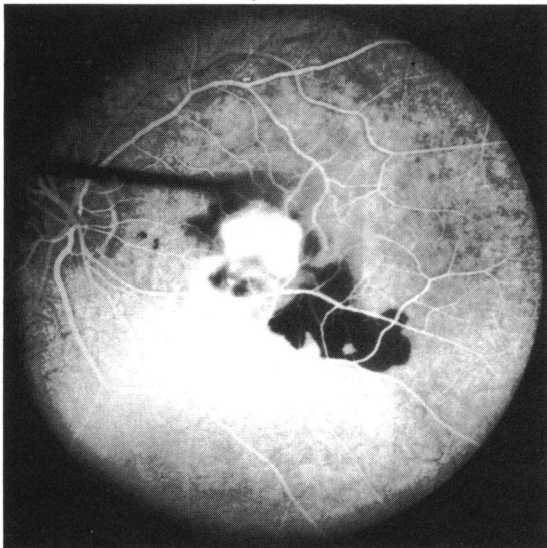


Fig. 2C

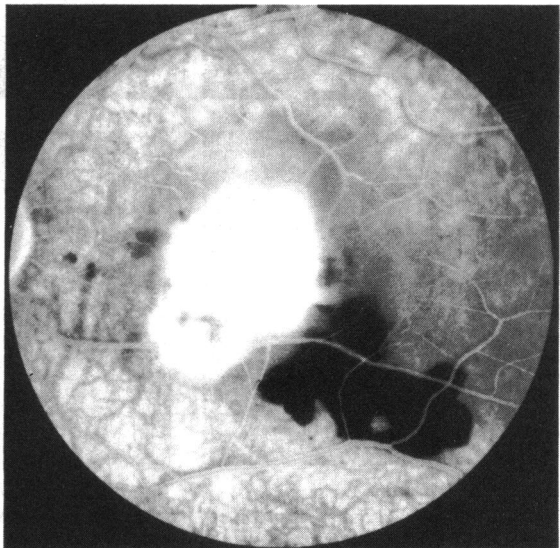


Fig. 2D

Figs. 2A,B,C,D Fluorescein angiogram case 1 in the early arteriovenous phase (A) reveals 2 foci of subretinal neovascularisation with progress in B and C to form a confluent area of leakage in D.

changes in the retinal pigment epithelium (RPE), with one area of exudation in the inferior papillo-macular bundle region. The overlying vitreous had several condensations, with no true cellular reaction (Fig. 3).

A fluorescein angiogram at that time revealed localised hyperfluorescence at the areas of RPE

changes, beginning at the arteriovenous phase, with little change with time. A diagnosis of retinal pigment epitheliitis was made, and the patient was started on prednisone 60 mg daily (Fig. 4).

The patient responded well to the corticosteroid therapy. At follow-up the visual acuity was 20/20 OD and he was asymptomatic. Within a month after

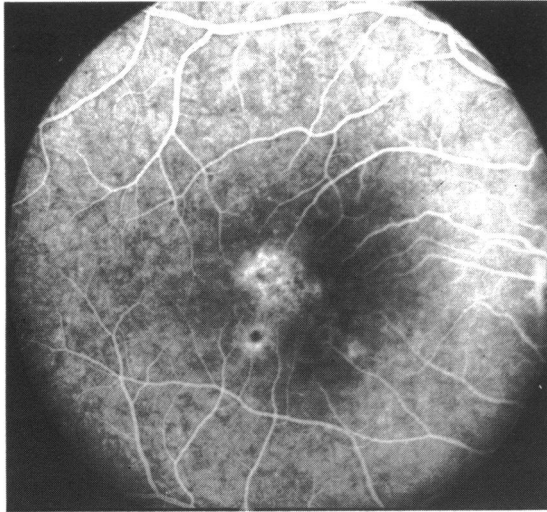


Fig. 4 *Fluorescein angiogram reveals localised hyperfluorescence at the level of the retinal pigment epithelium.*

cessation of steroid therapy he noted black spots subjectively in the right eye. They increased, and an ophthalmological examination revealed new, white, fluffy lesions in the right macula. A toxoplasmosis IFA titre at this time was 1:256.

In January 1979 the best corrected visual acuity was OD 20/40 and OS 20/20. Amsler grid testing displayed an abnormality in the right superonasal quadrant. The right anterior segment was unremarkable, while

the fundus examination showed a posterior vitreous detachment, and in the macula several old healed retinal lesions and several elevated exudative lesions with surrounding retinal oedema (Fig. 5). The patient was started on therapy with prednisone 80 mg, daraprim, sulphadiazine, and folic acid. The steroids and other medications were rapidly tapered as his acuity improved to 20/25+ OD in March 1979.

In September 1979, 6 months later, the patient returned because of recurrence of symptoms and severe visual loss in the right eye. The visual acuity OD was less than 20/200 and OS 20/20. Ophthalmoscopy revealed in the right macular area a new area of exudation with surrounding macular oedema (Fig. 6). A repeat IFA toxoplasmosis titre was 1:512. He was restarted on the previous therapy with the addition of clindamycin 1200 mg per day by mouth.

In November 1979 the macula showed a markedly distorted appearance. The superior and inferior vascular arcades were displaced toward the macula, a subretinal membrane was apparent, several subretinal haemorrhages were present temporally and inferiorly, and there was extensive serous subretinal fluid at the margins of the lesion (Fig. 7). A fluorescein angiogram performed shortly afterward showed subretinal neovascularisation with marked leakage of dye in later phases of the study (Figs. 8 and 9A and 9B).

Follow-up examination in March 1981 revealed a visual acuity of finger counting in the right eye and 20/15 in the left. The right fundus showed inward displacement of the macular arcades due to traction

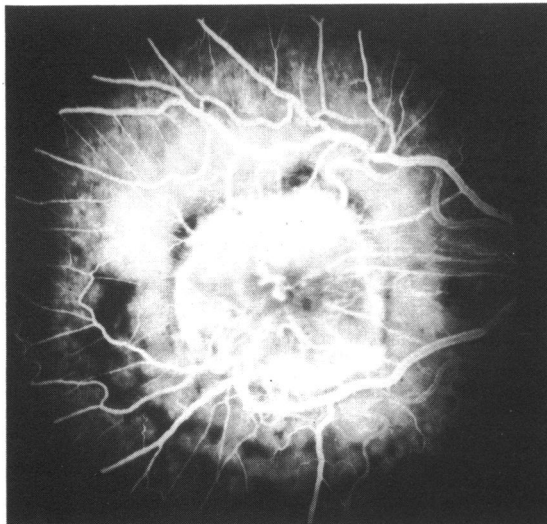


Fig. 9A

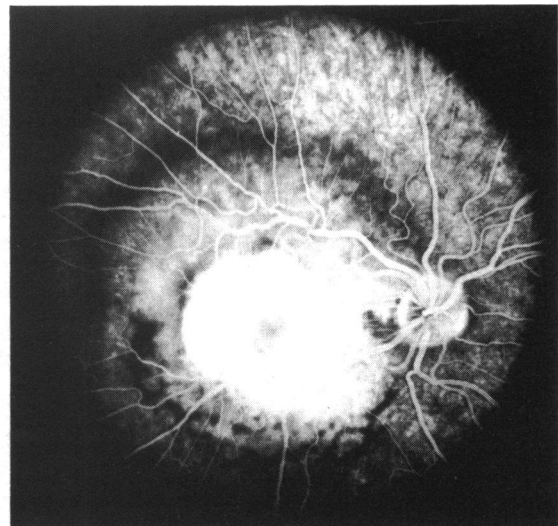


Fig. 9B

Fig. 9A,B *Fluorescein angiogram showing subretinal neovascularisation and extensive leakage.*

from the subretinal scar. There were focal areas of retinal pigment hyperplasia inferiorly (Fig. 10).

Discussion

Ocular toxoplasmosis is the local eye manifestation of a systemic infection which is due to a congenital infection that recurs later in life. The average age at the time of the first symptomatic attack is 25.3 years; the first symptoms appear between ages of 10 and 35 in 75% of the cases.³ A high percentage of initial episodes have been noted to occur at the time of puberty. Specific attacks have been reported to last anywhere from one week to 2 years, with an average of 4.2 months per attack and an average of recurrent episodes of 2.7 per patient.³

Different types of active retinitis have been described clinically in toxoplasmosis.³ The most commonly encountered lesion is the large destructive active retinitis with associated vitritis. A second type described is that of punctate inner areas of retinitis with minimal associated oedema and vitreous reaction. The third and most unusual form of toxoplasmosis has been characterised as deep retinal punctate lesions with subretinal exudate. The lesions in this group are associated with a minimal amount of vitreous reaction and with turbid subretinal fluid or blood. This group has been said to account for 0.3% of toxoplasmic lesions,¹ to be a type of disciform detachment of the retina in some ways similar to that of histoplasmosis, and always to be located in the macula or near the optic disc. Friedmann and Knox³ suggested that the subretinal fluid present was choroidal in origin and an inflammatory response secondary to retinal disease.

Histological examination of toxoplasmic lesions reveals a retinochoroiditis with an apparent predilection of the organisms for the retina and retinal pigment epithelium. The resultant coagulative necrosis of the retina is frequently associated with underlying choroidal and scleral inflammation. Toxoplasma organisms are usually found within necrotic retinal tissues and not in the choroid.⁵

Kennedy and Wise,⁶ in their case report of retinochoroidal vascular anastomosis in ocular toxoplasmosis, suggested that the formation of the anastomosis was the result of intense retinal inflammation with secondary destruction of Bruch's membrane and choriocapillaris.

The fluorescein angiographic signs of subretinal neovascularisation have been well documented and described in recent years.⁷ These criteria have enabled the ophthalmologist to identify subretinal neovascular membranes, often without the aid of fluorescein angiography. In both of our cases the ophthalmoscopic picture included deep retinal

Table 1 *Aetiology of subretinal neovascularization**

1.	Senile macular degeneration
2.	Presumed ocular histoplasmosis syndrome
3.	Angioid streaks
4.	Choroidal rupture
5.	Myopic maculopathy
6.	Heredodegenerative disease (e.g., Best's, dominant drusen)
7.	Optic nerve head drusen
8.	Over benign choroidal tumours
9.	Inflammation (e.g. toxoplasmosis)
10.	Postphotocoagulation
11.	Rubella retinopathy
12.	Retinal and pigment epithelial hamartoma
13.	Geographic helicoid peripapillary choroidopathy
14.	Choroidal osteoma
15.	Acute multifocal posterior placoid pigment epitheliopathy
16.	Vogt-Koyanagi-Harada syndrome
17.	Idiopathic

*Modified from Yannuzzi *et al.*⁷

haemorrhage and exudate in the macula. The fluorescein angiogram helped to confirm the clinical suspicion of subretinal neovascularisation by demonstrating the early hyperfluorescence which proceeded to detachment of the sensory retina in case 1 and subretinal scarring in case 2. In addition case 2 differs from case 1 and those described by Fine and co-workers⁴ in that the neovascular membrane may well have developed during an acute or subacute infectious stage.

Neither of these cases was amenable to argon laser therapy because of the central location of the subretinal neovascularisation. Conventional therapy was employed in both for treatment of the underlying condition.

In our experience we have generally found a predominance of posterior pole lesions, particularly macular, in patients with symptomatic early onset of ocular toxoplasmosis—i.e., in the second or third decade. Friedmann and Knox also found a 75% incidence of active central lesions (within 2 disc diameters of the macula) in their review of first symptomatic cases of toxoplasmosis.³

Subretinal neovascularisation has been generally associated with diseases of the elderly, most commonly with senile macular degeneration. Many other conditions, however, are associated with it (Table 1). It is our contention that severe macular toxoplasmosis in the young is also associated with subretinal neovascularisation and is not as uncommon as previously thought. We advise that young patients with a maculopathy possibly due to toxoplasmosis should be followed up very closely for the possible development of subretinal neovascularisation. Fluorescein angiograms should be a routine part of their examination and follow-up. Treatment, whether medical or laser, might be more effective if instituted

early, prior to the development of irreversible haemorrhage and scarring.

We are indebted to Drs Stuart L. Fine, Steven M. Podos, and Robert S. Coles for their critical reviews of the manuscript, Ms Elizabeth Wilkins for secretarial assistance, and Mr Robert Campanile and Mr Howard Radzyner for the photography.

This work was supported in part by an unrestricted grant from Research to Prevent Blindness Inc.

References

- 1 Schlaegel TF Jr. Toxoplasmosis. In: Duane TD, ed. *Clinical Ophthalmology*. Hagerstown: Harper and Row, 1979: 4: 1-16.
- 2 Cassady JV. Toxoplasmic retinochoroiditis. *Trans Am Ophthalmol Soc* 1960; **58**: 392-431.
- 3 Friedmann CT, Knox DL. Variations in recurrent active toxoplasmic retinochoroiditis. *Arch Ophthalmol* 1969; **81**: 481-93.
- 4 Fine SL, Owens SL, Haller JA, et al. Choroidal neovascularization as a late complication of ocular toxoplasmosis. *Am J Ophthalmol* 1981; **91**: 318-22.
- 5 Friedman AH, Luntz M, Henley W. *Diagnosis and Management of Uveitis*. Baltimore: Williams and Wilkins, in press.
- 6 Kennedy JE, Wise GN. Retinochoroidal vascular anastomosis in uveitis. *Am J Ophthalmol* 1971; **71**: 1221-5.
- 7 Yannuzzi L, Gitter K, Schatz H. *The Macula*. Baltimore: Williams and Wilkins, 1979: 180-201.