

Recurrence of keratoconus in donor cornea 22 years after successful keratoplasty

VERINDER S. NIRANKARI, JAMES KARESH, FRANK BASTION,*
VINOD LAKHANPAL, AND EMERY BILLINGS

*From the Departments of Ophthalmology and *Neuropathology, University of Maryland School of Medicine, Baltimore, Maryland, USA*

SUMMARY We report a second clinico-pathologic report of recurrent keratoconus in a 43-year-old white female with bilateral penetrating keratoplasties for keratoconus. She was found to have a recurrence of this condition in the right eye as manifested by increasing myopic oblique astigmatism, subepithelial and anterior stromal scarring and corneal thinning, 22 years following the initial grafting procedure. A second successful penetrating keratoplasty was performed. Light and electron microscopy demonstrated abnormalities in the basal epithelium, breaks in the basement membrane, duplication and thickening of Bowman's layer, and abnormal stromal keratocytes with accumulation of granular intra- and extracellular material. These findings are consistent with changes as seen in keratoconus.

Keratoconus is an axial corneal ectasia of obscure aetiology. It has been associated with many systemic and ocular diseases as well as with a variety of inheritance patterns.¹ Nonetheless, its underlying pathogenesis remains to be explained.

Penetrating keratoplasty has been highly successful in treating advanced cases.^{2–5} Recurrence of keratoconus following keratoplasty has been previously reported,^{6–8} but these reports were on the basis of clinical findings alone. A recent clinicopathological report has also indicated that keratoconus may recur years later in donor graft tissue following a successful corneal grafting procedure.⁹ We report a second such case, documented clinically and histopathologically, in a donor graft 22 years after successful penetrating keratoplasty for keratoconus.

Case report

A 43-year-old white female was referred to the Cornea Service at the University of Maryland. She had undergone bilateral penetrating keratoplasties for keratoconus—the right eye in 1958 and the left eye in 1968. Postoperatively she had done well, without evidence of any complications. The grafts

were clear and her vision was 20/20 OU with spectacle correction. She had remained stable for a period of 18 years.

During the last 4 years the vision in her right eye had deteriorated. She was noted by her ophthalmologist to have an increase in her myopic astigmatism, which was progressive over a follow-up period of 4 years.

On initial examination visual acuity was 20/400 in the right eye with a plano -6.50×55 and 20/30 in the left eye with $-4.25 -3.00 \times 55$. The right eye showed

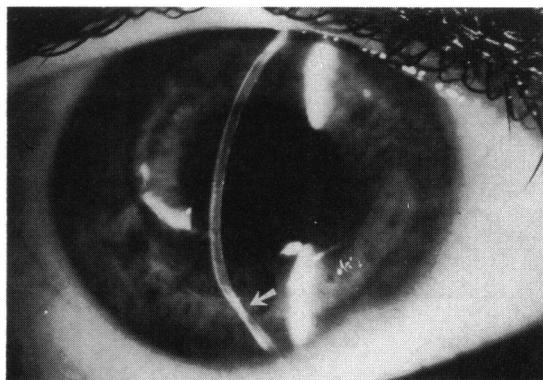
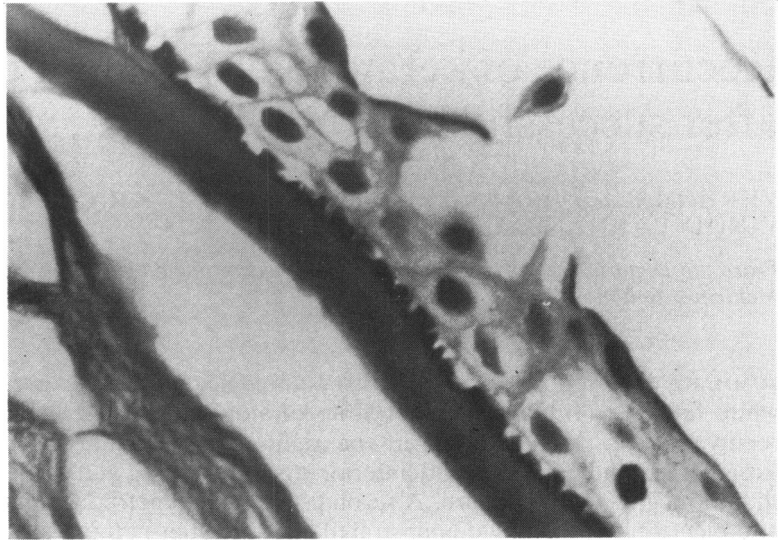

Fig. 1 Right eye, cornea showing thinning and protrusion of graft inferiorly.

Correspondence to V. S. Nirankari, MD, Cornea Service, University of Maryland, 22 South Greene Street, Baltimore, Maryland 21201, USA.

Fig. 2A Gaps in Bowman's layer filled with protrusions of overlying epithelial cells. (PAS, $\times 615$).

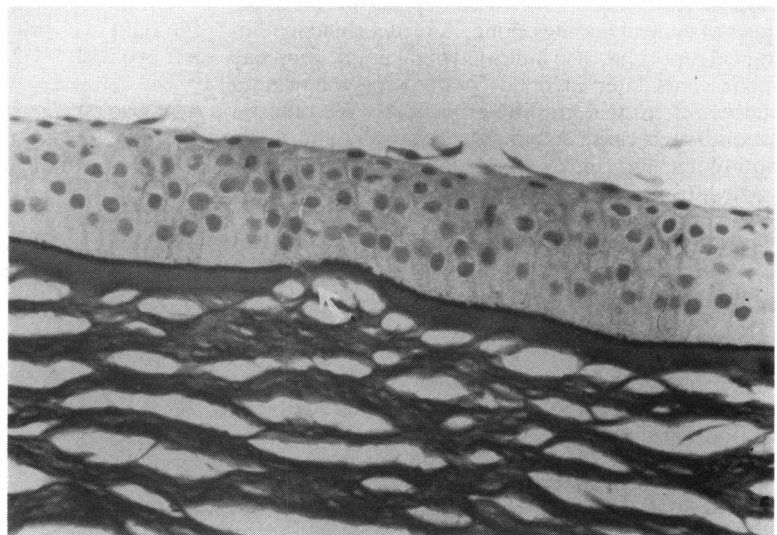


a slightly eccentric 8 mm corneal transplant. The cornea was relatively clear, with some subepithelial and anterior stromal opacities centrally. There was thinning and protrusion of the graft especially inferiorly (Fig. 1). The corneal transplant on the left eye was centrally located and clear. Keratometry on the right eye showed minified and distorted mires with an approximate reading of $42.25/57.25 \times 135$. On the left the readings were $46.62/52.00 \times 145$. The remainder of her ocular examination was normal. There was no history of atopy or eye rubbing. The patient had never worn contact lenses after her keratoplasties.

A full history of the donor tissue used for the graft in the right eye was obtained from the eye bank from which the tissue came, and details of her initial grafting procedure were obtained from the physician who performed the operation. The donor was a 51-year-old white female who had died suddenly following intestinal obstruction. She had no known history of any ocular disease.

An uncomplicated 8 mm penetrating keratoplasty with donor tissue stored in M-K medium was performed on the right eye. The excised button was examined by both light and electron microscopy. Postoperatively the patient has maintained a clear

Fig. 2B Break in basement membrane (BM) with thinning and dehiscence of Bowman's layer (BL). (PAS, $\times 125$).



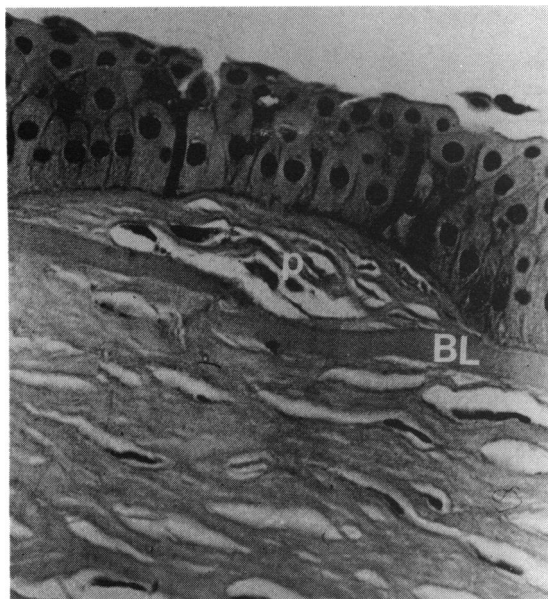


Fig. 3 Collagenous plaques containing keratocyte-like cells with large vesicular nuclei and basophilic cytoplasm; dehiscences in Bowman's layer (BL). (PAS, $\times 250$).

graft. At the present time her vision is 20/25 with a +0.75+4.50 \times 115 spectacle correction.

Results

The excised corneal button revealed significant pathological alteration by light microscopy. There was a reduction in epithelial cell layers over the central cornea. Focally, these layers were separated from Bowman's layer with bleb formation.

The basement membrane was dehisced in many areas. These gaps were filled by extensions of overlying basal epithelial cells (Figs. 2A, B). Plaques containing collagenous material as well as keratocyte-like cells with large vesicular nuclei and basophilic cytoplasm were between the basement membrane and Bowman's layer. In these areas Bowman's layer was often fragmented (Fig. 3). Examination of the remaining portions of the cornea was unremarkable.

Examination of the corneal tissue by electron microscopy also showed abnormal tissues. The basement membrane was markedly thickened and contained electron dense fibrillar material (Fig. 4). Bowman's layer was unremarkable. However, there

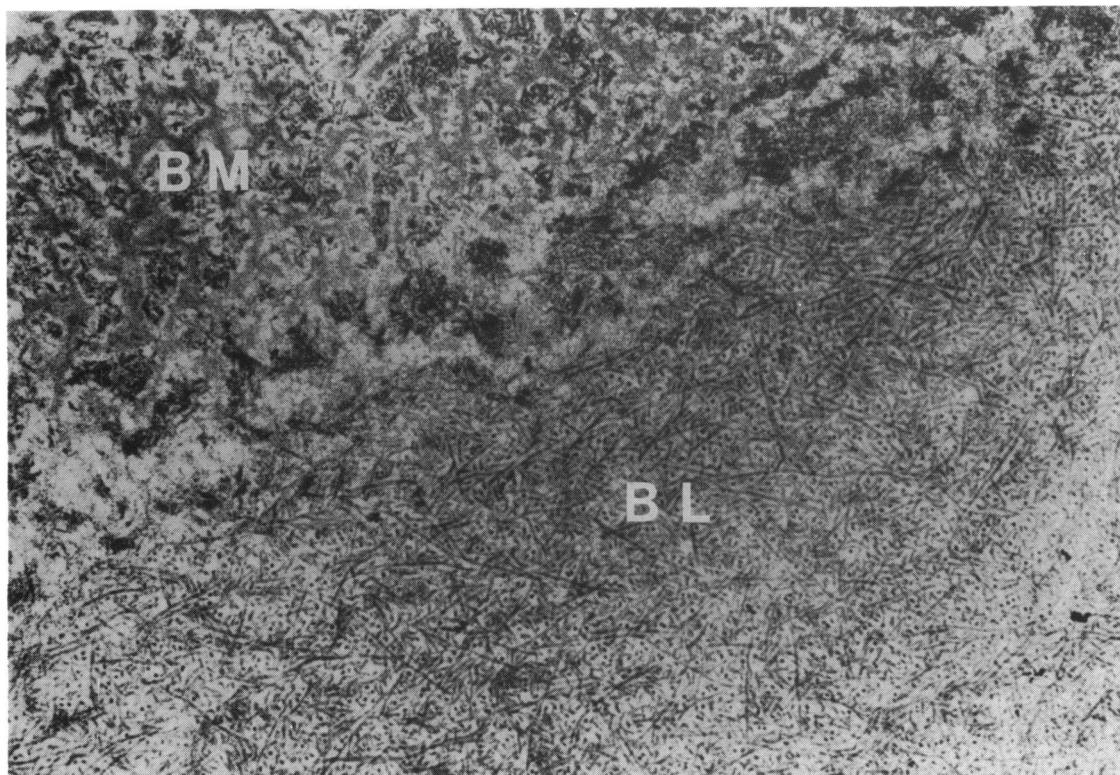
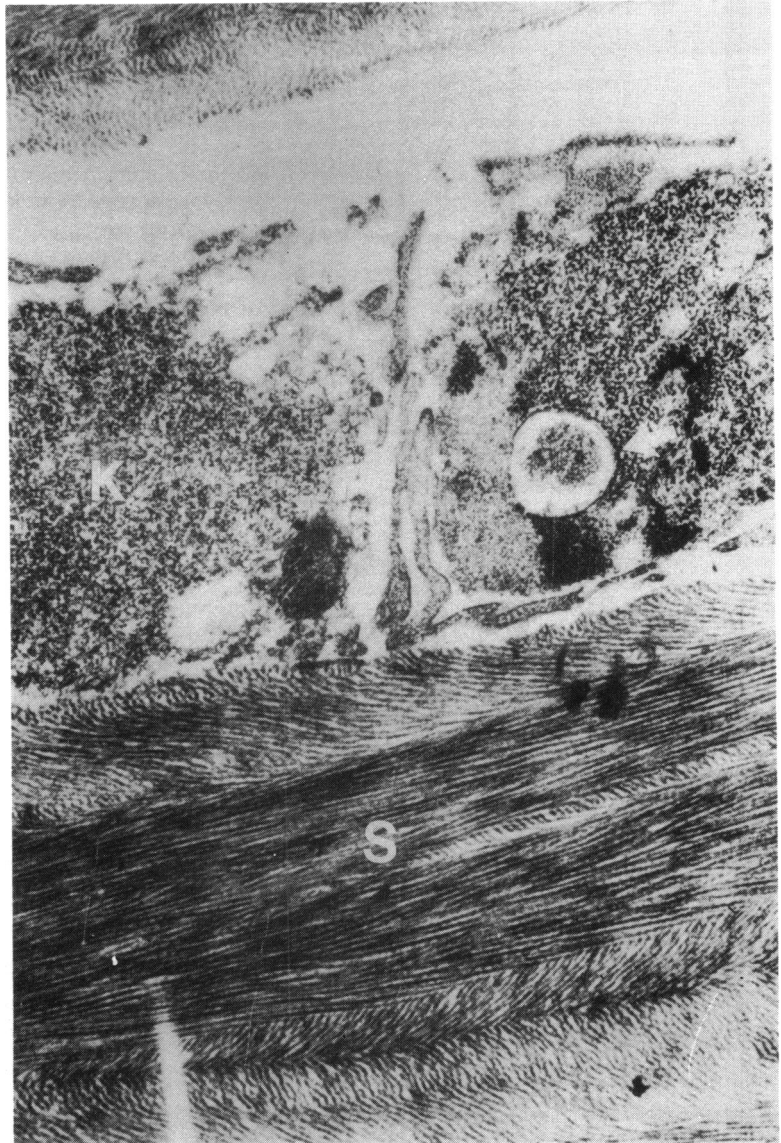


Fig. 4 Thickened basement membrane (BM) containing electron dense fibrillar material; Bowman's layer (BL) appears normal. (EM, $\times 10770$).

Fig. 5 *Stromal keratocyte with cytoplasmic vesicle containing amorphous granular material (arrow); increased rough endoplasmic reticulum within keratocyte. Stroma (S)* (EM, $\times 10\,667$).



was an increased amount of rough endoplasmic reticulum within the stromal keratocytes (Fig. 5). These cells also contained amorphous granular material within cytoplasmic vacuoles (Fig. 5). Similar material was also present extracellularly adjacent to the keratocytes (Fig. 6).

Discussion

Our patient is a 43-year-old white female who underwent successful keratoplasty for keratoconus. Eighteen years later she started showing corneal

changes on the right side characteristic of keratoconus, including increasing myopic and oblique corneal astigmatism, subepithelial and anterior stromal scarring, and corneal thinning.

The histopathological findings in our case resembled those found in other cases of keratoconus that have been studied extensively.¹⁰⁻¹² These findings have included breaks in the epithelial basement membrane, thickening of Bowman's layer, electron dense particles in Bowman's layer, abnormal keratocytes containing increased amounts of ribosomal material, and extra- and intracellular

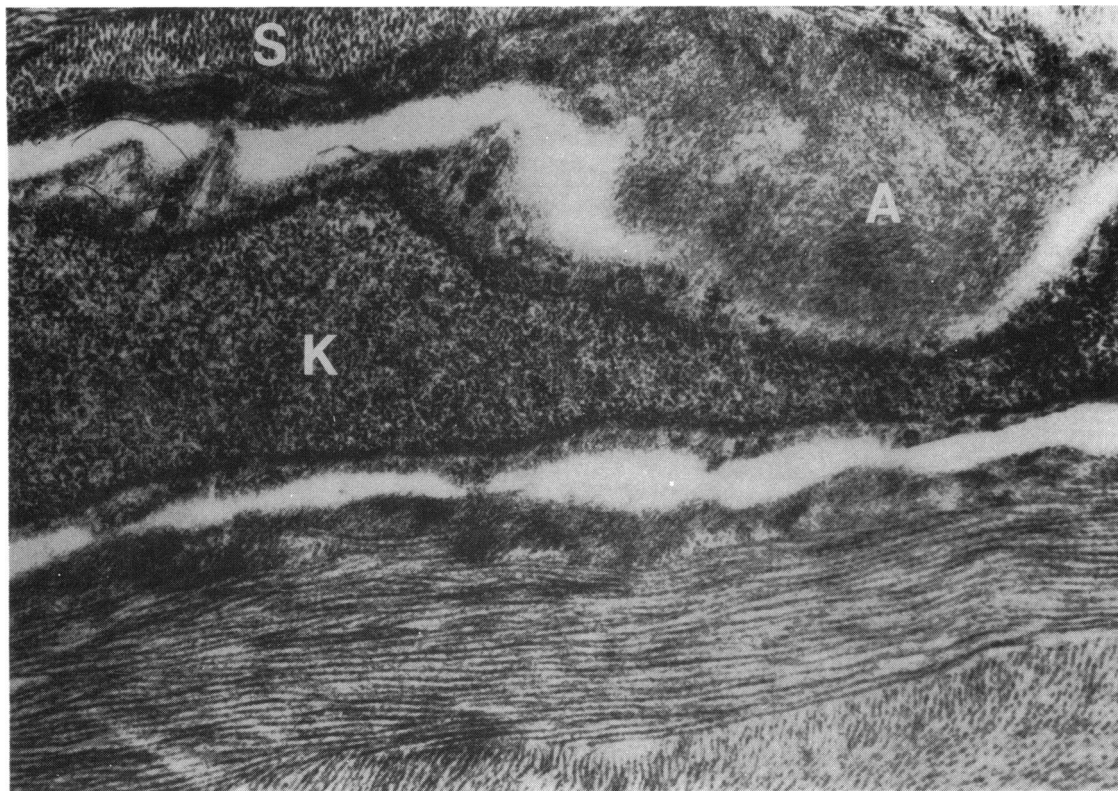


Fig. 6 Extracellular amorphous granular material within corneal stroma (S) and adjacent to keratocyte (K). (EM, $\times 10\,770$).

collections of amorphous granular material. Changes in the architecture of Bowman's layer, stromal thinning, and abnormalities in the structure of the collagen fibrils have also been noted.¹⁰⁻¹⁴

Prior to the present case only one histopathologically confirmed recurrence of keratoconus had been reported.⁹ The patient was a 35-year-old female who had had a penetrating keratoplasty 16 years prior to the redevelopment of the clinical changes of keratoconus. No information on the ocular health of the original donor was provided. The findings on light and electron microscopy resembled those in the present report. However, no plaque-like deposits between the basement membrane and Bowman's layer were noted. Moreover, unlike the present case, stromal thinning and degenerative changes in the collagen lamellae and fibres were described.

The underlying defect in keratoconus is obscure. In the present case the presence of keratoconus in the donor tissue was unlikely, since no evidence for this disease could be found in an investigation of the donor's ocular history. The patient also had no history of atopy,¹⁴ eye rubbing,¹⁴ or contact lens wear¹⁵ following the grafting procedure. It is possible, as

suggested by Abelson *et al.*,⁹ that either abnormal host keratocytes or epithelial cells infiltrated the donor tissue and caused the pathological changes of keratoconus. It is not unusual in lattice, macular, or granular dystrophy for abnormal host factors to affect donor tissue, resulting in a recurrence of the original pathology.¹⁶

Penetrating keratoplasty has been the treatment of choice for advanced stages of keratoconus. This procedure has been successful with a high percentage of clear grafts.²⁻⁵ It can be expected that as grafts survive for longer periods of time, and there is more long-term follow-up, more cases similar to the present one may be seen. Recurrence of keratoconus many years after penetrating keratoplasty represents a new late stage complication of this procedure and may eventually help to shed light on the aetiology of this disease process.

References

- 1 Gordon JM, Lemp MA, Leimbach RG, Wilson LA, Akashi R, Kersley JH. *Keratoconus: its etiology and management*. Amsterdam: Excerpta Medica, 1981.

- 2 Chandler JW, Kaufman HA. Graft reactions after keratoplasty for keratoconus. *Am J Ophthalmol* 1974; **77**: 543-7.
- 3 Moore TE, Jr, Aronson SB. The corneal graft: a multiple variable analysis of the penetrating keratoplasty. *Am J Ophthalmol* 1971; **72** (suppl): 205-98.
- 4 Keates RH, Falkenstein S. Keratoplasty in keratoconus. *Am J Ophthalmol* 1972; **74**: 442-4.
- 5 Hughes WF. The treatment of corneal dystrophies by keratoplasty. *Am J Ophthalmol* 1960; **50**: 1100-4.
- 6 Fanta H. Akuter Keratoconus. *Ber Dtsch Ophthalmol Ges* 1972; **71**: 46-51.
- 7 Jahne M. Keratokonusrezidiv nach Keratoplastik. *Z Aerztl Fortbild (Jena)* 1974; **68**: 434-6.
- 8 Matzen C. Das Endresultat von Keratoplastiken bei keratokonus nach Langzeitbeobachtung. In: Kruger KE, Tost M, eds. *Augenheilkunde in Forschung und Praxis*. Halle-Wittenberg: Martin Luther University, 1972; **2**: 118-9.
- 9 Abelson MB, Collin HB, Gillette TE, Dohlman CH. Recurrent keratocochus after keratoplasty. *Am J Ophthalmol* 1980; **90**: 672-7.
- 10 Teng CC. Electron microscope study of the pathology of keratoconus: Part 1. *Am J Ophthalmol* 1963; **55**: 18-47.
- 11 McTigue JW. The human cornea: a light and electron microscopic study of the normal cornea and its alterations in various dystrophies. *Trans Am Ophthalmol Soc* 1967; **65**: 591-660.
- 12 Polack FM. Contributions of electron microscopy to the study of corneal pathology. *Surv Ophthalmol* 1976; **20**: 375-414.
- 13 Cannon DJ, Foster CS. Collagen crosslinking in keratoconus. *Invest Ophthalmol Visual Sci* 1978; **17**: 63-5.
- 14 Karseras AG, Ruben M. Aetiology of keratoconus. *Br J Ophthalmol* 1976; **60**: 522-5.
- 15 Gasset AR, Honde WL, Garcia-Ben Cochea M. Hard contact lens wear as an environmental risk in keratoconus. *Am J Ophthalmol* 1978; **85**: 339-441.
- 16 Waring GO III, Rodrigues MM, Laibson PR. Corneal dystrophies. 1. Dystrophies of the epithelium, Bowman's layer, and stroma. *Surv Ophthalmol* 1978; **23**: 71-122.