

Adding Cases to the Study of Bucillamine-Associated Neural Epidermal Growth Factor-Like1-Positive Membranous Nephropathy



To the Editor: Miyazaki *et al.*¹ recently suggested in *Kidney International Reports* that neural epidermal growth factor-like1 (NELL1) is a causative antigen in bucillamine-associated membranous nephropathy (MN), and they described 4 Japanese patients with NELL1-positive MN complicated by rheumatoid arthritis (RA). Among 221 patients with MN who underwent NELL1 staining, 10 (4.5%) were positive for NELL1. Among them, 6 patients (60%) had NELL1-positive MN with RA, including 4 with suspected bucillamine-induced MN.

The rate of NELL1-positive MN with RA at our institutions is far lower, emphasizing the importance of the accumulation of more cases. Among 88 patients who underwent NELL1-staining at our institutions, 8 (9.1%) were diagnosed with NELL1-positive MN from 2013 to 2022, including 1 (12.5%) patient with MN associated with bucillamine-treated RA, 1 (12.5%) with immunoglobulin G4-related disease, and 6 (75%) with a nonspecific cause, suspected to be primary MN. Focusing on RA, 7 of our 88 patients (8.0%) were diagnosed with MN in a patient with RA, and 4 patients were treated with bucillamine. Only the bucillamine-treated patient (25%) mentioned above

was NELL1-positive. None of the non-bucillamine patients were NELL1-positive; however, 1 patient was positive for thrombospondin type-1 domain-containing 7A.

Our NELL1-positive MN patient with RA was a 64-year-old male who was diagnosed with RA 10 months before the renal biopsy and treated with bucillamine plus prednisolone. His laboratory tests showed urinary protein 5 months after bucillamine induction. His eGFR at the renal biopsy was 80 ml/min per 1.73 m², with 9.2 g/gCr urinary protein. Immunofluorescence microscopy revealed granular 1+ IgG, 2+ IgG1, 1+ IgG2, 1+ IgG3, 1+ IgG4, and 1+ NELL1, and negativity for IgA, IgM, C3, C1q, phospholipase A2 receptors, and thrombospondin type-1 domain-containing 7A. The NELL1 staining showed segmental distribution, which is consistent with electron-dense deposits (Figure 1). Even though the results obtained by both Miyazaki *et al.*¹ and us suggested that NELL1 can be a causative antigen in bucillamine-associated MN and shared the features of relatively short treatment duration and segmental distribution of deposits, further investigation with a greater number of cases is necessary to conclude the positive rate of NELL1 in MN with RA. Moreover, unknown antigens may still exist.

DISCLOSURE

All the authors have no competing interests.

ACKNOWLEDGMENT

We are deeply grateful to Ms. Mikie Daigo and Ms. Mami Kobayashi (University of Tsukuba, Tsukuba, Japan) for their technical support. This work was supported by grants from the Japan Society for the Promotion of Science KAKENHI (nos. JP22J20394, JP21H02822).

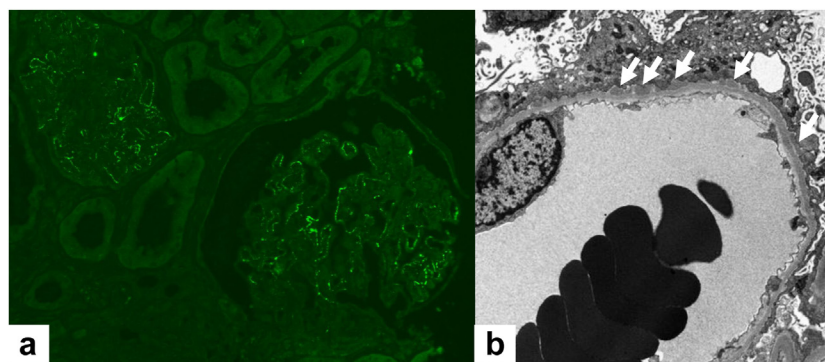


Figure 1. (a) NELL1 was positive in a patient with MN associated with bucillamine-treated RA. (b) Electron-dense microscopy showed segmental deposits, indicated by arrows.

- Miyazaki R, Ueda H, Hayashi A, et al. Neural epidermal growth factor-like 1-positive membranous nephropathy with rheumatoid arthritis. *Kidney Int Rep.* 2023;8:921–924. <https://doi.org/10.1016/j.ekir.2022.12.026>

Mayumi Takahashi-Kobayashi^{1,2}, Joichi Usui², Kunio Kawanishi³, Chie Saito², Itaru Ebihara⁴ and Kunihiro Yamagata²

¹Graduate School of Comprehensive Human Science, University of Tsukuba, Tsukuba, Ibaraki, Japan; ²Department of Nephrology, Institute of Medicine, University of Tsukuba, Tsukuba, Ibaraki, Japan; ³Department of Experimental Pathology, Institute of Medicine, University of Tsukuba, Tsukuba, Ibaraki, Japan; and ⁴Department of Nephrology, Mito Saiseikai General Hospital, Mito, Ibaraki, Japan

Correspondence: Joichi Usui, Department of Nephrology, Institute of Medicine, University of Tsukuba, 1-1-1 Tennodai, Tsukuba, Ibaraki 305-8575, Japan. E-mail: j-usui@md.tsukuba.ac.jp

Received 30 April 2023; accepted 1 May 2023; published online 8 June 2023

Kidney Int Rep (2023) **8**, 1698–1699; <https://doi.org/10.1016/j.ekir.2023.05.032>

© 2023 International Society of Nephrology. Published by Elsevier Inc. This is an open access article under the CC BY-NC-ND license (<http://creativecommons.org/licenses/by-nc-nd/4.0/>).

Response to Letter to the Editor entitled “Adding Cases to the Study of Bucillamine-Associated Neural Epidermal Growth Factor Like1-Positive Membranous Nephropathy”



The Author Replies: We thank Takahashi-Kobayashi *et al.* for reporting the additional Japanese case regarding bucillamine-associated neural epidermal growth factor-like 1 (NELL1)-positive membranous nephropathy (MN) in response to our report titled “Neural Epidermal Growth Factor-Like 1-Positive Membranous Nephropathy with Rheumatoid Arthritis.”¹ Of the 88 patients diagnosed with MN between 2013 and 2022, they found 8 (9.1%) with NELL1-positive MN, including 1 (12.5%) with a history of bucillamine-treated rheumatoid arthritis (RA). The frequency of cases with bucillamine-associated NELL1-positive MN was lower than that reported in our study (30%). It is worth noting that the 2 cohorts

differed in the time periods. Our cohort included patients with MN diagnosed between 2005 and 2018, and 3 patients with bucillamine-associated NELL1-positive MN were diagnosed in 2005, 2011, and 2013. Therefore, our patients with bucillamine-associated NELL1-positive MN were earlier cases. The difference in the time periods between the cohorts may have influenced the frequency of bucillamine-associated MN because the frequency of bucillamine use may have differed. Proteinuria is now a well-known side effect of bucillamine, which has led to closer monitoring and fewer cases that result in kidney biopsy. Around the same time as our report, Tsuji *et al.*² reported Japanese cases of bucillamine-associated NELL1-positive MN. In this cohort of patients diagnosed with RA-complicated MN between 2004 and 2020, 27 of 34 (79%) patients with RA-complicated MN had NELL1-positive MN, and 19 cases (56%) had a history of bucillamine treatment.² Collectively, these studies suggest a relatively high prevalence of bucillamine-associated MN among Japanese patients with NELL1-positive MN even though the prevalence may vary during different time periods. Importantly, the cohorts included patients with NELL1-positive MN complicated by RA without bucillamine treatment. Therefore, factors other than bucillamine use may contribute to the development of NELL1-positive MN, such as the genetic background or osteogenic properties of NELL1 in the joint involvement of patients with RA. A larger collection of cases and genetic background studies are warranted in the future.

- Miyazaki R, Ueda H, Hayashi A, et al. Neural epidermal growth factor-like 1-positive membranous nephropathy with rheumatoid arthritis. *Kidney Int Rep.* 2023;8:921–924. <https://doi.org/10.1016/j.ekir.2022.12.026>
- Tsuji T, Iwasaki S, Makita K, et al. Bucillamine use for rheumatoid arthritis and type 2 diabetes mellitus are associated with neural epidermal growth factor-like 1 (NELL1)-associated membranous nephropathy. Preprint. Published online December 5, 2022. <https://doi.org/10.1101/2022.12.02.22282616>

Hiroyuki Ueda¹

¹Division of Nephrology and Hypertension, The Jikei University School of Medicine, Nishi-shinbashi, Minato-ku, Tokyo, Japan

Correspondence: Hiroyuki Ueda, Division of Nephrology and Hypertension, The Jikei University School of Medicine, 3-19-18, Nishi-shinbashi, Minato-ku, Tokyo, 105-8471, Japan. E-mail: hi-ro@jikei.ac.jp

Received 1 June 2023; accepted 5 June 2023; published online 10 June 2023

Kidney Int Rep (2023) **8**, 1699; <https://doi.org/10.1016/j.ekir.2023.06.002>

© 2023 International Society of Nephrology. Published by Elsevier Inc. This is an open access article under the CC BY-NC-ND license (<http://creativecommons.org/licenses/by-nc-nd/4.0/>).