

Available online at [www.sciencedirect.com](http://www.sciencedirect.com)

ScienceDirect

journal homepage: [www.elsevier.com/locate/radcr](http://www.elsevier.com/locate/radcr)

## Case Report

# Diagnosing the culprit behind a subtle case of concomitant right atrial myxoma and atrial fibrillation: A case report <sup>☆</sup>

Muhammad Ahmad Qureshi, MD, Rana Uzair Ahmad, MBBS\*,  
Muhammad Fawad Ashraf, MBBS, Safi ur Rehman Daim, MBBS,  
Haseeb Khan Tareen, MD, Hamza Abdul Fattah, MD

Mayo Hospital, Anarkali, Lahore, Punjab, 54000, Pakistan

## ARTICLE INFO

## Article history:

Received 9 June 2023

Revised 7 July 2023

Accepted 8 July 2023

## Keywords:

Right atrial myxoma

Atrial fibrillation

Case report

Cardiac myxoma

## ABSTRACT

Myxomas are rare tumors arising from the uncontrolled proliferation of mesenchymal cells. Among cardiac conditions, cardiac myxomas account for less than 0.1% of cases, with the majority found in the left atrium and only 8% in the right atrium. Atrial myxomas present with various clinical manifestations, including constitutional symptoms, symptoms caused by blood flow obstruction, and tumor embolism. This case report describes a 50-year-old male patient presenting with syncope, fatigue, and dyspnea, who had a history of well-controlled hypertension and atrial fibrillation. Physical examination, further diagnostic workup, and echocardiography led to a provisional diagnosis of right atrial myxoma. The patient underwent a median sternotomy, and the tumor was surgically excised, resulting in both diagnostic and curative outcomes. Histological analysis confirmed the diagnosis of myxoma. This case report contributes valuable insights into the presentation, diagnostic challenges, and treatment of atrial myxoma.

© 2023 The Authors. Published by Elsevier Inc. on behalf of University of Washington.

This is an open access article under the CC BY-NC-ND license

(<http://creativecommons.org/licenses/by-nc-nd/4.0/>)

## Introduction

Cardiac tumors are rare, accounting for less than 0.1% of all cardiac conditions [1,2]. Among these, myxomas are the most common primary cardiac tumors, typically originating in the left atrium (75%). Only about 7.89% are found in the right atrium [3,4]. Myxomas can occur within a wide age range

(15–80 years), and the mean of approximately 50 years. Sporadic myxomas are more commonly found in females [5]. The familial forms of cardiac myxomas typically affect young males, are multiple in nature, and have a high risk of recurrence after surgical excision [6]. Right atrial myxomas present a unique clinical challenge due to their uncommon location and diagnostic considerations.

<sup>☆</sup> Competing Interests: The authors declare that they have no known competing financial interests or personal relationships that could have appeared to influence the work reported in this paper.

\* Corresponding author.

E-mail address: [ranauzair503@gmail.com](mailto:ranauzair503@gmail.com) (R.U. Ahmad).

<https://doi.org/10.1016/j.radcr.2023.07.021>

1930-0433/© 2023 The Authors. Published by Elsevier Inc. on behalf of University of Washington. This is an open access article under the CC BY-NC-ND license (<http://creativecommons.org/licenses/by-nc-nd/4.0/>)

These tumors arise from the connective tissue in the heart and can grow to obstruct blood flow, leading to a range of symptoms such as shortness of breath, fatigue, and heart palpitations [7]. This case report highlights the clinical manifestation, diagnostic challenges, and successful management of a right atrial myxoma in a patient with concurrent hypertension and persistent atrial fibrillation. Through this report, we aim to increase awareness and understanding of this condition among healthcare professionals. Early diagnosis and treatment are crucial in preventing complications and improving patient outcomes. We hope that this case report will serve as a valuable resource for clinicians in recognizing and managing the right atrial myxoma.

## Case presentation

A 50-year-old male patient with a known medical history of well-controlled hypertension and persistent atrial fibrillation sought medical attention at the neurology department's outpatient service. He reported an episode of syncope and mild headache that occurred the day before while standing on a 2-foot-high staircase. Before his fall, he experienced a sense of lightheadedness. The patient also reported increasing dyspnea during physical activity, which he had first noticed 6 months prior and had recently worsened. He further disclosed occasional palpitations and chest discomfort. Physical examination revealed generalized fatigue, an irregular heartbeat with a rate of approximately 110 beats per minute, mild fever with a temperature of 100°F, a normal respiratory rate of 17 breaths per minute, and low-normal oxygen saturation at 93%. Upper and lower extremity muscle strength was intact. Upon auscultation, irregular heart sounds were noted along with an indistinct additional sound. The electrocardiogram showed an irregularly irregular heartbeat, and a head computed tomography scan was normal. The patient was subsequently referred to the cardiology department for further evaluation.

During auscultation, a diastolic “plop” was suspected at the left sternal border, but the irregular heartbeat made diagnosis difficult. Laboratory investigations revealed elevated C-reactive protein levels of 5.5 mg/dL and normal levels of BMP, ESR, and immunoglobulins. There were no visible skin le-

sions. A transthoracic two-dimensional echocardiogram was performed, which revealed a large, well-defined, partially mobile, lobular mass measuring 4.93 × 3.20 × 5.82 cm, located within the right atrium. The mass was connected via a small stalk to the right atrial aspect of the interatrial septum, leading to a diagnosis of myxoma. During diastole, the mass obstructed blood flow through the tricuspid valve and protruded slightly into the right ventricle. The biventricular function was normal, and the right atrium was mildly dilated. The echocardiogram aided in ruling out the presence of a thrombus that could impede atrioventricular flow, particularly given the patient's history of atrial fibrillation. The results of echocardiogram are given in Figure 1A and B.

The patient's hypertension was well controlled, and rate control therapy was initiated for atrial fibrillation. The patient was referred to cardiac surgery for myxoma removal. Following median sternotomy, a complete resection of the myxoma and its stalk was carried out, with a small portion of the interatrial septum removed and subsequently sutured and closed with a prolene suture. Gross examination of the specimen revealed a multilobar hemorrhagic dark red mass with a glistening shiny surface and a small stalk attached to it. Microscopic examination of standard H & E stains revealed polygonal cells scattered within a sea of myxoid stroma thus confirming the diagnosis. Upon follow-up, the patient reported improvement in dyspnea, fatigue, and fever. The surgical wound underwent complete healing. Subsequent visits revealed no complaints, and the patient did not experience any recurrent syncope within 2 years following surgery.

## Discussion

Cardiac tumors are one of the rarest of all the tumors found in the human body. They are divided into primary and secondary (metastatic) types. Primary cardiac tumors are about 40 times less common than metastatic tumors [8]. Among the primary cardiac tumors, myxomas are the most common, accounting for approximately 50% of all benign cardiac tumors. They are most commonly found in the left atrium, with only a small percentage of cases occurring in the right atrium [1,6]. Myxomas can present with a wide range of symptoms, includ-

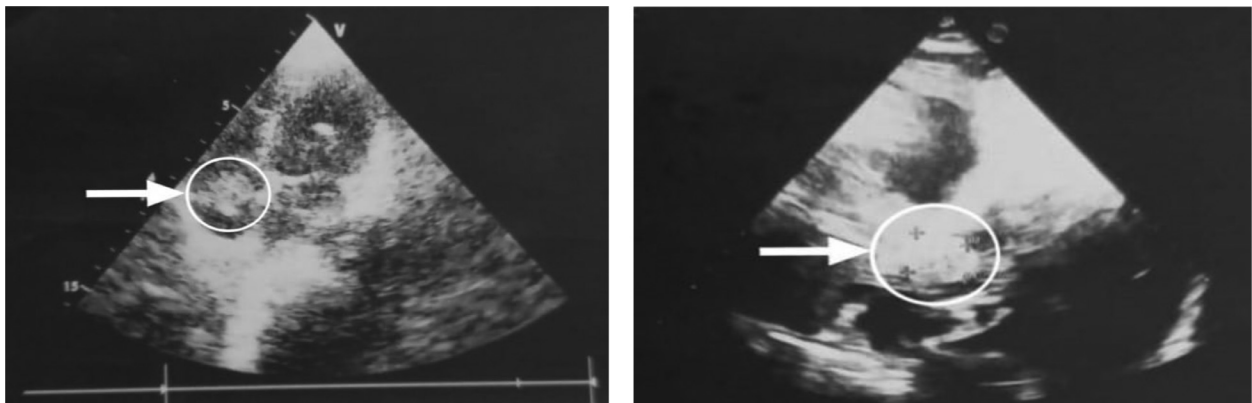


Fig. 1 – (A and B) Echocardiogram showing right atrial myxoma connected via a stalk to the interatrial septum.

ing constitutional symptoms such as fever and weight loss, as well as cardiac symptoms such as dyspnea and palpitations. Their classic presentation is usually in the form of a triad, described as obstruction of blood flow, constitutional symptoms, and thromboembolic events [9].

The diagnosis, in this case, was peculiar since the patient also exhibited atrial fibrillation in addition to the typical symptoms of syncope, headache, dyspnea, palpitations, and chest tightness. It is noteworthy that the symptoms of atrial fibrillation might mimic those of a myxoma, resulting in a diagnostic dilemma. For instance, on usual ultrasound imaging, the clot development associated with atrial fibrillation resembles a myxoma; also both myxomas and clots can present as intracardiac masses, raising the possibility of misunderstanding. Furthermore, in this case, the erratic pulse concealed the distinctive plop sound of the myxoma, which may have led to a misunderstanding of the circumstances. Considering all the possible differentials, the diagnosis was ultimately established using transthoracic 2-dimensional echocardiography, which revealed a significant mass within the right atrium. Additionally, the connection of the myxoma with the interatrial septum helped differentiate it from atrial fibrillation-induced clot formation.

Right atrial myxomas can obstruct blood flow through the tricuspid valve leading to dyspnea and fatigue; they can also embolize other parts of the body, including the lungs and brain. Pulmonary embolism can cause symptoms such as chest pain and shortness of breath [10], while cerebral embolism can cause stroke-like symptoms such as weakness or paralysis on one side of the body [11]. Additionally, if a myxoma is attached to the interatrial septum, it can cause damage to this structure and potentially lead to complications such as an atrial septal defect [12]. The myxoma in this present case also was attached to the inter-atrial septum but it was diagnosed at early stages and surgical removal proved to be beneficial as it saved the patient from possible complications of damage of the interatrial septum.

Macroscopically, most myxomas are polypoidal with smooth lobulated contours. The surface of myxomas may have smooth or lobulated macroscopic features. Oval, rounded, and irregular shapes have been described, and a brownish color appears to be predominant. The consistency of myxomas is also variable, from firm to gelatinous [13]. In this particular case report, a gross examination of the resected specimen revealed a multilobar hemorrhagic dark red mass with microscopic features of polygonal cells scattered within a sea of myxoid stroma. The diagnosis of myxoma can be challenging due to its nonspecific symptoms and the rarity of the condition. In this case, the diagnosis was made via a transthoracic 2-dimensional echocardiogram, which revealed a large mass within the right atrium. The echocardiogram is considered the gold standard for the diagnosis of myxoma. Surgical resection is the treatment of choice for myxomas [14].

In this case, the patient underwent successful resection of the myxoma and its stalk via median sternotomy. The patient reported improvement in symptoms following surgery and did not experience any recurrent syncope within 2 years following surgery. This case emphasizes the importance of a multidisciplinary approach, including clinical assessment, imaging modalities, and thorough evaluation of the tumor's character-

istics, to accurately diagnose myxomas, especially in the presence of atrial fibrillation. Further research and reported cases are warranted to enhance understanding of this unique clinical scenario and facilitate early and accurate diagnosis so that surgical intervention can lead to successful outcomes and prevent complications associated with right atrial myxoma.

---

## Conclusion

Our case portrays a 50-year-old male who presented with symptoms of syncope, fatigue, and dyspnea. He had well-controlled hypertension and persistent atrial fibrillation which presented a diagnostic challenge. Further workup and echocardiography suggested a diagnosis of right-sided atrial myxoma. He was treated with median sternotomy and surgical removal of the myxoma, which was diagnostic and curative. Histological analysis confirmed the diagnosis. Atrial myxomas are a rare cardiac condition and right-sided atrial myxomas account for less than 8% of all cardiac myxomas. Our report provides valuable information about the presentation, diagnostic difficulties, and treatment of right atrial myxomas.

---

## Patient consent

Written informed consent was obtained from the patient for the publication of this case report and accompanying images. A copy of the written consent is available for review by the Editor-in-Chief of this journal on request.

---

## REFERENCES

- [1] Reynen K. Cardiac myxomas. *N Engl J Med* 1995;333(24):1610–17.
- [2] Livi U, Bortolotti U, Milano A, Valente M, Prandi A, Frugoni C, et al. Cardiac myxomas: results of 14 years' experience. *Thorac Cardiovasc Surg* 1984;32(03):143–7.
- [3] Diaz A, Di Salvo C, Lawrence D, Hayward M. Left atrial and right ventricular myxoma: an uncommon presentation of a rare tumor. *Interactive Cardiovasc Thorac Surg* 2011;12(4):622–5.
- [4] Li H, Guo H, Xiong H, Xu J, Wang W, Hu S. Clinical features and surgical results of right atrial myxoma. *J Cardiac Surg* 2016;31(1):15–17.
- [5] Oliveira R, Branco L, Galrinho A, Abreu A, Abreu J, Fiarresga A, et al. Cardiac myxoma: a 13-year experience in echocardiographic diagnosis. *Rev Port Cardiol* 2010;29(7-8):1087–100.
- [6] Hermans K, Jaarsma W, Plokker HW, Cramer MJ, Morshuis WJ. Four cardiac myxomas diagnosed three times in one patient. *Eur J Echocardiogr* 2003;4(4):336–8.
- [7] Thyagarajan B, Kumar MP, Patel S, Agrawal A. Extracardiac manifestations of atrial myxomas. *J Saudi Heart Assoc* 2017;29(1):37–43.
- [8] Arruda MV, Braile DM, Joaquim MR, Soares MJ, Alves RH. Resection of left ventricular myxoma after embolic stroke. *Braz J Cardiovasc Surg* 2008;23:578–80.

- 
- [9] Swartz MF, Lutz CJ, Chandan VS, Landas S, Fink GW. Atrial myxomas: pathologic types, tumor location, and presenting symptoms. *J Card Surg* 2006;21(4):435–40.
- [10] Ma G, Wang D, He Y, Zhang R, Zhou Y, Ying K. Pulmonary embolism as the initial manifestation of right atrial myxoma: a case report and review of the literature. *Medicine* 2019;98(51):e18386.
- [11] Sabageh D, Odujoko OO, Komolafe AO. Right atrial myxoma as a possible cause of hemorrhagic stroke and sudden death. *Niger Med J* 2012;53(2):102.
- [12] Wang H, Li Q, Xue M, Zhao P, Cui J. Cardiac myxoma: a rare case series of 3 patients and a literature review. *J Ultrasound Med* 2017;36(11):2361–6.
- [13] Nina VJ, Silva NA, Gaspar SF, Rapôso TL, Ferreira EC, Nina RV, et al. Atypical size and location of a right atrial myxoma: a case report. *J Med Case Rep* 2012;6:1–5.
- [14] Nabil Chakfé MD, Kretz JG, Valentin P, Bernard Geny MD, Petit H, Popescu S, et al. Clinical presentation and treatment options for mitral valve myxoma. *Ann Thorac Surg* 1997;64(3):872–7.