

Control of astigmatism after surgery and trauma: a new technique

M J ROPER-HALL AND A D ATKINS

From the Birmingham and Midland Eye Hospital, Birmingham

SUMMARY Five patients were subjected to a new technique designed to correct high astigmatism not responding to suture removal or adjustment. The method is described and its use illustrated in five case histories. Four of the five cases were successfully treated. The reasons for the one failure are discussed. All procedures were uncomplicated. The technique is simple, safe, and reversible.

Despite safe surgical technique and generally accurate microsurgical wound closure some patients are found to have unacceptably high astigmatic errors. Some of these errors are amenable to the selective removal of overtight sutures, the adjustment of a continuous suture, or both.¹

However, in a number of cases of astigmatism these methods cannot be applied. There are several possible reasons: (1) All the sutures have already been removed. (2) The wrong sutures have been removed, making the astigmatism worse. (3) The initial injury caused so much scarring and traction that suture removal has no effect. (4) The sutures are buried, as in a standard corneoscleral section, under a limbal-based conjunctival flap. (5) Adjustment of a continuous suture has failed.

In these unfortunate patients further surgery may be required. Fyodorov² reintroduced methods of keratotomy and has described its use in the correction of astigmatism as well as refractive errors. Final results have not been predictable, with high errors, and there may be complications.³ Any surgical procedure involving cutting the cornea or removing a wedge³ is irrevocable, and if the outcome is unsatisfactory it is not reversible.

Material and methods

CASE SELECTION

Our five cases consist of: (1) One case of astigmatism following keratoplasty (case 1). (2) Three cases of astigmatism following routine cataract extraction with four-loop Binkhorst intraocular lens insertion (cases 2, 3, and 4). All three were subjected to adjustment of their continuous sutures,¹ but the

Correspondence to Mr M J Roper-Hall, FRCS, Birmingham and Midland Eye Hospital, Church Street, Birmingham B3 2NS.

procedure failed to correct their astigmatism. Two of these cases were part of a group of 36 such adjustment cases; the remainder were managed successfully without resorting to resuture. The results of these 36 cases are reported separately.⁴ (3) One case of penetrating trauma to corneosclera and lens. This case stands out as a separate problem and is presented last.

METHODS

After appropriate anaesthesia (our patients were treated under general anaesthesia) a superior rectus bridle suture is placed to control the position of the eye. Interrupted 9/0 nylon sutures are placed at 2/3rds depth in the clear peripheral cornea at and around the axis of the negative cylinder. The lengths of bite were 2–3 mm. For example: refraction +2.00 D.sp/–7.00 D.cyl axis 60° (Fig. 1).

Tight 9/0 nylon sutures will be placed as shown. They are placed in two rows on both ends of the 60° meridian. The first tie of the suture has three throws and is pulled tight enough to show stress in the cornea. This steepens the cornea sufficiently to convert the minus to a plus axis in the same meridian. An assistant holds the tie while the knot is completed with single throws to make it secure. The excess is cut off short with a sharp blade and the suture rotated to bury the knot in the suture track. Several knots are inserted, with the aim of overcorrecting the astigmatism at the time of surgery. This could well result in a 10–15 dioptre change in astigmatism and cause the eye in this example to have an early postoperative cylinder of 5 dioptres with a plus axis at the same 60° meridian—that is, a change of 12 dioptres. This allows for the reduction in the cylinder, as the effect degrades during a four to six weeks postoperative course. If necessary further adjustment is made after

CORNEAL SUTURING TECHNIQUE - EXAMPLE

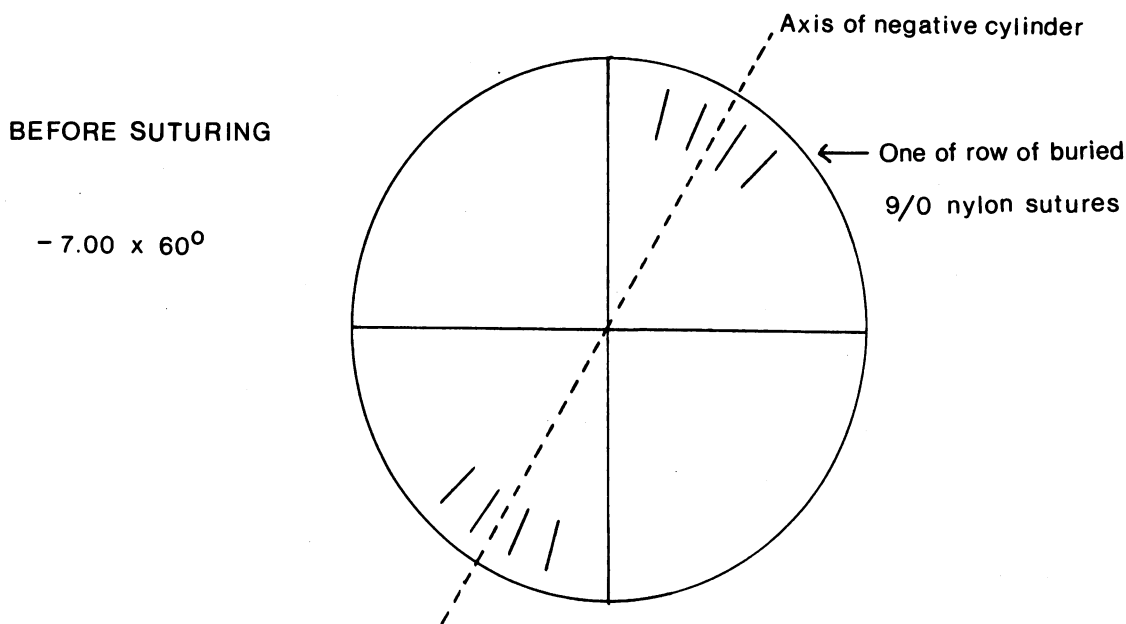


Fig. 1 Example of corneal suturing technique. A cylinder of $-7.00 \times 60^\circ$ would be treated by placing 9/0 nylon sutures tightly in clear cornea around the 60° axis (i.e., the axis of the negative cylinder) to steepen this meridian. The knots must be buried.

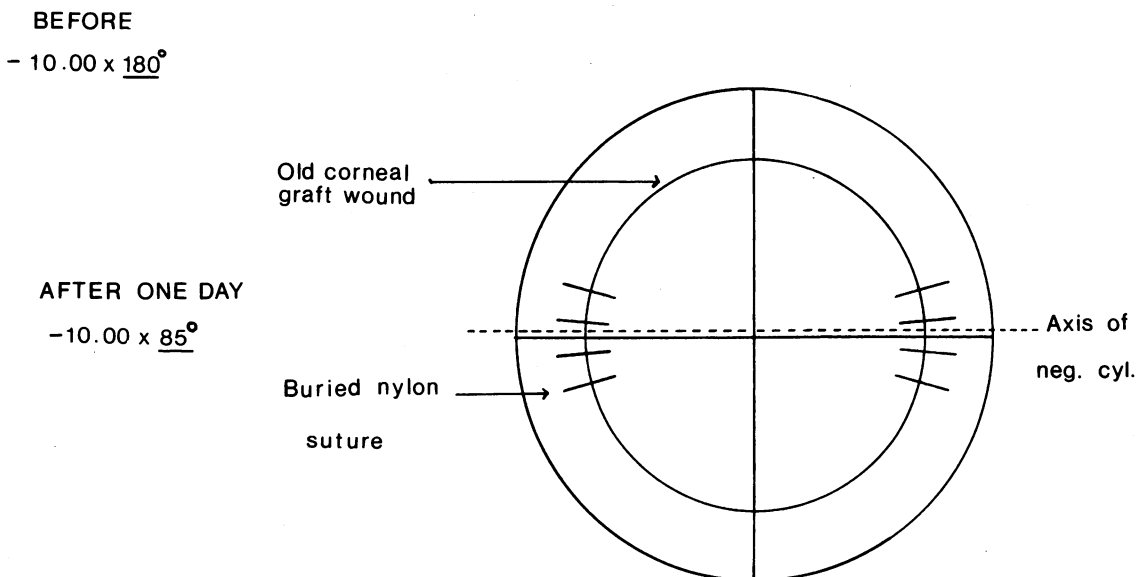


Fig. 2 Case 1. A female aged 28 years, underwent penetrating keratoplasty in June 1981 for corneal scarring following herpes zoster ophthalmicus. In February 1982 indiscriminate removal of all sutures in an attempt to correct 5.00 dioptres astigmatism actually produced a 10.00 dioptre cylinder axis 180° . Interrupted sutures as shown shifted the axis to 85° —a change in astigmatic power of 20.00 dioptres.

not less than four weeks by removing some of the newly placed individual sutures, which are now in the axis of the *positive* cylinder, and checking the refractive error between each removal until a satisfactory refraction is obtained. Experience has shown that it is often wise to make this adjustment over a period of a few weeks, only a single suture being removed at any one time. The optimum time for this adjustment seems to be between four and eight weeks after the tensioning sutures have been placed. The remaining sutures are left in situ.

We must stress that the tensioning sutures are placed in the negative axis, with the aim of overcorrection, and delayed single suture removal is in the same axis, which is then positive.

We have found 9/0 nylon to be most reliable; with finer gauge, tension may not be sufficient before the suture breaks. It is wise to warn the patient that surgery is aiming at an overcorrection. The refraction should be observed during the early postoperative course and removal of sutures firmly resisted until this observation has been sufficient for early moulding to have become stable. This period serves a similar purpose to that described previously.¹

Case reports

CASE 1 (Figs. 2, 3)

A female aged 28 years suffered right herpes zoster ophthalmicus with subsequent scarring. 10 June 1981: right penetrating keratoplasty, 7.5 mm. 18 February 1982: +4.25 D.sp/-5.00 D.cyl axis 100°= 6/18.

Unfortunately all the sutures were removed indiscriminately without reference to the axis of astigmatism, resulting in +3.00 d.sp/-9.00 D.cyl axis 20°. 21 June 1982: refraction still -0.50 D.sp/-10.00 D.cyl axis 180°.

Interrupted sutures were placed in her cornea (Fig. 2) under general anaesthesia round the axis of the negative cylinder. One day later: +6.50 D.sp/-10.00 D.cyl axis 85°—that is, a change of cylinder of 20.00 dioptres. Between one and six weeks later single sutures were removed in the axis of the *positive* cylinder until her refraction was plano/-2.00 D.cyl axis 70°.

She has subsequently retained the small cylinder, and on 9 June 1983, twelve months later, her refraction was -0.50 D.sp/-2.00 D.cyl axis 50°.

One week after suturing

$$- 9.50 \times 87\frac{1}{2}^{\circ}$$

Between one and
Six weeks after suturing,
selected suture removal
around positive axis
(dashed lines).

After suture removal:

$$- 2.00 \times 70^{\circ}$$

Twelve months after
suturing

$$- 2.50 \times 50^{\circ}$$

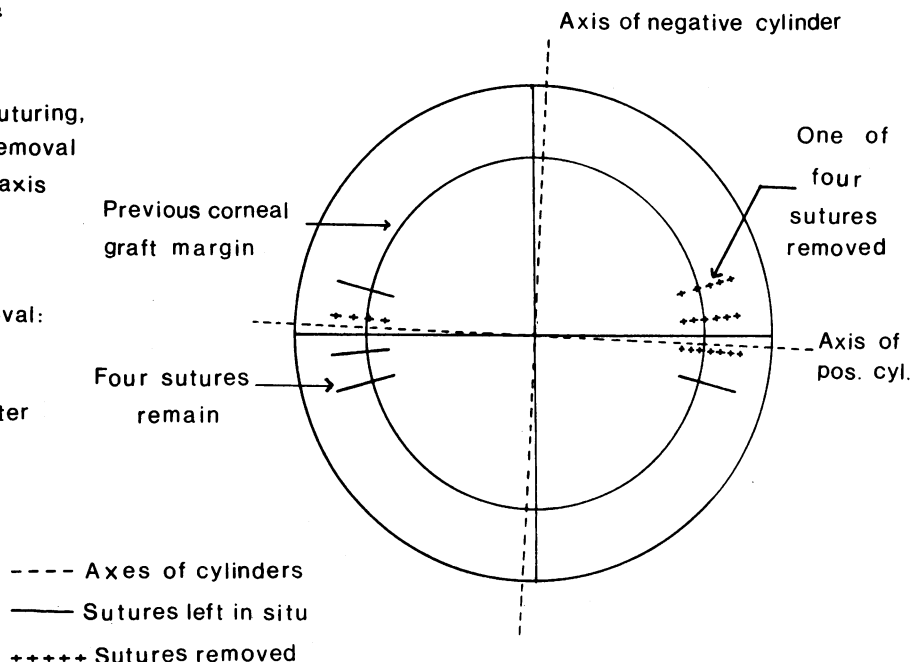


Fig. 3 Case 1. Between one and six weeks after suturing, selected sutures (shown as dashed lines) were removed around the line of the positive axis. The cylinder was checked between each removal until her refraction revealed 2 dioptres of astigmatism at six weeks. A year after suturing her cylinder is $-2.00 \times 50^{\circ}$.

COMMENT

The initial dramatic effect of the suturing can be seen, with a shift of the axis of astigmatism through 90° and a total change of 20 dioptres. Deliberate overcorrection was followed by cautious suture removal. Definitive adjustment was delayed for six weeks, to result in a 2.00 dioptre astigmatism still in the axis of the overcorrection. Her refraction has remained remarkably stable since then. Suture removal would have been equally effective and safer if begun at eight weeks.

CASE 2 (Fig. 4)

A female aged 68 years. 10 August 1982: left intracapsular extraction (corneal section) with four-loop Binkhorst intraocular lens. 14 October 1982: -1.00 D.sp/ -5.00 D.cyl axis 100° . Suture adjustment was attempted as described previously¹ but failed to improve her astigmatism, and the corneal suture was removed: -3.00 D.sp/ -5.00 D.cyl axis 90° . 18 January 1983: sutures were placed in the cornea (Fig.

4) with a resulting axis shift through 90° : -5.00 D.sp/ -2.00 D.cyl axis $180^\circ=6/6$.

Two weeks later the cornea was spherical and no suture removal was indicated. Four months later her refraction was still satisfactory: -4.50 D.sp/ -2.00 D.cyl axis $95^\circ=6/5$. 7 July 1983: six months after suturing had been undertaken a doctor unaware of our intention of long-term retention removed all the sutures. Fortunately in this case there was only a small change, and on 13 October 1983: -4.50 D.sp/ -2.50 D.cyl axis $97^\circ=6/6$ was found on refraction.

COMMENT

Overcorrection in this patient was small, and suture removal at six months carried a risk of recurrence of the original excessive error. However, the cornea in this case seems to have reached a stable form, and suture removal was not as unfortunate as expected. There is still a general misconception that corneal sutures need to be removed. It is emphasised that a

BEFORE SUTURING

$-5.00 \times 90^\circ$

Two days after

$-2.00 \times 180^\circ$

Two weeks after .

No astigmatism

Four months after

$-2.00 \times 95^\circ$

Nine months after

$-2.50 \times 97\frac{1}{2}^\circ$

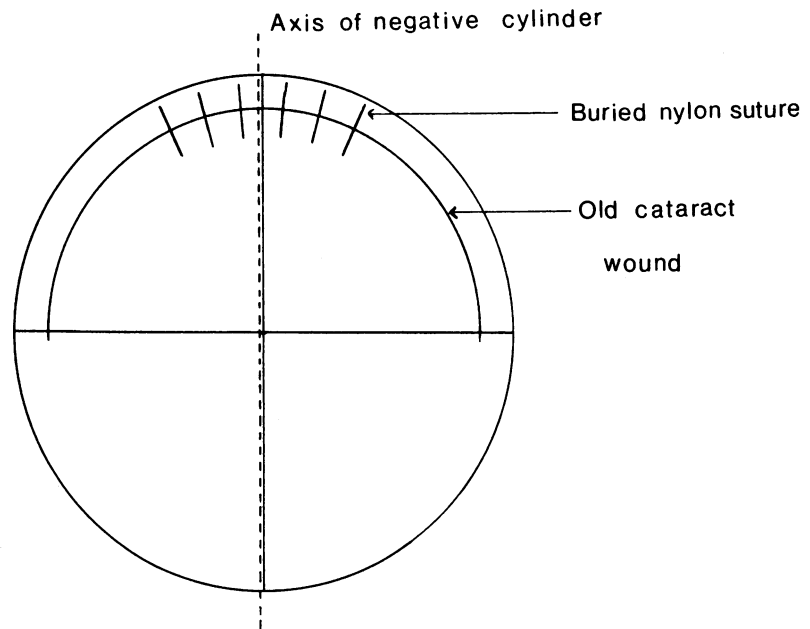


Fig. 4 Case 2. A female aged 68 years, had astigmatism following cataract extraction with insertion of intraocular lens. The astigmatism failed to respond to adjustment of the corneal continuous suture (see text) and the suture was removed. Interrupted nylon sutures were placed around the negative cylinder axis as shown, moving the axis through 90° . Two weeks later the cornea was spherical. Four months later the cylinder was $-2.00 \times 95^\circ$. Nine months after suturing the cylinder was $-2.50 \times 97\frac{1}{2}^\circ$ —that is, minimal change despite early removal of sutures (see text).

tightly organised follow-up is needed by those who are aware of the procedure and what it is intended to achieve.

CASE 3 (Fig. 5)

A male aged 65 years. 15 November 1977: right intracapsular extraction (corneal section) with four-loop Binkhorst intraocular lens insertion. 15 February 1978: +4.00 D.sp/−7.50 D.cyl axis 75° (adjustment and suture removal had failed). 25 February 1978: suturing of cornea (Fig. 5) in the axis of the negative cylinder. Initial overcorrection to +3.50 D.sp/−6.50 D.cyl axis 130°.

After single suture removal on 17 March 1978 his refraction was +1.50 D.sp/−3.00 D.cyl axis 105°. 21 March 1983: five years later (with frequent checks over the years showing stability) his refraction was still +1.50 D.sp/−3.00 D.cyl axis 97°=6/5.

COMMENT

Initial overcorrection was adjusted after three weeks with a satisfactory long-term result. We would wait longer now before adjusting.

CASE 4 (Fig. 6)

A male aged 70 years. 30 July 1982: right intra-

capsular extraction (corneal section) with four-loop Binkhorst intraocular lens insertion. 30 September 1982: continuous suture adjustment for 3.50 dioptres of astigmatism was attempted, but the suture broke and was removed. Immediate refraction was −5.00 D.sp/−1.00 D.cyl axis 90°. Three weeks later on 21 October 1982: +1.00 D.sp/−7.00 D.cyl axis 70°. A row of sutures (Fig. 6) was placed round the axis of the negative cylinder giving an initial result on 28 October 1982: +0.75 D.sp/−0.50 D.cyl axis 60°. Four weeks later on 25 November 1982: −1.75 D.sp/−1.25 D.cyl axis 90°. In December 1982 he died from a severe cerebrovascular accident.

COMMENT

This amount of corneal moulding (6 dioptres) after suture removal eight weeks after operation is unusual in our experience.

This man's tragic death prevented longer follow-up, but his case demonstrates slight undercorrection of the astigmatism—less reliable than initial overcorrection.

CASE 5 (Figs. 7 and 8)

A male aged 45 years sustained a perforating injury to his right eye in June 1978. The resultant cataract

BEFORE SUTURING

− 7.50 x 75°

AFTER: − 6.50 x 130°

3 Weeks later, after selected suture removal (not shown)

− 3.00 x 105°

Five years later

− 3.00 x 97°

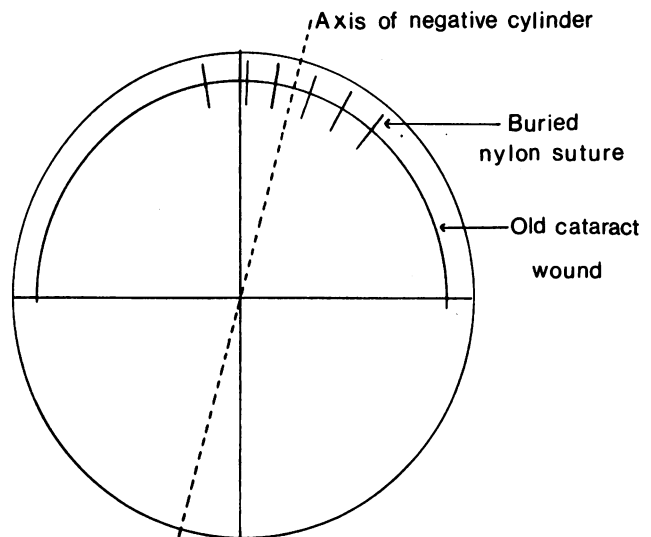


Fig. 5 Case 3. A male aged 65 years, had astigmatism following cataract extraction and intraocular lens insertion. Suture adjustment failed (see text) and the corneal sutures were removed, following which he still had 6.50 dioptres astigmatism. Buried nylon sutures were placed around the negative cylinder axis as shown, resulting in an axis shift from 75° to 130°. Three weeks later selected sutures were removed in stages until astigmatism was only 3.00 dioptres. Five years later he retained a refraction of −3.00 x 97° 6/5.

BEFORE SUTURING

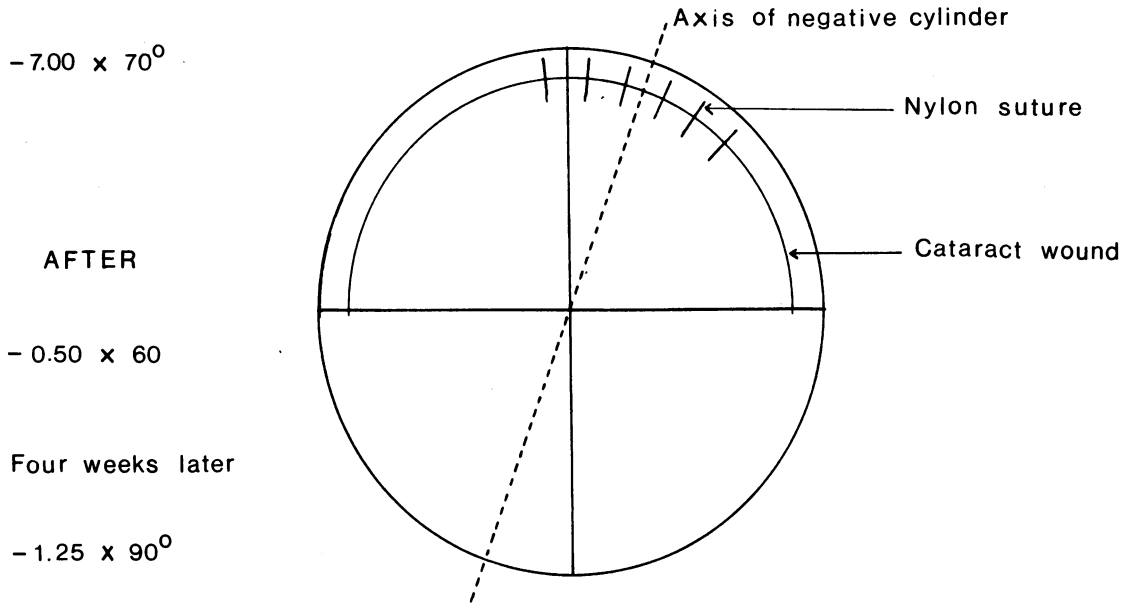


Fig. 6 Case 4. A male aged 70 years, developed astigmatism following cataract extraction using a continuous corneal suture. Suture adjustment was attempted at eight weeks after operation, but the suture broke. Over the next three weeks the cylinder increased to $-7.00 \times 70^\circ$. Interrupted sutures were placed around the negative cylinder axis, and after one week the cylinder was $-0.50 \times 60^\circ$. A month later, eight weeks after suturing, the cylinder was $-1.25 \times 90^\circ$. Further follow-up was prevented by his death from a cerebrovascular accident.

was removed in September 1981, but he had high astigmatism from the original scarring. 5 October 1982: $+15.00$ D.sp/ -7.00 D.cyl axis 85° . His cornea was sutured with buried 10/0 nylon around the negative cylinder axis (Fig. 4). Subsequent refraction was $+14.00$ D.sp/ -5.00 D.cyl axis 160° , a significant axis shift.

4 November 1982: interrupted sutures were removed in the axis of the new positive cylinder (Fig. 5) with an encouraging initial result: $+15.00$ D.sp/ -2.00 D.cyl axis 90° . 6 January 1983: his refraction had unfortunately changed to $+17.00$ D.sp/ -7.00 D.cyl axis 80° .

14 April 1983: the cornea was resutured in the same manner as before. Next day: $+17.00$ D.sp/ -7.00 D.cyl axis 165° . One suture was removed: $+15.00$ D.sp/ -6.00 D.cyl axis 120° . 9 June 1983: $+15.00$ D.sp/ -5.00 D.cyl axis 110° ; he had reverted to his original astigmatism.

COMMENT

The failure of both attempts at correction was probably explained by the large traumatic scar, which was more difficult to mould than keratoplasty or

cataract sections. In addition the 10/0 suture material was too weak and the sutures were removed too early after both attempts. 9/0 Material is preferable.

Discussion

These suturing procedures were uncomplicated both at the time of surgery and afterwards. The procedure is simple enough to require minimal skill, provided an operating microscope is used and the sutures are placed with care. It is perhaps less easy to decide where the sutures should be placed, how many, and when they should be removed to obtain the desired long-term result. The case reports show that changes continue for some time, and it is important to exercise patience before making the definitive 'final' adjustment. The procedure is essentially reversible, and it is intended that some sutures are left in place until they degrade and fragment some two years later. By that time it seems that the refraction will have stabilised without the suture support. In case 5 a number of factors contributed to this one failure: (1) the suture used was too thin; (2) sutures were removed too early; (3) the astigmatism was due to

BEFORE SUTURING

- 7.00 x 85⁰

AFTER

- 5.00 x 160⁰

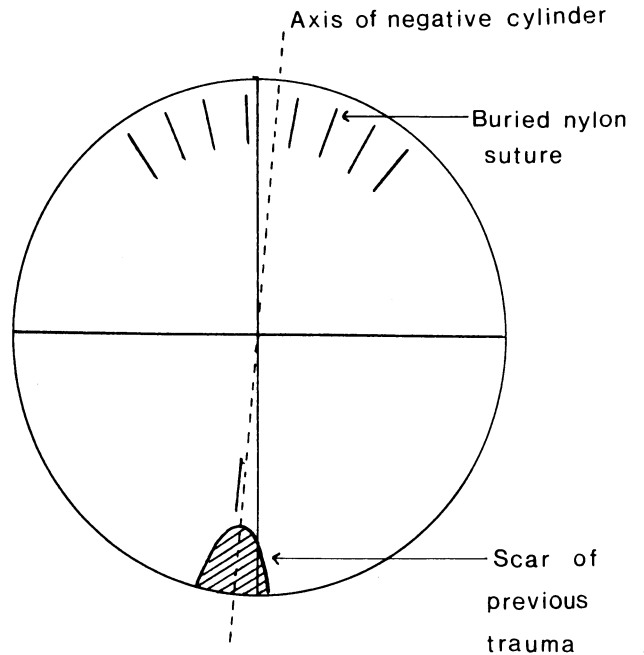


Fig. 7 Case 5. A man aged 45 years, sustained a perforating injury with lens damage in June 1979. His lens was removed in September 1981, but astigmatism of 7.00 dioptres remained after 28 months despite removal of corneal sutures in cataract section. A row of buried 10/0 nylon sutures were placed around 85° (the negative axis) overcorrecting the astigmatism to -5.00 x 160°.

Before suture removal

- 5.00 x 160⁰

After removal

- 2.00 x 90⁰

Two months later

- 7.00 x 80⁰

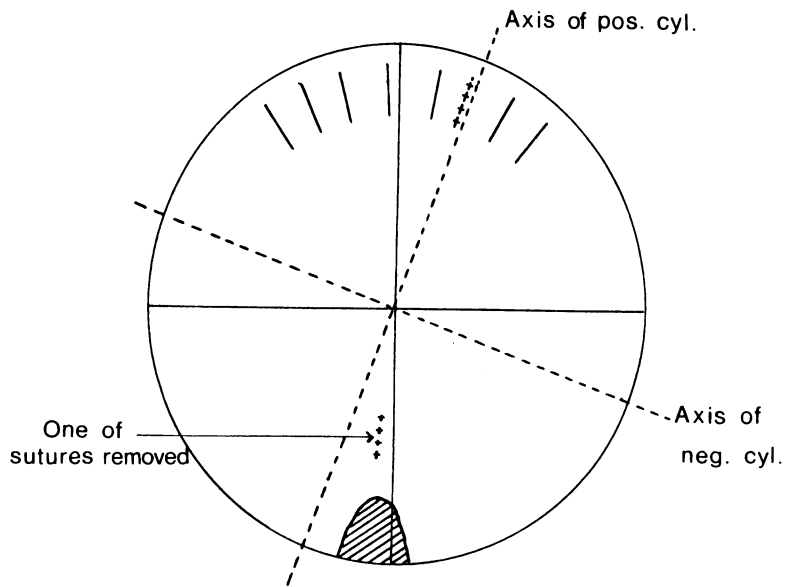


Fig. 8 Case 5. The new negative and positive axes are shown. One week after suturing, two sutures, shown dashed, were removed, giving an initial encouraging result of 2 dioptres. However, the suture material was too weak and the sutures were removed too early. Two months later the astigmatism was back to -7.00 x 80°. A further attempt at suturing was also unsuccessful (see text).

trauma and subsequent reparative surgery, resulting in two corneal wounds with complex stresses. The cornea was probably less able to undergo corneal moulding than the other cases which were routine keratoplasty or cataract sections.

From our experience of the cases described above and others in which selected suture removal or adjustment can not be applied we recommend over-correction of the astigmatism by suturing in uncut cornea with 9/0 nylon in the negative cylinder axis. After waiting 4–8 weeks for corneal moulding one selected suture is removed at a time in the new positive axis and the refractive error rechecked. 2–3

Dioptres should be left in the new axis to allow for further decay.

References

- 1 Roper-Hall MJ. The control of astigmatism after surgery and trauma: *Br J Ophthalmol* 1982; **66**: 556–9.
- 2 Fyodorov S. Surgical correction of myopia and astigmatism. In: Schachar RA, Levy NS, Schachar L, eds. *Keratorefraction*. Proceedings of the Keratorefractive Society. Denison, Texas, PO Box 145, 1980: 141–72.
- 3 Troutman RC. Microsurgical control of corneal astigmatism in cataract and keratoplasty. *Trans Am Acad Ophthalmol Otolaryngol* 1973; **77**: 563–72.
- 4 Atkins AD, Roper-Hall MJ. Control of postoperative astigmatism. *Br J Ophthalmol* 1985; **69**: 348–51.