

## Lacrimal canalicular papillomatosis

ROBERT WILLIAMS, MICHAEL ILSAR, AND RICHARD A N WELHAM

*From Moorfields Eye Hospital, City Road, London EC1V 2PD*

**SUMMARY** Three new cases of lacrimal canalicular papillomatosis are reported and the total of 12 cases in the literature reviewed. They present with epiphora or a local mass. Multiple recurrences over many years is characteristic. A minority have papillomata of the conjunctiva or lacrimal sac. Histopathological examination shows a benign papilloma with a fibrovascular stalk. Treatment was either multiple excision or cryotherapy, but neither affected the rate of occurrence. A viral aetiology is postulated in some cases.

Lacrimal canalicular papillomatosis was first described by Demaiens in 1818.<sup>1</sup> The aetiology and management remain obscure. We report three cases seen in the Lacrimal Clinic at Moorfields Eye Hospital, London, and review previously reported cases.

### Case reports

#### CASE 1

A 9-year-old West Indian girl presented with a four-month history of right epiphora and was found to have a mass protruding from the right lower punctum. There was nothing of note in the past ophthalmic or medical history. The mass was explored by a canaliculostomy. The canaliculus was seen to be grossly distended, and a papilloma originated from a stalk attached to the epithelium of the lacrimal canalicular ampulla. The papilloma was shaved off. Two months later it recurred at the same site and was similarly treated. Two months later it again recurred at the same site. (Syringing and a dacryocystogram suggested an obstruction at the lower end of the sac.) The papilloma was excised, the lacrimal sac was explored and found to have mucosal thickening, but no papillomata were seen. Six months later it recurred at the same site and an additional papilloma was seen arising from the superior canaliculus. Both were excised. At operation the superior papilloma was found to originate from the middle of the superior canaliculus and the inferior to originate from the ampulla. Cryotherapy was applied to the base of each. One month later it recurred and was seen to grow 4 mm in two weeks

prior to excision (Figs. 1 and 2). Both were again excised, but more extensive double freeze cryotherapy was applied. She was last seen four months after this and there was no further recurrence, but there was depigmentation of the skin and canalicular blockage. At no stage was she seen to have papillomata of the conjunctiva.

The histology of all the specimens showed a squamous papilloma (Fig. 3). There was no cellular atypia, koilocytosis, or nuclear inclusion bodies. Electron microscopy did not show any virus-like particles. Viral cultures of the lesions and viral serology were negative on two occasions. The white blood cell count and a standard set of immunological tests were within normal limits.

#### CASE 2

A 39-year-old Guyanan male resident in England presented with a mass on the tarsal conjunctival aspect of the right upper lid which had been present for three weeks. He was otherwise well. This was excised and found to be a squamous papilloma. Seven months later it recurred at the same site, and additional papillomata were seen growing out of the superior and inferior puncta. At canaliculostomy these were found to originate from the ampulla of the canaliculus. All were excised. During the next five years the canalicular lesions recurred on 11 occasions at intervals of one to nine months, and on two occasions additional lesions of the tarsal conjunctiva recurred. All recurrences were excised at the base. On four occasions cryotherapy was applied to the base but it did not appear to modify the recurrence. On one occasion radiotherapy was given 3600 R to the inner canthus and 2400 R to the lid, but the papillomata continued to enlarge for six months after

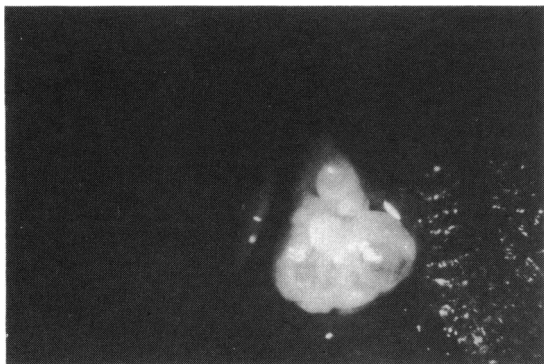


Fig. 1 *Lacrimal canalicular papilloma.*

this and were then excised. During this period dacryocystograms did not reveal any filling defects of the lacrimal sac.

There was then a respite of four years until he again developed symptoms at the age of 48, nine years after the original presentation. For three months he suffered mucous discharge from the previously treated right eye. A hard mass was palpable in the region of the lacrimal sac, and a dacryocystogram (Fig. 4) showed filling defects of the lacrimal sac compatible with multiple papillomata. He was treated with trifluorothymidine drops five times daily for two months with no relief. He then additionally developed recurrent papilloma of the tarsal conjunctiva. A dacryocystorhinostomy was performed and the lacrimal sac was found to be full of papillomata. All were excised along with the conjunctival papilloma and cryotherapy applied to their bases. Three months later, a small mass was noted in the inferior end of the incision scar. This was excised and found to be an intramuscular papilloma not communicating with the mucosa. Three months later there was a recurrence on the tarsal conjunctiva, which was excised and the

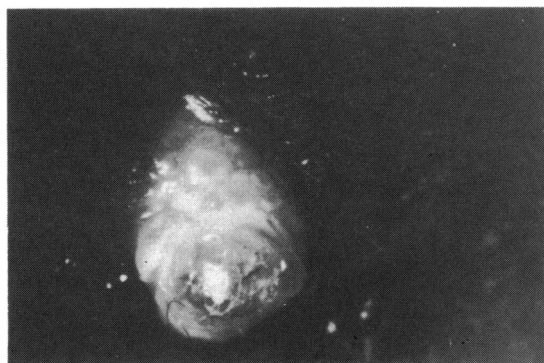

Fig. 2 *Lacrimal canalicular papilloma: same case as Fig. 1 after elapse of two weeks.*

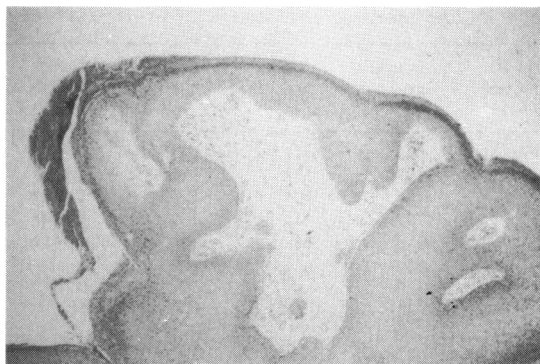

Fig. 3 *Lacrimal canalicular papilloma. (Haematoxylin and eosin,  $\times 85$ .)*

base treated with cryotherapy. Eight months after this there was a recurrence in the superior canaliculus and a papilloma in the nose arising from the mucosa at the site of the previous dacryocystorhinostomy. Both were excised and treated with cryotherapy. He was last examined 10 years after this, and there were no further recurrences or further tumours. The histopathology on all specimens was similar to the first case.

#### CASE 3

A 24-year-old white male presented with a two-month history of unilateral epiphora. Twelve years previously he had a squamous papilloma of the tongue, but there was nothing else of note in the previous medical history. On examination papillomata were protruding from the superior and inferior puncta. There were no conjunctival papillomata. Canaliculostomy was performed, and both papillomata were seen to originate from stalks attached to

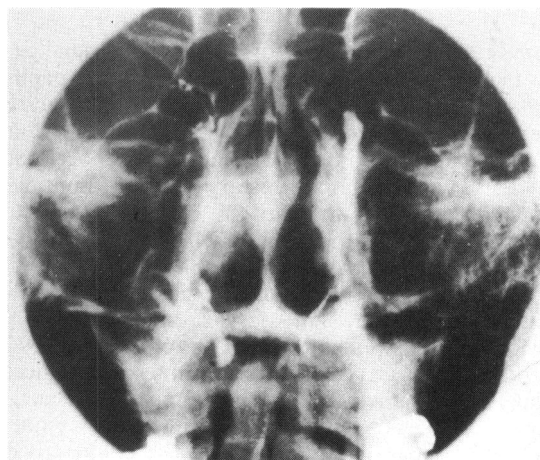


Fig. 4 *Dacryocystogram of papillomata lacrimal sac associated with papillomata of lacrimal canaliculus.*

Table 1 *Previously reported cases*

Author, reference number	Patient's age	Patient's sex	Side lesion	Canal-iculus involved	Total length history	Total No. recurrences	Treatment	Response to treatment
Anderson <sup>2</sup>	62	M	Left	Lower	3 weeks	Nil	Excision	No recurrences
Aubineau <sup>3</sup>	50	M	Left	Upper	1 Year	Nil	Excision	No recurrences
Ayres <sup>4</sup>	?	F	Right	Lower	1 Year	—	Excision	—
Burke <sup>5</sup>	74	M	Right	Lower	—	—	Excision	—
Camera and Quintana <sup>6</sup>	11	M	Right	Lower	2½ Years	1	Excision	Recurred 3 months
							Excision and cryotherapy	No recurrence
Corticelli <i>et al.</i> <sup>7</sup>	15	—	—	—	9 Years	2	Excision	Recurred 6 years
							Excision	Recurred 3 years
							Excision	No recurrence
							Excision × 4	Recurrence × 3
Juler <sup>8</sup>	14	F	Right	Lower	9 Years	4	Excision	—
Libby <sup>9</sup>	40	F	Right	Lower	2 Years	9	Pulled off	Recurred 2 days
							Excision × 7	Recurred 2 days × 7
							Excision and curettage and syringing boric acid	No recurrence
Maruko and Nakagawa <sup>10</sup>	12	M	Left	Lower	—	Nil	Excision	No recurrence
Nicoletti <sup>11</sup>	33	M	Left	Lower	10 Days	Nil	Excision	No recurrence

the ampulla of the canaliculi. These were excised and cryotherapy was applied. The canaliculi and nasolacrimal duct were probed and found patent to the nose. The pathology was similar to that in cases 1 and 2, and electron microscopy did not reveal virus-like particles. There was no recurrence for three years after surgery and he was then lost to follow-up.

#### PREVIOUSLY REPORTED CASES

The previously reported cases are summarised in Table 1.<sup>2-10</sup>

#### Discussion

The cases reported here show that lacrimal canicular papillomata are not usually associated with papillomata of the conjunctiva or lacrimal sac but a minority may be. They are usually unilateral, present with epiphora, with or without a mass, and occur at all ages, and the natural history is one of multiple recurrences over many years.

Human papilloma virus is a DNA virus; it may be implicated in lacrimal canicular papillomatosis.

Eleven serotypes occur and have been linked with papilloma of the skin, larynx, and genitalia.<sup>11</sup> Evidence of papilloma virus causing conjunctival papillomata is accumulating from histological appearances, immunofluorescent staining of specimens,<sup>12</sup> and DNA molecular hybridization.<sup>13</sup> Papilloma virus may cause some cases of conjunctival papillomata. However, the detection of viruses is much less frequent than in other papillomata, and, if

they are a causative factor, the serotype is as yet unknown. The coexistence in some cases of lacrimal canicular papillomata may also be caused by the papilloma virus. Failure to demonstrate papilloma virus in lacrimal canicular papillomatosis by either electron microscopy or viral culture does not exclude a viral aetiology, as these techniques are difficult in this group of viruses. However, koilocytosis and nuclear inclusion bodies are histopathological features suggesting a viral cause.<sup>12</sup> These are absent in lacrimal canicular papillomata, which may be considered a factor against a viral aetiology. Features of conjunctival papillomata have been listed suggesting that some are of viral origin and some are of another cause.<sup>14</sup> Extrapolation of these features to the lacrimal canicular papillomatosis is unhelpful, as the young age, multiple recurrences, and spontaneous resolution suggest a viral aetiology, whereas the unilaterality, long history, and non-transmissibility suggest some other aetiology in the same cases. Confirmation of a viral aetiology is important, as evidence is now accumulating that some papilloma viruses predispose to malignancy.<sup>11 15</sup> As yet there is no report of the lacrimal canicular papillomata undergoing malignant transformation.

Treatment of lacrimal canicular papillomata is to expose the base and excise the papilloma. Cryotherapy has been shown to be an effective alternative treatment of conjunctival papillomata<sup>16-18</sup> and may be considered in lacrimal canicular papillomata. An attempt at cryotherapy of lacrimal canicular papillomata would also necessitate canaliculostomy to

expose the base of the papilloma, and it has not been reported as the sole treatment. Antiviral chemotherapy has only once been tried and was ineffective, as new papillomata grew while it was being given, and there was no effect on the existing papillomata. The methods tried to prevent recurrence, cryotherapy, and radiotherapy have not been shown to be successful and may lead to local complications.

#### References

- 1 Demains AP. Traité des maladies des yeux. Paris: Chez L'auteur et Crochard, 1818; 2: 92.
- 2 Anderson DR. Unilateral epiphora caused by papilloma of lower canaliculus. *Arch Ophthalmol* 1967; **78**: 618–20.
- 3 Aubineau E. Polyypes du canalicule lacrymal superior. *Arch Ophthalmol* 1923; **40**: 228–31.
- 4 Ayres SC. Polypus of lower canaliculus. *Arch Ophthalmol* 1903; **32**: 369–71.
- 5 Burke JW. Papilloma lying within lower canaliculus. *Am J Ophthalmol* 1938; **21**: 189.
- 6 Camara J, Quintana M. Canaliculitis papillomatosa. *Arch Soc Espanol Oftalmol* 1975; **35**: 173–8.
- 7 Cotticelli L, Savastano S, Romano A, Dimeo A. Papilloma del canaliculo lacrimale inferior. *Boll Occulist* 1978; **57**: 75–8.
- 8 Juler FA. A papilloma in the upper canaliculus. *Trans Ophthalmol Soc UK* 1975; **35**: 243–4.
- 9 Libby GF. Polyps in the lower canaliculus. *Ophthalmic Record* 1904; **13**: 368–70.
- 10 Maruko H, Nakagawa T. A case of primary papilloma of lacrimal canaliculus. *Folia Ophthalmol Jpn* 1977; **27**: 937–9.
- 11 Niccoletti G. Papilloma del canaliculo lacrimale inferior. *Ann Ottalmol Clin Oculist* 1926; **12**: 24–6.
- 12 Howley, DM. The human papilloma virus. *Arch Pathol Lab Med* 1982; **106**: 429–32.
- 13 Lass JH, Jenson AB, Papale JJ, Albert DM, Papilloma virus in human conjunctival papillomas. *Am J Ophthalmol* 1983; **95**: 364–8.
- 14 Lass JH, Grove AS, Papale JJ, *et al.* Detection of human papilloma virus DNA. Sequences in conjunctival papillomata. *Am J Ophthalmol* 1983; **96**: 670–4.
- 15 Wilson FM, Ostler HB. Conjunctival papillomata in siblings. *Am J Ophthalmol* 1974; **77**: 103–7.
- 16 Singer A, Walker PG, McCance DS. Genital wart virus infection. *Br Med J* 1984; **282**: 735–7.
- 17 Harkey NE, Netz HS. Cryotherapy of conjunctival papillomas. *Am J Ophthalmol* 1968; **66**: 872–4.
- 18 Omohundro JM, Elliott JH. Cryotherapy of conjunctival papillomas. *Arch Ophthalmol* 1970; **84**: 609–10.