



Current use of extracorporeal life support in airway surgery: a narrative review

Alexis Slama^{1,2}, Theresa Stork^{1,2}, Stephane Collaud^{1,2}, Clemens Aigner^{1,3}

¹Department of Thoracic Surgery, University Medicine Essen, Ruhrlandklinik, Essen, Germany; ²Department of Thoracic Surgery, Cologne-Merheim Hospital, Witten/Herdecke University, Cologne, Germany; ³Department of Thoracic Surgery, Klinik Floridsdorf, Vienna, Austria

Contributions: (I) Conception and design: A Slama, C Aigner; (II) Administrative support: None; (III) Provision of study materials or patients: None; (IV) Collection and assembly of data: A Slama; (V) Data analysis and interpretation: A Slama, S Collaud, C Aigner; (VI) Manuscript writing: All authors; (VII) Final approval of manuscript: All authors.

Correspondence to: Alexis Slama. Department of Thoracic Surgery, Cologne-Merheim Hospital, Witten/Herdecke University, Ostmerheimer Str. 200, 51109 Cologne, Germany. Email: SlamaA@kliniken-koeln.de.

Background and Objective: Extracorporeal life support (ECLS) is widely used in patients with severe respiratory or cardiocirculatory failure. The most commonly used extracorporeal membrane oxygenation (ECMO) modes are veno-venous (V-V) and veno-arterial (V-A) ECMO, which can both be achieved by various types of vascular cannulation. Within the scope of tracheobronchial surgery, intraoperative ECLS may occasionally be necessary to provide sufficient oxygenation to a patient throughout a procedure, especially when conventional ventilation strategies are limited. Additionally, V-A ECMO can provide cardiopulmonary support in emergencies and in cases where hemodynamic instability can occur.

Methods: This narrative literature review was carried out to identify the use and the specifics of ECLS in airway surgery over the last years. Data from 168 cases were summarized according to the indication for surgery and the mode of ECLS (V-V, V-A).

Key Content and Findings: The most common tracheobronchial pathologies in which support was needed were: primary malignant disease of the airways, malignant infiltration, tracheal stenosis, injury of the airway, and congenital airway disease. With increasing experience in ECLS, the number of reported cases performed with intraoperative ECLS increased steadily over the last decade.

Conclusions: A trend favoring the use of V-V ECMO over V-A ECMO was identified. These approaches should now be considered indispensable tools for managing challenging surgical cases.

Keywords: Extracorporeal life support (ECLS); airway surgery; extracorporeal membrane oxygenation (ECMO); tracheobronchial; tracheal surgery

Submitted Oct 19, 2022. Accepted for publication Mar 01, 2023. Published online Mar 07, 2023.

doi: 10.21037/jtd-22-1483

View this article at: <https://dx.doi.org/10.21037/jtd-22-1483>

Introduction

Background

Airway patency and adequate oxygenation throughout elective or emergency procedures are significant requirements in thoracic surgery. Especially in patients suffering from a pathology affecting the central airways, it can be very challenging to maintain these conditions during both inductions of anesthesia and surgery. Different

ventilation strategies, such as intermittent apnea, cross table, or jet ventilation, are routinely used to supply O₂ sufficiently and eliminate CO₂ via the lungs. In rare and more complex cases, the applicability and usefulness of these methods may be limited either by the pathology itself or by the surgical extent of the resection. In these patients, intraoperative extracorporeal life support (ECLS) can provide a safe way to maintain gas exchange and hemodynamic stability during surgery if needed. ECLS is a collective term referring to

various modalities utilizing an extracorporeal blood circuit and oxygenator to achieve gas exchange and/or cardiac support (1).

Rationale

V-V ECMO and V-A ECMO represent the most commonly used ECLS modes during surgery involving the airways, whereas pumpless (pl) A-V and CPB are rarely used. Their specifics and the considerations on the choice of support have been extensively described previously within the scope of airway surgery (2) and lung transplantation (3). This review aims at giving a complete overview and update of published cases where ECLS was used to support surgery involving the central airways. It will focus on the diversity of indications for surgery and the performed operations without diving into technical details regarding ECLS, covered in another review of this *JTD* special series.

Objective

This narrative review focuses on the potential of identifying patterns regarding the different ECLS modes and configurations used in specific cases and recent changes in clinical practice. We present this article in accordance with the Narrative Review reporting checklist (available at <https://jtd.amegroups.com/article/view/10.21037/jtd-22-1483/rc>).

Methods

A PubMed search was conducted in September 2022 to identify published literature on the use of ECLS during airway surgery. The search query was: ((ECLS[Title/Abstract] OR (ECMO[Title/Abstract] OR (extracorporeal membrane oxygenation [Title/Abstract]))) AND ((airway[Title/Abstract] OR (trachea[Title/Abstract]))) AND ((surgery[Title/Abstract] OR (resection[Title/Abstract] OR (repair[Title/Abstract])). All results published since 2015 were screened for patients who underwent airway surgery with concomitant intraoperative ECLS support. Patients who underwent anatomical lung resections without bronchial sleeve anastomoses and those who underwent wedge resections, lung transplantation, or bronchoscopic interventions were not considered for this analysis. Since 2015, 29 published case reports/series were identified with a median of 3 patients (range, 1–23) per publication. In total, 168 published patient cases have been identified since 1992

(n=135 since 2015). Information on the indication, surgical procedure, ECLS modality, and configuration was recorded if available (*Table 1*). ECLS modes and configurations were defined according to the ELSO nomenclature (1). Flow diagrams were made with SankeyMATIC (www.sankeymatic.com).

Choice of ECLS mode in airway surgery

In surgical cases where only support for insufficient ventilation/oxygenation during the procedure is sought, veno-venous ECMO (V-V) was the most common support mode chosen as it is technically easier to set in place and less at risk of complications than veno-arterial ECMO (V-A). The most commonly reported cannula configurations in V-V ECMO are the femoral vein (V_f) for drainage and the internal jugular vein (V_j) to return oxygenated blood. 72% of the V-V cases (n=41/57) reporting information on cannulation had a V_f - V_j configuration. Alternatively, bifemoral cannulation (V_f - V_f) was used in 25% of V-V cases (n=14/57). A bifemoral approach bears the advantage of keeping the neck free in cases where broad surgical access and mobilization of the neck is needed (malignant infiltration in upper airways) or when the superior vena cava or the jugular veins are obstructed by either thrombi or tumor infiltration. With bifemoral cannulas, extracorporeal recirculation of already oxygenated blood is more likely to happen, inevitably limiting the amount of oxygen delivered to the patient. As both cannulas will have their tip placed in the inferior vena cava, they must be positioned with sufficient space apart. Of all reports, femoral pumpless arterio-venous CO_2 removal (ECCO2R: extracorporeal carbon dioxide removal, (pl)A-V) was only used in one case of a tracheoesophageal fistula repair (33). Double-lumen cannulas are a good alternative to conventional double cannulation approaches, but their use in intraoperative support during airway surgery remains very limited so far. Correct placement is crucial and has to be verified via fluoroscopy or transesophageal echocardiography (34,35).

V-A ECMO should be considered in patients who are already hemodynamically unstable before the intervention or who might become so during surgery. V-A ECMO allows for circulatory support by unloading the right and, to a certain extent, the left ventricle. Although in patients with high cardiac output and no alveolar ventilation, O_2 delivery to the systemic circulation can sometimes be less than with V-V ECMO, it may be necessary for patients where mediastinal access is difficult, and the heart needs to be

Table 1 Recently published experience on the use of ECLS during airway surgery since 2015 an own recent unpublished data

Author	Journal	Year	Pt#	Indication	Intervention	Modes	Configurations
Kim <i>et al.</i> (4)	<i>Ann Thorac Cardiovasc Surg</i>	2015	7	Tracheal injury, tumors, stenosis	Tracheal resection, repair	V-A, V-V	V _r -A _r , V _r -V _j
Lang <i>et al.</i> (5)	<i>Eur J Cardiothorac Surg</i>	2015	10	Malignant tumors	Carinal resection; bronchiovascular sleeves	V-A	7 RA-AO, V _r -A _r
Rinieri <i>et al.</i> (6)	<i>Eur J Cardiothorac Surg</i>	2015	23	ND	Tracheal resection, carinal resection, LMB resection	V-A, V-V	ND
Yuba <i>et al.</i> (7)	<i>Kyobu geka, Jpn. j. thorac. surg.</i>	2016	1	ACC	Tracheal resection	ND	ND
Kim <i>et al.</i> (8)	<i>Asaio j</i>	2017	9	Stenosis, ACC, malacia, tumor compression	Tracheal resection, debulking	8 V-V, 1 V-A	V _r -V _r , V _r -V _j , V _r -A _r
Antonacci <i>et al.</i> (9)	<i>Int J Surg Case Rep</i>	2018	1	Iatrogenic tracheal injury	Tracheal suture	V-V	V _r -V _j
Wannaz <i>et al.</i> (10)	<i>Int J Surg Case Rep</i>	2018	1	Paraganglioma	Membranous resection	V-A	V _r -A _r
Madurka <i>et al.</i> (11)	<i>Orv Hetil</i>	2019	3	Tracheal stenosis	ND	V-V	ND
Qiu <i>et al.</i> (12)	<i>Thorac Cancer</i>	2019	1	MEC	Carinal resection	V-V	V _r -V _j
Rajab <i>et al.</i> (13)	<i>Ann Thorac Surg</i>	2019	1	Tracheal stenosis, CAD	Tracheal resection, CABG	V-V, CPB	V _r -V _j , central CPB
Pu <i>et al.</i> (14)	<i>Ann Thorac Cardiovasc Surg</i>	2020	4	Tracheal stenosis	Tracheal resection; tracheoplasty	3 V-V, 1 V-A	V _r -V _j , V _r -A _r
Yang <i>et al.</i> (15)	<i>J Cardiothorac Surg</i>	2020	1	ACC	Sleeve pneumonectomy	V-V	V _r -V _j
Alkhasov <i>et al.</i> (16)	<i>J Laparoendosc Adv Surg Tech A</i>	2021	4	Congenital stenosis	Slide tracheoplasty	3 V-A, 1 CPB	central
Al-Thani <i>et al.</i> (17)	<i>J Surg Case Rep</i>	2021	3	Tracheal/bronchial injury	Surgical repair	V-V	ND
Chen <i>et al.</i> (18)	<i>J Thorac Dis</i>	2021	7	SCC, MEC, Schwannoma, lymphoma	Carinal resection, carinal resection + lobectomy, tracheal resection	V-V	V _r -V _j , V _r -V _s
Ikeda <i>et al.</i> (19)	<i>Surg Today</i>	2021	1	Thyroid carcinoma	Thyroidectomy + tracheal resection	V-A	V _r -A _r
Kim <i>et al.</i> (20)	<i>Ann Thorac Cardiovasc Surg</i>	2021	19	ND	ND	V-V, V-A	V _r -V _j , V _r -A _r
Liu <i>et al.</i> (21)	<i>Ann Palliat Med</i>	2021	8	SCC, MEC, ACC, stenosis	Tracheal resection	V-V	V _r -V _j
Zhang <i>et al.</i> (22)	<i>Perfusion</i>	2021	4	Traumatic rupture, stenosis, malignant stenosis	Surgical repair; resection	V-A	V _r -A _r
Bauer <i>et al.</i> (23)	<i>Int J Oral Maxillofac Surg</i>	2022	3	TEF	Repair	V-V	V _r -V _i
Choi <i>et al.</i> (24)	<i>Int Med Case Rep J</i>	2022	1	ACC	Tracheal resection	V-V	V _r -V _i
Evermann <i>et al.</i> (25)	<i>Annals of Thoracic Surgery</i>	2022	6	Tracheal injury	Surgical repair	4 V-V, 2 V-A	ND

Table 1 (continued)

Table 1 (continued)

Author	Journal	Year	Pt#	Indication	Intervention	Modes	Configurations
He et al. (26)	<i>Transl Lung Cancer Res</i>	2022	1	Malignant lesion	Carina+ LMB resection	V-A	V _r -AO
Koh et al. (27)	<i>SAGE Open Med Case Rep</i>	2022	1	Tracheal rupture	Posterior suture	V-V	V _r -V _f
Suzuki et al. (28)	<i>Annals of Thoracic Surgery</i>	2022	8	Malignant tumors	Sleeve pneumonectomy/sleeve lobectomy/trachea resection/bronchoplasty	ND	ND
Todo et al. (29)	<i>Surg Case Rep</i>	2022	1	Congenital stenosis	Slide tracheoplasty	V-A	V _r -A _r
Venkataramani et al. (30)	<i>Saudi J Anaesth</i>	2022	1	Tracheal stenosis	Tracheal resection	V-A	V _r -A _r
Voltolini et al. (31)	<i>Interact Cardiovasc Thorac Surg</i>	2022	1	Chondrosarcoma	Carinal resection	V-V	V _r -V _j
Martinod et al. (32)	<i>Am J Transplant</i>	2022	4	NET, ACC	Airway replacement	V-V	ND
Slama/Collaud	<i>Own unpublished data</i>		9	Malignant tumors, tracheal injury	Carinal resection, surgical repair	V-V	V _r -V _j , V _r -V _f

ND, not disclosed; ACC, adenoid cystic carcinoma; MEC, mucoepidermoid carcinoma; CAD, coronary artery disease; SCC, squamous cell carcinoma; TEF, trachea-esophageal fistula; CABG, coronary artery bypass graft; LMB, left middle bronchus; V-A, veno-arterial; V-V, veno-venous; CPB, cardio-pulmonary bypass; V_f, femoral vein; A_r, femoral artery; V_j, internal jugular vein; V_s, subclavian vein.

retracted during the procedure. In the available literature, 64% of cases (n=37/58) with intraoperative V-A ECMO had peripheral cannulation, whereas central cannulation was used in 36% (n=21/58).

Cardio-pulmonary bypass (CPB) has virtually disappeared from current practice in adult airway surgery (13,16). CPB has a significantly higher risk of complications, and its use within the scope of airway resections should be limited to procedures involving the great vessels or the heart. A noteworthy example is a tracheal resection with a concomitant coronary artery bypass graft (CABG) procedure (13).

Indications for surgery with intraoperative extracorporeal support

Primary malignancy of the central airways

The most common indication for airway surgery using ECLS was primary malignancy of the airways, with 27% of cases in the literature (n=45/168). The histological subtypes were: squamous cell carcinoma (SCC) in 15 cases (18,36,37), adenoid cystic carcinoma (ACC, n=10) (7,15,24), neuroendocrine tumor (NET, n=3) (5,18),

sarcoma (n=2) (31,38), mucoepidermoid carcinoma (MEC, n=2) (12,21) and adenocarcinoma (n=1) (39). Based on tumor localization, the type of resections was: carinal resection (n=16), segmental tracheal resection (n=9), pulmonary bronchial sleeve resections w/o carina (n=10), airway replacement with stented aortic matrices (n=4), left main bronchus resection w/o (Hemi-)carina (n=3) and resection of the membranous tracheal wall (n=3). Regarding the ECLS mode, V-A ECMO (both central and peripheral) was used equally often as V-V in those cases (V-V: 50%; V-A 50%).

Malignant infiltration of the trachea

In seven cases of reported intraoperative ECLS use (4.2%), the trachea was severely obstructed by a tumor originating from surrounding structures. These malignancies were limited to thyroid cancer (n=4) (19,40,41); and lymphoma (n=3) (8,18,22), and the surgeries performed consisted mainly in resecting the tumor and a segmental portion of the trachea (n=6). A surgical debulking was performed in one case (8). All cases were performed under peripheral ECLS cannulation with the prevalent use of V-A ECMO (n=5).

Interestingly, no cases involving a tracheal infiltration from other cancers (esophageal, thymic, or sarcomatous) have been reported.

Tracheal stenosis

The second most common use of intraoperative ECLS was reported in patients suffering from severe tracheal stenosis of various etiologies (n=23) (8,11,13,14,30,42,43). Of those, only three were operated on under V-A ECMO support, all via peripheral cannulas (13%), whereas the other patients underwent surgery with V-V ECMO support. Apart from tracheal resection (85%), one patient had a tracheoplasty (14), another had a carinal resection (4), and in another case, ECLS was solely used to surgically place a tracheostomy to secure the airway in a severe case of tracheal stenosis (4).

Airway injuries

Emergency ECLS cannulation has been rarely reported in the acute loss of a secured airway or after the inability to ventilate a patient with an airway injury (25). With timely repair being crucial in some cases to avoid further injury (either by the misplaced ET tube or mechanical ventilation), ECLS support may be required, allowing for long apneic phases. The causes of injury can be iatrogenic (during intubation, tracheostomy) or traumatic (both blunt or penetrating). The extent and localization of the planned repair and the patient's hemodynamic stability determine the need for ECLS. In a single case, surgical repair of a spontaneous tracheal rupture after long time steroid use has been reported (27). Out of 13 reports on surgical airway repair with ECLS support, most cases (n=11) were limited to a suture of the membranous portion of the trachea (9,22,25,27), whereas the two other patients had a traumatic bronchial rupture (22). Peripheral V-A ECMO was used in 3 cases where circulatory support was needed (22), whereas the other cases were performed with V-V ECMO support.

Congenital disease

The standard surgical treatment of congenital tracheal stenosis is slide tracheoplasty. It is usually performed at a young age as affected children can be highly symptomatic. Although the use of tracheal homografts has been published previously, no more recent report exists on this approach (44). In less severe cases of congenital

stenosis, the defect can sometimes be fully resected without requiring extensive tracheal reconstruction to increase the tracheal diameter. Because of the tiny size of pediatric airways, adequate ventilation throughout those procedures may be very challenging, and those cases have been initially performed via a sternotomy and with CPB support. In more recent reports (N=24), intraoperative ECMO has increasingly been used, and central V-A is the most common mode (43%).

Planning considerations

In most cases of airway surgery, intraoperative oxygenation of the patient can safely be maintained with conventional methods (jet ventilation, cross table ventilation, unilateral intubation, intermittent apnea). Although the need for ECLS in airway surgery may be comparably small, it should be assessed in every case where complex reconstruction is needed or when airway patency might be lost. When there is a risk of total airway obstruction and subsequent anoxia during induction of anesthesia (45), ECLS should be initiated under local anesthesia. In these cases of awake initiation (24,46,47), the mode (peripheral V-A or V-V) should be chosen solely dependent on hemodynamic considerations (2,34,48,49). Nevertheless, in most reported cases, patients were stable before induction of anesthesia, and the airways could be secured to maintain ventilation. Cannulation and ECLS can then be safely initiated immediately before or even during the procedure if needed with the perfusion system on "standby" (17).

Emergency ECLS before airway surgery has been described in trauma cases and cases where tumor obstruction led to desaturation and hemodynamic instability up to cardiopulmonary arrest (18,50). All of the most recently published cases of patients undergoing emergency airway surgery received V-A ECMO support because of its inherent advantage of maintaining the hemodynamic stability of a patient.

Patient positioning and draping

If ECLS is initiated straightaway before surgical draping and skin incision, the cannulas should be inserted in a supine position as both the groin and the neck can be easily accessed by both sides. A slight Trendelenburg or anti-Trendelenburg maneuver increases venous filling and eases cannulation. The patient can then be moved to a lateral decubitus position with the cannulas in place to allow for

Table 2 The search strategy summary

Items	Specification
Date of search	September 1 st 2022
Databases searched	PubMed
Search terms used (including MeSH and free text search terms and filters)	((ECLS[Title/Abstract]) OR (ECMO[Title/Abstract]) OR (extracorporeal membrane oxygenation [Title/Abstract])) AND ((airway[Title/Abstract]) OR (trachea[Title/Abstract])) AND ((surgery[Title/Abstract]) OR (resection[Title/Abstract]) OR (repair[Title/Abstract]))
Timeframe	2015–9/2022
Inclusion and exclusion criteria	Inclusion: airway surgery with concomitant intraoperative ECLS support Exclusion: anatomical lung resections without bronchial sleeve anastomoses, wedge resections, lung transplantation, or bronchoscopic interventions
Selection process	Selection conducted by first and corresponding author

ECLS, extracorporeal life support.

lateral thoracotomy. If ECLS might become necessary during the procedure, it is recommended to have a set-up ECLS circuit readily available and to assess vascular diameter and patency in both the groin and the neck via ultrasound before positioning the patient. The patient can then be placed accordingly (with the hip rotated outwards in lateral decubitus), and the skin can be prepared to include the potential cannulation site into the surgical field. If possible, the central venous catheter used for anesthesia should be placed contralaterally to the incision site to not hinder ECLS cannulation. In patients where cannulation might be challenging, a guidewire or a venous sheath introducer can be placed and secured sterilely before skin incision. Cannulation can then be easily performed over those by the Seldinger wire technique if ECLS is needed.

Anticoagulation

Although short-term intraoperative ECMO use bears a comparably small risk of thromboembolic events attributable to the cannulas or the extracorporeal circulation, anticoagulation [target activated clotting time (ACT): 160–180 seconds] with unfractionated Heparin should be administered (2,20). Although some centers measure and readjust ACT regularly throughout the procedure, others rely on a single heparin administration at the time of cannulation. Newer heparin-coated tubings and oxygenators significantly reduce the risk of circuit thrombosis. With this in mind, aggressive anticoagulation might unnecessarily increase the surgical risk of bleeding, depending on the extent of the procedure.

Current practice

Although the historical experience of extensive airway surgery initially made use of CPB (51), this approach has been left. With technical advances in ECLS devices and growing surgical experience, V-A ECMO took over and was increasingly used as it showed significantly fewer associated perioperative risks. In published data (*Tables 1,2*), the heterogeneity of surgical indications, procedures, and, ultimately, the choice of ECLS makes it challenging to find evidence to define a gold standard (*Figures 1,2*). Nevertheless, an algorithm regarding the modality of ECLS and the preferred cannulation site has been previously derived from a multicentric national cohort analysis (n=36 patients) (6). Later reviews all support the same approach (2,22,52). Additionally, cumulative published cases appear to favor V-V ECMO over V-A ECMO over the last years (*Figure 3*), although this claim doesn't account for different surgical indications and any reporting bias.

Conclusions

Without a doubt, most cases of trachea-bronchial surgery can be performed without ECLS but with appropriate anesthesiologic management. With growing experience, ECLS became more widely used in the last decade and should now be considered an indispensable tool in the management of patients with challenging airway pathologies. Nevertheless, evidence regarding the optimal approach and the post-operative results remains low, and so far, only three case series reported on more than ten patients (5,6,20).

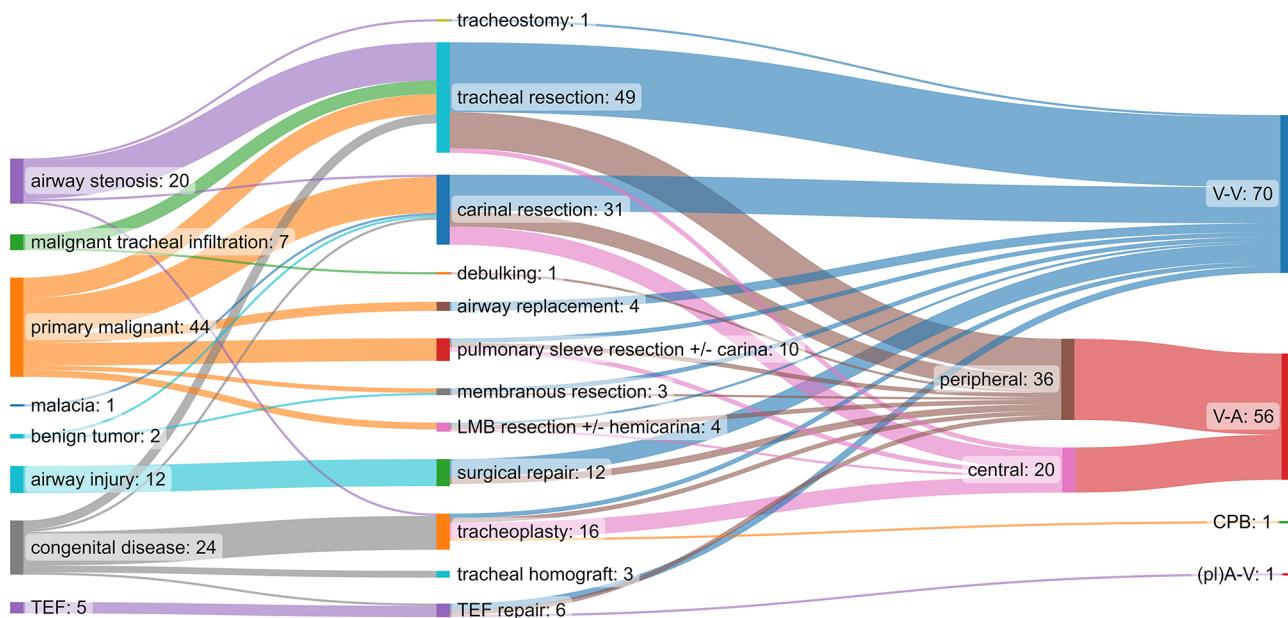


Figure 1 Flow diagram of surgical indication (left), the procedure performed (center), and the ECLS modality used in current literature from 1992–2022. Cases with missing information were omitted from the diagram. LMB, left main bronchus; TEF, trachea-esophageal fistula; V-V, veno-venous; V-A, veno-arterial; CPB, cardio-pulmonary bypass; pl, pumpless; A-V, arterio-venous; ECLS, extracorporeal life support.

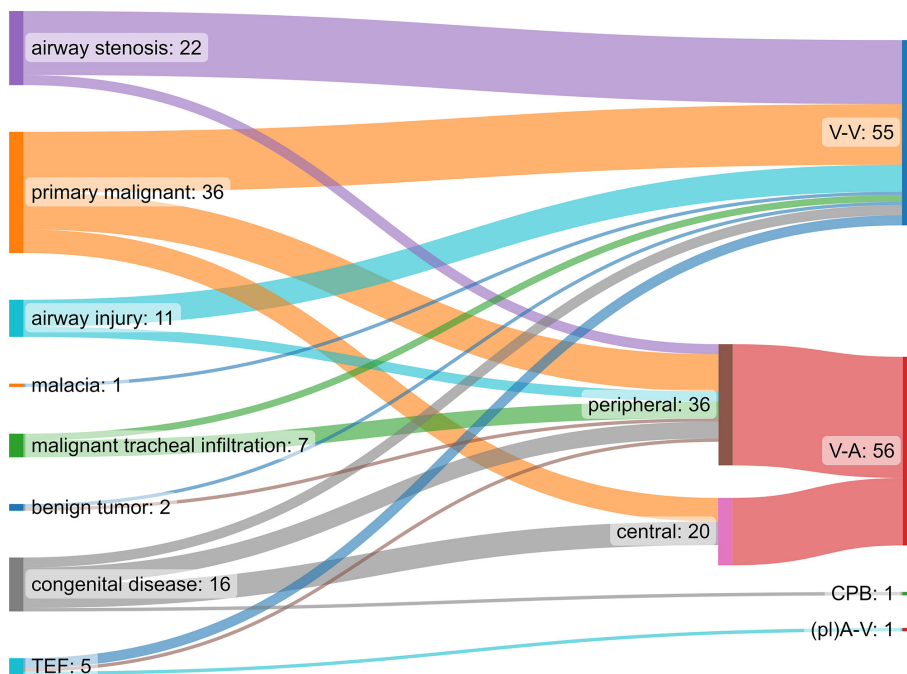


Figure 2 Flow diagram of operated pathologies (left) and the choice of ECLS used for surgical treatment (right) in published reports from 1992–2022; cases with insufficient data were omitted. TEF, trachea-esophageal fistula; pl, pumpless; V-V, veno-venous; V-A, veno-arterial; CPB, cardio-pulmonary bypass; A-V, arterio-venous; ECLS, extracorporeal life support.

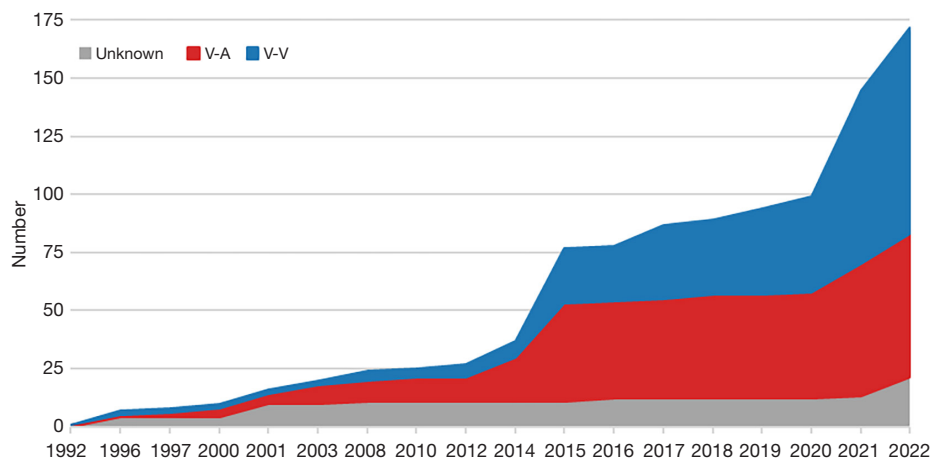


Figure 3 Cumulative cases of published ECLS use in airway surgery over the last 30 years according to the configuration; cases are counted in the year of publication. V-A, veno-arterial; V-V, veno-venous; ECLS, extracorporeal life support.

Acknowledgments

Funding: None.

Footnote

Provenance and Peer Review: This article was commissioned by the Guest Editor (Ilhan Inci) for the series “Extracorporeal Life Support in Thoracic Surgery” published in *Journal of Thoracic Disease*. The article has undergone external peer review.

Reporting Checklist: The authors have completed the Narrative Review reporting checklist. Available at <https://jtd.amegroups.com/article/view/10.21037/jtd-22-1483/rc>

Conflicts of Interest: All authors have completed the ICMJE uniform disclosure form (available at <https://jtd.amegroups.com/article/view/10.21037/jtd-22-1483/coif>). The series “Extracorporeal Life Support in Thoracic Surgery” was commissioned by the editorial office without any funding or sponsorship. The authors have no other conflicts of interest to declare.

Ethical Statement: The authors are accountable for all aspects of the work in ensuring that questions related to the accuracy or integrity of any part of the work are appropriately investigated and resolved.

Open Access Statement: This is an Open Access article distributed in accordance with the Creative Commons

Attribution-NonCommercial-NoDerivs 4.0 International License (CC BY-NC-ND 4.0), which permits the non-commercial replication and distribution of the article with the strict proviso that no changes or edits are made and the original work is properly cited (including links to both the formal publication through the relevant DOI and the license). See: <https://creativecommons.org/licenses/by-nc-nd/4.0/>.

References

1. Broman LM, Taccone FS, Lorusso R, et al. The ELSO Maastricht Treaty for ECLS Nomenclature: abbreviations for cannulation configuration in extracorporeal life support - a position paper of the Extracorporeal Life Support Organization. *Crit Care* 2019;23:36.
2. Hoetzenecker K, Klepetko W, Keshavjee S, et al. Extracorporeal support in airway surgery. *J Thorac Dis* 2017;9:2108-17.
3. Ius F, Tudorache I, Warnecke G. Extracorporeal support, during and after lung transplantation: the history of an idea. *J Thorac Dis* 2018;10:5131-48.
4. Kim CW, Kim DH, Son BS, et al. The Feasibility of Extracorporeal Membrane Oxygenation in the Variant Airway Problems. *Ann Thorac Cardiovasc Surg* 2015;21:517-22.
5. Lang G, Ghanim B, Hotzenecker K, et al. Extracorporeal membrane oxygenation support for complex tracheo-bronchial procedures. *Eur J Cardiothorac Surg* 2015;47:250-5; discussion 6.
6. Rinieri P, Peillon C, Bessou JP, et al. National review of

- use of extracorporeal membrane oxygenation as respiratory support in thoracic surgery excluding lung transplantation. *Eur J Cardiothorac Surg* 2015;47:87-94.
7. Yuba T, Yamashita Y, Harada H, et al. Tracheal Resection and Primary Anastomosis for Adenoid Cystic Carcinoma Using an Extracorporeal Membrane Oxygenation. *Kyobu Geka* 2016;69:447-51.
 8. Kim SH, Song S, Kim YD, et al. Outcomes of Extracorporeal Life Support During Surgery for the Critical Airway Stenosis. *ASAIO J* 2017;63:99-103.
 9. Antonacci F, De Tisi C, Donadoni I, et al. Venovenous ECMO during surgical repair of tracheal perforation: A case report. *Int J Surg Case Rep* 2018;42:64-6.
 10. Wannaz L, Roumy A, Letovanec I, et al. Non-circumferential membranous resection of the trachea for paraganglioma: A case report. *Int J Surg Case Rep* 2018;51:288-91.
 11. Madurka I, Elek J, Kocsis A, et al. Experiences with venovenous extracorporeal membrane oxygenation (ECMO) support for thoracic surgery in Hungary. Retrospective clinical study. *Orv Hetil* 2019;160:1655-62.
 12. Qiu Y, Chen Q, Wu W, et al. Extracorporeal membrane oxygenation (ECMO)-assisted intratracheal tumor resection and carina reconstruction: A safer and more effective technique for resection and reconstruction. *Thorac Cancer* 2019;10:1297-302.
 13. Rajab TK, Bedeir K, Taghavi FJ, et al. Combined Tracheal Resection and Coronary Artery Bypass With ECMO Support. *Ann Thorac Surg* 2019;108:e365-7.
 14. Pu H, Lei Y, Yuan D, et al. Tracheal Reconstruction Surgery Supported by Extracorporeal Membrane Oxygenation for Patients with Traumatic Post-Tracheotomy Tracheal Stenosis. *Ann Thorac Cardiovasc Surg* 2020;26:327-31.
 15. Yang H, Chen R, Chen J, et al. ECMO-assisted resection of left main bronchial malignant tumor and left pneumonectomy with comprehensive nursing support: a case report. *J Cardiothorac Surg* 2020;15:300.
 16. Alkhasov A, Razumovsky A, Gusev A, et al. Surgical Treatment of Patients with Full Tracheal Rings: Our Experience. *J Laparoendosc Adv Surg Tech A* 2021;31:1511-5.
 17. Al-Thani H, Ahmed K, Rizoli S, et al. Utility of extracorporeal membrane oxygenation (ECMO) in the management of traumatic tracheobronchial injuries: case series. *J Surg Case Rep* 2021;2021:rjab158.
 18. Chen L, Wang Z, Zhao H, et al. Venovenous extracorporeal membrane oxygenation-assisted tracheobronchial surgery: a retrospective analysis and literature review. *J Thorac Dis* 2021;13:6390-8.
 19. Ikeda Y, Saito Y, Kadomura T, et al. Extracorporeal membrane oxygenation for the anesthetic management of a patient with severe airway stenosis caused by thyroid carcinoma invasion. *Surg Today* 2021;51:2000-5.
 20. Kim DH, Park JM, Son J, et al. Multivariate Analysis of Risk Factor for Mortality and Feasibility of Extracorporeal Membrane Oxygenation in High-Risk Thoracic Surgery. *Ann Thorac Cardiovasc Surg* 2021;27:97-104.
 21. Liu X, Jiang R, Xiao J, et al. Anesthesia airway management for tracheal resection and reconstruction: a single-center case series. *Ann Palliat Med* 2021;10:3354-63.
 22. Zhang Y, Luo M, Wang B, et al. Perioperative, protective use of extracorporeal membrane oxygenation in complex thoracic surgery. *Perfusion* 2022;37:590-7.
 23. Bauer C, Jacquenod P, Fuchsmann C, et al. Extracorporeal lung support for tracheoesophageal fistula surgical repair with free flap. *Int J Oral Maxillofac Surg* 2022;51:883-5.
 24. Choi SR, Eom DW, Lee TY, et al. Anesthetic Management of Upper Tracheal Cancer Resection and Reconstruction: A Case Report. *Int Med Case Rep J* 2022;15:443-7.
 25. Evermann M, Roesner I, Denk-Linnert DM, et al. Cervical Repair of Iatrogenic Tracheobronchial Injury by Tracheal T-Incision. *Ann Thorac Surg* 2022;114:1863-70.
 26. He J, Xu X, Lan L, et al. End-to-side anastomosis in complex tracheal resection and reconstruction: a case series study. *Transl Lung Cancer Res* 2022;11:165-72.
 27. Koh YZ, Sewa DW, Soo IX. Impending spontaneous tracheal rupture due to steroid use. *SAGE Open Med Case Rep* 2022;10:2050313X221100875.
 28. Suzuki Y, Cass S, Lentz Carvalho J, et al. Extracorporeal Membrane Oxygenation for Patients With Thoracic Neoplasms: An Extracorporeal Life Support Organization (ELSO) Registry Analysis. *Ann Thorac Surg* 2022;114:1816-22.
 29. Todo M, Okuyama H, Saka R, et al. A case of successful slide tracheoplasty for long-segment congenital tracheal stenosis in a neonate with a congenital diaphragmatic hernia and Fallot's tetralogy. *Surg Case Rep* 2022;8:66.
 30. Venkataramani R, Lewis AE, Perez-Munoz I, et al. Management of refractory hypoxemia during elective extracorporeal support for complex tracheal resection. *Saudi J Anaesth* 2022;16:120-3.
 31. Voltolini L, Salvicchi A, Cianchi G, et al. Extracorporeal membrane oxygenation support in carinal resection for recurrent chondrosarcoma after previous distal

- tracheal resection. *Interact Cardiovasc Thorac Surg* 2022;35:ivac148.
32. Martinod E, Radu DM, Onorati I, et al. Airway replacement using stented aortic matrices: Long-term follow-up and results of the TRITON-01 study in 35 adult patients. *Am J Transplant* 2022;22:2961-70.
 33. Walles T, Steger V, Wurst H, et al. Pumpless extracorporeal gas exchange aiding central airway surgery. *J Thorac Cardiovasc Surg* 2008;136:1372-4.
 34. Ko M, dos Santos PR, Machuca TN, et al. Use of single-cannula venous-venous extracorporeal life support in the management of life-threatening airway obstruction. *Ann Thorac Surg* 2015;99:e63-5.
 35. Fuzaylov G, Cauley BD. Spontaneous ventilation via facemask and laryngeal mask airway as bridge to extracorporeal membrane oxygenation during long-segment tracheal stenosis repair. *Paediatr Anaesth* 2012;22:1226-8.
 36. Horita K, Itoh T, Furukawa K, et al. Carinal reconstruction under veno-venous bypass using a percutaneous cardiopulmonary bypass system. *Thorac Cardiovasc Surg* 1996;44:46-9.
 37. Keeyapaj W, Alfirevic A. Carinal resection using an airway exchange catheter-assisted venovenous ECMO technique. *Can J Anaesth* 2012;59:1075-6.
 38. Shiraishi T, Kawahara K, Shirakusa T, et al. Primary tracheal fibrosarcoma in a child: a case of tracheal resection under ECMO support. *Thorac Cardiovasc Surg* 1997;45:252-4.
 39. Lei J, Su K, Li XF, et al. ECMO-assisted carinal resection and reconstruction after left pneumonectomy. *J Cardiothorac Surg* 2010;5:89.
 40. Chang X, Zhang X, Li X, et al. Use of extracorporeal membrane oxygenation in tracheal surgery: a case series. *Perfusion* 2014;29:159-62.
 41. Liou JY, Chow LH, Chan KH, et al. Successful anesthetic management of a patient with thyroid carcinoma invading the trachea with tracheal obstruction, scheduled for total thyroidectomy. *J Chin Med Assoc* 2014;77:496-9.
 42. Walker LK, Wetzel RC, Haller JA Jr. Extracorporeal membrane oxygenation for perioperative support during congenital tracheal stenosis repair. *Anesth Analg* 1992;75:825-9.
 43. Connolly KM, McGuirt WF Jr. Elective extracorporeal membrane oxygenation: an improved perioperative technique in the treatment of tracheal obstruction. *Ann Otol Rhinol Laryngol* 2001;110:205-9.
 44. Goldman AP, Macrae DJ, Tasker RC, et al. Extracorporeal membrane oxygenation as a bridge to definitive tracheal surgery in children. *J Pediatr* 1996;128:386-8.
 45. Bittar D. Respiratory obstruction associated with induction of general anesthesia in a patient with mediastinal Hodgkin's disease. *Anesth Analg* 1975;54:399-403.
 46. Chakalov I, Harnisch LO, Meyer AC, et al. Preemptive veno-venous ECMO support in a patient with anticipated difficult airway: A case report. *Respir Med Case Rep* 2020;30:101130.
 47. Malpas G, Hung O, Gilchrist A, et al. The use of extracorporeal membrane oxygenation in the anticipated difficult airway: a case report and systematic review. *Can J Anaesth* 2018;65:685-97.
 48. Jensen V, Milne B, Salerno T. Femoral-femoral cardiopulmonary bypass prior to induction of anaesthesia in the management of upper airway obstruction. *Can Anaesth Soc J* 1983;30:270-2.
 49. Goyal A, Tyagi I, Tewari P, et al. Management of difficult airway in intratracheal tumor surgery. *BMC Ear Nose Throat Disord* 2005;5:4.
 50. Zhang X, Pan L, Wang L, et al. Intervention to severe lower trachea obstruction supported by extracorporeal membrane oxygenation in a human immunodeficiency virus patient: A case report and literature review. *Front Med (Lausanne)* 2022;9:965721.
 51. Louhimo I, Leijala M. Cardiopulmonary bypass in tracheal surgery in infants and small children. *Prog Pediatr Surg* 1987;21:58-63.
 52. Roskopfova P, Perentes JY, Ris HB, et al. Extracorporeal support for pulmonary resection: current indications and results. *World J Surg Oncol* 2016;14:25.

Cite this article as: Slama A, Stork T, Collaud S, Aigner C. Current use of extracorporeal life support in airway surgery: a narrative review. *J Thorac Dis* 2023;15(7):4101-4110. doi: 10.21037/jtd-22-1483