

Ocular histopathology of acrodermatitis enteropathica

J DOUGLAS CAMERON¹ AND CRAIG J McCLAIN²

*From the*¹*Department of Ophthalmology, University of Minnesota Medical School, Minneapolis, Minnesota 55455, and the*²*Department of Medicine, Gastroenterology Section, College of Medicine, University of Kentucky, Lexington, Kentucky 40536–0084, USA*

SUMMARY Acrodermatitis enteropathica is the clinical expression of congenital zinc deficiency and is now treated with supplemental zinc. This report details the ocular histopathology of a child who died before efficacious treatment was available. The findings include corneal epithelial thinning and loss of polarity, anterior corneal scarring and loss of Bowman's membrane, cataract formation, ciliary body atrophy, retinal degeneration, RPE depigmentation, and optic atrophy.

Acrodermatitis enteropathica (AE) is a rare hereditary abnormality of zinc metabolism which usually presents early in infancy, often after weaning from breast milk. Untreated, the disease follows a fluctuating course characterised by bullous pustular dermatitis of the extremities and about the body orifices, chronic diarrhoea associated with malabsorption and failure to thrive, central nervous system abnormalities, and impaired immune function with frequent infections.^{1,2} The dermatitis frequently involves the lateral canthal area and lids as a vesico-bullous eruption evolving into a psoriasiform reaction. The cilia of the brow and lid margin may be lost following the onset of the dermatitis. Conjunctivitis frequently accompanies the dermatitis.^{3,4} Linear subepithelial corneal opacities are occasionally found during exacerbations of the dermatitis.⁵ Cataracts, optic atrophy, and punctal stenosis have also been reported in patients with acrodermatitis enteropathica.^{4,6}

Initially human breast milk and antibiotic therapy produced a modest improvement in this disease. In 1953 diiodohydroxyquinolone therapy was accidentally found to be efficacious. The mechanism of action of the drug was not known at the time, but it has recently been shown that the drug augments intestinal zinc absorption. In 1973 Moynahan and Barnes⁷ recognised zinc deficiency as the basic defect in the disease process and successfully reversed all the clinical signs and symptoms with supplemental zinc sulphate alone. Oral zinc supplementation is the current mode of therapy.

The case described here was discovered during a

larger study of the ocular effects from all causes of zinc deficiency. The case was managed entirely between 1965 and 1971, four years before the discovery of the basic defect and effective treatment of AE. The disease was ultimately fatal in this case. Both eyes were obtained at necropsy for histological study. Except for a report of a corneal biopsy,⁵ there have been no previous reports of the ocular histology in this disease.

Case report

This male child was an 8 pound 9 ounce (3884 g) product of an uncomplicated, full term pregnancy. He was in good health until age 1 month when he developed a blistering skin rash on his cheeks. The rash spread to involve the skin around the eyes, nose, and mouth. By the end of two months skin lesions were also noted on the abdomen and extremities. At 3 months he developed diarrhoea and failure to thrive. A skin biopsy at that time showed parakeratosis typical of acrodermatitis enteropathica (Fig. 1). The association between zinc deficiency and AE had not been made at that time (1965), so the patient was treated over the next six years with intermittent courses of broad spectrum antibiotics, breast milk, and diodoquin. He partially responded to these modes of therapy but nevertheless developed total alopecia, intermittent acrodermatitis, and intermittent diarrhoea with suboptimal weight gain. Spasticity attributed to central nervous system involvement by the AE had developed by 8 months of age. The child suffered several episodes of cardiopulmonary arrest at 11 months. Because of lack of co-ordination of his vocal cords, a tracheostomy was required, which

Correspondence to J Douglas Cameron, Department of Ophthalmology, Hennepin County Medical Center, 701 Park Avenue South, Minneapolis, Minnesota 55415, USA.

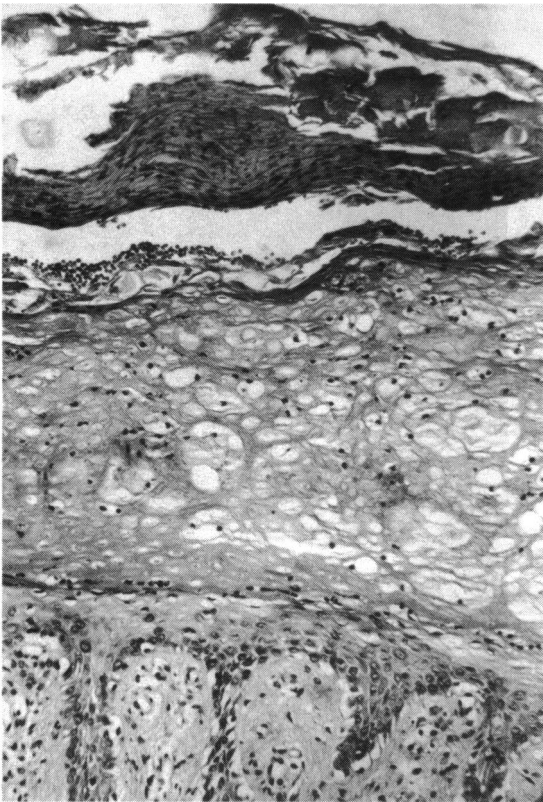


Fig. 1 Skin biopsy showing hyperkeratosis, parakeratosis, and acanthosis. (Haematoxylin and eosin, $\times 16$).

remained in place for one year. By age 18 months the child developed searching nystagmus associated with bilateral optic atrophy and slight attenuation of retinal vessels as well as signs of psychomotor retardation. Bilateral keratoconjunctivitis was noted, and this recurred concomitantly with the skin rash during the subsequent years. A second skin biopsy performed at age 3 again showed parakeratosis typical for AE. While the child was in hospital at age 4 for an episode of severe skin rash and diarrhoea, bilateral gross anterior corneal opacities were seen which had completely resolved by the time he was re-examined at age five. Bilateral severe blepharconjunctivitis and bilateral anterior corneal vascularisation had developed by the time of his final ocular examination at age 7.

The patient's entire course was complicated by frequent infections including otitis media, urinary tract infections, and skin infections. He died in 1971 (age 7) because of Gram-negative bacterial sepsis presumed to have originated in the perianal area. A necropsy was performed. Pertinent findings at post-mortem examination were the skin lesions typical

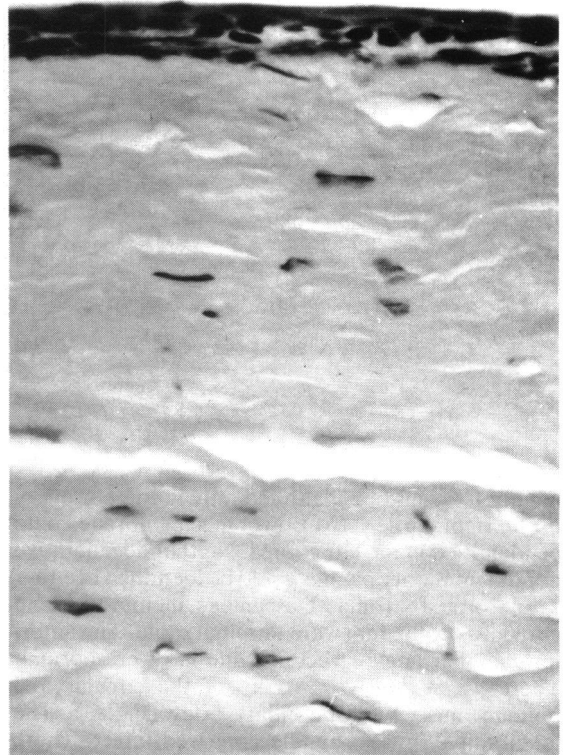


Fig. 2 Section of the cornea showing epithelial thinning and loss of polarity as well as anterior stromal scarring and loss of Bowman's membrane. (Haematoxylin and eosin, $\times 31$).

of acrodermatitis enteropathica, absence of thymic tissue, marked degeneration of the optic nerves, chiasm, and optic tracts and extensive cerebellar degeneration. Both eyes were removed for histological examination.

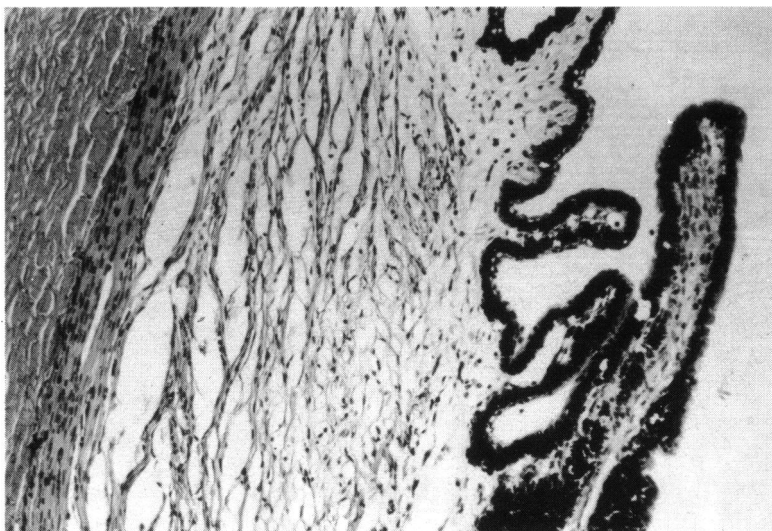
PATHOLOGY OF EYES

The right and left eyes were similar in appearance. They each measured $18 \times 18 \times 18$ mm with the optic nerve cut flush to the globe. The corneas were translucent and the optic discs were pale. The remaining structures of both globes appeared normal. Both globes were processed for paraffin embedding.

New sections were cut from the existing paraffin blocks and original sections containing the optic disc were restained.

Both eyes had a similar microscopic appearance. The corneal epithelium was reduced in thickness to one to three cell layers of flattened squamous epithelial cells over the entire surface of the cornea (Fig. 2). All polarity of the epithelium was lost. Bowman's

Fig. 3 Section of the ciliary body showing extensive loss of the circular and oblique muscle fibres. (Haematoxylin and eosin, $\times 6.2$).



membrane could be identified only in the periphery of the right cornea. No Bowman's membrane could be identified in the left cornea. Neither degenerative nor inflammatory pannus could be identified in either eye. Corneal stroma, Descemet's membrane, and corneal endothelium were unremarkable. The anterior chamber angle structures and iris were normal. There was extensive atrophy of the circular and oblique muscles of the ciliary body (Fig. 3). The longitudinal muscle bundle appeared intact. There was some posterior migration of lens capsular epithelium and early cortical degenerative changes (Fig. 4). The choroid was normal and the choriocapillaris was well preserved.

There appeared to be extensive degeneration of the retinal pigment epithelium throughout the posterior pole (Fig. 5), with relatively normal appearing pigment density in the periphery (Fig. 6). The retina was attached and showed mild autolytic changes throughout. There was some preservation of rod and cone outer segments in the posterior pole; however, these structures were completely lost anterior to the equator. There was extensive loss of the ganglion cell and nerve fibre layers of both eyes, and nearly complete atrophy of the disc and adjacent optic nerve (Fig. 7). There did not appear to be any extensive posterior bowing of the lamina cribrosa of the left eye. The central area of the optic nerve of the right eye was not represented in the sections available. The sclera was of normal calibre throughout.

Discussion

Zinc is an essential trace element which is necessary for RNA and DNA synthesis and the function of a



Fig. 4 Section of the lens showing early posterior migration of the lens epithelium and early cortical degenerative changes. (Periodic acid-Schiff, $\times 17$).

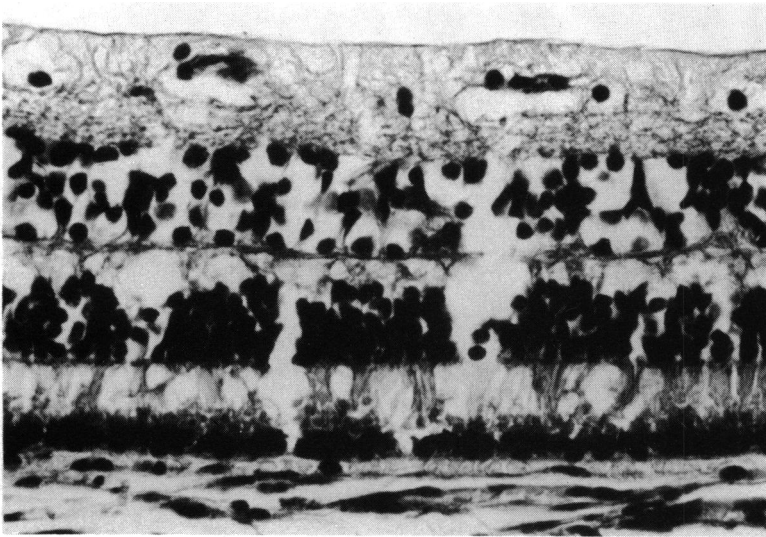


Fig. 5 Section of the posterior retina showing atrophy of the inner and outer retinal layers associated with a decreased density of the retinal pigment epithelium and preservation of the choriocapillaris. (Haematoxylin and eosin, $\times 25$).

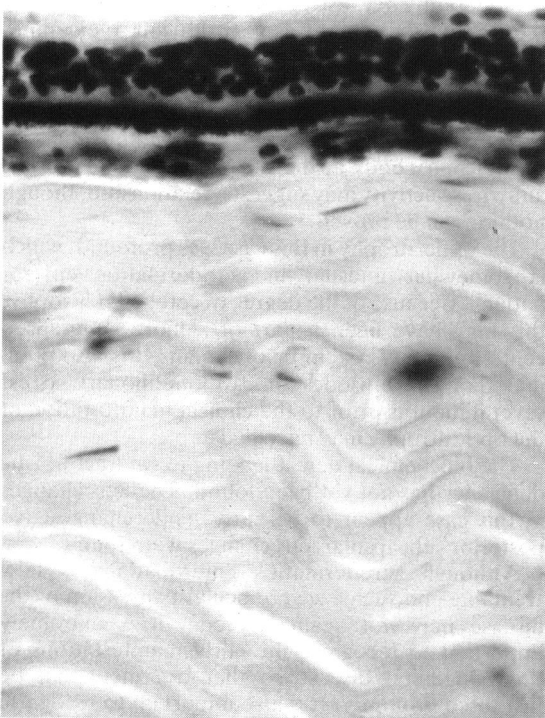


Fig. 6 Section of the peripheral retina showing severe atrophy of the neurosensory retina but near normal neuroectodermal pigment density of the retinal pigment epithelium. (Haematoxylin and eosin, $\times 31$).

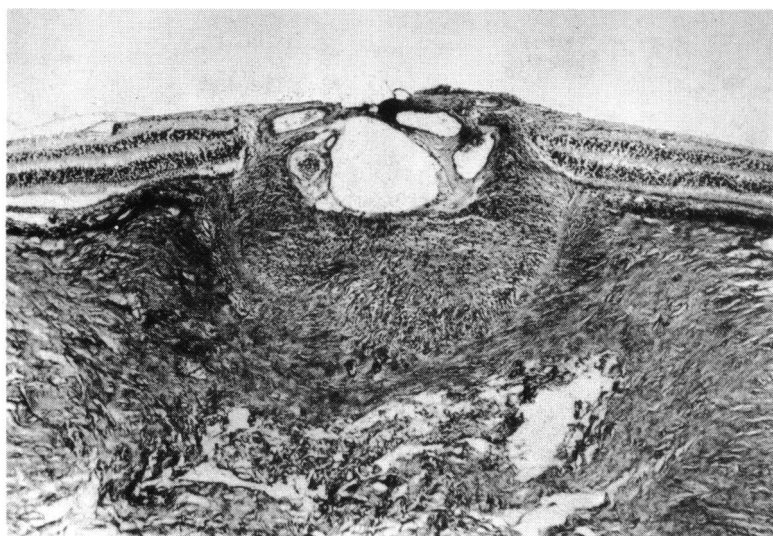
variety of zinc metalloenzymes.⁸ Much of the knowledge of the metabolic role of zinc has been derived from the manifestations of zinc deficiency such as acrodermatitis type skin lesions, diarrhoea with malabsorption, growth retardation, hypogonadism, anorexia with abnormalities of taste and smell, impaired wound healing, alterations in vitamin A metabolism and retinal dysfunction, impaired immune function, and teratogenesis.⁹⁻¹⁷ A variety of processes or disease states have now been identified in which zinc deficiency may occur, including alcoholism with or without liver disease, regional enteritis, sprue, short bowel syndrome, sickle cell anaemia, certain types of cancer, pregnancy, total parenteral nutrition (TPN), as well as the congenital form, acrodermatitis enteropathica.^{7 11 18-22}

The onset of the case presented here was characterised by the dermatitis of zinc deficiency. One aetiological factor for the dermatitis appears to be a marked alteration of amino acid metabolism, which is essential in cell renewal and repair processes of the integument.²³ The distribution of the skin lesions has not been explained. It has been suggested that persistent mechanical or chemical trauma to the areas of involvement may be partially responsible.²⁴ If this is true, the repeated chemical trauma of increased tear production associated with non-specific conjunctivitis may lead to the acrodermatitis of the lateral canthal area.

The child then developed severe diarrhoea and later developed manifestations of severe psychomotor retardation. The exact mechanism of these expressions of the disease has not yet been adequately explained.

Impaired cellular immunity and thymic atrophy

Fig. 7 Section of the peripheral optic disc showing extensive atrophy. (Haematoxylin and eosin, $\times 1.5$).



have been found in both experimental animals and humans with zinc deficiency.¹⁶ These findings may help to explain the child's frequent infections of the skin, middle ear, and urinary tract throughout his life.

Some of the highest concentrations of zinc in the body are found in the ocular tissues, yet the exact role of zinc in the eye is as yet ill defined.²⁵ The high turnover rate of the cells of the corneal epithelium appears to place them at the same risk of abnormality as the skin epithelium at the mucocutaneous junction and acral areas. The structural expression of this appears to be the thinning and loss of polarity seen in the corneal epithelium. The repeated trauma associated with the conjunctivitis and blepharitis of the disease to this already compromised epithelium probably explains the loss of Bowman's membrane and subsequent anterior corneal scarring. The transient corneal opacity seen clinically during severe exacerbation was most likely a gross manifestation of the scarring process which subsequently healed to a point where it was no longer clinically apparent.

Two metalloenzymes which are essential to ocular function are zinc dependent. They are alcohol dehydrogenase, which is active in converting retinol, the circulating form of vitamin A, to retinal, the form necessary for rhodopsin production, and carbonic anhydrase, which functions in aqueous production.⁸

Abnormalities in retinal function in humans, specifically impairment of dark adaptation, have been reported during episodes of zinc deficiency.^{18,19} Structural abnormalities in zinc deficient rats included a degeneration of the retinal pigment epithelium and disorganisation of the photoreceptor outer segments.^{26,27} In this case, although some auto-

lysis was present, there was evidence of depigmentation of the retinal pigment epithelium posteriorly and a loss of photoreceptor outer segments out of proportion to the degree of autolysis present.

Apparently because of the degree of psychomotor retardation, this child was very difficult to examine, and the intraocular pressure was never recorded. There was no clinical or histological evidence of increased or decreased intraocular pressure. The extreme atrophy of the circular and oblique muscles of the ciliary body at the site of presumed carbonic anhydrase activity may suggest a relationship, though nothing can be proved.

The optic atrophy in this case was profound, which is somewhat unusual in acrodermatitis enteropathica. Because of the degree of cerebellar atrophy, this may have been a part of a more generalised central nervous system involvement. It is also possible that the episodes of cardiopulmonary arrest several months prior to the clinical manifestation of the optic atrophy may have had a role.

The biochemical defect leading to cataract in zinc deficiency has not yet been found. The lens changes in this case appear to be early senile changes. No posterior subcapsular lens changes were found.

Although acrodermatitis enteropathica is now treatable and such a severe ocular expression of the disease may not again be seen, it is extremely important to recognise the early manifestations of this congenital disease so that treatment can be instituted promptly. It is also important to recognise that the ocular manifestations of zinc deficiency seen in acrodermatitis enteropathica may arise in many other, more common, diseases complicated by zinc deficiency.

This study was supported in part by grants from The Minnesota Lions Club and Research to Prevent Blindness (JDC) and the Veterans Administration and from the Office of Alcohol and Other Drug Abuse Programming of the State of Minnesota (CJMcC).

References

- 1 Weismann K, Wadskov S. Acrodermatitis enteropathica—hereditary zinc deficiency. *Nutr Rev* 1975; **33**: 327.
- 2 Sunderman FW. Current status of zinc deficiency in the pathogenesis of neurological, dermatological and musculoskeletal disorders. *Ann Clin Lab Sci* 1975; **5**: 132–145.
- 3 Wirsching L. Eye symptoms in acrodermatitis enteropathica. *Acta Ophthalmol (Kbh)* 1962; **40**: 567–74.
- 4 Matta CS, Felker GV, Ide CH. Eye manifestations in acrodermatitis enteropathica. *Arch Ophthalmol* 1975; **93**: 140–2.
- 5 Warshawsky RS, Hill CW, Doughman DJ, Harris JE. Acrodermatitis enteropathica. Corneal involvement with histochemical and electron micrographic studies. *Arch Ophthalmol* 1975; **93**: 194–7.
- 6 Racz P, Kovacs B, Varga L, Vjlaki E, Zombai E, Karbuczky S. Bilateral cataract in acrodermatitis enteropathica. *J Pediatr Ophthalmol Strabismus* 1979; **16**: 180–2.
- 7 Moynahan EJ, Barnes PM. Zinc deficiency and a synthetic diet for lactose intolerance. *Lancet* 1973; **i**: 676–7.
- 8 Subcommittee on Medical and Biological Effects of Environment Pollutants. Division of Medical Sciences, Assembly of Life Sciences, National Research Council. *Zinc*. Baltimore: Maryland University Park Press, 1979.
- 9 Sandstead HH. Trace elements in medical practice: zinc. *Pract Gastroenterol* 1978; **2**: 27–38.
- 10 McClain CJ, Soutor C, Stelle N, Levine AS, Silvis SE. Severe zinc deficiency presenting as acrodermatitis during hyperalimentation: diagnosis, pathogenesis and treatment. *J Clin Gastroenterol* 1980; **2**: 125–31.
- 11 Latimer JS, McClain CJ, Sharp HL. Clinical zinc deficiency during zinc-supplemental parenteral nutrition. *J Paediatr* 1980; **97**: 434–7.
- 12 Bates J, McClain CJ. The effect of severe zinc deficiency on serum levels of albumin, transferrin, and prealbumin in man. *Am J Clin Nutr* 1981; **34**: 1655–60.
- 13 Lei KY, Abbasi A, Prasad AS. Function of pituitary-gonadal axis in zinc deficient rats. *Am J Physiol* 1976; **230**: 1730–2.
- 14 Henkin RI, Schechter PJ, Hoye R, Mattern C. Ideopathic hypogensia with dysgeusia, hyposmia and dysosmia. A new syndrome. *JAMA* 1971; **217**: 434–40.
- 15 Solomons NW, Russell RM. The interaction of vitamin A and zinc: implications for human nutrition. *Am J Clin Nutr* 1980; **33**: 2031–40.
- 16 Allen JI, Kay NE, McClain CJ. Severe zinc deficiency in humans: association with a reversible T-lymphocyte dysfunction. *Ann Intern Med* 1981; **95**: 154–7.
- 17 Warkany J, Petering HG. Congenital malformations of the central nervous system in rats produced by maternal zinc deficiency. *Teratology* 1972; **5**: 319–34.
- 18 McClain CJ, Van Thiel DH, Parker S, Badzin LK, Gilbert H. Alterations in zinc, vitamin A and retinol-binding protein in chronic alcoholics: a possible mechanism for night blindness and hypogonadism. *Alcoholism* 1979; **3**: 135–41.
- 19 Morrison SA, Russell RM, Carney EA, Oaks EV. Zinc deficiency: a cause of abnormal dark adaptation in cirrhotics. *Am J Clin Nutr* 1978; **31**: 276–81.
- 20 McClain C, Soutar C, Zieve L. Zinc deficiency: a complication of Crohn's disease. *Gastroenterology* 1980; **78**: 272–9.
- 21 Abbasi AA, Prasad AS, Ortega J, Congco E, Oberleas D. Gonadal function abnormalities in sickle cell anemia. Studies in adult male patients. *Ann Intern Med* 1976; **85**: 601–5.
- 22 McClain CJ. Trace metal abnormalities in adults during hyperalimentation. *J Parent Enterol Nutr* 1981; **5**: 424–9.
- 23 Hsu JM, Anthony WL, Buchanan PJ. Zinc deficiency and incorporation of ¹⁴C-labeled methionine into tissue proteins in rats. *J Nutr* 1969; **99**: 425–32.
- 24 Weismann K, Wadskov S, Mikkelsen HI, Knudsen L, Christensen KC, Storgaard L. Acquired zinc deficiency dermatosis in man. *Arch Dermatol* 1978; **114**: 1509–11.
- 25 Leopold IH. Zinc deficiency and visual impairment. *Am J Ophthalmol* 1978; **85**: 871–5.
- 26 Leure-duPree AE. Electron-opaque in rat retinal pigment epithelium after treatment with chelators of zinc. *Invest Ophthalmol Vis Sci* 1981; **21**: 1–9.
- 27 McClain CJ, Leure-duPree AE, Cameron JD. The effect of zinc deficiency on the function and morphology of the eye in rats and man. *J Clin Res* 1981; **29**: 703A.

Accepted for publication 13 December 1985.