

Arteriovenous communication of the iris

MAREK PROST

From the Ophthalmology Clinic, Medical Academy in Lublin, Poland

SUMMARY A case of arteriovenous communication of the iris in the left eye of a 45-year-old man is reported. The haemodynamic changes and differential diagnosis of this kind of communication are briefly discussed.

Haemangiomas of the iris are extremely rare.¹⁻⁴ They are usually capillary^{1,3,5,6} or cavernous haemangiomas^{1,7,8} but so-called racemose haemangiomas are observed very rarely.⁹ This lesion is not a true tumour but a vascular anomaly. It consists of abnormal, direct, bypassing capillary bed communications between more or less fully developed, dilated, and tortuous arteries and veins.^{10,11} Some authors have therefore recently suggested that the term racemose haemangioma or racemose aneurysm should be replaced by arteriovenous communications¹² or arteriovenous anastomoses.¹¹

It seems that arteriovenous communications are a congenital anomaly.¹¹ Their pathogenesis is unknown, but they probably arise from a local defect in the maturation of the primitive mesenchymal cells. In the early stages of development of the vascular system, for example in the retina, primitive mesenchymal cells differentiate into solid cords of endothelial cells which gradually become canalised to form a primitive capillary network.¹³ As blood enters this network, the primitive vessels develop into arteries, veins, and connecting capillaries, with the simultaneous retraction and atrophy of some primitive capillaries.¹³ In arteriovenous communications extensive capillary retraction and atrophy may occur, with development of a single channel to shunt blood across this defective capillary zone.¹²

Because of their slow development, arteriovenous communications are usually encountered for the first time in the second or third decade of life.^{9,11} Lesions occur mainly in the retina,^{4,11,12} and less frequently in the orbit, conjunctiva, and sclera.^{4,14-17} There are very few reports of arteriovenous communications in the iris.⁹ In view of the rarity of this lesion the case described here was considered worth reporting.

Case report

A 45-year-old man was admitted to this clinic because of a vascular anomaly of the left iris. The patient said he had noticed red spots on the iris about 15 years before. As he had no disturbance of vision, he did not consult an ophthalmologist.

Ocular examination showed: in the right eye, visual acuity 1.0, IOP 15 mmHg, anterior segment and fundus normal, visual field normal; in the left eye, visual acuity 1.0, IOP 15 mmHg. A dilated episcleral vessel coursing towards the corneal limbus was seen at 2 o'clock (Fig. 1). It entered the sclera at 3 o'clock

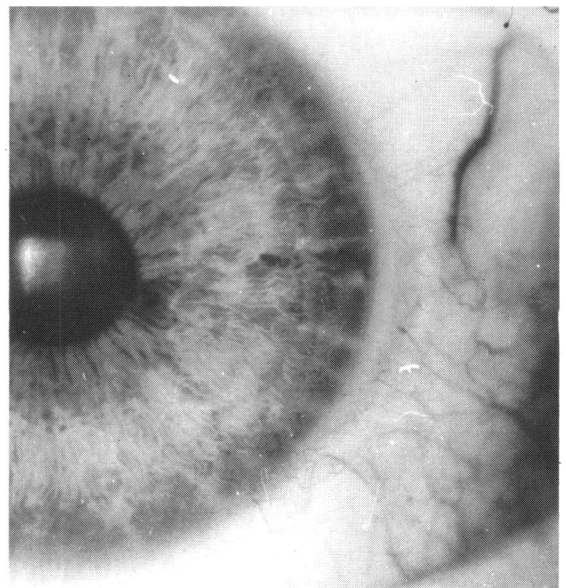


Fig. 1 Appearance of sclera and iris with arteriovenous communication.

Correspondence to Marek Prost, MD, Ophthalmology Clinic, Chmielna 1, 20-079 Lublin, Poland.

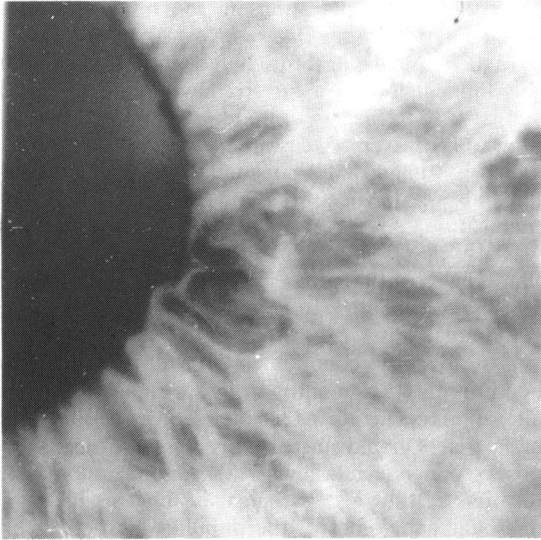


Fig. 2 Conglomerate of convoluted vessels at the pupillary border.

1 mm from the limbus. The dilated vessel could be seen subsequently gonioscopically in the anterior chamber angle, and it entered the surface layers of the iris stroma. After entering the angle the vessel became wider and more tortuous as compared with its episcleral segment. It then coursed towards the pupillary border of the iris, where it formed a conglomerate of greatly dilated and tortuous vessels (Fig. 2). Above this vessel another one slightly less dilated and tortuous could be seen. From the conglomerate of vessels at the pupillary border of the iris a dilated and tortuous vessel emerged, the course of which was only partially seen because it penetrated

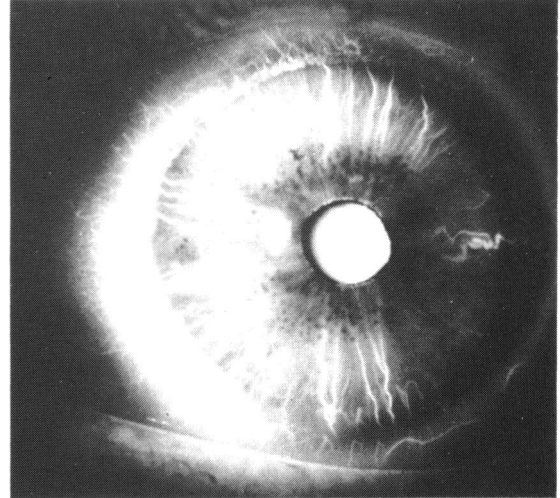


Fig. 3 A

Figs. 3 ABC Fluorescein angiography of arteriovenous communication of the iris. Note sequence of filling of communication with fluorescein and small blurring (Leakage?) of vessels at the pupillary border.

deeper into the iris stroma. This vessel disappeared within the anterior chamber angle and reappeared as a dilated episcleral vessel in the corneal limbus. No other ocular changes were found besides those described within the anterior segment. The visual field was normal.

Fluorescein angiography of the iris enabled us to delineate accurately the course of the altered vessels and to determine the afferent and efferent part of the communication (Figs. 3A, B, C). The dilated and tortuous iris vessel at 3 o'clock was the first to fill.

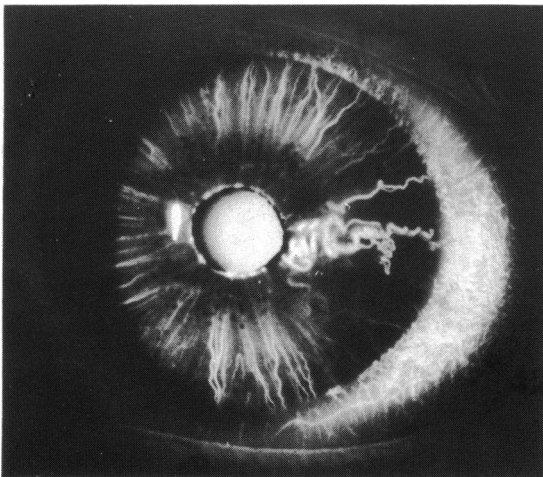


Fig. 3 B

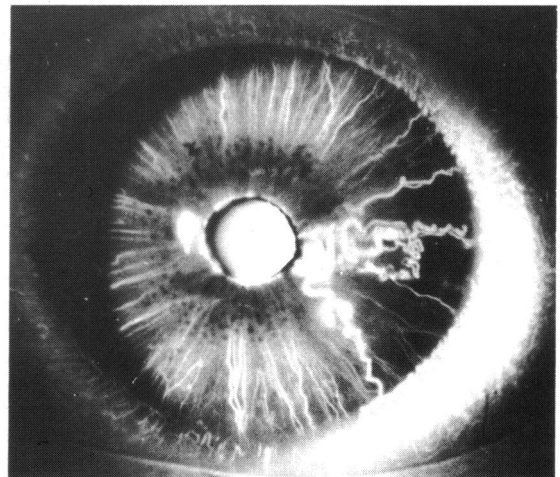


Fig. 3 C

This vessel then divided into several branches which in their course formed a conglomerate of greatly dilated and tortuous vessels. They were seen not only in the peripupillary part of the iris but also in its medial part, which could not be seen in the slit-lamp. At 2 o'clock a slightly dilated vessel was observed which filled with fluorescein slightly later than the vessel at 3 o'clock. From the vessel conglomerate at the iris margin a dilated vessel emerged which coursed towards the corneal limbus at 5 o'clock. In the part of the iris in which the anomaly occurred the vessels filled later than in the other parts. Moreover in that part fewer vessels were shown up by fluorescein even in the late phases of the examination. During the examination a small leakage of dye from the vessels forming the arteriovenous communication could be observed. However, this leakage may have been at least in part an artefact owing to the vessels of the iris being slightly out of focus in the camera. Such artefacts have been reported.¹⁸ Fluorescein angiography of the left fundus was normal.

When the intraocular pressure was increased by means of the ophthalmodynamometer, pulsation of the arteriovenous communication as well as of the afferent and efferent vessels could be observed at a pressure above 90 mmHg.

Neurological examination did not show any alterations indicating changes in the central nervous system. The patient was therefore not considered suitable for carotid angiography.

Discussion

The lesion found in this patient corresponds to the arteriovenous communications usually observed within the retina.^{11,12} As in the retina, dilated afferent and efferent vessels, which had already been noted in the episclera, as well as a mass of convoluted channels between them could also be distinguished here. The appearance of this vascular disorder, as well as the fact that pulsation of the afferent and efferent vessels occurred almost at the same level as the raised intraocular pressure, indicates that this arteriovenous communication can be included in group 2 of the classification of Archer *et al.*¹² The angiographic evidence of slight leakage of fluid from the vessels involved as well as of reduced perfusion of the iris in the sector where the lesion lay, pointed to the existence of some, though not intense, decompensation of the arteriovenous communication. It accounts also for the fact that this communication can be included in group 2 of Archer *et al.*¹² Because of the small number of reported cases of arteriovenous communications in the iris it is of course difficult to say whether the division into three groups introduced

for pathological alterations in the retina will also apply to lesions in the iris.

In the available literature only a few descriptions of this kind of lesion in the iris have been found. A similar case to that presented here was described by Stur and Strasser.⁹ A case presented by Ida Mann¹⁹ which was diagnosed as congenital angioma of the iris may also have been one of arteriovenous communication. A case of vascular anomaly of the iris was also described by Savir and Manor,²⁰ but, since that abnormality did not have afferent and efferent vessels, it cannot be regarded as an arteriovenous communication.

Arteriovenous communications of the iris need to be differentiated mainly from secondary vascular alterations occurring in the course of various diseases of the iris.²¹ Dilated and tortuous vessels of the iris are observed in association with cysts and melanomas of the iris.²¹ Other lesions, such as rubeosis iridis or microhaemangiomas of the pupillary border^{22,23} can be easily distinguished from arteriovenous communications.

Owing to the asymptomatic course of the disease in the patient reported on here no treatment was applied. If complications arise, such as spontaneous hyphaema, the possibility of performing photocoagulation can be considered.

References

- 1 Ashton N. Primary tumours of the iris. *Br J Ophthalmol* 1964; **48**: 650-68.
- 2 Ferry AP. Hemangioma of the iris and ciliary body: do they exist? *Int Ophthalmol Clin* 1972; **12**: 177-94.
- 3 Goder G, Lommatsch P, Noor MS. Differentialdiagnostische Probleme bei Tumoren der vorderen Uvea. *Klin Monatsbl Augenheilkd* 1975; **166**: 340-53.
- 4 Reese AB. *Tumors of the eye*. 2nd ed. New York: Harper and Row, 1963: 364-431.
- 5 Amasio E, Brovarone FV, Musso M. Angioma of the iris. *Ophthalmologica* 1980; **180**: 15-8.
- 6 Cashell GTW. Angioma of the iris. *Br J Ophthalmol* 1967; **51**: 633-5.
- 7 Magrane WG. Cavernous hemangioma of the iris. *North Am Veterinarian* 1954; **35**: 516-9.
- 8 Naidoff MA, Kenyon KR, Green WR. Iris hemangioma and abnormal retinal vasculature in a case of diffuse congenital hemangiomatosis. *Am J Ophthalmol* 1971; **72**: 633-44.
- 9 Stur M, Strasser G. Sektorförmige Gefäßmissbildung der Iris vom razemösen Typ. *Klin Monatsbl Augenheilkd* 1983; **183**: 50-2.
- 10 Apple DJ, Rabb MF. *Clinicopathologic correlation of ocular disease*. St Louis: Mosby, 1978: 408.
- 11 Baurmann H, Meyer F, Oberhoff P. Komplikationen bei der arteriovenösen Anastomose der Netzhaut. *Klin Monatsbl Augenheilkd* 1968; **153**: 562-71.
- 12 Archer DB, Deutman A, Ernst JT, Krill AE. Arteriovenous communications of the retina. *Am J Ophthalmol* 1973; **75**: 224-41.
- 13 Ashton N. Oxygen and the growth and development of retinal vessels. *Am J Ophthalmol* 1966; **62**: 412-35.
- 14 Duke-Elder S. *System of ophthalmology*. Diseases of the outer

- eye: conjunctiva, cornea and sclera. London: Kimpton, 1965; 8 (2): 1198–202.
- 15 Knobloch R. Hemangioma sclerae et corneae. *Cesk Oftalmol* 1951; 7: 336–9.
- 16 Meisenbach AE. Hemangioma of the orbit. *Am J Ophthalmol* 1940; 23: 286–9.
- 17 Redslob E. Cirsoïd aneurysm de la conjonctive bulbaire. *Bull Mem Soc Fr Ophthalmol* 1926; 39: 91–4.
- 18 Hayreh SS, Scott WE. Fluorescein iris angiography. I. Normal pattern. *Arch Ophthalmol* 1978; 96: 1383–9.
- 19 Mann I. *Developmental abnormalities of the eye*. London: British Medical Association, 1957.
- 20 Savir H, Manor RS. Spontaneous hyphema and vessel anomaly. *Arch Ophthalmol* 1975; 93: 1056–8.
- 21 Kottow M. Fluoreszenzangiographische Beurteilung von primären und sekundären Raumforderungen der Iris. Doctorate thesis. Bonn: Rheinischen Friedrich-Wilhelms-Universität, 1976.
- 22 Coleman SL, Green WR, Patz A. Vascular tufts of pupillary margin of iris. *Am J Ophthalmol* 1977; 83: 881–3.
- 23 Podolsky MM, Srinivasan BD. Spontaneous hyphacma secondary to vascular tuft of pupillary margin of the iris. *Arch Ophthalmol* 1979; 97: 301–2.

Accepted for publication 11 February 1986.