

Primary vitreoretinal dysplasia resembling Norrie's disease in a female: association with X autosome chromosomal translocation

NORIO OHBA AND TOYOMI YAMASHITA

'From the Department of Ophthalmology, Kagoshima University Faculty of Medicine, Kagoshima-shi, Japan

SUMMARY A female infant with the typical clinical and histopathological features of vitreoretinal dysplasia is described. She had an apparently balanced reciprocal chromosomal translocation 46XX,t(X;10) with the X chromosome breakpoint being on the short arm. Since the parents' karyotypes were normal, it is most plausible that a *de novo* chromosomal translocation disrupted the vitreoretinal dysplasia gene itself. The severe clinical symptoms of this heterozygous female patient were explained by non-random X inactivation. She may have had Norrie's disease, an X linked recessive disorder due to an X autosome translocation.

Vitreoretinal dysplasia is induced by an arrest in the development of the vitreous and retina due to either genetic or environmental factors. Aetiologically heterogeneous diseases frequently present morphological similarities in their clinical and histopathological features. Congenital pseudoglioma, non-attachment of the retina, and falciform folds of the retina among others are terms used to describe the clinical picture, and the histopathological abnormalities, usually designated as retinal dysplasia, include the formation of rosettes in the dysplastic retina and proliferated primary vitreous.¹⁻⁴ The aetiology of the primary vitreoretinal dysplasia is genetically also heterogeneous. As regards the Mendelian mode of inheritance, autosomal recessive traits with or without systemic anomalies^{4,5} and the X-linked condition Norrie's disease^{6,7} are well documented. Chromosomal aberrations also induce typical vitreoretinal dysplasia as part of systemic syndromes. Trisomy 13 or Patau's syndrome is the commonest chromosomal disorder affecting the vitreous and retina, but other chromosomal syndromes include severe vitreoretinal dysplasia only exceptionally.⁸⁻¹⁰

We report the case of a girl who had the typical clinical and histopathological features of vitreoretinal dysplasia and in addition had an apparently

balanced X;10 chromosomal translocation. Neither parent had the translocation. The proposed interpretation of these data is that the translocation breakpoint involving the X chromosome disrupted the vitreoretinal dysplasia gene itself, implying that this sporadic case was indeed one of Norrie's disease due to a rare X autosome chromosomal translocation.

Case report

A Japanese female infant was born at full-term with a birth weight of 2402 g without any gestational illness or birth trauma. She appeared listless after the delivery, with absent neonatal reflexes, and had closure of the fontanelles, lack of deep tendon reflexes, and general hypotonia with intermittent twitches. The electroencephalogram showed a diffuse suppression of brain activity, though computerised tomography revealed no gross brain lesion. She had micrognathia, cleft lip, high-arched palate, and low-set earlobes, but had no visceral malformations.

Detailed ophthalmological examinations were first performed on the ninth postnatal day. There was no external anomaly, but marked malformations were found in the vitreous and retina, their degree being more severe in the left eye.

Right eye. The cornea was clear, 10×10 mm diameter. The pupil was round but reacted to light only sluggishly. The anterior chamber was clear and normal in depth. There were numerous persistent

Correspondence to Dr Norio Ohba, Department of Ophthalmology, Kagoshima University Faculty of Medicine, Usuki-cho 1208-1, Kagoshima-shi, Japan (890).

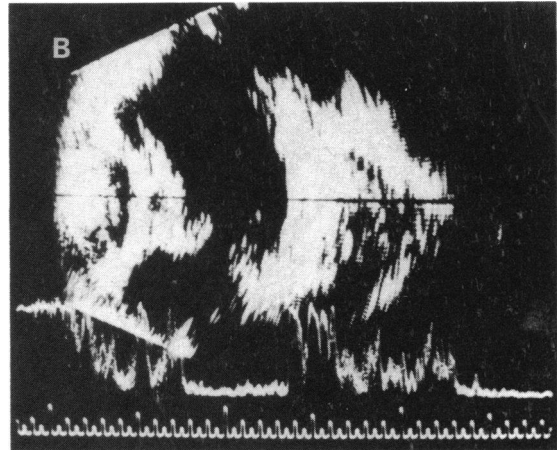
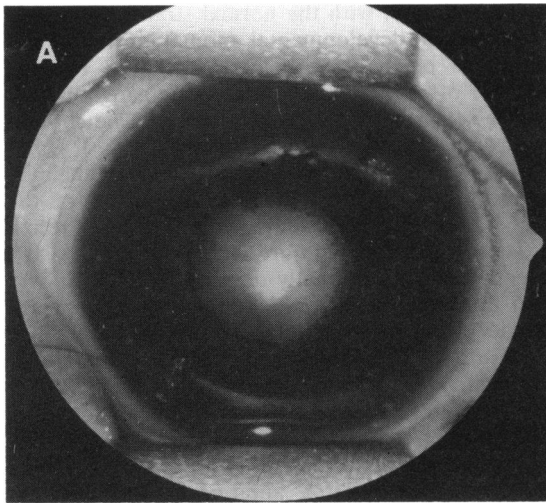


Fig. 1 (A) Retrolental vascularised mass. (B) Ultrasonographic demonstration of the retrolental opaque mass. Left eye.

pupillary membranes. The lens and vitreous were clear, making the eyeground visible. The optic disc appeared hypoplastic, with pale colour and deep cupping. The posterior eyeground was mottled with scarce, narrow retinal vessels. The macular region could not be identified. The peripheral eyeground appeared dull whitish.

Left eye. The eyeball was microphthalmic. The intraocular pressure was low in digital pressure, measuring 4 mmHg by Schiøtz tonometry. The cornea was clear, 8.5×8.0 mm in diameter. The pupil did not react to light and was dilated irregularly with mydriatics owing to posterior synechiae. The anterior chamber was shallow. The iris was partly atrophic, and numerous aberrant vessels of the iris extended radially on to the surface of the clear lens or towards the posterior chamber. Part of the ciliary processes was elongated. Just behind the clear lens a

yellowish-white vascularised mass filled the pupillary space of the anterior vitreous cavity, so that the fundus could not be visualised. Ultrasonography confirmed the microphthalmic eyeball and the presence of a retrolental opaque mass (Figs. 1A, B).

During the follow-up examinations no substantial change occurred in either eye, except that the anterior chamber of the left eye became shallower. The patient died at the age of 14 months from intractable pneumonia. The eyeballs were enucleated for medicolegal necropsy two hours after the death and examined with haematoxylin-eosin staining.

OCULAR HISTOPATHOLOGY

Right eye. This eye measured 22×20×20 mm. The cornea was entirely normal. The epithelial and stromal layers of the iris were normal, but the

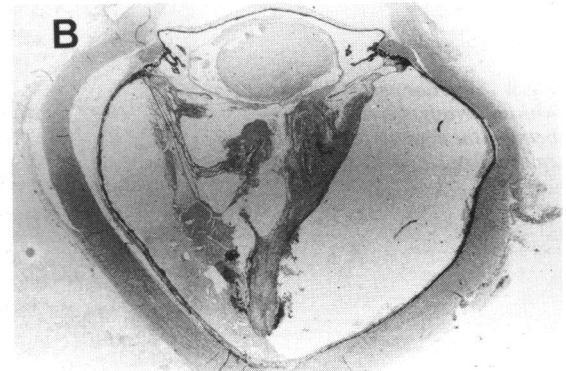
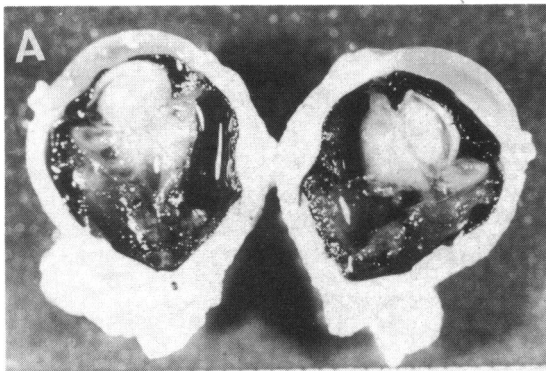


Fig. 2 (A) General appearance of the left eye. (B) Totally detached retina adherent to the retrolental fibrous tissue.

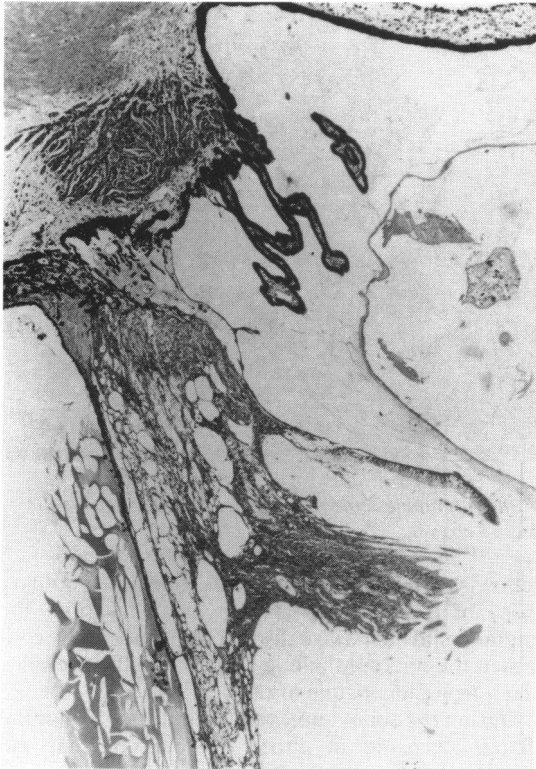

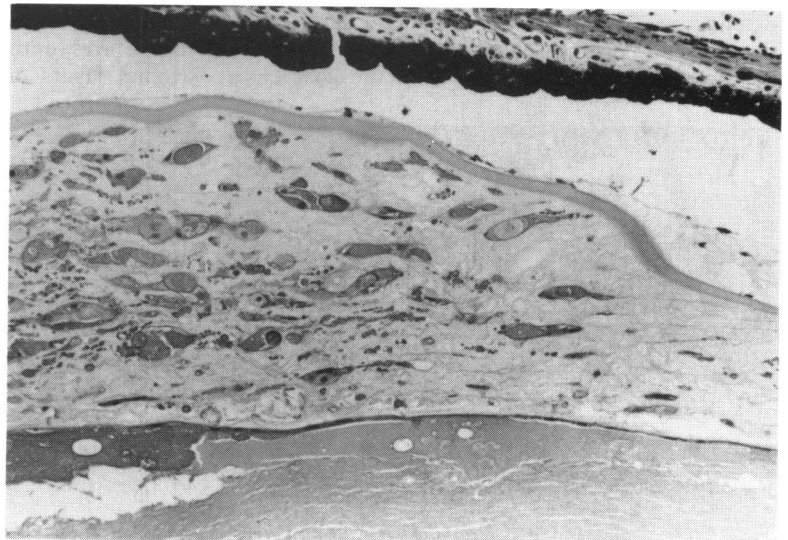
Fig. 3 Part of ciliary processes elongated. ($\times 29$).

sphincter muscle cells were not separated from the pigmented cells. The lens, ciliary body, anterior chamber angle structure were well developed. There was no aberrant tissue in the vitreous. The retina was

well developed, with the normal stratification, and there was no developmental anomaly in the neural retina or pigment epithelium, except a reduced number of retinal vessels and scarce ganglion cells with associated thin nerve fibre layer. The choroid was composed mainly of large vessels.

Left eye. This eye was evidently microphthalmic, measuring $18.5 \times 15.5 \times 15$ mm. Inspection of the sectioned eyeball disclosed a piece of detached retina attached to retrolental fibrous tissue (Figs. 2A, B). The cornea was normally developed. The iris was also normally developed, but part of its pigment epithelial layer had nodule-like proliferations. The ciliary muscles were arranged irregularly, and a part of the ciliary processes was elongated and adherent to the proliferated connective tissue behind the lens. The anterior chamber angle was immature (Fig. 3). The whole circumference of the lens had epithelial cells, and between the anterior capsule and the epithelial cell layer were present numerous aberrant cells (Fig. 4). Adherent to an irregularly curved posterior capsule of the lens was a mass of dense fibrous tissue containing numerous small vessels, which was regarded as persistent primary vitreous (Fig. 5). The bulk of the retina was completely detached from the pigment epithelium and firmly adherent to the retrolental vascularised tissue, at the periphery of which there were numerous macrophages containing melanin granules. The retina was highly dysplastic and composed of undifferentiated embryonic tissue containing a number of rosettes; the rosettes had a clear or fibrillar central lumen surrounded by fine limiting membranes and one or two layered dark nuclei; in shape they were oval, elliptical, or oblong in accordance with the plane

Fig. 4 Anterior part of the lens with numerous aberrant cells between the anterior capsule and epithelial cell layer. ($\times 60$).



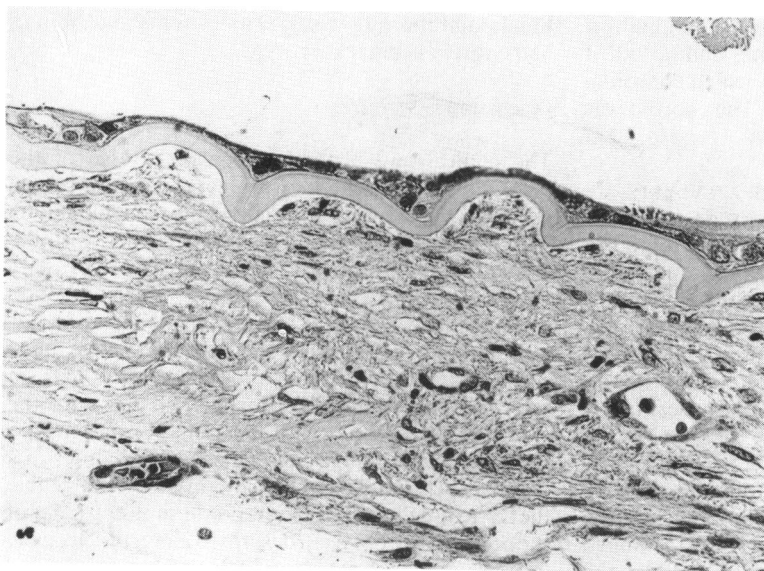


Fig. 5 *Vascularised fibrous tissue adherent to the posterior surface of the lens. ($\times 60$).*

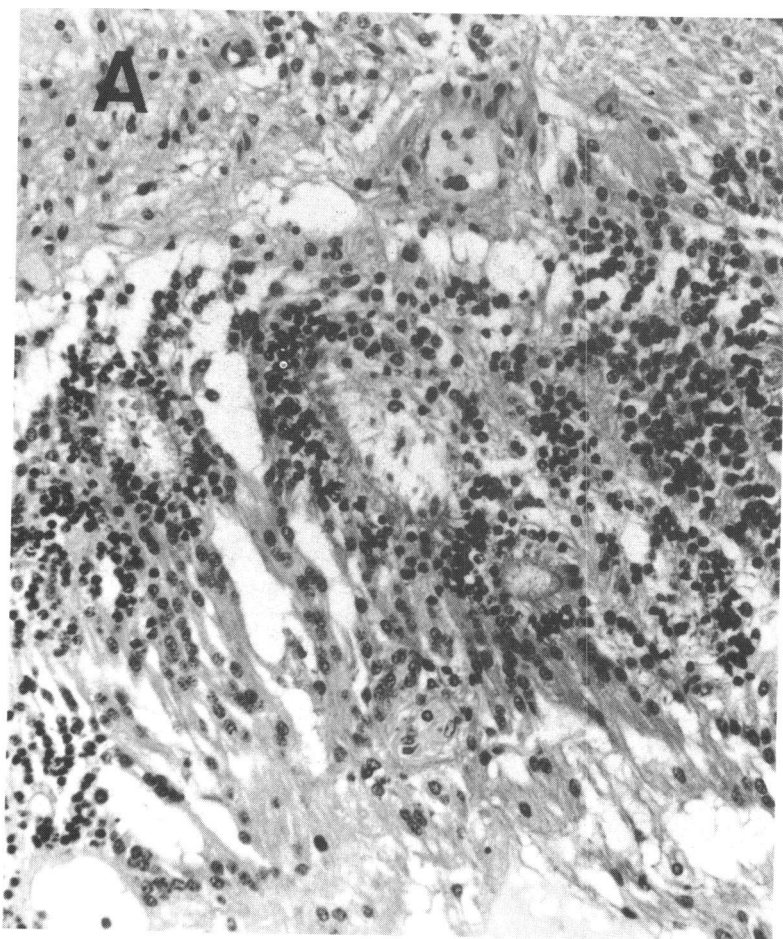


Fig. 6A *Dysplastic retina with formation of rosettes. ($\times 50$).*

sectioned (Fig. 6A, B). The pigment epithelium of the retina was also dysplastic, being composed of multiple layers of proliferated cells which choroidal vessels had invaded here and there. The choroid was poorly developed (Fig. 7).

FAMILY HISTORY AND KARYOTYPE ANALYSIS

The patient was the third of three children of non-consanguineous parents. The parents and siblings (a brother and sister) were examined and found to be normal, and there was no family history of systemic or ocular malformations. Chromosome analysis was performed on peripheral blood cultures and banded with Giemsa. The patient showed 46 female chromosomes with an apparently balanced reciprocal translocation between an X chromosome and a C group autosome, most probably autosome 10. The breakpoint of the X chromosome was estimated as being Xp11 (Figs. 8A, B). Thus her karyotype may be described as 46XX, t(X;10) (p11; p14), though detailed cytogenetic studies are needed to define the

breakpoint more precisely. Her parents and siblings had entirely normal karyotypes.

Discussion

The clinical and histopathological features of the patient are consistent with typical vitreoretinal dysplasia, presenting as a congenital pseudoglioma with poorly differentiated dysplastic retina, with the formation of rosettes and proliferated primary vitreous. The cause of these developmental anomalies is certainly a chromosomal aberration.

A number of chromosomal diseases have been shown to induce ocular anomalies as a part of systemic syndrome. Dymorphic changes of the external eye together with facial malformations are the most commonly found ocular abnormalities in a variety of chromosomal aberrations. It is noticeable that a severe vitreoretinal dysplasia similar to that of the present case has been described almost exclusively in association with an excess of the genetic material of

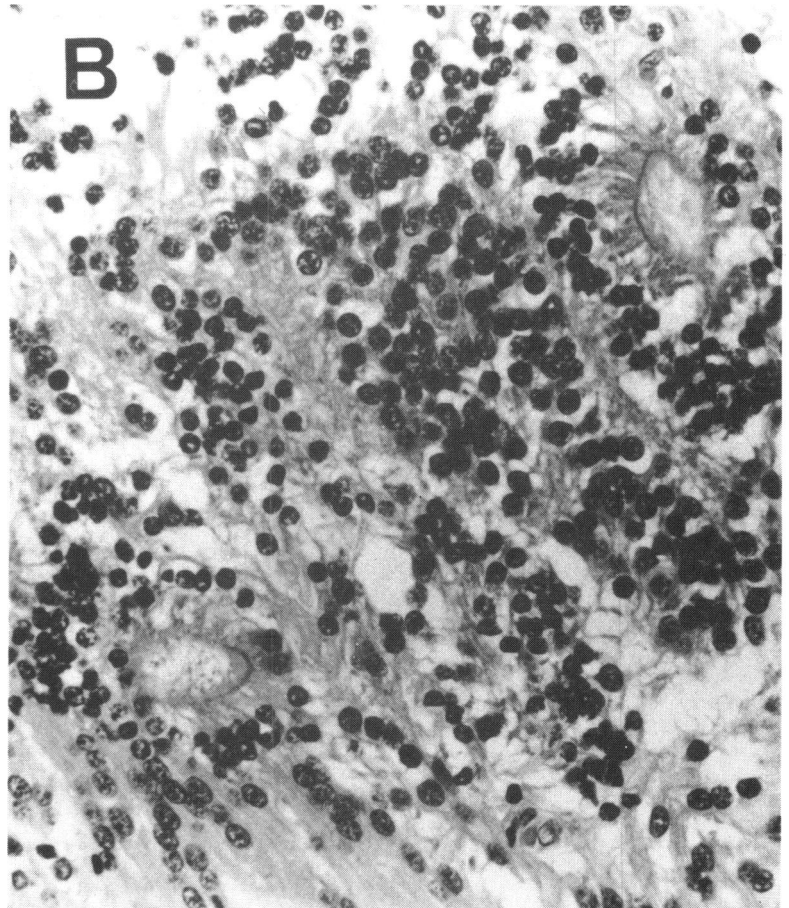


Fig. 6B *Dysplastic retina with formation of rosettes. (×100).*

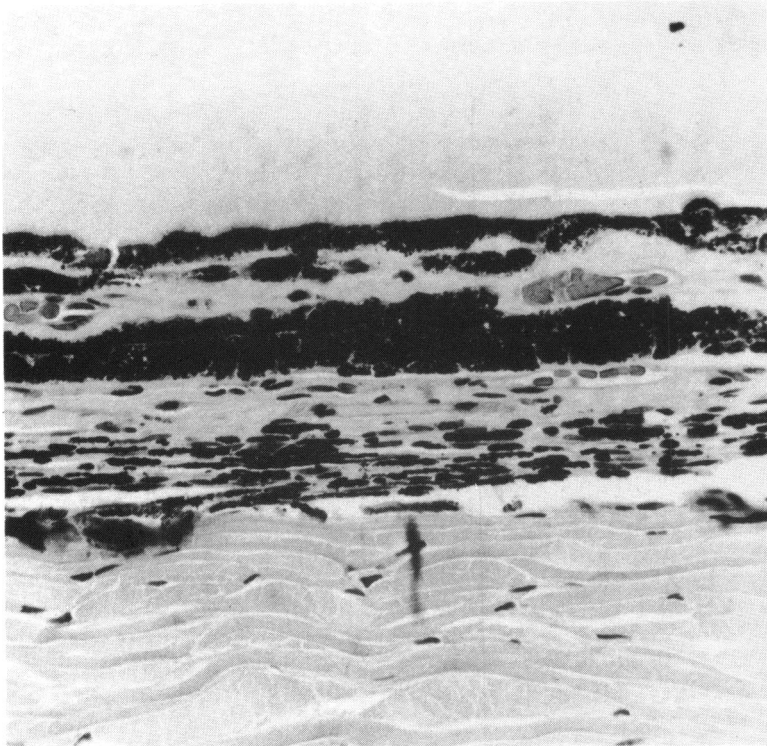


Fig. 7 *Dysplastic retinal pigment epithelium and choroid, multiple layered pigment epithelium invaded by choroidal vessels. ($\times 80$).*

autosome 13, its trisomy or partial trisomy, referred to as Patau's syndrome.⁸⁻¹⁰ The present case is therefore exceptional in that chromosome analysis revealed 46XX, t(X;10), a seemingly balanced reciprocal translocation between an X chromosome and one of the C group autosomes, probably autosome 10. It is most likely that this rare chromosomal aberration occurred as a *de novo* mutation in view of the normal karyotypes of the parents. Therefore Patau's syndrome can safely be ruled out, and the autosomal recessive trait of vitreoretinal dysplasia can also be excluded, since it is extremely unlikely that a new mutation at an autosome-linked gene locus and a *de novo* chromosomal translocation involving the X chromosome could occur by coincidence. Thus it is plausible that the chromosomal translocation happened to disrupt the vitreoretinal dysplasia gene itself, and the apparent translocation breakpoint Xp11 suggests the gene locus for the disease of this patient, though a precise localisation must depend on more detailed cytogenetic studies.

If the above explanation is correct, it is still necessary to explain why our patient showed the full clinical features of vitreoretinal dysplasia when she was heterozygous for the disease gene and had one normal allele. Heterozygous females of X-linked condition usually show mild, if any, clinical symp-

toms, since the X chromosome having the normal allele is inactivated in a random manner.¹¹ The reason for the full clinical picture in our patient is almost certainly that her normal X chromosome, which carries the normal allele at the vitreoretinal dysplasia gene locus, is almost inactive, either because of non-random X chromosome inactivation or because of some subsequent selection of the cells in which the mutant X chromosome is active. This non-random X inactivation in X autosome translocation has been well described.¹² In this connection it is remarkable that the degree of the clinical symptoms of the present case varied considerably between the two eyes; one eye had severe vitreoretinal dysplasia, whereas the other eye showed a relatively mild condition. This suggests a variable degree in the inactivation of the X chromosome bearing the normal allele.

A phenomenon similar to the present case has been reported in heterozygous females of X linked recessive disorders such as Hunter's disease and Duchenne muscular dystrophy. The heterozygous females of these conditions usually have normal karyotypes and no or only mild clinical symptoms. A female patient with the full clinical picture of Hunter's disease showed a *de novo* balanced reciprocal chromosomal translocation 46XX, t(X;5) with the

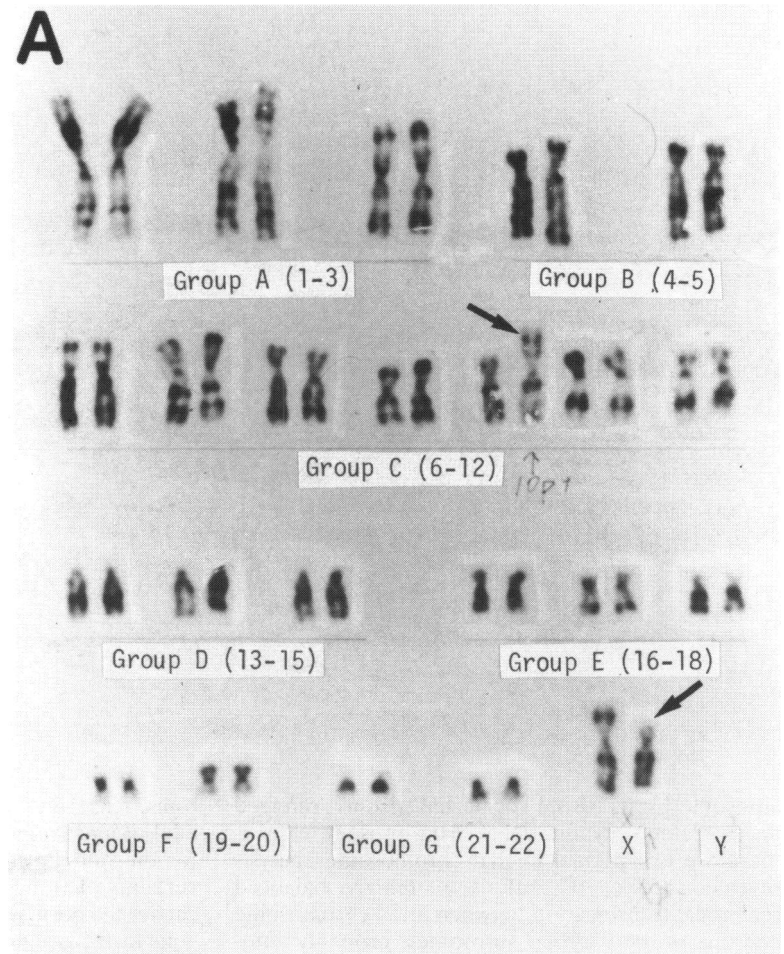


Fig. 8A Giemsa-banded karyotype of the patient.

X chromosome translocation breakpoint being between Xq26-27.¹³ More than five unrelated female patients with the typical clinical features of Duchenne muscular dystrophy were reported to have an apparently balanced reciprocal X autosome translocation 46XX, t(X;A), and, although different autosomes were affected among the patients, the breakpoint on the X chromosome was invariably Xp21.¹⁴

It is tempting to assume with reference to the above reports that the present case was indeed one of Norrie's disease, a rare X-linked recessive disorder characterised by bilateral blindness due to severe vitreoretinal dysplasia and in some instances by associated mental retardation and hearing impairment. Heterozygous females do not show any clinical symptoms with normal karyotypes.^{6,7} The clinical and histopathological features of the present case are consistent with the full clinical symptoms of Norrie's

disease except for the associated facial dysmorphic anomalies, which are not usually found in this disease.^{6,7} By analogy with the sporadic female patients of X-linked disorders mentioned above, it may be possible to conclude that the present case had Norrie's disease due to X autosome translocation. If this interpretation is correct, it is suggested that the gene locus of Norrie's disease is located at the short arm of the X chromosome.

Genetic linkage studies have suggested a loose linkage of Norrie's disease with the glucose-6-phosphate dehydrogenase locus,⁶ and no measurable linkage with Xg blood group locus.^{6,15} The former locus has been assigned to the long arm of the X chromosome, Xq28, and the latter to the short arm of the X chromosome, Xp2.¹⁶ Our assumption for the Norrie's disease gene locus, the short arm of the X chromosome, seems inconsistent with these genetic linkage data. In any event family studies of Norrie's

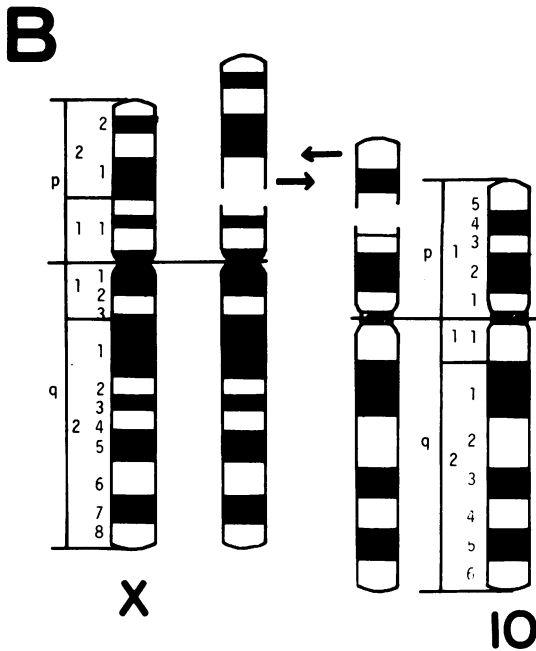


Fig. 8B Idiogram showing the apparently balanced reciprocal translocation between chromosome X and 10 (arrows).

disease with reference to the linkage with various gene loci mapped on the X chromosome, and detailed chromosome analysis on sporadic female patients with features of Norrie's disease, will be required for a more precise localisation of the Norrie's disease gene.

This study was supported in part by a research grant for retinochoroidal atrophy from the Japanese Ministry of Health and Welfare.

References

- 1 Reese AB, Blodi FC. Retinal dysplasia. *Am J Ophthalmol* 1950; **33**: 23-32.
- 2 Babel PJ. Les malformations pseudotumorales du globe oculaire. *Ophthalmologica* 1966; **151**: 405-26.
- 3 Lahav M, Albert DM, Wyand S. Clinical and histopathologic classification of retinal dysplasia. *Am J Ophthalmol* 1973; **75**: 648-67.
- 4 Warburg M. Retinal malformations. Aetiological heterogeneity and morphological similarity in congenital retinal non-attachment and falciform folds. *Br J Ophthalmol* 1979; **99**: 272-83.
- 5 Ohba N, Watanabe S, Fujita S. Primary vitreoretinal dysplasia transmitted as an autosomal recessive disorder. *Br J Ophthalmol* 1981; **65**: 631-5.
- 6 Warburg M. Norrie's disease. A congenital progressive oculo-acoustico-cerebral degeneration. *Acta Ophthalmol (Kbh)* 1966; suppl **89**: 1-147.
- 7 Fujita S, Fujiwara S, Ohba N. Norrie's disease: report of cases of two Japanese families. *Jpn J Ophthalmol* 1980; **24**: 22-8.
- 8 Apple DJ. Chromosome-induced ocular disease. In: Goldberg MF, ed. *Genetic and metabolic eye disease*. Boston: Little, Brown, 1974: 527-66.
- 9 François J, Berger R, Saraux H. *Chromosomal aberrations in ophthalmology*. Assen: Van Gorcum, 1975.
- 10 deGrouchy J, Turler C. *Clinical atlas of human chromosomes*. New York: J Wiley, 1977.
- 11 Lyon MF. Genetic activity of sex chromosome in somatic cells of mammals. *Phil Trans R Soc Lond (Biol)* 1970; **259**: 41-52.
- 12 Therman E, Patau K. Abnormal X chromosomes in man: origin, behaviour and effects. *Humangenetik* 1974; **25**: 1-16.
- 13 Mossman J, Blunt S, Stephens R, Jones EE, Pembrey M. Hunter's disease in a girl: association with X:5 chromosomal translocation disrupting the Hunter gene. *Arch Dis Child* 1983; **58**: 911-5.
- 14 Zatz M, Vianna-Morgante AM, Campos P, Diamant AJ. Translocation (X;6) in a female with Duchenne muscular dystrophy: implications for the localization of the DMD locus. *J Med Genet* 1981; **18**: 442-7.
- 15 Nance WE, Hara S, Hansen A, Elliot J, Lewis M, Chown B. Genetic linkage studies in a negro kindred with Norrie's disease. *Am J Hum Genet* 1969; **21**: 423-9.
- 16 McKusick VA. The human genome through the eyes of a clinical geneticist. *Cytogenet Cell Genet*. 1982; **32**: 7-23.

Accepted for publication 24 May 1985.