

A penetrating orbitocranial stab wound

CAROLINE J MAC EWEN AND G FULLARTON

From the ¹Ophthalmology Department, Gartnavel General Hospital, Glasgow, and the ²Accident and Emergency Department, Glasgow Royal Infirmary, Glasgow

SUMMARY An unusual case of intracranial penetration of a bread knife through the orbit is described. Despite the proximity of the blade to the internal carotids, the optic nerves and chiasm, and the pituitary the patient survived with only a minimal field defect affecting the eye opposite to the entry site; otherwise no neurological or endocrine deficit was evident.

Penetrating intracranial orbital stab wounds have attracted much attention mainly because of the morbidity and mortality associated with them.¹⁻⁵ Damage to the orbital contents may result in a rupture of the globe; retinal detachment, immediate or delayed; extraocular muscle injury; optic nerve avulsion; and lacrimal gland damage. Penetration into the cranial cavity is commonly via the superior orbital fissure or optic canal, which provide direct access with no bone fracture, or through the orbital roof, which has thin bone and therefore offers little resistance. Complications of orbitocranial penetration are serious and include laceration of brain cortex by bony spicules or the penetrating object; meningitis or abscess formation; carotid cavernous fistula and false aneurysm formation; hydrocephalus; and intracranial haemorrhage. But little has been published on minor or trivial defects.⁶ The following case illustrates an interesting example of a deep penetrating stab wound causing only a minimal field defect, and that on the contralateral side to the injury.

Case report

A 28-year-old woman was admitted to the Accident and Emergency Department, having been stabbed with a 10 inch (25 cm) bread knife. On admission the knife was firmly embedded along the right infra-orbital margin to a depth of approximately 5 inches (13 cm) (Fig. 1). Attempts by friends to remove it had resulted in the handle breaking off. She was alert and orientated with no evidence of focal neurological signs. Blood and clear fluid oozed from the wound. She had difficulty in elevating the right eye. Assess-

ment of visual acuity was difficult owing to lack of cooperation, but perception of light was present and the pupillary reactions were normal. The globe was not penetrated.

Radiological examination revealed that the knife passed along the infraorbital floor, through the ethmoid sinuses and tuberculum sella, and the tip lay in the suprasellar cistern (Figs. 2 and 3). She was transferred to the local neurosurgical unit. Penicillin and sulphadimidine therapy was begun. Bilateral carotid angiography revealed that the blunt edge was in close proximity to the right internal carotid artery and the serrated edge lying close to the left internal carotid. A right frontal craniotomy was performed, and direct inspection at frontal craniotomy confirmed these findings. After proximal and distal vascular control the knife was removed with much difficulty, and fortunately caused no visible damage to the carotid arteries, optic chiasm, or pituitary. Post-

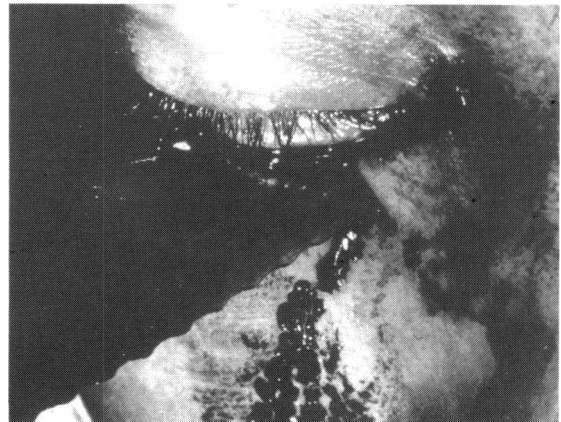


Fig. 1 Blade in situ on presentation.

Correspondence to Dr C J MacEwen, Department of Ophthalmology, Gartnavel General Hospital, 1053 Great Western Road, Glasgow G12 0YN.

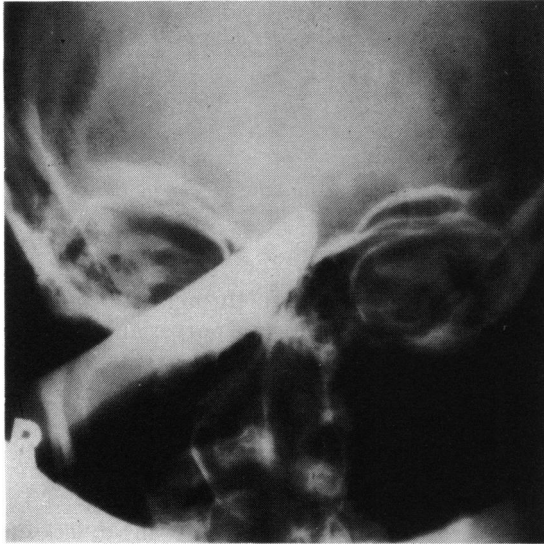


Fig. 2 Anteroposterior skull radiograph.

operatively and at follow-up there was no evidence of neurological or endocrine deficit. Ophthalmological follow-up showed visual acuities of 6/6 in each eye with no refractive error. External signs of injury were limited to a small wound below the right eye, which healed into a virtually invisible scar. Pupillary reactions were normal. Extraocular eye movements were full. Fundal examination revealed bitemporal disc pallor. Visual field testing was carried out and indicated a small absolute inferonasal defect in the left eye, which persisted 18 months after the injury (Fig. 4). The right visual field was normal from first examination.

Discussion

Penetrating intracranial injuries characteristically cause considerable morbidity and mortality by direct damage to vital structures, circulatory compromise, or infection. Circulatory compromise may be due to direct vascular trauma, distortion of the vessel due to local effects such as haematoma formation or oedema, or vasospasm.⁵ The pathogenesis of this vasospasm is not understood.⁷ A recent report⁴ provides an excellent example of this: at open removal of an intracranial foreign body the internal carotid artery was seen to be completely thrombosed, with no evidence of external damage or direct contact with the foreign object.

The striking feature of this case is how little damage was done by the penetration of 5 inches (13 cm) of knife into an area rich in important structures—the internal carotids, the optic nerves and chiasm, and the pituitary gland. The skilled

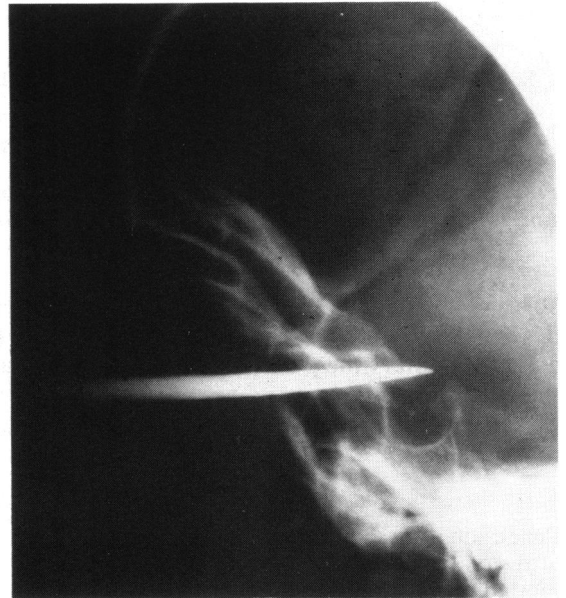

Fig. 3 Lateral skull radiograph.

removal of the knife by the neurosurgical team after careful dissection and identification of structures resulted in no significant damage. Detailed examination showed the only deficit to be an inferonasal field defect in the left eye (Fig. 4). This is in agreement with reflex vasospasm causing reduced flow in the smaller branches of the internal carotid, which led to reversible damage to the intracranial part of the optic nerve apart from an area of permanent damage in the superotemporal portion.

The detailed blood supply to the intracranial optic nerve is still controversial. The controversy mainly surrounds the inferonasal aspect of the nerve and the relative importance of the ophthalmic artery⁸ and the

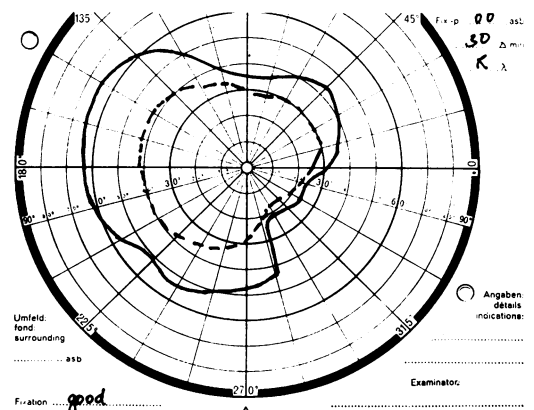


Fig. 4 Left inferonasal field defect which persists.

anterior superior hypophyseal artery.⁹ Supply to the superior and temporal parts is better agreed upon with contributions from the anterior cerebral artery, internal carotid artery, and ophthalmic artery being generally accepted.¹⁰⁻¹² The detailed account by Isayama *et al.*¹² describes the superotemporal aspect of the nerve as the only area which (a) receives only one nutrient artery, the lateral chiasmal artery, and (b) receives blood only directly from the internal carotid artery. Permanent damage to the flow in this lateral chiasmal artery either by spasm or by clot would explain the subsequent field defect in this patient. She does not notice this defect.

Damage to structures on the contralateral side to the entry wound is rarely seen. In De Villiers' series⁵ of 10 transorbital stab wounds only one had this complication, and the penetrating foreign body entered the lateral orbital margin and followed its anatomical direction of 45° to the sagittal plane, and thus crossed the midline.

Despite the enormous potential for serious injury the woman reported on here has survived with such a negligible defect in vision that she is unaware of its existence.

We thank Dr R McFadzean for his constructive criticism and Miss Lorna Gow for typing the manuscript.

References

- 1 Bard LA, Vannett WH. Intracranial complications of penetrating orbital injuries. *Arch Ophthalmol* 1964; **71**: 332-43.
- 2 Schueider RC, Henderson VW. Penetrating orbital wound with intracranial complications. *Arch Ophthalmol* 1952; **47**: 81-5.
- 3 Kjer P. Orbital and transorbital stab wounds. *Arch Ophthalmol* 1954; **51**: 811-21.
- 4 Doucet TW, Harper DW, Royers J. Penetrating orbital foreign body with intracranial involvement. *Ann Ophthalmol* 1953; **15**: 325-7.
- 5 De Villiers JC. Stab wounds of the brain and skull. In: Vinken PJ, Bruyn JW, eds. *Handbook of clinical neurology*. Amsterdam: North Holland, 1975; **1**: 477-93.
- 6 Hickmann DM. Benign sequelae of a trans orbital stab wound: an unusual case report. *Ann Plas Surg* 1984; **12**: 279-83.
- 7 Wilkens RH. Intracranial vascular spasm in head injuries. In: Vinken PJ, Bruyn JW, eds. *Handbook of clinical neurology*. Amsterdam: North Holland, 1975; **1**: 163-93.
- 8 Hayreh SS. The ophthalmic artery. III. Branches. *Br J Ophthalmol* 1982; **66**: 212-47.
- 9 Steele EJ, Blunt MJ. The blood supply of the optic nerve and chiasma in man. *J Anat* 1956; **40**: 486-93.
- 10 Francois J, Neetens H. Vascularisation of the optic pathway. IV. Study of the intraorbital and intracranial optic nerve by serial sections. *Br J Ophthalmol* 1956; **40**: 45-52.
- 11 Hughes B. Blood supply of the optic nerve and chiasma and its clinical significance. *Br J Ophthalmol* 1958; **42**: 106-25.
- 12 Isayama Y, Hiramatsu K, Asakura S, Takahashi T. Posterior ischaemic optic neuropathy. I. The blood supply of the optic nerve. *Ophthalmologica* 1983; **186**: 197-203.

Accepted for publication 30 May 1985.