

# Acute posterior multifocal placoid pigment epitheliopathy associated with diffuse retinal vasculitis and late haemorrhagic macular detachment

MAKOTO ISASHIKI, HIROSHI KOIDE, TETSUHIRO YAMASHITA,  
AND NORIO OHBA

*From the Department of Ophthalmology, Kagoshima University Faculty of Medicine, Kagoshima-shi, Japan*

**SUMMARY** A 20-year-old healthy man suffered rapid loss of bilateral central vision with placoid lesions at the level of the retinal pigment epithelium and choriocapillaris scattered in the posterior pole of the fundus. In addition, acute vasculitis of the retinal veins was remarkable and widespread throughout the posterior pole and midperiphery. These inflammatory signs subsided in several weeks and were succeeded by recovery of the normal visual acuity with residual pigment derangements in the deep retina. Sixteen months after the onset of the disease choroidal neovascular membranes developed in the macular region of the left eye, followed by haemorrhagic macular detachment and marked visual loss. Significant increases in the serum cold agglutinin titre occurred as isolated laboratory findings concurrently with the acute stage of the disease and the late macular complication, though no clinical or other laboratory sign suggested viral infection.

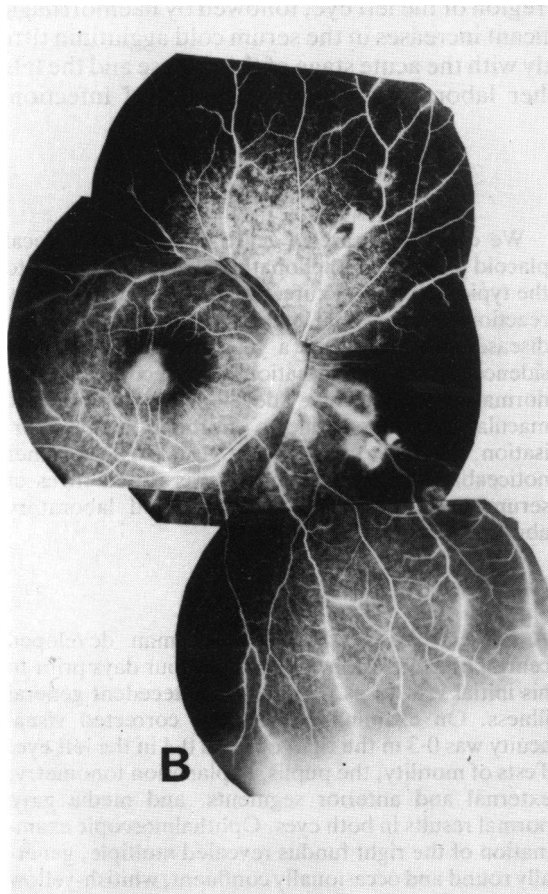
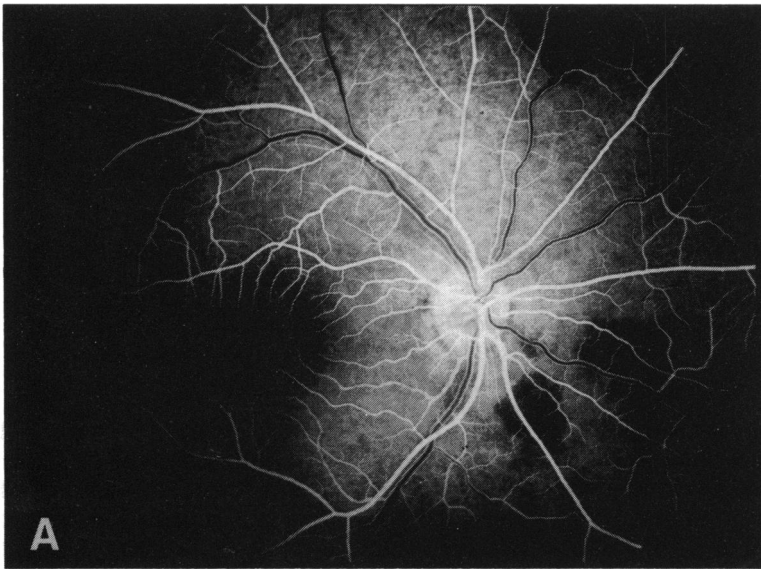
Acute posterior multifocal placoid pigment epitheliopathy, originally defined by Gass,<sup>1</sup> is a disease characterised by the acute onset of multiple, yellow or cream-coloured, placoid lesions at the level of the retinal pigment epithelium and choriocapillaris scattered in the posterior pole of the fundus. The disease affects both eyes of healthy young adults with or without a history of recent viral illness involving the upper respiratory or gastrointestinal tract just prior to the onset of visual symptoms, and it leads to a rapid loss of central vision when the macular region is involved. The prognosis is favourable, so that the characteristic lesions resolve over several weeks, leaving alternating depigmentation and pigment clumping, with remarkable improvement of visual function.<sup>1-9</sup> Occasional abnormalities associated with the acute stage of the disease include episcleritis,<sup>4,9</sup> subconjunctival haemorrhage,<sup>9</sup> anterior uveitis<sup>4,5,8,10</sup> or vitreitis,<sup>6,8,10,11</sup> serous detachment of the sensory retina,<sup>2,6,9,10,11</sup> optic disc swelling,<sup>3,9,11,12</sup> segmental retinal vasculitis,<sup>9,12</sup> and small retinal haemorrhages.<sup>4,10,12</sup>

We describe a case of acute posterior multifocal placoid pigment epitheliopathy which, in addition to the typical clinical picture, had diffuse inflammatory reactions of the retinal veins in the acute stage of the disease and, more than a year after complete subsidence of the inflammation with recovery of the normal visual acuity, developed haemorrhagic macular detachment due to choroidal neovascularisation, leading to irreversible visual loss. Another noticeable finding in this case was raised titres of serum cold agglutinins as an isolated laboratory abnormality.

## Case report

A 20-year-old healthy Japanese man developed central blurred vision of both eyes four days prior to his initial visit to us. He had no antecedent general illness. On examination his best corrected visual acuity was 0.3 in the right eye and 0.4 in the left eye. Tests of motility, the pupils, applanation tonometry, external and anterior segments, and media gave normal results in both eyes. Ophthalmoscopic examination of the right fundus revealed multiple, generally round and occasionally confluent, whitish-yellow

Correspondence to Dr Makoto Isashiki, Department of Ophthalmology, Kagoshima University Faculty of Medicine, Usuki-cho 1208-1, Kagoshima-shi, Japan (890).



**Fig. 1** Fluorescein angiograms recorded one week after the onset of disease. (A) Early phase of the angiogram, showing blockages of the background choroidal fluorescence in the placoid lesions (right eye). (B) Right eye, (C) left eye, late phase of the angiogram, showing hyperfluorescence in the placoid lesions and diffuse retinal phlebitis with associated small retinal haemorrhages (arrow).

lesions scattered in the posterior pole and the mid-periphery. The lesions were at the level of the retinal pigment epithelium and choriocapillaris. There was no serous detachment of the sensory retina or pigment clumping. The optic disc, retina, and choroid between these lesions were normal except for widespread abnormalities of the retinal veins, showing extensive distortion, tortuosity, and sheathing. In contrast the retinal arteries appeared virtually normal. Ophthalmoscopic examination of the left fundus showed similar placoid lesions and inflammatory changes of retinal veins associated with small retinal haemorrhages.

Fluorescein angiography in the arterial and arteriovenous phases revealed discrete blockage of the background fluorescence by the whitish-yellow lesions. Later the lesions became gradually fluorescent and progressively hyperfluorescent, so that the periphery of the lesions was stained more prominently, but there was no leakage of dye into the subretinal space. The retinal veins behaved normally in the early phases of the angiography, followed by marked leakages of dye into the surrounding retina

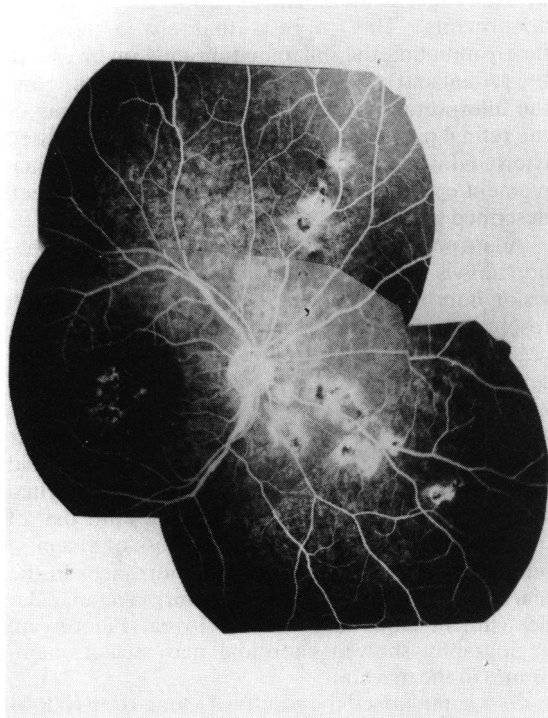


Fig. 2 Fluorescein angiogram recorded four weeks after the onset of disease (right eye), showing window-defect hyperfluorescence in the periphery of the placoid lesions and pigment clumping hypofluorescence in the centre of the lesions. Retinal phlebitis had disappeared.

and staining of the large and medium sized vessels in the posterior pole and midperiphery. The retinal phlebitic changes appeared to be independent of the whitish-yellow placoid lesions. Meanwhile the retinal arteries appeared normal on fluorescein angiography (Figs. 1A, B, C).

Systemic corticosteroids with a total dosage of 400 mg prednisolone were given for two weeks. The whitish-yellow lesions gradually resolved over three weeks and were followed by greyish discoloration and pigment clumping in this central area. The widespread retinal phlebitis subsided in a few weeks together with the resolution of the placoid lesions. The macular region of both eyes retained marked pigmentary derangement. Fluorescein angiography performed four weeks after the onset of the disease showed early hyperfluorescence due to window-defect in the periphery of the placoid lesions and hypofluorescence in their centre. The retinal veins were of normal appearance (Fig. 2). Along with the subsidence of the inflammatory changes the visual acuity improved gradually, and three months later it returned to normal in both eyes.

Sixteen months after the onset of the disease the patient returned to us with complaints of paracentral blurred vision in the left eye. On examination there was no substantial change in the right fundus, with sustained normal visual acuity. The left eye still had normal visual acuity, but there was a small paracentral scotoma inferotemporal to the centre. Ophthalmoscopic examination of the left fundus showed subretinal haemorrhages in the pigmentary deranged macular region superonasal to the fovea, followed several weeks later by a haemorrhagic retinal detachment, which eventually extended to the fovea and led to visual acuity loss to 0.2. Fluorescein angiography showed early hyperfluorescence in the macular region, which increased in intensity and area in the course of the angiography, indicating the presence of choroidal neovascularisation, while the choroidal fluorescence was masked in areas of subretinal haemorrhages. Dye leakage from the choroidal neovascular membranes extended into the subretinal spaces in the later stage of the angiography (Figs. 3A, B). In the following months the subretinal haemorrhages were gradually absorbed, leaving proliferated scar tissues with pigment clumpings in the macular region. Six months after the onset of the macular episode the visual acuity remained 0.4.

Physical examination and thorough laboratory survey were repeated several times during the follow-up. The patient kept physically healthy. Haematological tests, urine analysis, and serological tests for various agents including toxoplasmosis and syphilis were negative except for a positive tuberculin skin

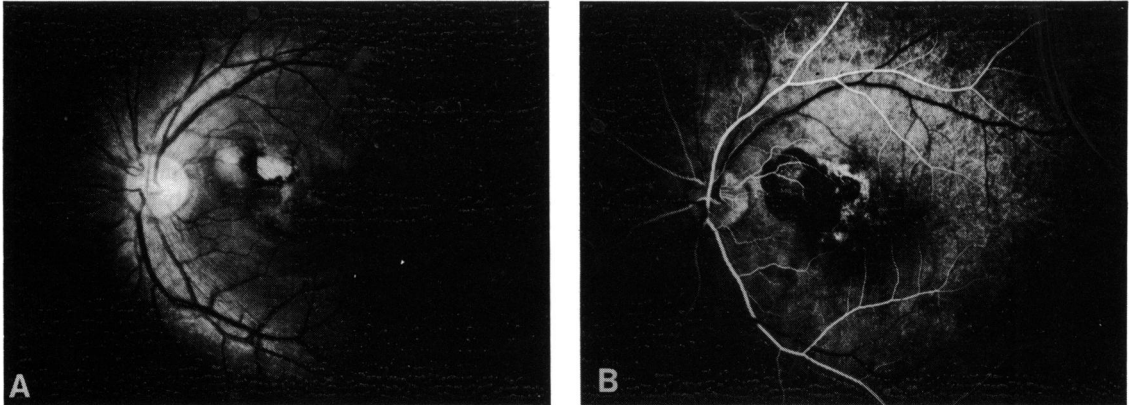


Fig. 3 Fundus photograph (A) and early phase of fluorescein angiogram (B), left eye, recorded 16 months after the onset of disease, showing development of subretinal haemorrhage due to choroidal neovascularisations in the macular region.

test and an increase of cold agglutinin. The cold agglutinin titre was 1024 on the initial examination and 2048 one month later, followed by a return to the normal level (less than 256), and it rose transiently 16 months after the onset of the disease when subretinal macular haemorrhage developed (Table 1).

### Discussion

The clinical features, course, and prognosis of this case conform for the most part to acute posterior multiple placoid pigment epitheliopathy, but some findings notable with reference to the pathogenesis of placoid lesions and the late complications of the disease.

The disease has been recognised as an acute inflammatory condition affecting the retinal pigment epithelium and choriocapillaris, though serous detachment of the retina or optic disc swelling are complications in occasional cases. Our case is unusual in that diffuse inflammatory reactions of the retinal vasculature associated with small retinal

haemorrhages occurred in a concurrent but topographically independent manner, with the multifocal placoid lesions at the level of the retinal pigment epithelium and choriocapillaris. It is noticeable that the vasculitis was confined to the retinal veins, and that they subsided dramatically without any residual abnormality. This suggests that any aetiological factor initiating the inflammation may involve both the retinal and choroidal vasculatures. This supports the interpretation that the acute cloudy swelling of the retinal pigment epithelium represents a localised choroidal vasculopathy rather than a primary retinal pigment epitheliopathy.<sup>7</sup> Retinal vasculitis has been described in occasional cases.<sup>9,12</sup>

Acute posterior multifocal placoid pigment epitheliopathy is usually benign in nature. The central vision improves rapidly in the first weeks along with resolution of the macular placoid lesions; a more gradual improvement follows even months after cessation of the inflammatory condition, though normal visual acuity may not return when the fovea is damaged severely.<sup>12</sup> A recurrence is rare.<sup>10,11</sup> Our case showed a typical clinical course, with a rapid inactivation of inflammation and a return to normal visual acuity in both eyes, but it is remarkable that 13 months later the patient again had loss of vision in one eye because of subretinal haemorrhages in the macular region, followed by haemorrhagic macular detachment extending into the fovea. Fluorescein angiography showed choroidal neovascular membranes in the macula.

Gass summarised the results of a long-term follow-up study of 30 cases of the disease and found one case which developed haemorrhagic macular detachment caused by a juxtapapillary choroidal neovascular membrane after recovery of normal visual acuity.<sup>9</sup> Shatz and associates briefly, reported one case which

Table 1 Serum cold agglutinin titre at various times after onset of the disease

Months after onset of disease	Cold agglutinin titre (normal: $\leq 256$ )
0	1024
1	2048
2	128
3	256
16*	512
17	1024
22	256

\*Haemorrhagic macular detachment occurred.

had a focal area of subretinal neovascularisation developed at the margin of a subacute lesion of the disease.<sup>13</sup>

We therefore wish to emphasise that development of a choroidal neovascular membrane is an occasional association of the disease, possibly leading to haemorrhagic retinal detachment. Choroidal neovascular membrane has been shown to form not only in degenerative diseases, including senile macular degeneration, but also in inflammatory diseases.<sup>14</sup> Although the exact mechanism is unknown, it is probable that the subretinal neovascularisation in acute posterior multifocal placoid pigment epitheliopathy represents a late complication rather than a process related to the acute disease. In any event, patients with severe macular pigmentary derangement should be followed up for at least a year after resolution of the inflammatory process. This would provide an early detection of the possible development of choroidal neovascularisation. The present case was not suitable for laser therapy because of the central location of the complication.

The aetiology of acute posterior multifocal placoid pigment epitheliopathy has yet to be defined, but viral infection has been assumed to be responsible in some cases.<sup>3,5</sup> It is noticeable that our case showed raised titres of cold agglutinins in the acute inflammatory stage of the disease. The cold agglutinin titre of the serum is known to rise in acute viral diseases and *Mycoplasma pneumoniae* infection, and the increase may be an isolated laboratory finding or coexist with underlying disease.<sup>15</sup> Our case showed the abnormality as an isolated laboratory finding. The significance of the further rise of the titre long after cessation of the acute disease is not clear, but it occurred coincidentally with the late development of subretinal choroidal neovascularisations.

#### References

- 1 Gass JDM. Acute posterior multifocal placoid pigment epitheliopathy. *Arch Ophthalmol* 1968; **80**: 177–85.
- 2 Bird AC, Hamilton AM. Placoid pigment epitheliopathy, presenting with bilateral serous retinal detachment. *Br J Ophthalmol* 1972; **56**: 881–6.
- 3 Ryan SJ, Maumenee AE. Acute posterior multifocal placoid pigment epitheliopathy. *Am J Ophthalmol* 1972; **74**: 1006–74.
- 4 Annesley WH, Tomer TL, Shields JA. Multifocal placoid pigment epitheliopathy. *Am J Ophthalmol* 1973; **76**: 511–8.
- 5 Fitzpatrick PJ, Robertson DM. Acute posterior multifocal placoid pigment epitheliopathy. *Arch Ophthalmol* 1973; **89**: 373–6.
- 6 Savino PJ, Weinberg RJ, Yassin JG, Pilkerton AR. Diverse manifestation of acute posterior multifocal placoid pigment epitheliopathy. *Am J Ophthalmol* 1974; **77**: 659–62.
- 7 Deutman AF, Lion F. Choriocapillaris nonperfusion in acute multifocal placoid pigment epitheliopathy. *Am J Ophthalmol* 1977; **84**: 652–7.
- 8 Priluck IA, Robertson DM, Buettner H. Acute posterior multifocal placoid pigment epitheliopathy. *Arch Ophthalmol* 1981; **99**: 1560–2.
- 9 Gass JDM. Acute posterior multifocal placoid pigment epitheliopathy. A long term follow up. In: Fine SL, Owens SL, eds. *Management of retinal vascular and macular disorders*. Baltimore: Williams and Wilkins, 1983: 176–81.
- 10 Holt WS, Regan CDJ, Trempe C. Acute posterior multifocal placoid pigment epitheliopathy. *Am J Ophthalmol* 1976; **81**: 403–12.
- 11 Maruyama H. Acute posterior multifocal placoid pigment epitheliopathy. *Jpn J Clin Ophthalmol* 1975; **29**: 729–36.
- 12 Kirkham TH, Ffytche TJ, Sanders MD. Placoid pigment epitheliopathy with retinal vasculitis and papillitis. *Br J Ophthalmol* 1972; **56**: 875–80.
- 13 Shatz H, Gitter KA, Yannuzzi LA. Inflammation of the pigment epithelium and choriocapillaris. In: Yannuzzi LA, Gitter KA, Shatz H, eds. *The macula*. Baltimore: Williams and Wilkins, 1979: 247.
- 14 Shatz H, Yannuzzi LA, Gitter KA. Subretinal neovascularization. In: Yannuzzi LA, Gitter KA, Shatz H, eds. *The macula*. Baltimore: Williams and Wilkins, 1979: 180–201.
- 15 Talmage DW, Rose B, Sherman WB, Vaughan JH. The cold agglutinin syndrome. In: Samter M, ed. *Immunological diseases*. Boston: Little, Brown, 1971: 471–4.

Accepted for publication 29 July 1985.