

Light microscopic and electron microscopic histopathology of an iris microhaemangioma

KERRIE V MEADES,¹ IAN C FRANCIS,¹ MEDDUMA B KAPPAGODA,¹
AND MARIJAN FILIPIC²

From the ¹Department of Ophthalmology, Concord Hospital, and the ²Department of Pathology, Sydney Eye Hospital, Sydney, Australia

SUMMARY A patient who had been observed to have an iris microhaemangioma (capillary haemangioma), confirmed on fluorescein iris angiography, came to cataract surgery. The lesion was excised at the time of surgery and submitted to light and electron microscopic study. It had the features of a hamartoma of the capillary haemangioma type, with its characteristics being specific for vessels seen in iris tissue.

Iris microhaemangiomas (IMHs) (capillary haemangiomas) are vascular tufts usually found at the pupillary margin, but occasionally they are situated in the anterior stroma. Usually they are found in older people (over 60 years) and are better seen with an undilated pupil. Their association with diabetes mellitus, chronic obstructive airways disease, and myotonic dystrophy has been noted.¹⁻⁴

Correspondence to Dr Ian C Francis, 8 Daisy Street, Chatswood NSW 2067, Australia.

IMHs consist of tightly coiled blood vessels with capillary-like walls, and have an overall size of 150 μ . They have also been described as an aggregation of blood vessels at the pupillary border,⁴ but there have been few histopathological studies. Amasio *et al*⁵: described them as abnormal blood vessels that destroyed and replaced iris stroma and were composed of fissures paved with endothelial cells. Both Ashton⁶ and Cashell⁷ described them as thin walled vessels, associated with some connective tissue.

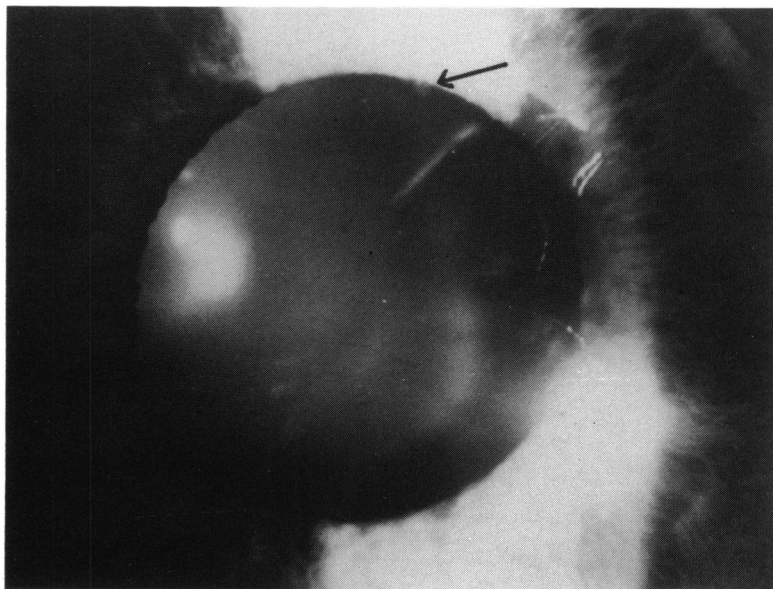


Fig. 1 Iris microhaemangioma on slit-lamp examination.

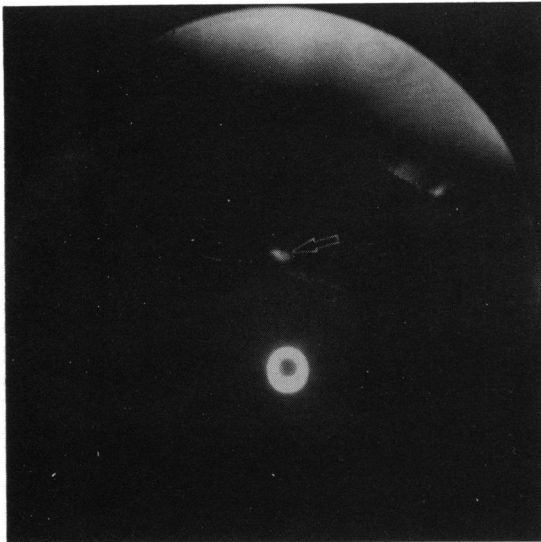


Fig. 2 Iris fluorescein angiogram.

Knapp⁸ thought that the endothelial cells proliferated, forming a nodular protuberance, and Anderson and Øther⁹ thought they were a cystic lesion caused by the dilatation of a vein.

Iris fluorescein angiography (IFA) has been used to investigate these lesions and help to distinguish them from vascular malignant melanomas.⁵ They are seen as multiple hyperfluorescent dots at the pupillary border,^{4,10} and IFA shows them to be more numerous than their appearance on slit-lamp examination suggests.¹¹ IFA has shown leakage from the vessels of the IMH into the aqueous,¹² but fluorescein leakage has also been noted from normal pupillary vessels with increasing age.^{13,14}

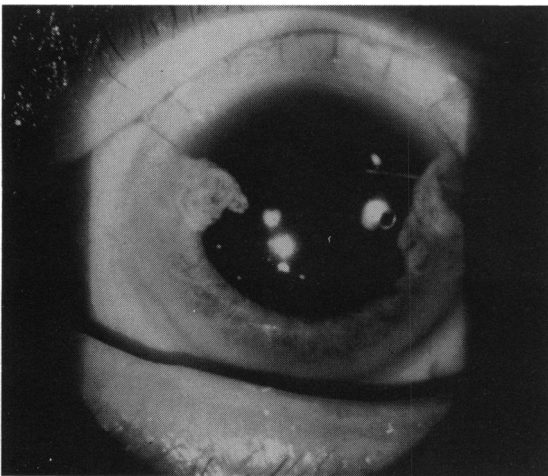


Fig. 3 Cataract extraction with posterior chamber intraocular lens and sector iridectomy.

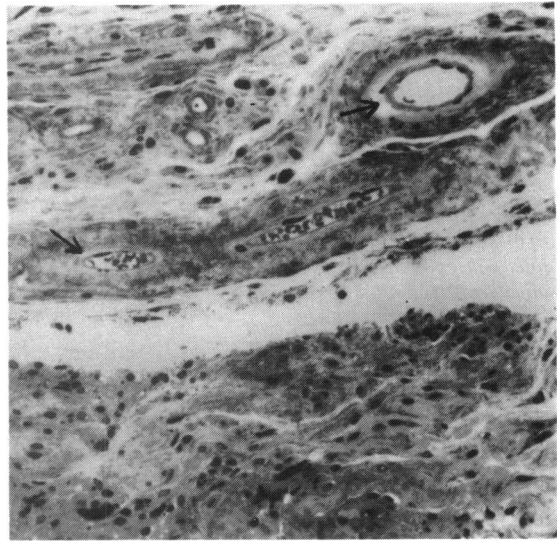


Fig. 4 Light photomicrograph of an IMH. Note the 'thick walls' (arrows) of normal iris stromal blood vessels. (Toluidine blue stain, $\times 256$).

IMHs are important clinically because they have been cited as a cause of spontaneous hyphaema and secondary glaucoma.^{1,15-17}

Case report

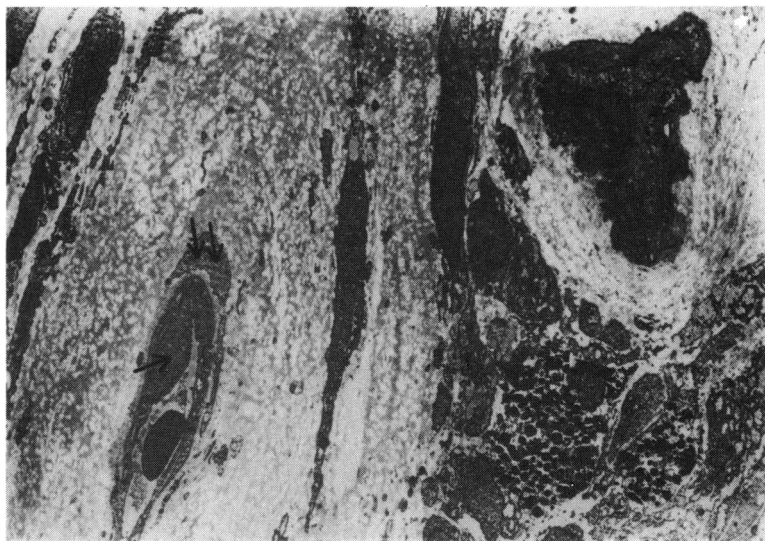
A 79-year-old male who had mild congestive failure and chronic obstructive airways disease and a history of glaucoma and cataracts was observed in 1980 to have a right IMH at 1 o'clock on the pupillary border (Fig. 1). The vascular nature of the lesion was confirmed on IFA (Fig. 2). The patient's vision was reduced to 6/12 part in the right eye, and 6/18 part in the left eye, owing to cataracts. He was on timolol drops for his chronic glaucoma, with intraocular pressures in the low teens. An IMH was visible on his left superior pupillary border also. He was visually asymptomatic at that time and remained so until two years later, when he presented for cataract surgery because of failing vision. His vision in the right eye at that stage was 6/24.

A right extracapsular cataract extraction with posterior chamber intraocular lens implantation and sector iridectomy was performed (Fig. 3). There were no operative or postoperative complications. The iridectomy enabled the IMH to be removed intact, and the specimen was submitted for light microscopic and electron microscopic histopathology.

RESULTS OF HISTOPATHOLOGY

Histologically an IMH appears to be a hamartoma (a mass of tissue normally found at the involved site)

Fig. 5 Electron photomicrograph of the stromal vessels of an IMH lined with endothelial cells (arrow) and pericytes (double arrow) in a basement membrane which connects with the surrounding tissue. ($\times 2000$).



composed primarily of iris stromal blood vessels. The 'thick walls' of these vessels, seen in the light photomicrograph (Fig. 4) are due to the arrangement of endothelial cells and pericytes surrounded by loose connective tissue.

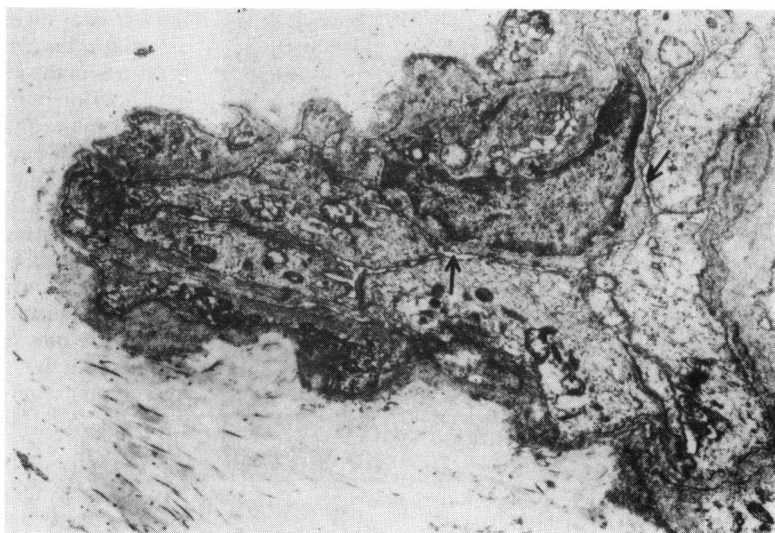
On electron microscopy these stromal vessels are lined with typical endothelial cells of normal thickness (Fig. 5) with no fenestrations, and joined at their apices by terminal bars composed of zonula occludens and zonula adherens. These terminal bars are better seen in Figs. 6 and 7. The apical portion (zonula occludens) consists of dense plasma membranes so closely apposed that there appears to be no intercellular space. The zonula adherens (on the

basal aspect of the zonula occludens) resembles a desmosome, but its intercellular space is narrower than that of a desmosome. Endothelial cells and pericytes lining the capillary are enveloped in a basement membrane, which connects with the surrounding loose connective tissue (Fig. 8).

Discussion

Normal iris capillaries have a bilaminar structure, with a loose connective tissue enclosing basement membrane, endothelial cells, and pericytes. This connective tissue connects the capillary with the surrounding iris stroma. Such a structure allows the

Fig. 6 The lumen of the vessel in the upper right of Fig. 5 is compressed to a branching slit (arrows). The apical junctions of the endothelial cell are intact. ($\times 5000$).



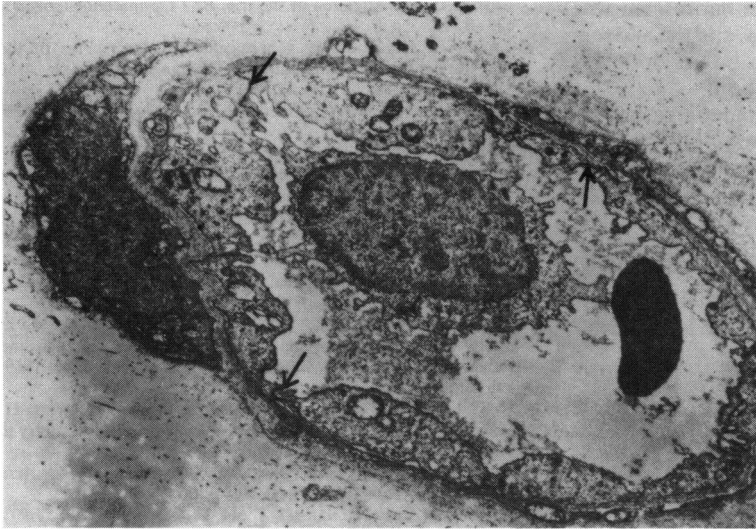


Fig. 7 The lumen of this stromal vessel in the IMH is open. Endothelial cells are joined at their apices by terminal bars (arrows). ($\times 5000$).

capillary to remain patent on movements of the iris and gives the stromal iris blood vessels a typical 'thick walled' appearance. The endothelial cells are non-fenestrated and are joined by terminal bars.

The histology of the IMH described therefore shows them to be hamartomas consisting of iris stromal blood vessels. This case report accurately describes the light microscopic findings and electron microscopic findings of this lesion.

Daidoff *et al.*¹⁸ described abnormal iris vessels in a peripheral lesion of the iris in a case of diffuse congenital haemangiomas, but this lesion was a cavernous haemangioma, not a microhaemangioma, and electron microscopy was not done on the iris

lesion. Knapp⁸ also described a case of generalised vascular naevi with abnormal blood vessels, but again this was a much larger lesion than an IMH.

Some authors^{5,6,9,19,20} have described the angiomatous blood vessels as being dilated with thinned endothelial cells invaded by connective tissue, but electron microscopic studies have not been performed.

In contrast, one electron microscopic study of iris neovascularisation by Ringvold and Davanger²¹ showed a narrowing of the blood vessel lumen with an increase in volume of the endothelial cells and tight junctions between the cells. The basement membrane was thin and broken, and the endothelial

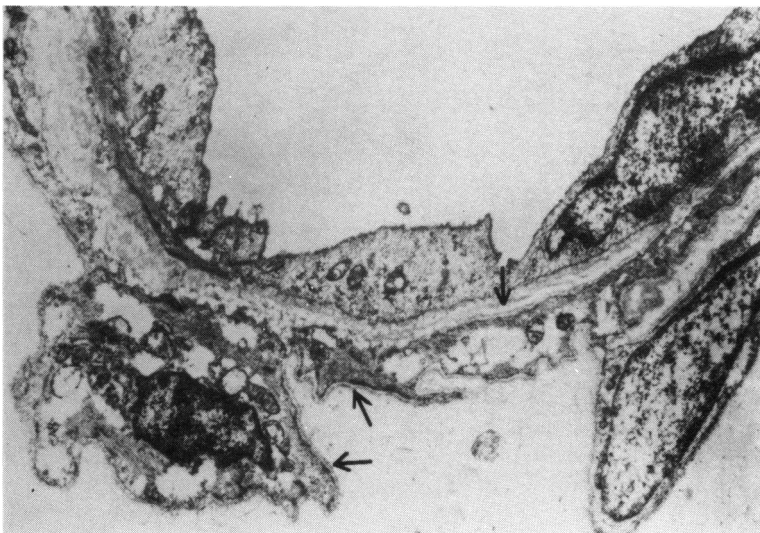


Fig. 8 Another stromal vessel lined with endothelial cells (with intact apical junctions) and pericytes enveloped in a basement membrane (arrows) connecting with the surrounding tissue. ($\times 5000$).

cells were fenestrated. On IFA the fluorescein was localised to the neovascularised area, and the appearance was attributed to gaps in the interendothelial junctions or to endothelial fenestration.

In cases of IMHs, IFA has sometimes shown leakage from angiomatic vessels,^{11,12} but this has also been seen in normal stromal blood vessels with increasing age.^{13,14} The leak can be explained by breaks in the endothelial cells rather than gaps between the cells.

In conclusion, we believe this to be the first electron microscopic description of an iris microhaemangioma, indicating it to be a true hamartoma of the iris stromal blood vessels.

We thank Miss Robyn Morgan for typing the manuscript in the preparation of this paper.

References

- 1 Francis IC, Kappagoda MB. Iris microhaemangiomas. *Aust J Ophthalmol* 1982; **10**: 167-71.
- 2 Cobb B. Vascular tufts at the pupillary margin: a preliminary report on 44 patients. *Trans Ophthalmol Soc UK* 1968; **88**: 211-21.
- 3 Cobb B, Shilling JS, Chisolm MB. Vascular tufts at the pupillary margin in myotonic dystrophy. *Br J Ophthalmol* 1970; **69**: 573-82.
- 4 Coleman SL, Green WR, Patz A. Vascular tufts of the pupillary margin of the iris. *Am J Ophthalmol* 1977; **83**: 881-3.
- 5 Amasio E, Brovarone FV, Musso M. Angioma of the iris. *Ophthalmologica* 1980; **180**: 15-8.
- 6 Ashton N. Primary tumours of the iris. *Br J Ophthalmol* 1964; **48**: 630-68.
- 7 Cashell GTW. Angioma of the iris. *Br J Ophthalmol* 1967; **51**: 633-5.
- 8 Knapp A. Glaucoma in generalised vascular naevus of the skin—report of case with angiomatic changes in the iris. *Arch Ophthalmol* 1928; **57**: 219-23.
- 9 Anderson SR, Øther A. Varix of the iris. *Arch Ophthalmol* 1975; **93**: 32-3.
- 10 Perry HD, Mallen FJ, Sussman W. Microhaemoangiomas of the iris with spontaneous hyphaema and acute glaucoma. *Br J Ophthalmol* 1977; **61**: 114-6.
- 11 Israel MP, Lorenzetti DWC. Bilateral microhaemangiomas of the pupillary border with later hyphaema. *Can J Ophthalmol* 1974; **9**: 138-40.
- 12 Rosen E, Lyons D. Microhemangiomas at the pupillary border. *Am J Ophthalmol* 1969; **67**: 846-53.
- 13 Vannas A. Fluorescein angiography of the vessels of the iris in pseudoexfoliation of the lens capsule, capsular glaucoma and some other forms of glaucoma. *Acta Ophthalmol (Kbh)* 1969; **105** (suppl): 9-75.
- 14 Van Nerom P, Rosenthal R, Jacobson D, Pieper I, Schwartz H, Greider BW. Iris angiography and aqueous photofluorometry in normal subjects. *Arch Ophthalmol* 1981; **99**: 489-93.
- 15 Sellman A. Hyphaema from microhaemangiomas. *Acta Ophthalmol (Kbh)* 1972; **50**: 58-61.
- 16 Magauran DM. Unilateral spontaneous hyphaema. *Br J Ophthalmol* 1973; **57**: 945-7.
- 17 Mason GI, Ferry AP. Bilateral spontaneous hyphema arising from iridic hemangiomas. *Ann Ophthalmol* 1979; **11**: 87-91.
- 18 Daidoff MA, Kenyon KR, Green WR. Iris hemangioma and abnormal retinal vasculature in a case of diffuse congenital hemangiomatosis. *Am J Ophthalmol* 1971; **72**: 633-44.
- 19 Savir H, Manor RS. Spontaneous hyphema and vessel anomaly. *Arch Ophthalmol* 1975; **93**: 1056-8.
- 20 Reese AB. *Tumours of the eye*. 2nd ed. New York: Hoeber, 1963.
- 21 Ringvold A, Davanger M. Iris neovascularisation in eyes with pseudoexfoliation syndrome. *Br J Ophthalmol* 1981; **65**: 138-41.

Accepted for publication 5 August 1985.