

## Diagnosis of orbital myositis by nuclear magnetic resonance imaging

H S DUA,<sup>1</sup> F W SMITH,<sup>2</sup> A K SINGH,<sup>1</sup> AND J V FORRESTER<sup>1</sup>

From the Departments of <sup>1</sup>Ophthalmology and <sup>2</sup>Nuclear Medicine, University of Aberdeen, Aberdeen Royal Infirmary, Foresterhill, Aberdeen

**SUMMARY** Two cases of orbital myositis are reported in which precise identification of the involved muscle was possible with the use of surface coil nuclear magnetic resonance (NMR) imaging. A clinical response to oral steroids in both cases coincided with a marked reduction in the abnormal thickening of the muscles as seen on the NMR images.

The diagnosis of orbital 'space occupying lesions' poses a considerable challenge to the clinical acumen of the treating surgeon. Over the years several techniques, both invasive and non-invasive, have been developed and employed to differentiate such lesions.<sup>1</sup> These have their own advantages and limitations and are often complementary to each other. The most recent innovation is nuclear magnetic resonance (NMR) imaging, and early impressions from clinical evidence indicate certain distinct advantages.<sup>2,3</sup>

NMR imaging of the ocular and orbital structures has been in use for four or five years.<sup>2-6</sup> In addition to being a non-invasive, non-ionising method for imaging soft tissue its chief advantage lies in its ability accurately to localise pathological lesions without artefactual interference from the bony tissue that surrounds the orbital structures on all four sides.<sup>3,7</sup> Apart from precise anatomical localisation, valuable information about the composition of tissues can also be obtained, in some situations, by studying the proton density (PD) and proton spin lattice relaxation time (T1) images.<sup>2,3</sup>

We report two cases of subacute orbital myositis in which precise localisation of the inflammatory process to the lateral rectus muscle was demonstrated by NMR imaging and a clinical response to oral steroids coincided with corresponding reduction in the muscle mass on the NMR images.

### Patients and methods

The patients were examined in the Aberdeen NMR

Correspondence to Professor J V Forrester, Department of Ophthalmology, University of Aberdeen, Polwarth Building, Foresterhill, Westburn Road, Aberdeen AB9 2AY.

imager, developed and built in the department of Bio-Medical Physics and Bio-Engineering at the University of Aberdeen. The imager is based on a four-coil, air-cored resistive magnet of 0.08 tesla which gives a resultant resonant frequency of 3.4 MHz for hydrogen protons. Data for each section, which may be either sagittal, coronal, or axial, are collected in 256 s by the 'spin-warp' method. The pulse sequence employed consists of readout pulses every 1000 ms with alternate readout pulses preceded by inversion. The inversion is accomplished by adiabatic fast passage with a continuous delay of 200 ms. In other words, the pulse sequence consists of interleaved saturation recovery (S1) and inversion recovery (S2) pulses (TR=1000 ms, T1=200 ms). After acquisition the data may be displayed as proton density, inversion recovery, or calculated T1 images on a grey-scale visual display unit. T1 is calculated for each element from the formula:  $T1 = 200 / \ln(2 \times S1 / (S1 - S2))$ .<sup>3</sup> The section thickness is 10 mm and sections are made at 5 mm increments, allowing for complete examinations of the orbit.

### CASE 1

A 53-year-old male was admitted with an eight-day history of redness and swelling of the right eye. The lids were oedematous and the conjunctiva congested and chemosed, especially over the insertion of the lateral rectus muscle. The globe showed a relative proptosis of 3 mm with increased orbital resistance. The eye was deviated nasally by 10 prism dioptres, and abduction was considerably restricted, with diplopia on dextroversion. The eyeball was normal in all other respects. The x-rays of the orbits and results of haematological investigations, serum biochemistry, and thyroid function tests were all normal.

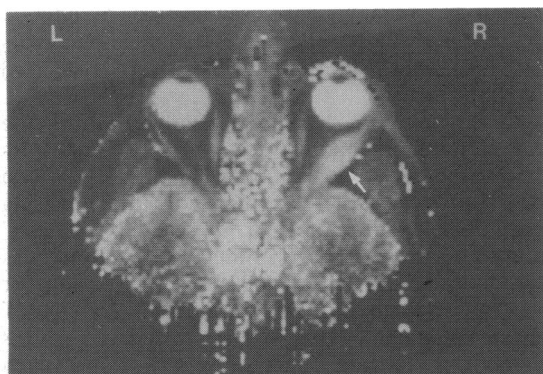


Fig. 1 NMR image (calculated T1; long T1=white; short T1=black) of case 1 showing a fusiform enlargement of the right lateral rectus muscle (arrow).

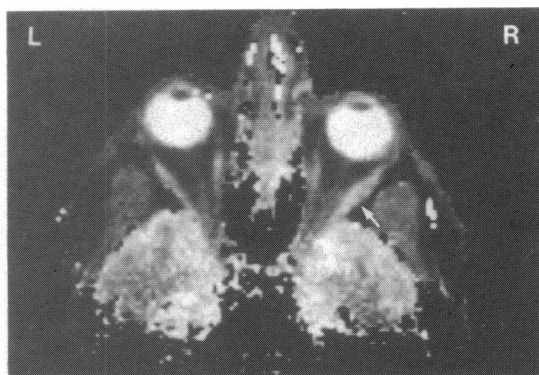


Fig. 3 Calculated T1 image of case 1 performed 17 days after treatment with oral steroids. Note the considerable reduction in size of the right lateral rectus muscle (arrow).

NMR scans of the orbit with a surface coil showed a gross fusiform enlargement of the right lateral rectus muscle (Fig. 1). A CT scan was also carried out. This showed the muscle to be enlarged, but the image was less well defined (Fig. 2). It failed to show the full extent of the muscle swelling. The patient was treated with 40 mg of prednisolone daily by mouth. Clinical improvement occurred rapidly, with recovery of the lateral rectus muscle function and decreased chemosis and congestion within a week. The steroid dose was gradually reduced to 20 mg per day. A follow-up NMR scan, 17 days after admission showed marked reduction in the thickness of the lateral rectus muscle (Fig. 3).

#### CASE 2

A 55-year-old female was referred with complaints of watering, redness, and swelling of the right eye of five days' duration. A history of eyelid/ocular contact with an insect some 24 hours previously was elicited,

and she had been treated for angioneurotic oedema with topical steroids by her general practitioner. Ocular examination revealed lid oedema with considerable conjunctival chemosis and congestion. There was no proptosis and only a slight restriction of abduction of the right eye. The eyeball was normal in all other respects. X-rays of the orbit, haematological investigations, serum biochemistry, and thyroid function tests were normal. Surface coil NMR imaging of the orbits revealed a gross thickening of the right lateral rectus muscle (Fig. 4). A CT scan of the orbit also showed the muscle enlargement (Fig. 5), but, as in the first case, the latter method did not demonstrate the full extent of the muscle swelling. She was treated with 20 mg of oral prednisolone daily, and clinical improvement was observed within the first week. The eye could be fully abducted and the chemosis and congestion had subsided. She was discharged and the steroid dose reduced over the following weeks. A repeat NMR scan was performed

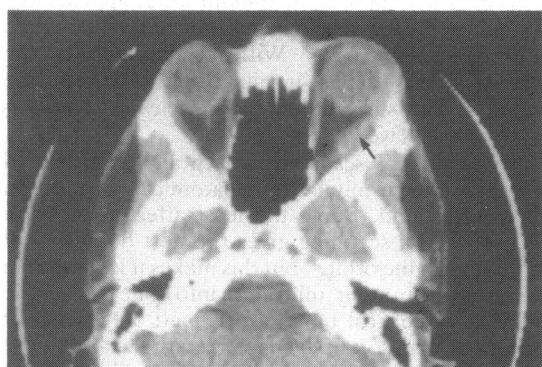

Fig. 2 CT scan of case 1 showing enlargement of right lateral rectus muscle (arrow). The fusiform shape is not very obvious and the outlines are not clearly defined.

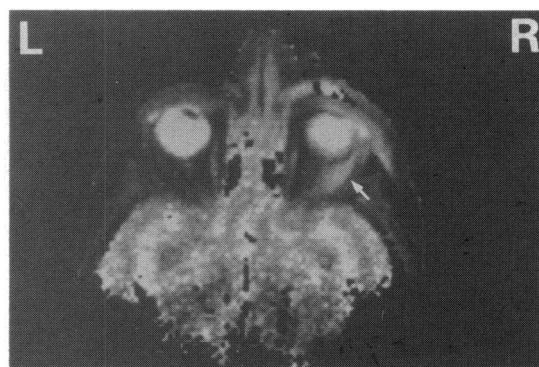


Fig. 4 Calculated T1 image of case 2 showing a fusiform enlargement of the right lateral rectus muscle (arrow).

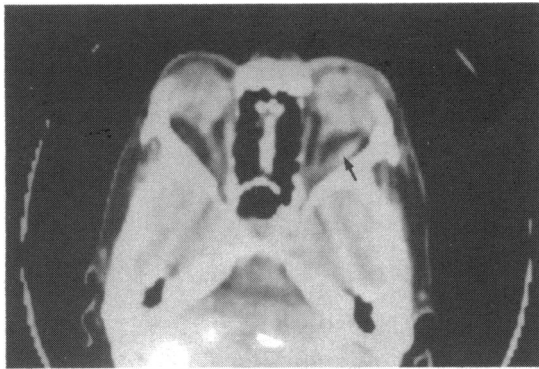


Fig. 5 CT scan of case 2 demonstrating a thickened and enlarged right lateral rectus muscle (arrow). Note that muscle enlargement appears less by this technique.

six weeks after admission and showed a complete resolution of the earlier lesion in the lateral rectus muscle (Fig. 6).

#### Discussion

Orbital fat, because of its relatively high hydrogen ion content, gives a very dark shadow on the T1 NMR image. This provides an excellent contrast for delineating outlines of other soft tissue structures such as muscle and nerve, both of which have a low hydrogen ion concentration and appear white or light grey. The extraocular muscles appear as thin strap-like structures running from the apex of the orbit to the wall of the globe, and the nerve forms a sinuous image within the cone formed by the muscles.<sup>3,6</sup> With the improved images produced by a surface coil other orbital structures such as branches of the trigeminal nerve and the ophthalmic vessels can be delineated.<sup>6</sup> The coats of the eye—sclera, choroid, and retina—

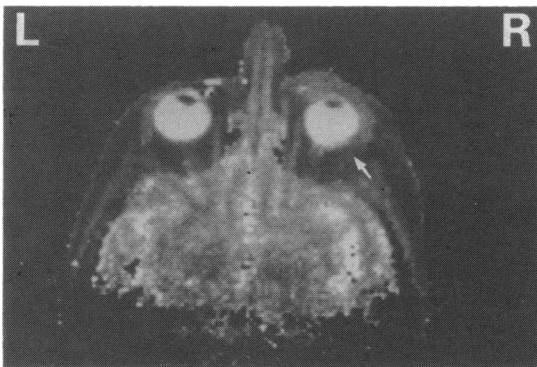


Fig. 6 Calculated T1 image of case 2 performed six weeks after treatment with oral steroids. Note the complete resolution of the muscle swelling (arrow).

appear as a homogeneous grey layer surrounding a dense white vitreous and the crystalline lens appears black. The bony orbital wall is not clearly visualised on the T1 image.<sup>3</sup>

Orbital myositis has been classified within the category of 'pseudotumours' of the orbit.<sup>18</sup> Its cardinal feature is a painful swelling usually of one ocular muscle. Other common conditions causing enlargement of extraocular muscles are Graves' disease, chronic inflammatory granulomas (pseudotumours), and neoplasms, either primary or secondary.<sup>9</sup> With the advent of ultrasonography, CT scanning, and now NMR imaging a precise diagnosis of myositis is possible, and it should be regarded as a distinct clinical entity.<sup>9</sup> The condition responds dramatically to systemic steroids, as illustrated by the above cases. It is important therefore to diagnose the condition with reasonable accuracy and attempt a trial of steroids before embarking on more invasive investigative and therapeutic measures.

In Graves' disease ocular muscle enlargement is uniform along the muscle length, and usually more than one muscle is involved. The degree of muscle involvement, however, is asymmetrical, some muscles being involved more than others. Increase in amount and anterior displacement of the orbital fat with forward bowing of the orbital septum are additional features.

In orbital myositis swelling may affect only a segment of the muscle, giving it a fusiform appearance, and usually only one muscle is involved.<sup>9</sup> This is demonstrated in both the cases presented (Figs. 1 and 4).

Differentiation of ocular muscle disorders from orbital neoplasia and pseudotumours is usually a simple task by NMR or CT scanning. Lymphoma, lymphosarcoma, and metastatic deposits usually present with a mass adjacent to or compressing the extraocular muscle or infiltrating its substance.<sup>9</sup> With metastatic carcinomas the tumour tissue appears as a discrete deposit with a longer T1 relaxation time than the adjacent muscle.<sup>3</sup> With pseudotumours the lesions appear as an irregular infiltration of the orbital tissues surrounding the muscle and are comparatively less well delineated.<sup>3</sup>

NMR and CT scans give sharp and well defined images, and permit better anatomical localisation than ultrasound. Being the least affected by bone images, NMR scanning gives the best definition of structures in the orbit,<sup>3,6</sup> but this makes it less suitable for detecting tumour infiltration into bone tissue. The margins of cortical bone are defined only where it interfaces with soft tissue and not with the air.<sup>3</sup> NMR also fails to demonstrate soft tissue calcification, for example in orbital granulomas, varices, and benign neoplasms. Small lesions of 1 or 2 mm diameter

cannot be visualised by any of these techniques.<sup>3</sup> Multiplanar imaging is possible with NMR and CT scanning, but the increased radiation dose involved in multiplanar CT scanning is avoided in NMR imaging.<sup>5</sup> High doses of radiation may result from faulty collimation when a large number of fine sections are obtained for reformatting purposes. This is a definite advantage of NMR techniques. Prolonged or repeated NMR imaging has not shown any untoward effects.<sup>10</sup> This makes the technique very suitable for monitoring the progress of a lesion and its response to therapy. Since the T1 relaxation time and the proton density image of tissues vary according to their hydrogen atom content, valuable information on changes in composition of some tissues can now be obtained by NMR imaging. This was hitherto impossible except by biopsy.

The use of surface coils in NMR imaging has considerable potential in ocular and orbital diagnosis.<sup>3,6</sup> This will be realised as more clinical experience is gained with this technique and the technique itself is further refined. Improved spatial resolution of images by decreasing pixel size and section thickness is possible with magnets of high magnetic field strength. Study of substances other than hydrogen, such as sodium, potassium, and fluorine, may also be possible and may give further insight into tissue

composition and probably increase the range over which tissue differentiation is possible.

#### References

- 1 Ashworth B, Isherwood I. *Clinical Neuro-ophthalmology*. Oxford: Blackwell, 1981: 81.
- 2 Moseley I, Brant-Zawadzki M, Mills C. Nuclear magnetic resonance imaging of the orbit. *Br J Ophthalmol* 1983; **67**: 333–42.
- 3 Smith FW, Cherryman GR, Singh AK, Forrester JV. Nuclear magnetic resonance tomography of the orbit at 3.4 MHz. *Br J Radiol* 1985; **58**: 947–57.
- 4 Hans JS, Benson JE, Onstelle CT, Alfidi RJ, Kaufman B, Levine M. Magnetic resonance imaging of the orbit. A preliminary experience. *Radiology* 1984; **150**: 755–9.
- 5 Hawles RC, Holland GN, Moore WS, Rizk S, Worthington BS, Kean DM. NMR imaging in the evaluation of orbital tumors. *Am J Neuroradiol* 1983; **4**: 254–6.
- 6 Zimmerman RA, Bilaniuk LT, Yanoff M, *et al*. Orbital magnetic resonance imaging. *Am J Ophthalmol* 1985; **100**: 312–7.
- 7 Morrice GD, Smith FW. Early experience with nuclear magnetic resonance (NMR) imaging in the investigation of ocular proptosis. *Trans Ophthalmol Soc UK* 1983; **103**: 143–54.
- 8 Wilner HI, Gupta KL, Kelly JK. Orbital pseudotumor: association of orbital vein deformities and myositis. *Am J Neuroradiol* 1980; **1**: 305–9.
- 9 Trokel SL, Hilal SK. Recognition and differential diagnosis of enlarged extraocular muscles in computed tomography. *Am J Ophthalmol* 1979; **81**: 503–12.
- 10 Reid A, Smith FW, Hutchison JMS. Nuclear magnetic resonance imaging and its implications. *Br J Radiol* 1982; **55**: 784–6.

Accepted for publication 24 April 1986.