

# Perinuclear lens retrodots: a role for ascorbate in cataractogenesis

A J BRON AND N A P BROWN

From the Nuffield Laboratory of Ophthalmology, Walton Street, Oxford OX2 6AW

**SUMMARY** Lens retrodots are round, oblong, or oval features in the perinuclear zone of the adult lens after the fifth decade of life and associated with cataract. Retrodots were found in 47 out of 121 eyes with cataract (39%) in the present series. They show birefringence *in vivo* and *in vitro*, and chemical studies suggest that they contain calcium oxalate. It is proposed that ascorbic acid, which is abundant in the normal human lens, is the most likely source for this oxalate. Ascorbic acid is thought to have a protective role against oxidative stress in the lens and other parts of the eye, and its level is known to be reduced in senile cataract. The presence of the retrodots may identify lenses which have been exposed to oxidative stress and are less capable of resisting oxidative damage.

Vogt described a feature seen in the adult lens by specular microscopy with the slit-lamp.<sup>1,2</sup> He observed a 'relief pattern' of knobs and bumps softly delineated from the adjacent cortex and distributed over the anterior perinuclear surface. With Lussi he prepared accurate models of these changes.<sup>3</sup> Reese and Wadsworth,<sup>4</sup> unaware of these studies, reported a change found in the anterior and posterior surfaces of the adult lens which they termed 'cystoid spaces', stating them to be present in 10% of otherwise normal lenses, though they did not define their population. A further report by Bron and Matsuda<sup>5</sup> and a more detailed paper by Bron and Brown<sup>6</sup> termed these changes 'retrodot' lens opacities because of their ease of visibility against the red reflex in contrast to their poor visibility by focal slit-lamp illumination. They emphasised that the features are seen by both retro and specular modes of illumination. All authors are agreed that the isolated changes have only a small effect on vision.

In this paper these features are discussed in detail and an attempt is made to relate them to certain other chemically characterised lens opacities.

## Definitions of lens zones

The literature abounds in different definitions of the zones of the lens. This often leads to descriptive confusion. The definition used here is as follows.<sup>6</sup> The lens consists of nucleus and cortex (Fig. 1).

## NUCLEUS

The 'nucleus' in this paper will be taken to be that portion of the central lens (e.g., in the adult) which represents the lens at birth. Since the lens at birth has a diameter of approximately 6.0 mm, this is the size of the lens nucleus as defined here. It is implicit in this terminology that all lens fibres added after birth will be designated 'cortex'. This approach avoids the

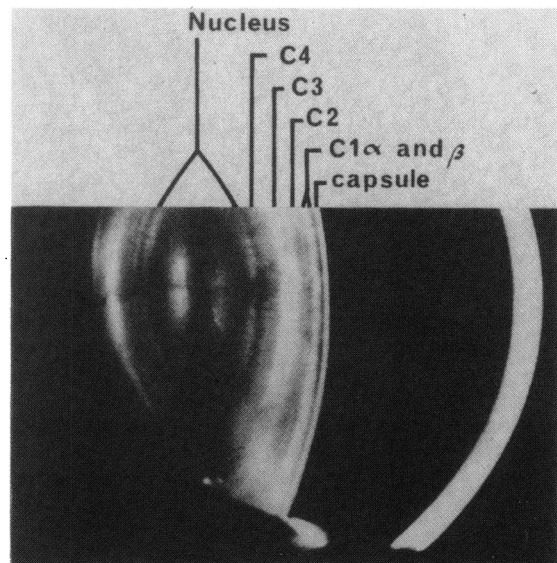


Fig. 1 Classification of the zones of the adult lens.

Correspondence to Mr A J Bron.

confusion which arises from such terms as 'infantile nucleus', representing the size of the lens at some time in infancy. Clearly such an approach results in the same part of the lens being referred to as cortex in youth and nucleus in later life.

The lens nucleus as described here is well demarcated optically from subsequent cortical layers and is that part of the lens which in later life first develops the colouring and scattering changes commonly referred to as nuclear sclerosis. This approach therefore has both descriptive value and probably biological significance.

#### CORTEX

In the young adult lens the cortex displays four optically distinct layers in the slit beam. These layers are retained throughout life, though they become subdivided by the acquisition of further optical zones of discontinuity.

The outer two zones (C1 and C2) are designated superficial cortex, while the inner two (C3 and C4) are termed the deep or perinuclear cortex. (Zone C1 includes a clear zone C1<sub>α</sub>, and the first bright band or zone of disjunction which is designated C1<sub>β</sub>). Perinuclear cortex has the distinction of being strongly autofluorescent, emitting a bright apple green fluorescence when stimulated with blue light.<sup>7</sup> This autofluorescence falls off abruptly to either side of C3 and C4 (that is, it is less marked in the nucleus and in C1 and C2). Autofluorescence may be appreciated by means of the standard blue exciting source of the slit-lamp—for example, combined with a Kodak Wratten No. 15 yellow barrier filter.

#### Methods of examination

*Focal illumination* uses a broad slit beam and examines the scattering properties of the lens. The common focal dot opacities of the lens are best seen in focal illumination.

*Slit examination* employs a narrow beam and examines the lens in optical section.

*Red reflex examination.* (a) Conventional retroillumination directs a broad vertical beam through the pupil at one side and provides indirect retroillumination. (b) The Fincham-Kawara system employs for example a Zeiss Photo-Slit Lamp whose optical head has been removed. Light is directed centrally through the pupil by a 45° glass plate, the incident beam passing through a polarising filter. The reflected beam passes through a further polarising filter at right angles to the first. This arrangement blocks out the corneal reflection but, since light returning from the fundus is no longer polarised the red reflex may be viewed though the luminosity is reduced.<sup>8,9</sup> A modified system is used here.

*Specular microscopy.* Changes in contour are observed when light is reflected from a refractive interface.

#### Features of lens retrodots

##### DEFINITION

Lens retrodots are small, discrete, smooth contoured features located anteriorly and posteriorly in cortical zones C3 and C4. They are seen well by retroillumination and specular microscopy and less well by focal illumination.

##### SHAPE AND SIZE

Retrodots seen against the red reflex are round, oblong, or oval or sometimes have a lobular appearance suggesting coalescence of adjacent lesions, or superimposition of opacities lying at different depths (Figs. 2, 3). Probably both forms occur. Their contours are always smooth. They vary in apparent size from 80 μm to 500 μm with a modal value of about 300 μm (measured on red reflex photographs without correction for magnification). The anterior retrodots are more easily seen than the posterior retrodots, a point also noted by Reese and Wadsworth.<sup>4</sup>

##### DISTRIBUTION AND LOCALISATION

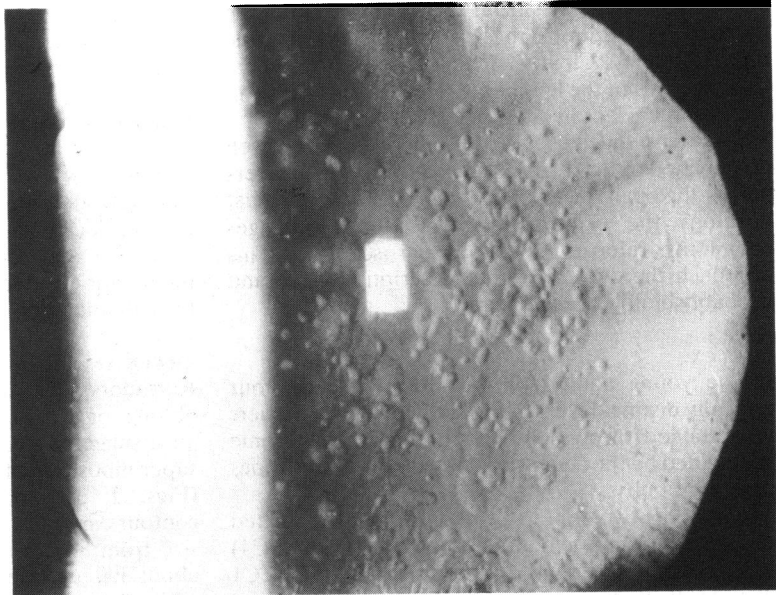
It may be easily seen in the red reflex that the retrodots are disposed in a circular or somewhat spiral manner, concentric with the anteroposterior axis of the lens and suggesting a relationship to the fibre arrangement (Figs. 2, 3). The long axis of the oval retrodots is often also concentric in the same way. The dots are located at varying depths in a continuous anterior and posterior shell of cortex at the level of C<sub>3</sub> and C<sub>4</sub> and may also be observed in the superficial layers of the nucleus. The lens may show one or two, or there may be a crowded field of retrodots in roughly the same plane. In one patient, aged 71 years, 400 were counted in a single lens in the anterior perinuclear cortex. Peripheral dots are often smaller than central dots. Small peripheral dots may sometimes be seen so far peripherally that it is likely they reside outside perinuclear cortex and therefore in C<sub>2</sub>.

##### OPTICAL FEATURES

###### *Retroillumination* (Figs. 2, 3, 4)

In the red reflex the dots may be clear in content, and, if the light source is offset with conventional, indirect retroillumination, the pattern of luminosity is reversed, that is, the dots exhibit a light and a dark zone, with the light zone on the *opposite* side to the retinal illumination. This is in contrast with the pattern created by lens vacuoles, which is unreversed

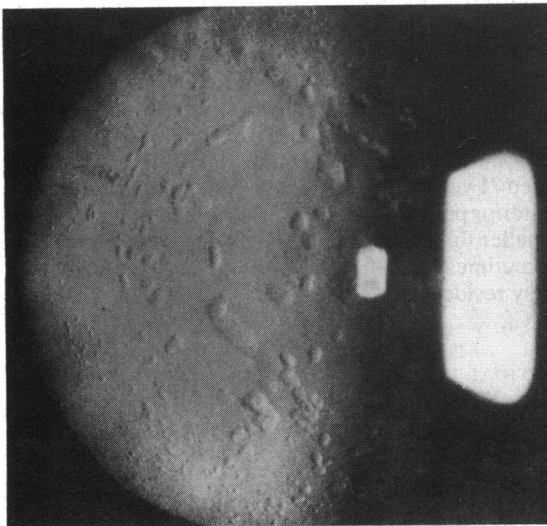
**Fig. 2** Multiple retrodots in a 71-year-old lens by indirect retroillumination.



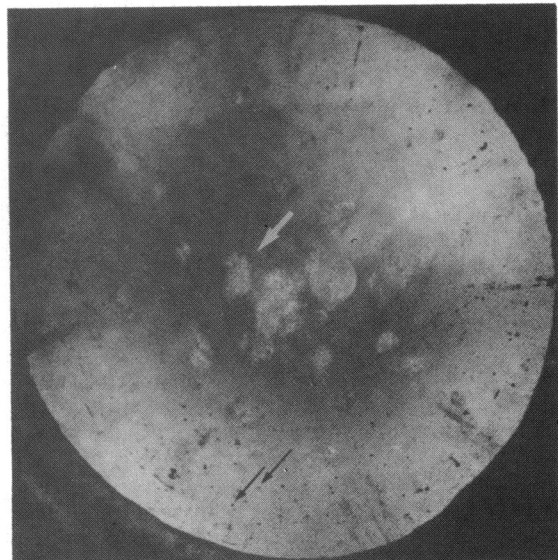
(that is, with the light field on the same side as the illumination source). The unreversed pattern is thought to be generated by an optical medium of lower refractive index than its surrounding, while the reversed pattern is generated by a medium of higher refractive index.<sup>10</sup> At times the dots may appear slightly opaque and granular. Sometimes they have a tiny dark dot within the substance, seen against the red reflex. At other times, when the illumination

source is angled to give a relatively dark red reflex, the retrodots may appear bright and relatively opaque (Fig. 4a). This probably occurs when the structures are illuminated more obliquely.

If the lens is viewed with crossed polarisers, the retrodots are either less visible than when viewed



**Fig. 3** A less obvious example of retrodots in a 69-year-old lens. These are easily overlooked unless a careful search is made with indirect retroillumination.



**Fig. 4a** Retrodot lens opacities showing a bright crystalline birefringent structure by retroillumination in polarised light (same eye as in Fig. 2). Focal dot opacities are seen in the periphery of this lens as dark silhouettes. (The perfectly round light is an artefact.) Patient aged 81.




Fig. 4b Retrodots appearing as dark 'butterflies' in polarised light in the presence of nuclear sclerosis. Retrodots arrowed.

by the conventional mode or they show a highly luminous profile, appearing as bright points of whitish light, often with a punctate pattern, against the red reflex. This appearance suggests that they exhibit birefringence and are visible by reflection and rotation of the ingredient polarised light. In some circum-

stances, in the presence of a scattering nucleus, they appear as dark 'butterflies' on a light ground (4b).

*Slit illumination*

Retrodots are not always visible by slit illumination. However, they may be visible as narrow crescentic or narrow oval slits most readily demonstrated when they occur in association with nuclear sclerosis. Then they are seen as clear, dark, 'cystoid' spaces against a coloured and highly scattering ground. These cystoid spaces are usually at the level of C<sub>3</sub> and C<sub>4</sub> anteriorly and posteriorly, but may also be found occasionally in the superficial nucleus (Figs. 5 and 6).

*Focal illumination*

In focal light the retrodots are invisible, or faintly visible as an opalescent structure. This scattering is never marked. Occasionally, when the retrodots are associated with a marked nuclear scattering, a single polarising filter placed in the incident beam will render the dots visible as a dark granular opacity seen against the bright scattering ground; with rotation of the polariser the opacities may then be made to disappear (Fig. 7).

*Specular illumination*

The anterior retrodots are visible by specular microscopy as elevations convex forwards (Fig. 7). Their visibility is enhanced with increasing age, when so-called lamellar separation of the cortical layers increases the specular features of the anterior cortex. The margins of the retrodots are less well defined by

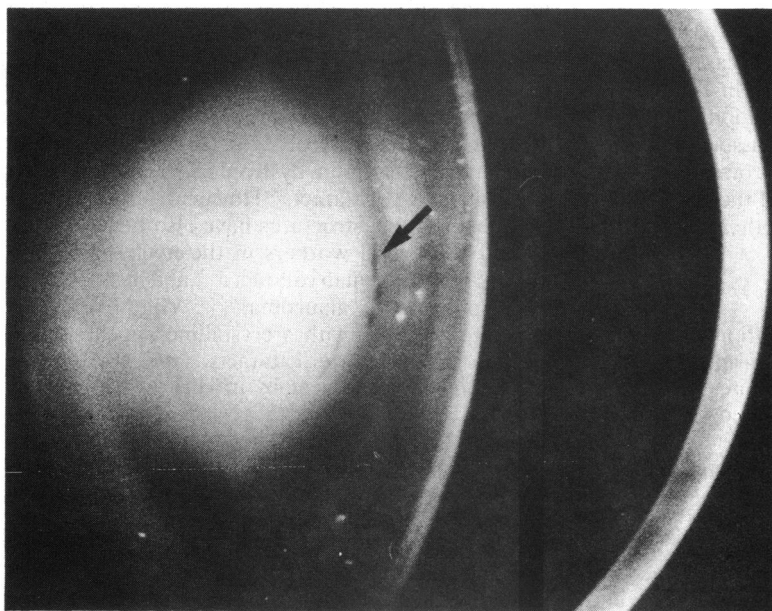
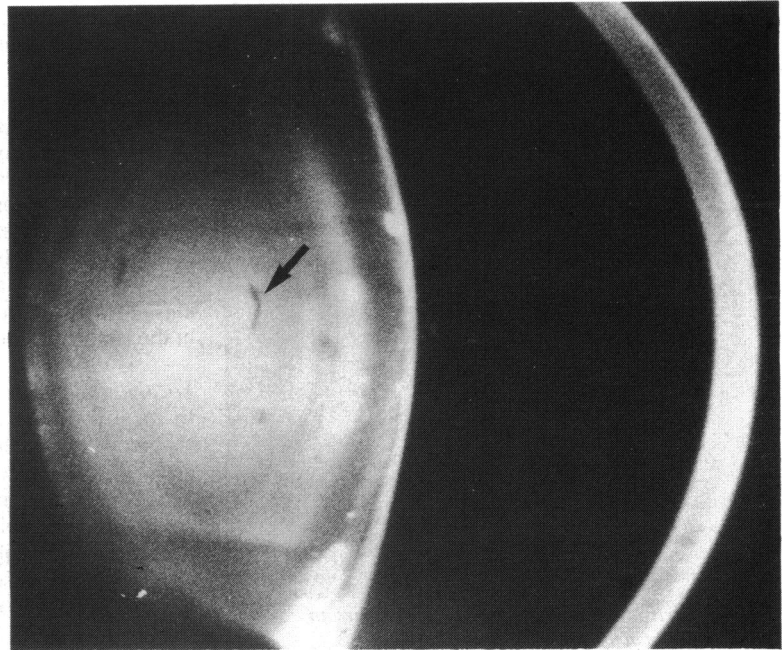


Fig. 5 A slit image picture in which the presence of retrodot opacities is shown by clear clefts in the anterior perinuclear region of the lens cortex (arrowed). This lens also shows marked nuclear sclerosis.

Fig. 6 Slit image picture of a 71-year-old lens showing retrodots in the perinuclear cortex and also clefts within the nucleus, which are presumed to represent more deeply situated retrodots.



specular microscopy than in the red reflex. Posterior retrodots are not seen by specular microscopy.

With the various modes of illumination discussed the impression is created of a discoid structure lying in the perinuclear cortex, flattened in the plane of adjacent layers of lens fibres, and whose superficial surface is convex towards the surface of the lens.

#### ASSOCIATED LENS CHANGES

In 73 clinic and ward patients with cataract (aged 35–93 years) retrodots were observed in 47 out of 121 eyes (39%). As the sample is non-random, no special conclusions can be drawn from this association other than that retrodot changes are common, but a population study is in progress and the relationship between retrodot changes and other cataractous changes is being studied.

#### VISION

When lens retrodots occur in isolation or in small numbers, they have no effect on vision. In larger numbers they may cause a more definite reduction to the 6/9 region. When they are associated with nuclear sclerosis it appears that visual function may be more seriously affected than when either occurs alone.

#### ONSET AND PROGRESSION

Retrodots appear to be acquired in the 40s, in the presbyopic period. It is likely that they increase in number over time, but, though Reese and

Wadsworth<sup>4</sup> state that they progress, their natural history is not fully known.

#### Discussion

The structures described here are the same as those described by Vogt<sup>1,2</sup> and Reese and Wadsworth<sup>4</sup> in the living subject. They are rare before the fifth decade and occupy chiefly the perinuclear cortex. Retrodots are optically denser than the surrounding normal lens and are birefringent.

Brightly reflective structures in the lens<sup>11</sup> have been attributed to cholesterol<sup>12,13</sup> or to a non-crystalline lamellar structure<sup>14</sup> in dystrophia myotonica or in 'christmas tree' cataract.<sup>15</sup> However, crystalline or pseudocrystalline structures have also been demonstrated by several workers in the nuclei of hypermature or morgagnian cataracts<sup>16–20</sup> and in association with phacolytic glaucoma.<sup>21–23</sup> Vogt<sup>2</sup> observed punctate opacities with a crystalline appearance *in vivo* in hypermature cataracts, and these were studied in the same year by *in vitro* microscopy by Wessley,<sup>24</sup> who termed these objects spheroliths. They have been further studied in recent years.<sup>25,26</sup>

The chemical nature of these crystalline bodies has been demonstrated by a number of authors to be calcium oxalate.<sup>17,18,21,23</sup> Flocks *et al.*,<sup>21</sup> Zimmerman and Johnson,<sup>17</sup> Goldberg,<sup>23</sup> and Bron and Habgood<sup>18</sup> examined the bodies found *in vitro* within morgagnian lenses, while Pau<sup>20</sup> studied spheroliths known to be

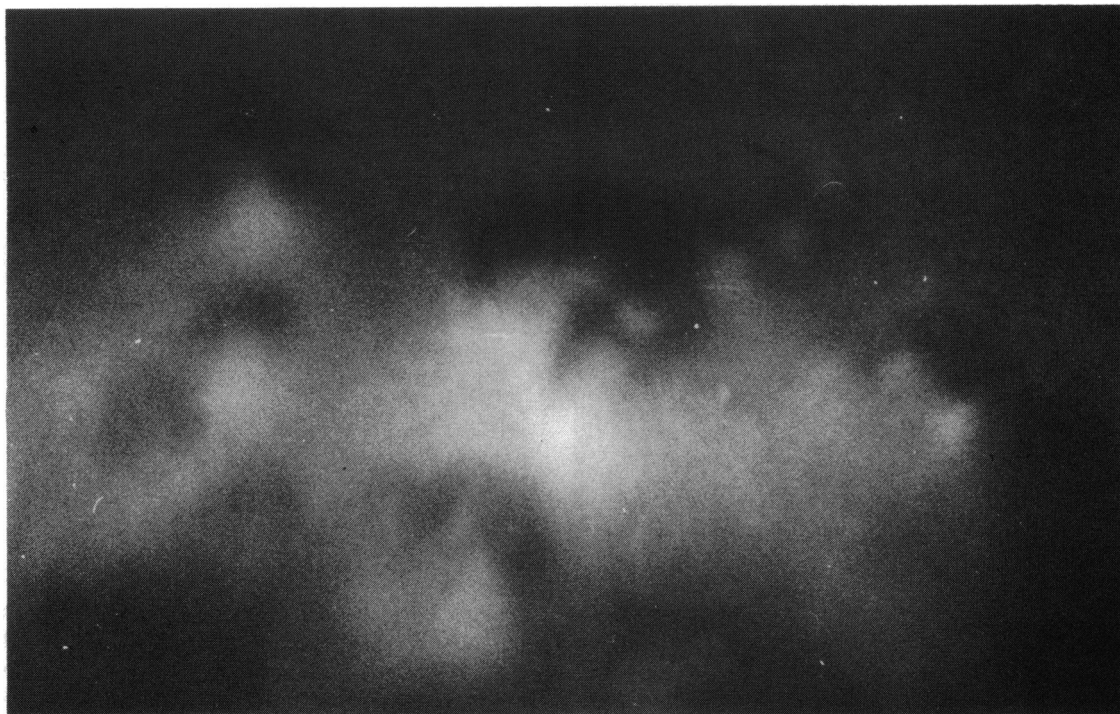


Fig. 7 Photomacrograph by specular illumination of the anterior nuclear face showing retrodots as small elevations. (Brown macrocamera at a primary magnification of 15 times.)

present in vivo. Harding *et al.*<sup>27</sup> identified bodies within fresh cataractous lenses in vitro documented by the stereo photographic procedure of the collaborative cataract research group (CCRG). The latter authors noted the value of crossed polarising filters in the system to make the features visible. Using energy dispersion *x*-ray analysis (EDXA), they found the opacities to be high in calcium, low in sulphur, and lacking in phosphate. Microchemical analysis suggested the presence of oxalate. Histologically the bodies were 'spheroidal' in cross section. They raised the question whether such opacities might be identified in the living patient, and it is our contention that the bodies which we have called retrodots are related to the spheroliths of the German literature and are identical to the calcium-containing, birefringent bodies observed by Harding *et al.*<sup>27</sup> We can regularly show that the bodies described by us as retrodots in vivo are strikingly birefringent in vitro in the extracted lens (Figs. 8a, b).

The bodies described here as retrodots are disc-shaped, being flattened from before backwards. This flattened shape is probably determined by the concentric lamellar arrangement of the lens fibres, which could affect either the direction of growth of these structures or mould their shape if they are sufficiently

fluid at some stage. The birefringence of these structures suggests that they contain a birefringent, crystalline material probably identical to the oxalate bodies of morgagnian cataract (the spheroliths of the German literature) and the oxalate bodies observed by Harding *et al.*<sup>27</sup> But certain differences do exist. Spheroliths are described in the lens nucleus, while retrodots are found mainly in the deep lens cortex, but also in the nucleus. The difference here may merely be one of definition. As nuclear sclerosis advances, so the brunescence colour change often extends to affect the deep cortex. However, spheroliths found in a morgagnian cataract are distinctly spherical and therefore are morphologically different from retrodots. Also, where the retroillumination characteristics of spheroliths have been recorded, they have been described as dark, and in this characteristic too are clearly different from retrodots.<sup>25</sup> Since both lesions are birefringent it is tempting to conclude that they are related, and, since spheroliths are most common in association with advanced cataract, it is reasonable to hypothesise that the retrodots are a precursor of the spheroliths.

There thus now seems to be good evidence that the material within the retrodot is calcium oxalate, and it is reasonable to consider ascorbic acid as its source

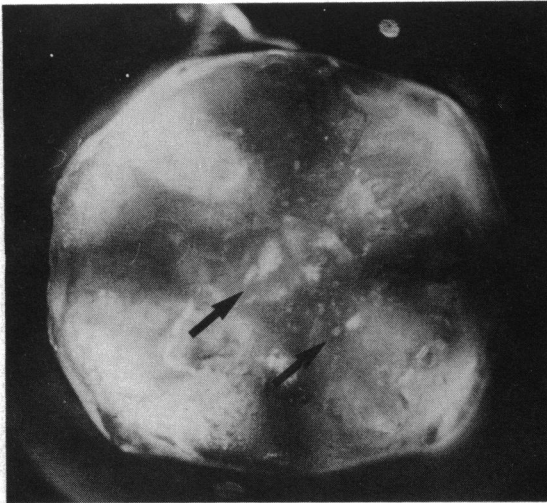


Fig. 8a *Retrodots demonstrated in the cataractous lens in vivo are shown here to be highly birefringent in the extracted lens under crossed polarisers (arrowed). Birefringence of the whole lens is visible as a dark 'Maltese cross'.*

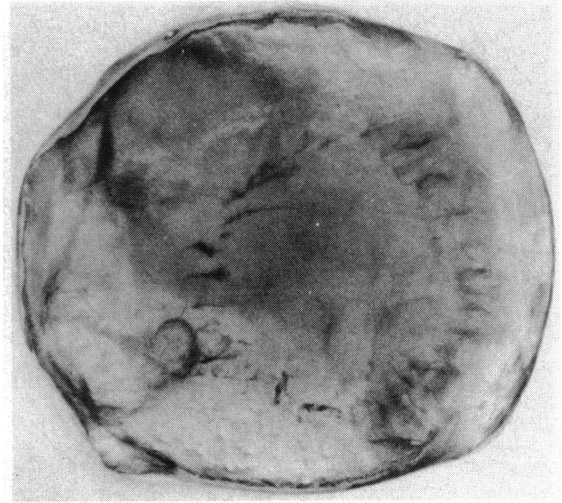


Fig. 8b. *Without crossed polarisers the retrodots are not visible in this system.*

for a number of reasons. Ascorbic acid is abundant in human adult aqueous and lens.<sup>27-31</sup> In man, monkey, and rabbit prenatal levels are low and similar to plasma levels (0.05 mM).<sup>32</sup> However, postnatal levels are about 20–40 times the plasma levels (1–1.8 mM)<sup>32</sup> as a result of active secretion by the ciliary epithelium.<sup>33</sup> In some animals of chiefly nocturnal habit aqueous ascorbate levels are low (rat, trace; galago, 0.03; and cat, 0.07 mM), and it has been suggested that this is an adaptive difference reflecting an antiphototo-oxidative role of ascorbic acid in the eye.<sup>34,35</sup> Differences in ascorbate levels between lens and plasma do not depend on the ability to synthesise ascorbate, since rat lens levels are high, though there is no synthetic ability. Human lens levels have been said to exceed aqueous levels, but a mechanism for this is not clear.<sup>35,36</sup>

Ascorbic acid has a role as a cofactor in a post-translational step of collagen biosynthesis,<sup>36</sup> and in the maintenance of intercellular ground substance material.<sup>37,38</sup> Apart from this it is a component of a protective system against damage by oxygen and free radicals derived from photo-oxidation. The most significant of these systems is the glutathione system in conjunction with glutathione peroxidase, superoxide dismutase, and ascorbic acid.<sup>39</sup> A number of workers have noted a drop in lens ascorbate levels associated with age,<sup>29,30</sup> and in experimental cataract and human senile cataract.<sup>40-53</sup> There is a greater fall in mature than immature cataractous lenses. Some workers have proposed an aetiological role for this fall of ascorbate in senile cataract with dietary

implications, while others have denied this.<sup>45,52,53</sup> Lens vitamin C falls to low levels early in the course of microwave cataract.<sup>54,55</sup> Glutathione levels are also reduced in senile cataract,<sup>49,50,52,56,57</sup> along with levels of glutathione reductase and protein thiols,<sup>56</sup> and the degree of fall correlates with increased nuclear brunescence.<sup>58</sup>

It is accepted that loss of reduced glutathione on exposure to photo and other oxidative stresses results in the formation of protein-protein disulphides and mixed (protein-glutathione) disulphides, with the formation of light-scattering insoluble and high molecular weight crystallin aggregates.<sup>58</sup> A fall in glutathione levels in the lens is the earliest change to occur in cataract caused by ionising radiation when vitamin C levels are unchanged.<sup>57</sup> Consul and Nagpal<sup>52</sup> demonstrated a simultaneous fall in vitamin C and glutathione in cataractous lenses (for example: normal vitamin C, 24.1 mg/100 g wet weight; immature cataract, 6.7 mg/100 g; mature, 5.8 mg/100 g; normal glutathione, 354.3 mg/100 g; immature cataract, 29.6 mg/100 g; mature, 3.2 mg/100 g.<sup>52</sup> Other workers have also noted this combined fall of glutathione and vitamin C in cataract.<sup>49,50,59</sup> This could be construed as a response to oxidative stress and also represents a state whereby such lenses would be more susceptible to oxidative stress than normal lenses. In the normal lens the level of ascorbate is about 1  $\mu\text{mol/g}$  of lens, which is one-tenth the concentration of GSH.<sup>57</sup> It is of interest that *in vitro* ascorbate oxidation is inhibited by the thiol groups of glutathione, cysteine, or lens proteins, while conversely glutathione is oxidised when incubated with ascorbate but not when incubated alone.<sup>57</sup>

The latter action may relate to the formation of hydrogen peroxide when ascorbate is oxidised.<sup>60</sup> However, in other circumstances vitamin C is a powerful inhibitor of oxidative processes, such as the photo-oxidation of tryptophan and other aromatic amino acids.<sup>61</sup>

Support for a role of ascorbate protecting against photo-oxidative and other oxidative stress comes from various sources. Varma *et al.* demonstrated a protective role for ascorbate against light-induced damage to the epithelial cation pump of the rat lens<sup>62</sup> and Zigman *et al.* demonstrated that ascorbate inhibited lens darkening in experimental ultraviolet cataract.<sup>63</sup> A comprehensive series of studies by Tso has shown a protective effect of dietary supplementation with ascorbic acid, L-dehydroascorbic acid and sodium ascorbate, against the photoreceptor damage induced by intense light in the rat retina. This group have demonstrated a light induced fall in retinal ascorbate in rat, guinea pig, and monkey retina. They conclude that ascorbate functions as an antioxidant molecule in the retinae of these species.<sup>64-69</sup>

At biological pH L-ascorbic acid is readily and reversibly oxidised to L-dehydroascorbate and can be further degraded through 2,3 diketo-L-gulononic acid to L-xylonic and L-lyxonic acid (by a decarboxylation, or to L-threonic acid and oxalic acid (by oxidation).<sup>70,71</sup> Although oxalic acid can be converted to formate and carbon dioxide by bacteria, plants, and certain animals, it is a metabolic end product in mammalian systems, and 89–99% of an administered dose in humans is excreted in the urine. Ascorbate accounts for about 35–50% of oxalate excretion; but glyoxylate is the major pathway of biosynthesis.<sup>70</sup> It is this last pathway which is affected in primary oxalosis or oxaluria (types I and II), in which renal and other tissue deposition of oxalate is accompanied by oxaluria. The eye is not involved in this condition. Two minor sources of oxalate in mammalian systems include tryptophan—probably by interconversion with serine and then to glyoxylate—and tyrosine or phenylalanine, presumably via auto-oxidation of their  $\alpha$ -keto-analogues.<sup>70</sup>

Secondary oxaluric states occur after ingestion of ethylene glycol (a precursor of glyoxylate)<sup>72</sup> in pyridoxine deficiency, because of a reduced removal of glyoxylate through transamination to glycine,<sup>73</sup> and after ileal resection, possibly because of bacterial conversion of bile glycocholate into glyoxylate, and increased absorption.<sup>70</sup>

Oxalate retinopathy has been encountered clinically in a patient who received methoxyfluorane anaesthesia.<sup>74</sup> Methoxyfluorane is readily metabolised to glyoxylate.

Experimental oxalate retinopathy was also studied by van Heyningen and Pirie after naphthalene

administration in the rabbit.<sup>75</sup> Naphthalene toxicity consists of a cataract accompanied by profuse oxalate deposition in the retina and vitreous. van Heyningen and Pirie proposed that 1,2-naphthoquinone is a metabolite of naphthalene, which oxidises ascorbic acid to oxalate and is itself reduced to 1,2-dihydroxy naphthalene. This is strong evidence for the possibility of oxalate formation in the living eye by oxidation of ascorbate. Lens ascorbate falls in naphthalene cataracts,<sup>75</sup> but oxalate levels do not appear to have been measured in this condition. Vitamin C feeding has an equivocal effect on naphthalene cataract.<sup>76</sup>

A major feature of naphthalene cataract, apart from the development of opacity, is a brown discoloration, which has been attributed to the presence of naphthoquinone-protein compounds within the lens.<sup>77-79</sup> Another possibility could be the formation of non-enzymatic brown adducts between ascorbate and lens crystallins and other proteins. Bensch *et al.*<sup>80</sup> have demonstrated that ascorbic acid will form adducts with bovine crystallins or serum albumin with the same fluorescence excitation and emission spectra as the yellow-brown glycosylation products formed by glucose and other aldoses. (This latter reaction involves Schiff-base formation between an aldol group of glucose and amino groups of protein and subsequent stabilisation of the aldimine bonds by the Amadori rearrangement.<sup>81</sup> This is followed by a 'browning reaction', leading to stable, yellow-brown products.<sup>81,82</sup> These stable, covalently linked adducts have similar fluorescence spectra to chromophores extracted from human cataractous lenses. Bensch *et al.*<sup>80</sup> point out that ascorbate forms condensation products with proteins at a rate faster than that shown by common aldoses. Furthermore, outside the diabetic state, lens ascorbic acid levels are much higher than lens glucose, which should encourage brown-adduct formation from ascorbate. Such adducts have been proposed to account for the insoluble brown chromophore found in brunescient lenses.

These various accounts give the opportunity to propose a coherent hypothesis relating cataractous events occurring in and around the lens nucleus, supporting a general role for oxidative stress mechanisms. Three forms of lens change may be seen in the region of the nucleus. Retrodot lens opacities may be seen on their own or in combination with 'nuclear sclerosis.' Nuclear sclerosis may be either a colourless scattering opacity, a yellow to brown opacity, or a mixed opacity where scattering and colour changes are both seen. From what has been said above it may be inferred that the presence of retrodots implies that the lens has suffered oxidative stress which has oxidised ascorbic acid to oxalate.



The ascorbic acid content of the lens could be reduced. Pure, scattering sclerosis could be ascribed to a series of events following adduct formation between, say, lens crystallins and cyanate (carbamylation), with the resulting conformational changes exposing protein thiols. A decreased protective system against oxidative stress—for example, decreased levels of reduced glutathione—would expose lens crystallin thiols to oxidation, encouraging high molecular weight aggregate formation and a non-brunescant scattering type of opacity. Brunescant changes would be attributed at least in part to the formation of non-enzymatic brown adducts, to which oxidised ascorbate would make a major contribution in non-diabetics and glycosylation an increasing contribution in diabetics.

New techniques of classification and examination of the lens and cataract make it possible to explore these hypotheses clinically as well as biochemically. We are engaged in an epidemiological study of lens opacities and will be able to quantify and correlate the features discussed. In patients coming to lens extraction further correlations will be made between the content of ascorbate and its metabolic products, including oxalate, and the morphological features of the cataracts.

#### References

- Vogt A. Klinischer und anatomischer Beitrag zur Kenntnis der Cataracta senilis, insbesondere zur Frage des subcapsularen Beginnes derselben. *Graefes Arch Klin Exp Ophthalmol* 1914; **88**: 329–91.
- Vogt A. Weiterer Ergebnisse der Spaltlampenmikroskopie des vorderen Bulbusabschnittes. IV. Prasenile und senile Linsentrübungen. *Graefes Arch Klin Exp Ophthalmol* 1922; **108**: 192–218.
- Vogt A, Lussi U. Weitere Untersuchungen über das Relief des menschlichen Linsenkerne oberfläche. *Graefes Arch Klin Exp Ophthalmol* 1919; **100**: 157–67.
- Reese AB, Wadsworth JAC. Occurrence of cystoid spaces in the lens. *Arch Ophthalmol* 1954; **51**: 315–7.
- Bron AJ, Matsuda K. Specular microscopy of the human lens. *Trans Ophthalmol Soc UK* 1981; **101**: 163–9.
- Bron AJ, Brown NAP. Classification, grading and prevention of cataract. *Trans Ophthalmol Soc UK* 1983; **4**: 21–47.
- Klang G. Measurements and studies of the fluorescence of the human lens in vivo. *Acta Ophthalmol (Kbh)* 1948; suppl 31: 1–152.
- Fincham EF. Photographic recording of opacities in the ocular media. *Br J Ophthalmol* 1955; **39**: 85–9.
- Kawara T, Obazawa H. A new method for retro-illumination photography of cataractous lenses. *Am J Ophthalmol* 1980; **90**: 186–9.
- Brown NAP. Visibility of transparent objects in the eye by retroillumination. *Br J Ophthalmol* 1971; **55**: 517–24.
- Kranz. Kristallbildungen in Auge, insbesondere in der Linse. *Klin Monatsbl Augenheilkd* 1927; **79**: 654.
- Lang W. Cholesterin crystals in the lens. *Trans Ophthalmol Soc UK* 1885; **15**: 117–8.
- Bunge E. Zum histologischen Cholesterinnachweis bei verschiedenen Trübungsformen der menschlichen Linse. *Arch Augenheilkd* 1936; **109**: 503–53.
- Dark AJ, Streeten BW. Ultrastructural study of cataract in myotonia dystrophica. *Am J Ophthalmol* 1977; **84**: 666–74.
- Hayes BP, Fisher RF. Ultrastructural appearances of a lens with marked polychromatic lustre: evidence of diffraction as a cause. *Br J Ophthalmol* 1984; **68**: 850–8.
- Cogan DG, Kuwabara T, Silbert J, Kern H, McMurray V, Hurlbut C. Calcium oxalate and calcium phosphate crystals in detached retinas. *Arch Ophthalmol* 1958; **69**: 366–71.
- Zimmerman LE, Johnson FB. Calcium oxalate crystals within ocular tissues. *Arch Ophthalmol* 1958; **60**: 372–83.
- Bron AJ, Habgood JO. Morgagnian cataract. *Trans Ophthalmol Soc UK* 1976; **96**: 265–77.
- Pau J, Forster H. Die Doppelbrechung von Kristallen in der Linse (Sphärolithen, 'Christbaum-Schmuck') und im Glaskörper (Scintillatio nivea). *Graefes Arch Klin Exp Ophthalmol* 1982; **219**: 295–7.
- Pau H. Die Sphärolithen der Linse. *Klin Monatsbl Augenheilkd* 1984; **184**: 159–62.
- Flocks N, Littwin CS, Zimmerman LE. Phacolytic glaucoma. *Arch Ophthalmol* 1955; **54**: 37–45.
- Fenton RH, De Buen S. Phacolytic glaucoma aggravated by hyphema that followed iridectomy. *Arch Ophthalmol* 1964; **72**: 227–30.
- Goldberg MF. Cytological diagnosis of phacolytic glaucoma utilizing millipore filtration of the aqueous. *Br J Ophthalmol* 1967; **51**: 847–53.
- Wessley K. Über sphärolithische Kristallaggregate in kataraktösen Linsen. *Arch Augenheilkd* 1922; **91**: 158–64.
- Jaeger W, Olbert Crusius A, Frey M. Calcium gehalt cataractöser Linsen beim Menschen—Das Verhältnis des calcium gehaltes zu Form und Ausmass der mit Hilfe der Scheimpflug-Kamera dokumentierten Linsen trübungen fortschritte für Ophthalmologie 1985; **82**: 377–81.
- Pau H, Kaufmann R. Laser microprobe analysis (LAAMA) of spheruliths in human cataract lenses. *Arch Ophthalmol* 1983; **101**: 1935–7.
- Harding CV, Chylack LT Jr, Susan SR, Lo WK, Bobrowski WF. Calcium-containing opacities in the human lens. *Invest Ophthalmol Vis Sci* 1983; **24**: 1194–202.
- Glick D, Biskind GR. Studies in histochemistry. Distribution of vitamin C in lens of eye. *Arch Ophthalmol* 1936; **16**: 990–5.
- Muller HK. C-Hypovitaminose und Altersstar. *Klin Monatsbl Augenheilkd* 1938; **100**: 478.
- Nakamura B, Nakamura O. Ueber das Vitamin C in der Linse und dem kammerwasser der menschlichen Katarakte. *Graefes Arch Klin Exp Ophthalmol* 1935; **134**: 197–200.
- Gala A, Melka J. Der Gehalt an Vitamin C in Humor aqueous des normalen und pathologisch veränderten Auges. *Arch Augenheilkd* 1936; **109**: 726–31.
- Kinsey VE, Jackson B. Investigation of the blood-aqueous barrier in the new born. *Am J Ophthalmol* 1949; **32**: 374–8.
- Davson H. *The eye*. New York: Academic Press, 1962; **1**: 90.
- Kinsey VE. Transfer of ascorbic acid and related compounds across the blood-aqueous barrier. *Am J Ophthalmol* 1947; **30**: 1262–6.
- Duke-Elder S. *System of ophthalmology*. St Louis: Mosby, 1958; **1**: 605.
- Heath H. Distribution and possible functions of ascorbic acid in the eye. *Exp Eye Res* 1962; **1**: 362–7.
- Bellows JG. *Cataract and abnormalities of the lens*. New York: Grune and Stratton, 1975: 75.
- Robertson W van B. The biochemical role of ascorbic acid in connective tissue. *Ann NY Acad Sci* 1961; **92**: 159.
- Augusteyn RC. In: Duncan G, ed. *Mechanisms of cataract formation in the human lens*. New York: Academic Press, 1981; 71–115.
- Muller HK, Buscke W, Gurewitsch A, Bruhl F. Vitamin C in Kammer wasser und Linse—seine bedeutung für Physiologie und Pathologie des Linsenstoffwechsels. *Klin Wochenschr* 1934; **13**: 20–9.

- 41 Bellows J, Rosner L. Biochemistry of the lens VIII. New proof of the presence of vitamin C in the crystalline lens. *Arch Ophthalmol* 1936; **16**: 248–51.
- 42 Birch TW, Dann WJ. Estimation and distribution of ascorbic acid (vitamin C) and glutathione in animal tissues. *Nature* 1933; **131**: 469–75.
- 43 von Euler HV, Malmberg M. Neue Versuch ueber Ascorbinsaure (C-Vitamin) in tierischen Augenlinsen. *Arch Augenheilkd* 1936; **109**: 225–42.
- 44 Bellows J. Biochemistry of lens. Cevitamic acid content of the blood and urine of subjects with senile cataract. *Arch Ophthalmol* 1936; **15**: 78–83.
- 45 Hawley E, Pearson O. Vitamin C and its relation to cataract. *Arch Ophthalmol* 1938; **19**: 959–67.
- 46 Urbanek J. Der C-vitamin—stoffwechsel bei starkranken. *Klin Monatsbl Augenheilkd* 1938; **101**: 670–92.
- 47 Urbanek J, Albrecht W. C-vitamin und Lebensalter. *Z Augenheilkd* 1938; **95**: 192–8.
- 48 Gapeev PI. Ascorbic acid content of aqueous humour, crystalline lens and blood in cataract patients and in normals. *Vestn Oftalmol* 1941; **18**: 154–7.
- 49 Disch Z, Zil H. Studies on the oxidation of cysteine to cystine in lens proteins during cataract formation. *Am J Ophthalmol* 1951; **34**: 104–13.
- 50 Pirie A, Van Heyningen R, Boag JW. Changes in lens during formation of x-ray cataract in rabbits. *Biochem J* 1953; **54**: 682–8.
- 51 Pirie A, van Heyningen R. *Biochemistry of the eye*. Springfield: Thomas, 1956: 24–8.
- 52 Consul BN, Nagpal PN. Quantitative study of the variations in the levels of glutathione and ascorbic acid in human lenses with senile cataract. *Ear Nose Throat J* 1968; **47**: 336–9.
- 53 Vogt A. Zur stardiskussion in Heidelberg. *Klin Monatsbl Augenheilkd* 1938; **101**: 530–43.
- 54 Carpenter RL. Experimental study of the biological effects of microwave radiation in relation to the eye. *Technical note of Rome air development center RADC-TDR* 1962; **62**: 131.
- 55 Merola LO, Kinoshita JH. In: *Proceedings of the fourth Annual Tri-Service Conference on biological effects of microwave radiation*. New York: Plenum, 1965; **1**: 285–91.
- 56 Rogers KM, Augusteyn RC. Glutathione reductase in normal and cataractous lenses. *Exp Eye Res* 1978; **27**: 719–21.
- 57 Kinoshita JH. Selected topics in ophthalmic biochemistry. *Arch Ophthalmol* 1964; **72**: 554–72.
- 58 Harding JJ, Crabbe MJC. In: Davson H, ed. *The eye*. vol. 1B. Vegetative physiology and Biochemistry 3rd Edition (1984).
- 59 Rosner L, Farmer CJ, Bellows SJ. Biochemistry of the lens: XII. Studies on glutathione in the crystalline lens. *Arch Ophthalmol* 1938; **20**: 417–26.
- 60 Fukui HN, Epstein DL, Kinoshita JH. Ascorbic acid effects on lens. Rubidium transport. *Exp Eye Res* 1973; **15**: 249–53.
- 61 Pirie A. Formation of N'-formylkynurenine in proteins from lens and other sources by exposure to sunlight. *Biochem J* 1971; **125**: 203–8.
- 62 Varma SD, Kumar S, Richards RD. Light-induced damage to ocular lens cation pump: prevention by vitamin C. *Proc Natl Acad Sci USA* 1979; **76**: 3504–6.
- 63 Zigman S, Griess G, Yulo T, Schultz J. Ocular protein alterations by near UV Light. *Exp Eye Res* 1973; **15**: 255–64.
- 64 Tso MOM, Woodford BJ. Effect of photic injury in the retinal tissues. *Am Acad Ophthalmol* 1983; **90**: 952–8.
- 65 Woodford BJ, Tso MOM, Lam L-W. Reduced and oxidised ascorbate in guinea pig retina under normal and light-exposed conditions. *Invest Ophthalmol Vis Sci* 1983; **24**: 862–7.
- 66 Tso OM, Woodford BJ, Lam L-W. Distribution of ascorbate in normal primate retina after photic injury: a biochemical morphological correlated study. *Curr Eye Res* 1984; **3**: 181–91.
- 67 Organisciak DT, Wang H-M, Kou A. Ascorbate and glutathione levels in the developing normal and dystrophic rat retina: effect of intense light exposure. *Curr Eye Res* 1984; **3**: 257–62.
- 68 Li ZY, Tso MO, Wang H-M, Organisciak DT. Amelioration of photic injury in rat retina by ascorbic acid: a histopathologic study. *Invest Ophthalmol Vis Sci* 1985; **26**: 1589–99.
- 69 Organisciak DT, Wang H-M, Li ZY, Tso OM. The protective effect of ascorbate in retinal light damage of rats. *Invest Ophthalmol Vis Sci* 1985; **26**: 1580–8.
- 70 Williams HE, Smith, LH. Primary hyperoxaluria. In: Stanbury JB, Wyngoarden JB, Fredrickson DS, eds. *The metabolic basis of inherited disease*. 3rd ed. New York: McGraw Hill, 197–219.
- 71 Lewin S. *Vitamin C: its molecular biology and medical potential*. London: Academic Press, 1976.
- 72 Friedman EA, Greenberg JB, Merill JB, Dammin GJ. Consequences of ethylene glycol poisoning. *Am J Med* 1962; **32**: 891–902.
- 73 Faber SR, Feitler WW, Bleiler RE, Ohlson MA, Hodges RE. The effects of an induced pyridoxine and pantothenic acid deficiency on excretions of oxalic and xanthurenic acids on the urine. *Am J Clin Nutr* 1963; **12**: 406–11.
- 74 Bullock JD, Albert DM, Skinner CW, Miller WH, Galla JH. Calcium oxalate retinopathy associated with generalised oxalosis: x-ray diffraction and electron microscopic studies of crystal deposits. *Invest Ophthalmol Vis Sci* 1974; **13**: 256–5.
- 75 Van Heyningen R, Pirie A. The metabolism of naphthalene and its toxic effect on the eye. *Biochem J* 1967; **102**: 842–52.
- 76 Müller HK. Zur Kenntnis der durch Naphthal in hervorgerufen biochemischen Augenveränderungen und ihre Beeinflussung durch Vitamin C. *Arch Augenheilkd* 1936; **109**: 304–13.
- 77 Müller HK, Buschke W. Ueber die behandlung der Naphthalinkatarakt mit Vitamin C. *Arch augenheilkd* 1934; **108**: 597–99.
- 78 Pirie A. A light catalysed reaction in the aqueous humour of the eye. *Nature* 1965; **205**: 500–1.
- 79 Pirie A. Pathology in the eye of the naphthaline-fed rabbit. *Exp Eye Res* 1968; **7**: 354–7.
- 80 Bensch KS, Fleming JE, Lohmann W. The role of ascorbic acid in senile cataract. *Proc Natl Acad Sci* 1985; **82**: 7193–6.
- 81 Brownlee M, Cerami A. The biochemistry of the complications of diabetes mellitus. *Am Rev Biochem* 1981; **50**: 385–432.
- 82 Namiki M, Hayashi T. In: Waller GR, Feather MS, eds. *The Maillard reaction in foods and nutrition. ACS symposium series 215*. Am Chem Soc, Washington, DC. 1983: 21–46.