

# Management of unsuccessful lacrimal surgery

RICHARD A N WELHAM<sup>1</sup> AND ALLAN E WULC<sup>2</sup>

*From* <sup>1</sup>*Moorfields Eye Hospital, London, and the Royal Berkshire Hospital, Reading; and the* <sup>2</sup>*Scheie Eye Institute, University of Pennsylvania, Philadelphia, USA*

**SUMMARY** Two hundred and eight cases of failed dacryocystorhinostomy presenting to the Lacrimal Clinic at Moorfields Eye Hospital between 1970 and 1985 were reviewed. All cases underwent a further operation. The reasons for failure were usually apparent on reoperation. The surgical technique is described. A second dacryocystorhinostomy is a highly successful technique that spares both patient and surgeon the lifelong commitment to a bypass tube.

Professor Barrie Jones concluded in a paper given before the Ophthalmological Society of the United Kingdom in 1973 that if one adheres to certain basic principles in both dacryocystorhinostomy (DCR) and canalicular surgery, 'it is possible to achieve, in a high proportion of cases, an accurate and large anastomosis of sac to nasal mucosal wall, or of canaliculus to sac to nose, with a very high rate of permanent success, leaving only a small minority of cases that are best dealt with by less satisfactory intubational procedures which require continuing aftercare.'<sup>1</sup>

The failure of dacryocystorhinostomy is rare, occurring in most series in less than 10% of cases.<sup>2-7</sup> The management of unsuccessful DCR poses a therapeutic problem. Some authors recommend the insertion of a Lester Jones bypass tube,<sup>8</sup> which, despite its usefulness, necessitates a lifetime of continuing aftercare. Procedures directed at the ablation of tear production are to be discouraged, as most of them can cause a dry uncomfortable eye and may occasionally pose a threat to vision.<sup>9-11</sup>

Secondary surgery on the lacrimal drainage system, if performed with attention to the principles stressed by Professor Jones, is likely to be successful in a high proportion of cases. Our initial results with this technique were reported in 1973.<sup>12</sup>

From 1970 to 1985, 204 patients have presented to the Lacrimal Clinic at Moorfields with symptoms attributed to a non-functioning dacryocystorhinostomy and undergone secondary DCR surgery. Four patients had bilateral failed dacryocystorhinostomies. The purpose of this communication is to describe our technique and present the results of this

further surgery. The patients were also examined retrospectively to determine what factors were responsible for the failure of the primary operation.

## Patients and methods

In addition to a history the preoperative assessment included a dye test, syringing, slit-lamp and intranasal examination, and diagnostic probing. Contrast studies<sup>13</sup> were performed in the majority of patients; this essential investigation was omitted in patients who could not co-operate or in those with large regurgitating mucocoeles. The x-ray findings were most helpful in planning the secondary procedure. In those patients with a large sac remnant, whether completely obstructed or partially patent, as in the sump syndrome (Fig. 1), the reoperation consisted in identifying the anterior aspect of the previous rhinostomy in the first instance, enlarging it anteriorly, and if necessary in all directions, to find virgin nasal mucosa. In the presence of a canalicular obstruction or where there was only a small remnant of sac (Fig. 2) it was essential to identify the junction of the sac and common canaliculus before isolation of the rhinostomy site. Dissection and identification of the common canaliculus as an initial step are technically easier when the medial tissues are fixed to the rhinostomy and immobile.

At the time of operation the appropriate procedure was performed by a technique described more completely below. Possible reasons for failure of the primary operation were noted.

After discharge the day after operation patients were seen one week postoperatively, at six weeks, and again at three months. Canalicular tubing, if introduced, was removed three months later. The

Correspondence to R A N Welham, FRCS, Moorfields Eye Hospital, City Road, London EC1V 2PD.

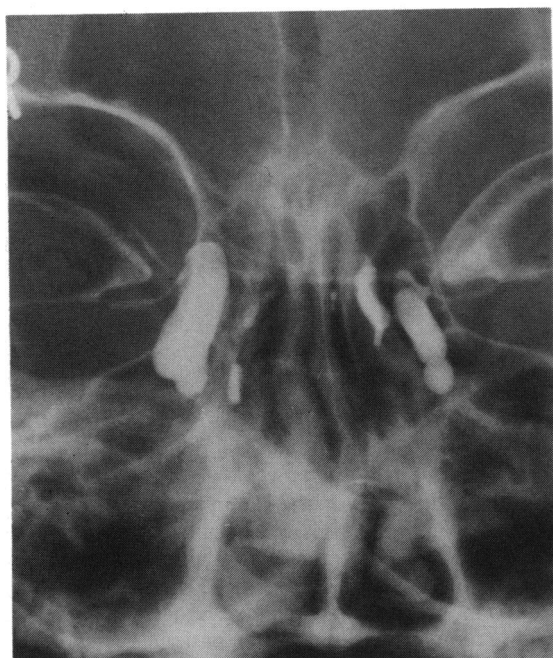


Fig. 1 DCG. Bilateral sump syndrome following failed lacrimal surgery. Contrast enters nose; also partially retained within large sac remnant.

patients were seen subsequently five to six months postoperatively, and a dye test was repeated. The absence of symptoms and a positive dye test were construed as evidence of success. Some patients with symptoms of watering only in adverse climatic conditions and who had positive dye tests were also considered successful, but grouped separately. A failure was defined as any patient with a negative dye test that had symptoms.

TECHNIQUE OF REOPERATION

Operations in adults are carried out under hypotensive anaesthesia, when possible.<sup>14</sup> In children and adults in whom hypotension is contraindicated, lignocaine 1% with adrenaline is infiltrated locally for haemostasis.

A skin incision is made through the original scar. Orbicularis is separated at the junction of orbital and palpebral portions by a technique of traction sutures previously described.<sup>1</sup>

If a dacryocystogram has shown a canalicular obstruction or a small sac to be present, probes are passed into the canaliculi. The medial palpebral tendon, if present, is divided (Fig. 3). Beneath the cut tendon canalicular tissue is sought lateral to the sac in the tissues of the medial lid. A combination of sharp and blunt dissection is used to separate the scar above and below the probes (Fig. 4). Great care is taken not

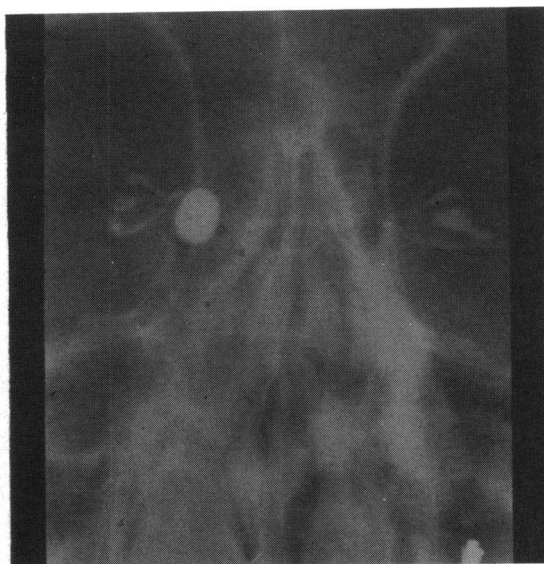


Fig. 2 DCG. Common canalicular obstruction following failed lacrimal surgery. Note contralateral mucocele.

to enter the lumen of the canaliculi. When the probes can be seen and easily felt within the canaliculi, attention is directed to defining the anterior edge of the original rhinostomy.

Periosteum is freed from bone for approximately 4 mm anterior to the bony edge of the original rhinostomy (Fig. 5). The nasal mucoperiosteum is then separated from the front edge of the rhinostomy, to which it is usually adherent, by means of a Traquair periosteal elevator. This manoeuvre usually provokes bleeding. The bone is removed approximately 4 mm anteriorly, and may be enlarged inferiorly and superiorly, to expose virgin nasal mucosa (Fig. 6).

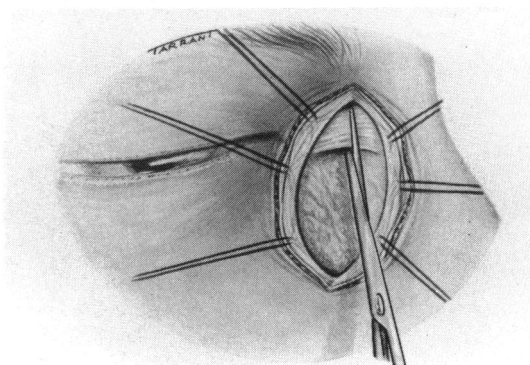


Fig. 3 Operative. Medial palpebral tendon divided if present. Canaliculi sought in tissue beneath it. Traction sutures to orbicularis and deep tissues aid exposure. Right eye.

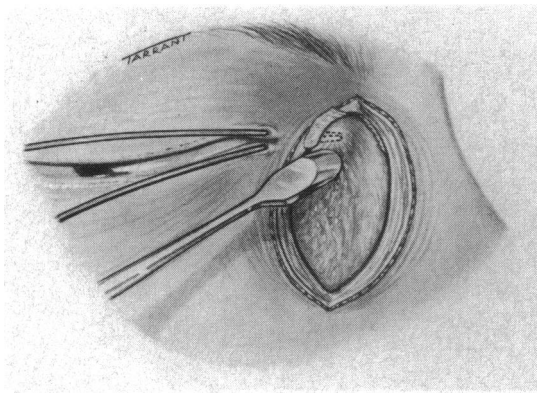


Fig. 4 Operative. Junction of common canaliculus with remaining lacrimal sac exposed by blunt dissection with probes in canaliculi.

A trapdoor incision based in the newly exposed virgin nasal mucosa is cut so that the lateral free edge is close to the previously identified common canaliculus and the upper and lower edges are adjacent to the edges of the newly enlarged rhinostomy (Fig. 6). If a large sac remnant exists and the canaliculi are not isolated, the trapdoor incision may be made at the site of the old anastomosis. The flap is reflected anteriorly with traction stitches (Fig. 7). The interior of the rhinostomy is then inspected.

At this stage the reason for the original failure of the original DCR may become apparent. Bone, ethmoid air cell, turbinate, non-absorbable sutures, stones, or scar may be present and must be removed (Fig. 7A).

If the common canaliculus is obstructed, an incision is made lateral to the obstruction to expose healthy canalicular mucosa (Fig. 7B). All intervening scar tissue is excised and healthy canalicular mucosa is then anastomosed to the remaining sac or the nasal

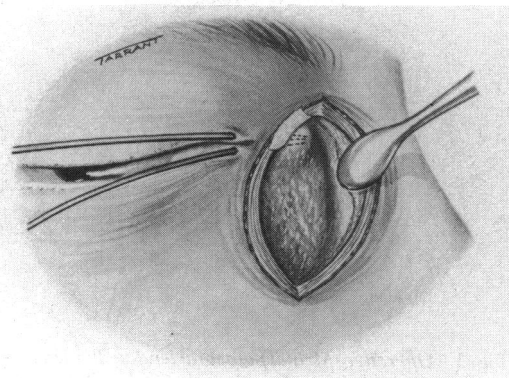


Fig. 5 Operative. Bone at anterior edge of previous anastomosis identified, and periosteum stripped anteriorly.

mucosa. Canalicular flaps should be sutured under slight tension so that they do not adhere internally and obstruct. All canalicular obstructions are intubated and the tubes secured within the nose (Fig. 8).

Anterior and posterior mucosal flaps are created and sutured with fine absorbable suture material such as 6/0 Dexon (Fig. 9).

Orbicularis and tendon are repositioned with an absorbable suture, and the skin is closed with an interrupted nylon suture.

## Results

Of the 204 patients studied 137 were female and 67 were male. Four patients had bilateral failed DCRs. There were 102 left eyes and 106 right eyes, giving a total of 208 cases.

The average age of the patients at onset of the original symptoms was 39 years and at initial surgery was 42 years. The interval from initial surgery to reoperation averaged 5 years. Follow-up ranged from 3 months to 10 years and averaged 15 months.

One hundred and sixty-three patients complained of tearing. Forty patients had residual discharge with pressure on the lacrimal sac. The primary procedure was a DCR in 150, a DCR with tubes in 45, and a canaliculo-dacryocystorhinostomy (CDCR) in 7, while 6 patients had a dacryocystectomy. One hundred and forty-seven patients had had a single procedure prior to presentation, 54 had had one unsuccessful secondary procedure elsewhere, and seven patients had had more than one unsuccessful secondary procedure.

Of 154 DCGs available for review, a common canalicular obstruction was noted in 101 cases, a dilated sac in 29 cases, a dilated sac with overflow into the nose (sump syndrome) in 12, and blockage at the site of the rhinostomy in 12.

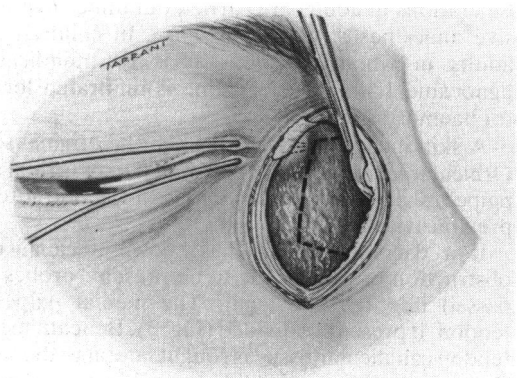
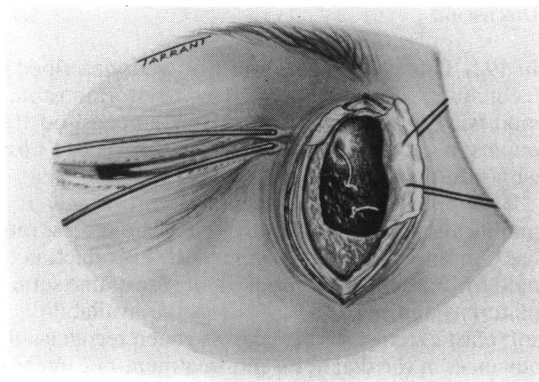
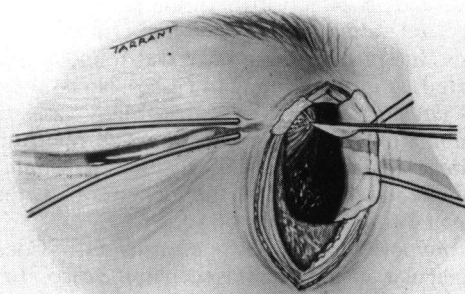


Fig. 6 Operative. Bony rhinostomy enlarged. (Dotted lines: approximate location of trapdoor incision).



A



B

Fig. 7 Operative. Flap reflected forward using traction sutures. Interior of rhinostomy inspected. At this time reasons for failure often become evident. Possible findings on inspection include: (A) Non-absorbable suture or scar in relation to common canaliculus, or (B) membranous scar over internal common opening, which can be incised with scalpel guided by ends of lacrimal probes. For other possible findings see text.

**Type of surgery.** Of the 208 cases 37 DCRs, 127 DCRs with intubation of the canaliculi, and 44 CDCRs with anastomosis of canalicular remnants to the nasal mucosa were performed.

**Results of surgery.** Of the 208 secondary operations performed 176 were successful (85%). Ten patients were dry following surgery with positive dye tests, but admitted to moisture in the cold and the wind. Therefore 186 patients had successful secondary surgery (89%).

Of the 22 patients who had unsuccessful secondary operations 15 consented to have a third operation. Of these 15 patients 13 were cured of tearing. Therefore the success of a third operation was 87%, essentially the same as for the primary procedure. With a third operation 96% of the cases operated on were cured without recourse to a bypass tube.

**REASONS FOR FAILURE**

The presumed cause of failure of the primary operation(s) are depicted graphically in Table 1.

**Errors in ostium location or bone removal.** One hundred and eleven errors in ostium location were noted. In eight cases the ostium was located too posteriorly, in 10 cases it was too anterior, in 25 too

Table 1 Reasons for failure of primary operation

Reasons for failure	No. of patients
Inappropriate size or location of ostium	111
Common canalicular obstruction	108
Scarring within rhinostomy	28
Intervening ethmoid	15
Sump syndrome	10
Active systemic disease	7
DCR to air cell	6
Three of above	36

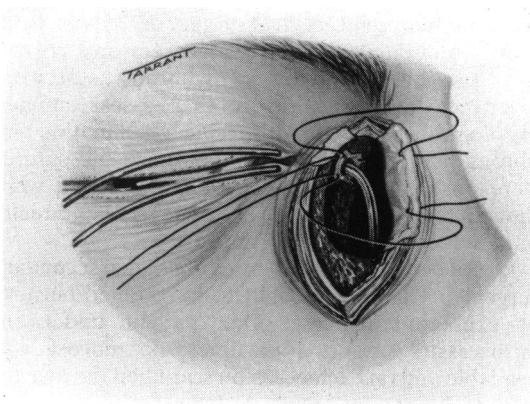


Fig. 8 Operative. Anterior and posterior common canalicular mucosal flaps sutured to mucous membrane posteriorly and anteriorly with absorbable suture. Canaliculi intubated.

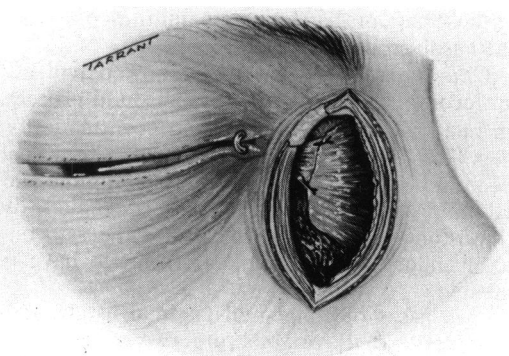


Fig. 9 Operative. Anterior flap closed. Tubing in situ, ends of tubing secured in nose.

high, and in 24 too low. Ethmoids were found in direct relation to the opened and scarred sac in 15 cases. Intervening loose bone was found within the scarred sac in an additional 18 cases. No bony ostium was detected at all in 19 cases. Many cases had a combination of these errors in bone removal and ostium location: a posteriorly placed ostium, for example, might have had the remains of an ethmoid air cell within the rhinostomy.

*Common canalicular obstruction.* Common canalicular obstruction was seen in 108 cases. In 26 of these patients canalicular obstruction occurred in conjunction with an associated inflammatory process within the sac, and in 39 patients bone was seen in close proximity to the obstructed internal opening. Three patients had scarring, with non-absorbable suture found against the common opening. Two patients had sarcoid involving the sac and common canaliculus.

*Scarring within the anastomosis.* Sac scarring was the only abnormality seen at surgery in 17 cases. Both small obliterated and obstructed sacs and normal sized sacs filled with chunks of fibrous tissue were observed: the large majority of these cases examined histologically showed non-specific inflammation and fibrous tissue. In 11 cases non-absorbable sutures were observed in the midst of the scar and were thought to have provoked the scarring, either directly or indirectly as a result of infection.

Of note is that, of the 15 cases that failed secondary surgery, 93% were thought to have failed because of exuberant scarring. One patient underwent unsuccessful surgery four times: no mucosa was available and on each occasion scar filled the anastomosis. This patient required a bypass tube.

*Persistent mucocele and sump syndrome.* In all 29 cases of persistent mucocele a failure fully to open the sac and duct into the nose was noted. Ten patients had a sump syndrome diagnosed on the basis of their DCG findings. A typical DCG is seen in Fig. 1. Eight of these patients had bone remaining medially within the nasolacrimal canal.

*Other findings.* Several cases showed evidence of an incomplete or anatomically unsound procedure. In one case an anastomosis had been made to the maxillary antrum. In six cases the anastomosis had been incorrectly made between lacrimal sac and an ethmoid air cell. In nine cases an adequate bony rhinostomy was found, but either the sac, or the nasal mucosa or both appeared not to have been opened.

Two cases of congenital lacrimal fistula undiagnosed prior to the original surgery were corrected by methods described elsewhere.<sup>15</sup> Two cases with multiple unremoved sac stones were found. In six cases no obvious cause for initial failure was found.

## Discussion

In 1921 Dupuy-Dutemps and Bourguet described a technique of external dacryocystorhinostomy modifying Toti's operation.<sup>16</sup> They emphasised the importance of making an anastomosis of sac to nose with sutured mucosal flaps.

This procedure has undergone surprisingly few modifications over the past 65 years. The success rate has improved, however, owing to the introduction of modern anaesthetic techniques, the use of fine suture materials and needles, as well as the availability of soft plastic stents. There have also been recognisable advances in the diagnosis and treatment of canalicular disease, made possible by macrodacryocystography and microscopic surgery of the common canaliculus. These techniques, pioneered by Professor Barrie Jones, reached a level of refinement whereby, in a series of 100 of his DCRs, a success rate of 99% was achieved.<sup>17</sup>

Since the initial descriptions of this operation surgeons reporting on many large series have modified the technique and examined the reasons for failure in the patients in whom DCR did not result in relief of symptoms.<sup>2-7 12 15</sup> The occurrence of scarring within the anastomosis in the patients who were reoperated on is common to all these series.<sup>2-7 12 15</sup> The failure rate due to scarring in some series, particularly the more recent ones, is alarmingly high.<sup>6 7</sup>

This finding may be partly attributed to an emergent trend in lacrimal surgery that pays too little attention to careful suturing of flaps. It is often not enough, and never adequate, simply to punch a hole in the nose and line it with tubing in the hope that mucosa will grow round it before a fibrous scar can form. It is a basic principle of general surgery that tissues should be repaired when possible by primary rather than secondary intention. Massive granulation and scarring, secondary haemorrhage and infection from unapposed mucosal flaps, and the inefficient passage of tears through scar rather than through a mucosa lined orifice can be the result.

The scarring that was observed in 128 patients in this series fell into two types. A localised common canalicular scar, perhaps the result of persistent sac disease following the primary operation, was seen in 111 cases. Dense scarring within the anastomosis was observed in 17 cases. In all cases but one case mucosa was found anterior to the rhinostomy of the original operation and used to recreate an anastomosis whose goals were to incorporate the common canalicular opening completely into the nose, and to create a mucosa lined drainage apparatus with the careful suturing of flaps. One case that had no available mucosa underwent four unsuccessful procedures, but eventually a Jones tube was required. A secondary

intention technique with extirpation of sac and nasal mucosa at the time of primary operation doomed to failure all attempts at reoperation.

Some authors have noted that bone regrowth is occasionally responsible for failure of the primary operation.<sup>4,6</sup> Others maintain that bony regrowth does not occur and that fibrous tissue is primarily responsible for obstructions at the site of the bony ostium.<sup>5</sup> In our series 19 cases had no bony ostium at the time of secondary surgery. The bone and mucosal surfaces in these cases appeared as though no previous rhinostomy had been performed. A larger percentage of children were seen to have 'reformed' ostia at the time of reoperation (24%) than adults (6%). Because bone growth is more rapid in a growing child, the contention of bone regrowth cannot altogether be excluded. However, if a mucosal edge-to-edge anastomosis was performed at the primary operation, it is highly unlikely that bony regrowth could proceed across an established tissue plane. This emphasises further the control on outcome exerted by mucosal end-to-end suturing.

Pure ostium problems were presumed to be the cause of failure in 52% of cases in this series. An ostium that is too low may not bypass a mid or upper sac obstruction; an ostium that is too high forces tears to defy gravity and leaves the nasolacrimal duct as a blind pouch vulnerable to reinfection. The ideal ostium, in our view, should remove all bone between the medial wall of the sac and the nose, leaving approximately 5 mm around the canaliculus free of bone. Thus, following DCR, the sac and duct should cease to exist as anatomical structures and be incorporated instead into the nose.

Persistent mucocoeles were seen because of a failure to attain this goal completely rather than from any obscure infection. Either the bone or the mucosa of the lacrimal duct, or both, were observed not to have been adequately marsupialised into the nose.

Other causes for DCR failure that have been recognised include conjunctivitis,<sup>2,4</sup> septate sacs incompletely connected to the nose,<sup>3</sup> bone within the rhinostomy and intranasal adhesions,<sup>3</sup> and canalicular problems.<sup>6,7,12,15</sup> The last can be minimised by preoperative recognition, care in manipulation of the canaliculi, and deliberate inspection of the internal opening at the time of surgery. Additional causes for failure seen in this series included chronic inflammation from non-absorbable suture in relation to the internal common opening, operations that connected sac to ethmoids or other sinuses, sarcoid, interference of the middle turbinate, and undiagnosed congenital lacrimal fistula.

The success rate for a second DCR is about 85%. The reoperation may be repeated, if necessary, with the same success rate as the one that attends initial reoperation. Thus reoperation can cure a significant proportion of failed dacryocystorhinostomies. These patients will be spared recourse to a permanent indwelling Pyrex appliance. In addition, if the primary operation is performed on the basic surgical principle of edge-to-edge anastomosis as described by Dupuy-Dutemps and Bourget and as emphasised by Professor Jones, the need for secondary surgery may diminish.

We thank Terry Tarrant for providing the illustrations, Dr Glynn A S Lloyd for arranging the DCGs, and Carol A Sauser, registered nurse, for her aid in the compilation and recording of data.

#### References

- 1 Jones BR. Principles of lacrimal surgery. *Trans Ophthalmol Soc UK* 1973; **93**: 611–8.
- 2 Romanes GJ. Dacryocystorhinostomy: clinical report of fifty cases. *Br J Ophthalmol* 1955; **39**: 237–40.
- 3 McPherson SD, Egleston D. Dacryocystorhinostomy: a review of 106 operations. *Am J Ophthalmol* 1959; **47**: 328–31
- 4 Iliff CE. A simplified dacryocystorhinostomy. *Arch Ophthalmol* 1971; **85**: 586–91.
- 5 Pico G. A modified technique of external dacryocystorhinostomy. *Am J Ophthalmol* 1971; **72**: 679–90.
- 6 McLachlan DL, Shannon GM, Flanagan JC. Results of dacryocystorhinostomy: analysis of the reoperations. *Ophthalmic Surg* 1980; **11**: 427–30.
- 7 Burns JA, Cahill KV. Modified Kinosian dacryocystorhinostomy: a report of 122 cases. *Ophthalmic Surg* 1985; **16**: 710–6.
- 8 Jones LT. The cure of epiphora due to canalicular disorders, trauma, and surgical failure on the lacrimal passages. *Ophthalmology* 1962; **66**: 506–24.
- 9 Rycroft B. Problems of lacrimal obstruction. *Trans Ophthalmol Soc UK* 1956; **36**: 395–7.
- 10 Jameson PC. Subconjunctival section of the ductules of the lacrimal gland as a cure for epiphora. *Arch Ophthalmol* 1937; **17**: 206–8.
- 11 Whitwell J. Denervation of the lacrimal gland. *Br J Ophthalmol* 1958; **42**: 518–25.
- 12 Welham RAN, Henderson PH. Results of dacryocystorhinostomy: analysis of causes for failure. *Trans Ophthalmol Soc UK* 1973; **93**: 601–9.
- 13 Lloyd GAS, Jones BR, Welham RAN. Intubation macrodacryocystography. *Br J Ophthalmol* 1972; **56**: 600–3.
- 14 Smith B. Anaesthesia for lacrimal surgery. *Trans Ophthalmol Soc UK* 1973; **93**: 619–22.
- 15 Welham RAN, Bergin DJ. Congenital lacrimal fistulas. *Arch Ophthalmol* 1985; **103**: 545–8.
- 16 Dupuy-Dutemps L, Bourget J. Procède plastique de dacryocysto-rhinostomie et ses résultats; *Ann Oculist (Paris)* 1921; **158**: 241–61.
- 17 Jones BR, Corrigan MJ. Obstruction of the lacrimal canaliculi. In: Rycroft PV, ed. *Corneoplastic surgery: proceedings of the Second International Corneo-Plastic Conference*. Oxford: Pergamon, 1969: 101–11.