

Congenital iris cysts

RICHARD D GRUTZMACHER, THOMAS D LINDQUIST, MARK E CHITTUM,
ANN H BUNT-MILAM, AND ROBERT E KALINA

From the Department of Ophthalmology, University of Washington, Seattle, Washington 98195, USA

SUMMARY Unilateral, spontaneous, non-pigmented iris cysts appeared before the age of 2 years in four patients. Histopathological specimens obtained in three cases showed stratified to cuboidal, non-pigmented, epithelial lined cysts. Goblet cells were recognised in two of the three specimens. The clinical features and histopathological findings indicate that these cysts are derived from surface ectoderm and may be congenital.

Cysts of the iris have been divided into three groups: (1) acquired non-pigmented, (2) spontaneous non-pigmented, and (3) pigmented.¹ Acquired non-pigmented iris cysts arise from implanted surface epithelium months or years after penetrating ocular injuries or surgical procedures.² The time of onset of spontaneous or primary non-pigmented cysts is unclear, since often they are noted during general eye examinations. Spontaneous cysts are believed to be congenital, though they may not be detected until late in the first or second decade of life.^{3,4} The clinical and histopathological appearances of spontaneous non-pigmented iris cysts is similar to that of acquired cysts. Pigmented cysts arise from the iris pigment epithelium, usually as a developmental anomaly. The clinical and histopathological appearance of pigmented iris cysts is quite distinct from that of non-pigmented cysts.¹

The pathogenesis of spontaneous non-pigmented iris cysts is not clear. Proposed mechanisms include developmental entrapment of (1) surface ectoderm, or (2) neuroectoderm, or (3) surface ectodermal implantation secondary to occult trauma. Ectopic cystic lacrimal tissue also may occur within the iris stroma but is histologically distinct from non-pigmented iris cysts.^{5,6}

Much of the confusion regarding the onset and aetiology of spontaneous non-pigmented iris cysts relates to their low incidence; hence the preponderance of single case reports.^{1,3,4,7–12} Within the past 50 years published reports have rarely dealt with more than one case.¹³ We report four cases of spontaneous, non-pigmented cysts of the iris.

Illustrative cases

CASE 1

A 4-year-old boy was seen at the University of Washington, Seattle, with a history of a non-traumatic iris cyst involving the inferonasal quadrant of the left eye. The child's mother had noticed a 'spot' on the left iris when he was 3 months old. At 4 months of age examination elsewhere established a diagnosis of iris cyst. Pregnancy and delivery were uncomplicated, and there was no history of amniocentesis or trauma. Progressive enlargement of the iris cyst had been noted since detection. During the previous 3–4 months the cyst had enlarged to involve the pupil, with resultant decrease in visual acuity from 20/30 to 20/60.

There was a 6 mm diameter transparent iris cyst filling the inferonasal quadrant of the anterior chamber (Fig. 1). The cyst wall showed overlying blood vessels that appeared to originate from the anterior chamber angle and adjacent iris. The fluid within the cyst was slightly turbid. The cyst touched the corneal endothelium, with mild stromal oedema over the area of contact. The underlying iris pigment epithelium appeared intact; however, the iris was adherent to the lens in the midperiphery. The remainder of the anterior chamber was deep and clear. The lens was clear. Applanation pressures were 12 mmHg in each eye. Ophthalmoscopic examination was normal.

Surgical excision was performed through a limbal incision. The iris cyst was densely adherent to the corneal endothelium in the inferonasal quadrant and extended into the peripheral angle. The iris pigment epithelium was adherent to the lens capsule in the inferonasal quadrant. The iris cyst was completely

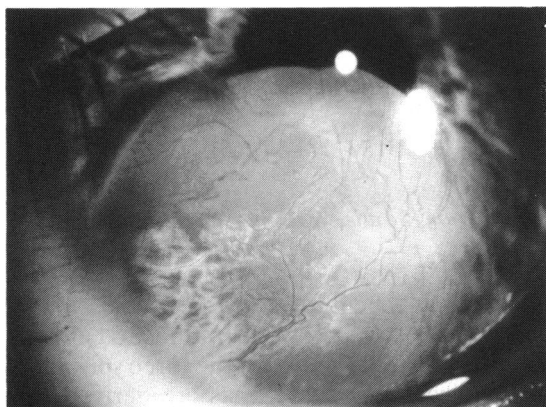

Fig. 1 (Case 1). Iris cyst filling the inferonasal quadrant of the left anterior chamber. Prominent vessels arise from iris stroma and anterior chamber angle.

dissected from the cornea and the lens and excised. Cryotherapy by a double freeze-thaw technique was applied at the inferonasal limbus after filling the anterior chamber with air. Examination one year later showed no recurrence (Fig. 2). Visual acuity was 20/40.

Half of the specimen was fixed in Yanoff's solution, and processed in methacrylate for light microscopy and in Epon for electron microscopy. The other half was fixed in methyl Carnoy's fixative and processed in paraffin for immunocytochemistry. Light microscopy showed a two to three layered non-pigmented intrastromal epithelial iris cyst with numerous goblet cells (Figs. 3, 4). The stroma surrounding the cyst was fibrous, without inflammatory cells, but contained numerous congested

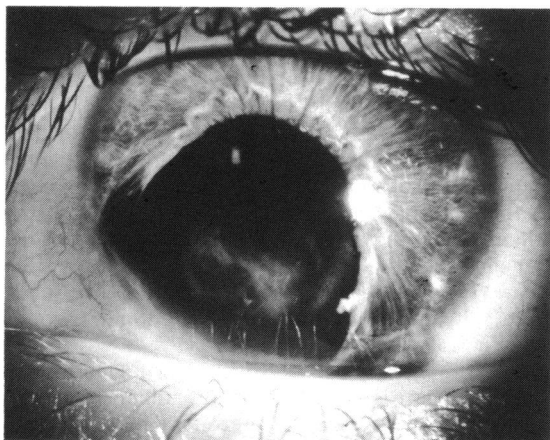


Fig. 2 (Case 1). Appearance one year after excision of iris cyst. The visual axis is clear, but deep stromal corneal scarring is present.

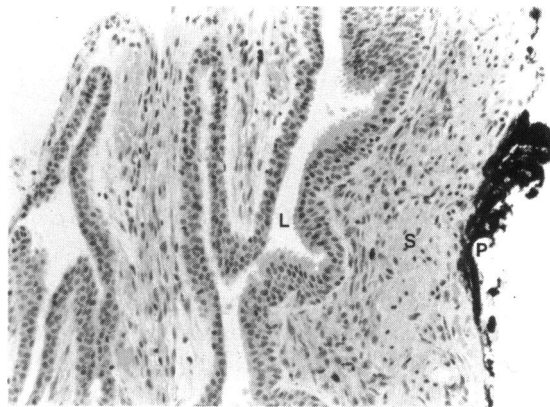


Fig. 3 (Case 1). Collapsed wall of iris cyst, illustrating multilayered lining of epithelial cells. L, lumen of cyst; S, iris stroma; P, iris pigment epithelium. Haematoxylin and eosin.

vessels. Electron microscopy confirmed the presence of goblet cells (Fig. 5). Monoclonal antibodies to intermediate filaments gave strong reactivity to epithelial cyokeratin markers, but were negative for other antigens tested (muscle specific actin, smooth muscle actin, vimentin, human melanoma antigen, S-100 protein).

CASE 2

A 22-year-old woman was seen at Pacific Medical Center, Seattle, Washington, because of a recently irritated left eye. Examination at 2 years of age had revealed a small yellow-white spot of the left inferior iris. There was no antecedent history of birth or postnatal trauma. At age 21 an iris cyst was noted that did not contact the corneal endothelium.

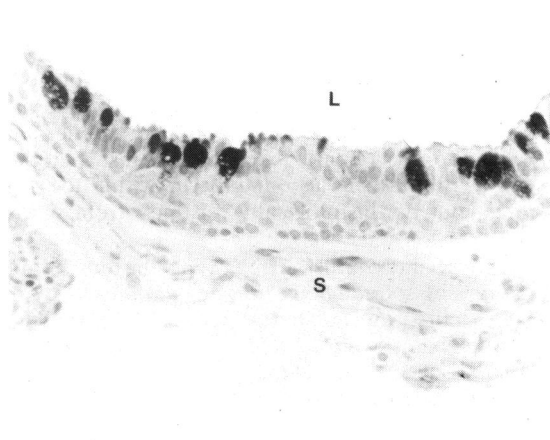


Fig. 4 (Case 1). Densely stained goblet cells are evident in the epithelial wall of the cyst. L, lumen; S, stroma. Periodic acid-Schiff stain.

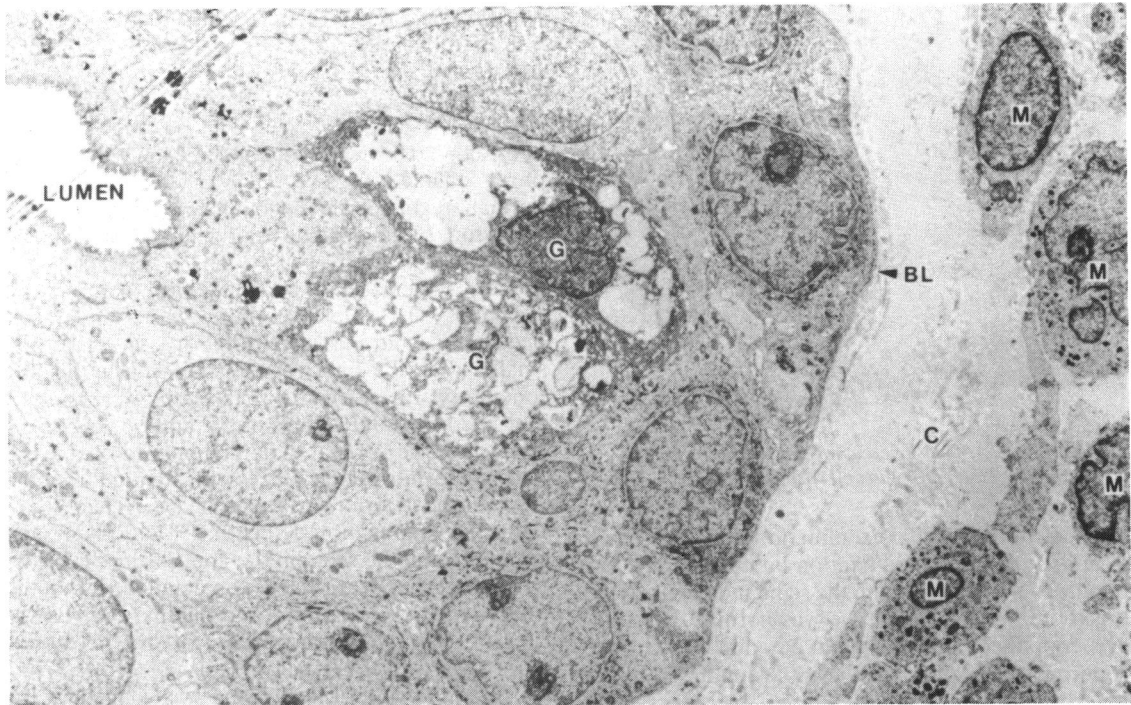


Fig. 5 (Case 1). Transmission electron micrograph of wall of cyst, illustrating lumen, stratified epithelial cells resting on basal lamina (BL), and two goblet cells (G). M, stromal melanocytes; C, stromal collagen.

Visual acuity was 20/20 OU. The right eye was normal. Left bulbar injection and photophobia were noted. The left cornea was clear; the anterior chamber was deep with 2+ cells and flare. A 4 mm iris




Fig. 6 (Case 2). Iris cyst contacts cornea in left eye.

cyst was present in the inferior anterior chamber (Fig. 6). The anterior surface of the cyst was translucent and contacted the corneal endothelium. The contents of the cyst were turbid, but there was no layered debris. The iris pigment epithelium appeared intact, and the lens was clear. Applanation pressures were 7 mmHg OD and 12 mmHg OS.

The iris cyst was completely excised by surgical iridectomy via an inferior limbal approach. Corrected postoperative visual acuity was 20/20 and intraocular pressure remained at 12 mmHg OS. Follow-up at one year showed no recurrence.

The tissue was fixed in Yanoff's solution and processed in paraffin. Histopathological study showed a cyst wall of two-layered non-pigmented epithelium (Fig. 7) with occasional goblet cells apparent on PAS staining. Immunocytochemical studies with monoclonal antibodies to intermediate filaments yielded a positive reaction only to epithelial cytokeratin markers.

CASE 3

A 2-year-old boy was referred to the University of Washington for evaluation of recently recognised anisocoria. The pregnancy and delivery were uncomplicated, with no history of amniocentesis or birth trauma. There was no known history of ocular

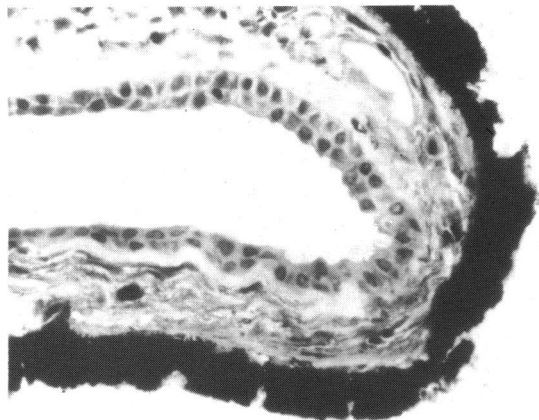


Fig. 7 (Case 2). Two-layered non-pigmented epithelial-lined iris cyst. Haematoxylin and eosin.

or head trauma. Initial examination showed central, steady, and maintained fixation bilaterally. The left pupil was 1 mm larger than the right and both reacted briskly to light. The left eye was normal. The right eye contained a transparent 2.5 mm cyst in the superonasal quadrant of the iris extending into the anterior chamber (Fig. 8). White debris was seen in the inferior part of the cyst. The anterior cyst wall was in contact with the cornea, causing mild stromal oedema. Careful review of family photographs showed the iris cyst to have been present by age 6 months.

Three months later the child developed photophobia and tearing, which responded to topical corticosteroids. The cyst appeared slightly larger at this time. Aspiration and injection of the cyst with trichloroacetic acid was performed at the University of Oregon. The cyst involuted initially but by age 4 years it was noted to have increased in size once

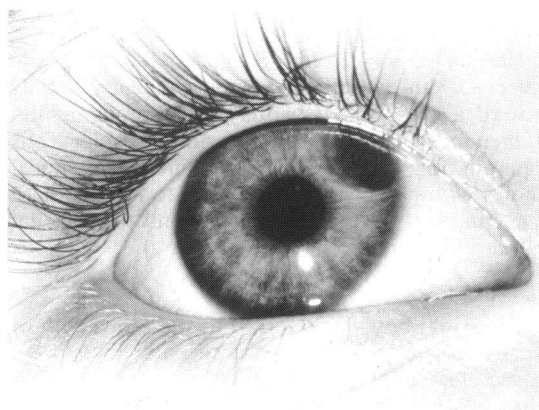


Fig. 8 (Case 3). Transparent iris cyst, right eye.

again. Visual acuity was 20/25, and the child had intermittent, minor symptoms of photophobia and irritation.

CASE 4

A 14-day-old boy was evaluated for a one-day history of an inflamed left eye. He was the product of a normal pregnancy and uncomplicated delivery, with no history of amniocentesis or trauma at birth. The right eye appeared normal. There was slight left eyelid erythema and oedema, with conjunctival injection. The left cornea was moderately oedematous and measured 10.0×10.5 mm (0.5 mm smaller than the right cornea). Tension by Schiøtz tonometry was normal in both eyes. A translucent cyst filled the inferior half of the anterior chamber, contacting the corneal endothelium and containing flocculent white material. Vessels extended from the iris over the anterior surface of the cyst. There was a faint transillumination defect of the underlying iris. Pigment could be seen on the anterior lens capsule; the lens itself appeared clear. No detailed view of the fundus was possible, but a red pupillary reflex was present, and ultrasonography of the posterior segment appeared normal.

The initial clinical impression was congenital iris cyst. Because of the significant ocular inflammation further investigations were thought to be indicated. Examination under anaesthesia and diagnostic paracentesis was performed at 18 days of age. Intraocular tensions by Perkins applanation was 11 mmHg OD and 13 mmHg OS. Aqueous fluid was withdrawn from the superior portion of the anterior chamber (away from the iris cysts) and submitted for cytological and microbiological examination. Cultures were negative and cytology revealed non-specific inflammatory response.

The inflammation and corneal oedema subsided with use of topical corticosteroids. Alternate day patching of the right eye was tolerated for six months. Recurrent episodes of inflammation occurred with cataract formation noted at 2½ years of age.

At 3 years of age a 2 cm mass was excised from the superonasal quadrant of the left orbit. Histopathological examination revealed a dermoid cyst consisting of stratified squamous epithelium with dermal appendages including pilosebaceous units.

At age 4 years marked photophobia and intermittent pain were present, with light perception vision OS. Clinical examination was remarkable for band keratopathy, cystic structure within the inferior two-thirds of anterior chamber, posterior synechiae, elevated intraocular pressure, and cataract. The left globe was enucleated and submitted to the Armed Forces Institute of Pathology in Washington, DC (AFIP Accession number 1927918).

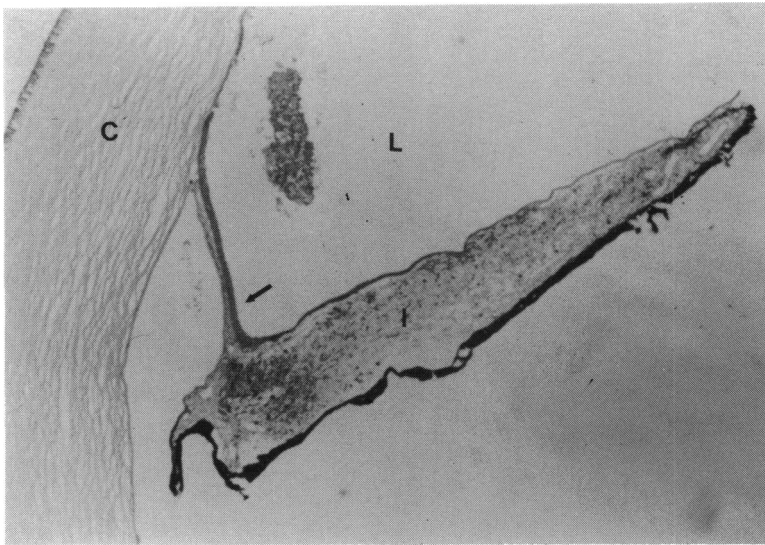


Fig. 9 (Case 4). Portion of epithelial cyst (arrow) lining the inferior two-thirds of the left anterior chamber. I, iris; C, cornea; L, lumen. Haematoxylin and eosin.

Light microscopy revealed a 1–3-cell layered non-pigmented epithelial cyst filling most of the anterior chamber (Figs. 9, 10). The cyst contacts both corneal endothelium and iris surface with areas of near-total iris stromal atrophy (Fig. 11). Goblet cells were not present. Cataractous lens remnants were present (Fig. 12). Mild optic atrophy was present.

Discussion

The aetiology of spontaneous or congenital non-pigmented iris cysts has been controversial. Early twentieth century reports suggest these cysts arise

from displaced surface ectoderm during lens vesicle formation.¹⁴⁻¹⁶ Some later authors have concurred,^{7 10 12 17-19} while others have argued in favour of a neuroepithelial origin from the anterior portion of the optic vesicle.^{3 9 20-25}

Histopathological specimens of spontaneous non-pigmented iris cysts typically consist of two to three layered squamous to cuboidal epithelium. Numerous reports demonstrate goblet cells,^{7 8 10 12 13 17} while they are absent in a nearly equal number of reports.^{3 4 9-11 13} The presence of goblet cells within some iris cysts clearly establishes surface epithelium as the cellular origin in those cases. The absence of goblet cells in

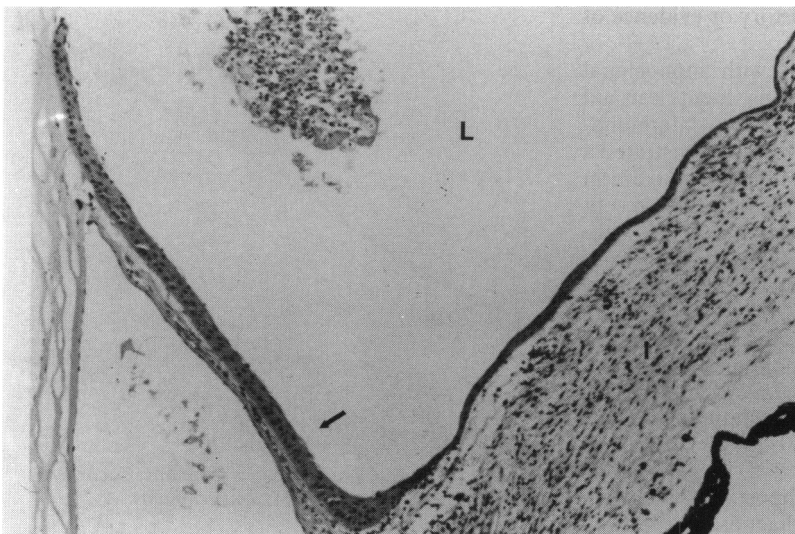



Fig. 10 (Case 4). Squamous epithelial cyst (arrow) filling inferior anterior chamber of right eye. I, iris; L, lumen. Haematoxylin and eosin.

Fig. 11 (Case 4). Part of cyst showing single epithelial layer (arrows) with nearly-total loss of iris stroma. P, iris pigment epithelium; L, lumen. Haematoxylin and eosin.



spontaneous non-pigmented cysts raises the possibility of other cellular origins. It remains possible that more than one cellular origin and pathogenic mechanism exist.

Goblet cells were readily recognised in two of our three cases in which the histopathology was examined. Surface epithelium is undoubtedly the origin of these iris cysts; however, it does not establish the manner in which these cells are entrapped within the iris stroma. Various authors believe that occult trauma is the cause in many, if not all, spontaneous non-pigmented iris cysts.^{8 26 27} One report suggests that intrauterine trauma from amniocentesis may be a factor.²⁸ There was no history of amniocentesis or other prenatal trauma in our cases. Similarly, there was no history or evidence of birth or postnatal trauma.

Immunohistochemical studies with monoclonal antibodies to intracytoplasmic constituents can aid diagnosis of various ophthalmic entities.²⁹ Immunocytochemical studies of cases 1 and 2 demonstrated a positive reaction only with epithelial cytokeratin markers. These correlate with tonofilaments present at desmosomal junctions. Although this finding substantiates the epithelial origin of the cysts, it does not differentiate between surface ectodermal and neuroectodermal origin.

A recent case report demonstrated hyaluronic acid within epithelial cells of a spontaneous nonpigmented iris cyst.³ The authors favoured a neuroepithelial origin, since a similar staining characteristic can be obtained from ciliary body epithelium.

Although our four cases had a varied clinical course, they do have certain important features in common. All cases were either diagnosed or showed

some iris abnormality within the first two years of life. The diagnosis was made in three of the four cases during general examination or following awareness of a subtle iris anomaly. There was no known history of intrauterine or postnatal trauma in any of the four

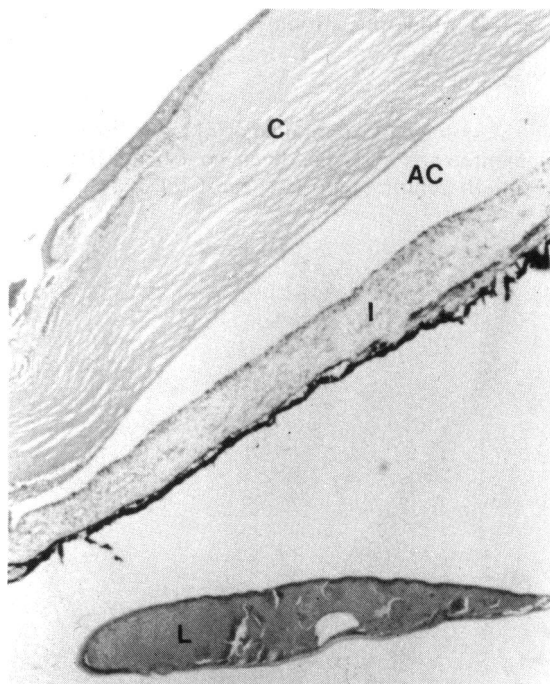


Fig. 12 (Case 4). Cataractous lens remnants. C, cornea; AC, anterior chamber; I, iris; L, lens remnants. Haematoxylin and eosin.

cases. Three of the four cases had some degree of intraocular inflammation, although it was severe in only one case (4). The clinical course in three of the four cases was characterised by gradual enlargement over years with occasional, mild inflammatory episodes. Treatment was initiated owing to impairment in visual acuity or concern over recent enlargement.

Most reports indicate that iris cysts are not inflammatory in nature and generally produce symptoms only when the visual axis is compromised, but there are earlier reports of uveitis and glaucoma complicating iris cysts.⁸ Two of our cases (2 and 3) had mild intraocular inflammation, while one case (4) was associated with episodic severe inflammation. Presumably this resulted from release of mucous or protein debris, causing an inflammatory response and, when severe, blockage of trabecular meshwork. With large cysts a secondary angle closure mechanism may also be contributory.

Several features of case 4 were unusual and deserve comment. The cyst filled much of the anterior chamber, contacting both the corneal endothelium and iris. From histopathological examination only it is not possible to determine if this originated from the iris or from the anterior chamber. The earlier clinical appearance, however, suggested an iris origin. The areas of marked iris stromal loss are presumably secondary to pressure induced ischaemic changes. The presence of cataractous lens remnants is puzzling and suggests possible lens trauma during the paracentesis, though this was not thought to have occurred. There was no history of amniocentesis or other pre- or postnatal trauma.

The occurrence of an orbital dermoid cyst and intraocular epithelial cyst in the same patient is of interest. Dermoid cysts are thought to arise from sequestered surface epithelium.³⁰ An analogous pathogenic mechanism is likely in the aetiology of iris or anterior chamber non-pigmented epithelial cysts. We are unaware of the simultaneous occurrence of these epithelial cysts in the same patient. Presumably the association here is coincidental.

Several forms of management have been advocated for non-pigmented iris cysts. Congenital iris cysts should be observed for growth if the visual axis is spared. Their characteristic slow growth patterns may allow for prolonged observation and avoidance of operative complications during an amblyogenic age. Of particular interest are reports of spontaneous regression of non-pigmented iris cysts.³¹ When the visual axis is compromised, surgical excision remains the most commonly employed treatment. Various forms of excision exist, including sector iridectomy,^{2-4 7-10 17 32 33} iridectomy plus corneal curettage,²⁷ excision plus posterior corneal lamellar

resection,³⁴ iridectomy plus cryotherapy of possible limbal remnants,^{33 35 36} iridocyclectomy,^{34 37 38} and penetrating keratoplasty plus iridocyclectomy.³⁹ Recurrences have been reported, including formation of sheet-like epithelial ingrowths.^{13 33 36 37 40} These recurrences are most notable in cases of incomplete excision or piecemeal excision as with suction-cutting instruments.³³

Certain non-excisional treatments have been largely abandoned owing to inherent complications or frequent cyst recurrence, including electrolysis^{41 42} and diathermy.^{26 43 44} Cyst aspiration with injection of chemicals such as iodine⁴⁵ and trichloroacetic acid⁴⁶ may be effective, but concern over possible intraocular damage has limited their popularity. Case 3 demonstrates recurrence after trichloroacetic acid instillation.

Photocoagulation with or without cyst aspiration has been used for acquired non-pigmented iris cysts.^{37 47-50} However, multiple treatments may be required and recurrences may occur.^{37 51} Photocoagulation of congenital iris cysts in children would require use of a photocoagulation device suitable for recumbent patients under general anaesthesia.

We believe that some spontaneous non-pigmented iris cysts are congenital and occur in the absence of trauma. The correct diagnosis is usually established in early childhood. Episodes of intraocular inflammation are frequent. Observation for growth is indicated prior to treatment. The cellular origin is usually, and possibly always, surface epithelium. Developmental entrapment during lens vesicle formation appears to represent a plausible pathogenic mechanism.

We gratefully acknowledge the assistance of Ian W McLean, MD, of the Armed Forces Institute of Pathology in Washington, DC, for providing histopathological slides of case 4, and D Frank Milam Jr, MD, for evaluation of the pathology specimens.

Supported in part by NIH Research Grant EY-01730, by the Lions' Sight Conservation Foundation of Washington and Northern Idaho, and in part by an unrestricted award from Research to Prevent Blindness, Inc. Dr Bunt-Milam is a William and Mary Greve International Research Scholar of Research to Prevent Blindness, Inc.

References

- Shields JA, Kline MW, Augsburger JJ. Primary iris cysts: a review of the literature and report of 62 cases. *Br J Ophthalmol* 1984; **68**: 152-66.
- Farmer SG, Kalina RE. Epithelial implantation cyst of the iris. *Ophthalmology (Rochester)* 1981; **88**: 1286-9.
- Rush JA, Weinstein GW, Meriwether WA. Spontaneous non-pigmented iris cyst. *Arch Ophthalmol* 1982; **100**: 304-5.
- Guey D, Weisinger H. Spontaneous cyst of the iris stroma. *Am J Ophthalmol* 1957; **44**: 106-7.
- Bruce G. Aberrant glandular tissue in iris. *Trans Am Acad Ophthalmol* 1952; **56**: 47-51.
- Hunter WS. Aberrant intraocular lacrimal gland tissue. *Br J Ophthalmol* 1960; **44**: 619-25.

- 7 Sugar HS, Nathan LE. Congenital epithelial cysts of the iris stroma. *Ann Ophthalmol* 1982; **14**: 483-5.
- 8 Layden WE, Torczynski E, Font RL. Mucogenic glaucoma and goblet cell cyst of the anterior chamber. *Arch Ophthalmol* 1978; **96**: 2259-63.
- 9 Roy RH, Hanna C. Spontaneous congenital iris cysts. *Am J Ophthalmol* 1971; **72**: 97-108.
- 10 Hvidberg-Hanson J, Larsen FE. Congenital iris cysts. A case study by light and electron microscopy. *Acta Ophthalmol (Kbh)* 1972; **50**: 501-14.
- 11 Laval J. Spontaneous cyst of the iris. *Am J Ophthalmol* 1947; **30**: 55-7.
- 12 Mullaney J, Fitzpatrick C. Idiopathic cyst of the iris stroma. *Am J Ophthalmol* 1973; **76**: 64-8.
- 13 Naumann G, Green WR. Spontaneous nonpigmented iris cysts. *Arch Ophthalmol* 1967; **78**: 496-500.
- 14 Koch K. Kongenitale Iriscyste. *Klin Monatsbl Augenheilkd* 1921; **67**: 407-10.
- 15 Nadal R. Note sur la pathogénie des kystes séreux congénitaux de l'iris. *Arch Ophthalmol* 1911; **31**: 363-73.
- 16 Streiff JJ. Kryptenblatt und kryptengrundblatt der Regenbogenhaut und die Entstehung der serösen Cysten an der vorderen Seite der Iris. *Arch Augenheilkd* 1904; **50**: 56-119.
- 17 Klein BA, Tanner GS. Congenital epithelial cyst of the iris stroma. *Am J Ophthalmol* 1963; **55**: 291-5.
- 18 Thiel R. Secundärglaukom nach epithel-oder endothel-einwanderung in die Vorderkammer. *Klin Monatsbl Augenheilkd* 1960; **137**: 705-20.
- 19 Duke-Elder S, Perkins ES. Cysts and tumours of the uveal tract. In: Duke-Elder S, ed. *System of ophthalmology*. St Louis: Mosby, 1966; **9**: 754-63.
- 20 Inselius E. Die spontanen Iriscysten, ihre Pathogenese und Entwicklung. *Klin Monatsbl Augenheilkd* 1908; **46**: 300-10.
- 21 Ginsberg S. Uvea. In: Henle F, LuBarsch O, eds. *Handbuch der speziellen pathologischen Anatomie und Histologie*. Berlin: Springer, 1928; **11**(1): 389-577.
- 22 Bergemann H. Beitragzuden angeborenen Iriscysten. *Arch Augenheilkd* 1910; **66**: 37-42.
- 23 Politzer G. Die Entstehung der spontanen epithelialen Iriscysten. *Graefes Arch Klin Exp Ophthalmol* 1953; **153**: 497-503.
- 24 Mann I. *Developmental abnormalities of the eye*, 2nd ed. London: British Medical Association, 1957: 295.
- 25 Kozart DM. Spontaneous cysts of the ciliary epithelium. *Trans Am Acad Ophthalmol* 1970; **75**: 534-47.
- 26 Hogan MJ, Goodner EK. Surgical treatment of epithelial cysts of the anterior chamber. *Arch Ophthalmol* 1980; **64**: 286-91.
- 27 Maumenee AE, Shannon RG. Epithelial invasion of the anterior chamber. *Am J Ophthalmol* 1956; **41**: 929-42.
- 28 Cross HE, Maumenee AE. Ocular trauma during amniocentesis. *Arch Ophthalmol* 1973; **90**: 303-4.
- 29 Messmer EP, Font RL. Applications of immunohistochemistry to ophthalmic pathology. *Ophthalmology (Rochester)* 1984; **91**: 701-7.
- 30 Howard GM. Cystic tumours. In: Duane TD, Jaeger EA, eds. *Clinical ophthalmology*. Philadelphia: Harper and Row, 1985; **2**: Ch. 31: 1.
- 31 Winthrop SR, Smith RE. Spontaneous regression of an anterior chamber cyst: a case report. *Ann Ophthalmol* 1981; **13**: 431-2.
- 32 Brouchoff SA, Kenyon KR, Foulks GN, Green WR. Epithelial cysts of the iris following penetrating keratoplasty. *Br J Ophthalmol* 1980; **64**: 440-5.
- 33 Bruner WE, Michaels RG, Stark WJ, Maumenee AE. Management of epithelial cysts of the anterior chamber. *Ophthalmic Surg* 1981; **12**: 279-85.
- 34 Sugar HS. Further experience with posterior lamellar resection of the cornea for epithelial implantation cyst. *Am J Ophthalmol* 1967; **64**: 291-9.
- 35 Ferry AP, Naghdi MR. Cryosurgical removal of epithelial cyst of iris and anterior chamber. *Arch Ophthalmol* 1967; **77**: 86-7.
- 36 Stark WJ, Michaels RG, Maumenee AE, Cupples H. Surgical management of epithelial ingrowth. *Am J Ophthalmol* 1978; **85**: 772-80.
- 37 Sugar J, Jampol LM, Goldberg MF. Argon laser destruction of anterior chamber implantation cysts. *Ophthalmology (Rochester)*. 1984; **91**: 1040-3.
- 38 Malbran ES, Charles D, Garrido CM, Croxato O. Iridocyclectomy technique and results. *Ophthalmology (Rochester)* 1979; **86**: 1048-66.
- 39 Eiferman RA, Rodrigues MM. Squamous epithelial implantation cyst of the iris. *Ophthalmology (Rochester)* 1985; **88**: 1281-5.
- 40 Harbin TS, Maumenee AE. Epithelial downgrowth after surgery for epithelial cyst. *Am J Ophthalmol* 1974; **78**: 1-4.
- 41 Wilson W. Iris cyst treated by electrolysis. *Br J Ophthalmol* 1964; **48**: 45-9.
- 42 Kennedy AJ. Treatment of cysts of the iris with electrolysis. *Arch Ophthalmol* 1956; **55**: 522-5.
- 43 Vail D. Treatment of cysts of the iris with diathermy coagulation. *Am J Ophthalmol* 1954; **38**: 513-18.
- 44 Alger EM. Large implantation cyst of the iris treated by aspiration and injection of iodine. *Arch Ophthalmol* 1932; **7**: 984-6.
- 45 Okun E, Mandell A. Photocoagulation as a treatment of epithelial implantation cysts following cataract surgery. *Trans Am Ophthalmol Soc* 1974; **72**: 170-83.
- 46 Swan KC. Epithelial cell cysts of the anterior chamber treated by acid injections. *Doc Ophthalmol Proc* 1979; **18**: 362-70.
- 47 Scholz RT, Kelly JS. Argon laser photocoagulation treatment of iris cysts following penetrating keratoplasty. *Arch Ophthalmol* 1982; **100**: 926-7.
- 48 Cleasby GW. Photocoagulation of iris-ciliary body epithelial cysts. *Ophthalmology (Rochester)* 1971; **75**: 638-42.
- 49 Honrubia FM, Brito C, Grijalbo MP. Photocoagulation of iris cyst. *Trans Ophthalmol Soc UK* 1982; **102**: 184-6.
- 50 Chara K. A case of spontaneous cyst of the iris treated with photocoagulation. *Jpn J Clin Ophthalmol* 1976; **30**: 99-107.
- 51 Butler TH. A case of cyst of the iris. *Trans Ophthalmol Soc UK* 1921; **41**: 452-5.

Accepted for publication 9 May 1986.