

An association between 'Desert lung' and cataract – a new syndrome

NOUR-EL-DIN HAWASS

From the College of Medicine, King Saud University, Riyadh, Saudi Arabia

SUMMARY Sixteen cases of desert lung with cataracts were previously reported on, and an additional 14 cases have now been encountered from the same area of which 13 had cataracts. The association of cataract with desert lung was not commented on in the previous report, because it was thought to be coincidental. It now appears to be real rather than coincidental. Analysis of these 33 patients showed the following: none had significant clinical signs; *x*-ray findings were mainly those of micronodular miliary infiltrates; 88% were found to have cataracts; 85% were females. The frequency of cataract among patients over the age of 50 years coming to the hospital for eye problems was 26%. These figures showed a distinct relationship between desert lung and cataract in the Arabian desert. The causal relationship is not as yet clear, but 'tandoor' baking is suggested as the main factor.

The term 'desert lung' has been used to describe a non-occupational pneumoconiosis which is relatively common in desert areas. Its cause is prolonged, excessive exposure to atmospheric dust. Cases have been reported from the Sahara Desert,² Libyan Desert,³ and Negev Desert.⁴

Nineteen cases of desert lung from the Najd area (the central province of Saudi Arabia) have previously been reported from this centre,¹ of which 16 were found to have cataracts. Of this cataract subgroup 11 cases had undergone general anaesthesia for senile mature cataracts, while five cases were retrospectively diagnosed and had not been operated upon. An additional 14 cases of desert lung have now been encountered from the same region, 13 of which also have cataracts. This concurrent finding of cataracts was not commented upon in the previous report, because initially it was considered to be coincidental and the cataract due to the aging process. The frequent association of these two apparently unrelated diseases, desert lung and cataract, suggests the possibility of a common aetiology.

The aim of this study is to describe briefly the 29 patients who had both desert lung and cataracts and to suggest possible causes of this combination.

Material and methods

Cases. During a four-year period a total of 38 570

Correspondence to Dr N D Hawass, Department of Radiology (40), College of Medicine, PO Box 2925, Riyadh 11461, Saudi Arabia.

chest *x*-rays were seen at King Abdul Aziz University Hospital in Riyadh, Saudi Arabia. Of these patients 4090 were over the age of 50 years, and among these were the majority of desert lung cases. Among these 4090 patients 33 cases were found to have desert lung (one case was 48 years old) and 29 of these 33 cases were found to have cataracts. Desert lung was diagnosed mainly by the presence of miliary or predominantly miliary mottling in chest *x*-rays in asymptomatic patients who lived in desert areas and had no occupational history. These patients showed normal results from relevant laboratory tests. (Three cases with desert lung were confirmed by lung biopsies.) The cases detected were then age matched with a control group from a similar geographic and ethnic background in the Najd area (central province of Saudi Arabia).

Controls. Six hundred and twenty-eight controls over the age of 50 years were obtained from a series of patients who attended the Ophthalmology Clinic and were referred for chest *x*-ray at King Abdul Aziz University Hospital in Riyadh. The chest *x*-rays of these patients showed no evidence of desert lung.

Statistics. Student's *t* test was used to determine the relationship between sex and mean age among desert lung cases and among controls. The χ^2 test was used to study the association between desert lung and sex of cases and controls. Fisher's exact test was used to compare cataract between cases and controls in

Table 1 Sex distribution and mean age of cases and controls

Sex	Desert lung cases		Controls	
	Mean age (years)	Standard deviation	Mean age (years)	Standard deviation
Males	69.0	13.0	63.0	9.6
Females	59.2	6.0	60.5	8.2

Table 2 Association between desert lung and sex

Sex	Desert lung cases		Controls		Total	
	Number	Percent	Number	Percent	Number	Percent
Males	5	15	326	52	331	50
Females	28	85	302	48	330	50
Total	33	100	628	100	661	100

males and females. The incidence of desert lung was determined for the total survey population of 38 570 and for those over 50 years.

Results

FREQUENCY OF DESERT LUNG

Among 38 570 chest *x*-rays 33 cases of desert lung were identified (0.086%). Their ages ranged from 48 to 90 years; all but one were over 50 years. A frequency of 0.78% of desert lung cases over 50 years old was found.

AGE OF CASES AND CONTROLS

The mean age by sex of cases and controls is shown in Table 1. The mean age of female cases and controls was not statistically significantly different (Student's *t* test, $p > 0.05$). The mean age of male cases and controls was also not statistically different (Student's *t* test, $p > 0.05$). The male patients were about 10 years older than the female, but this result was not statistically significant (Student's *t* test, $p > 0.05$). The lack of significance may be due to the small number of male cases analysed.

SEX OF PATIENTS

The relationship of sex to desert lung is summarised in Table 2. Female sex was very strongly associated with desert lung ($\chi^2 = 16.9$, $p < 0.001$).

PRESENCE OF CATARACTS

The frequency of cataracts in female cases was 93% compared with 25% in female controls, a highly significant difference (Fisher's exact test $p < 0.001$). No significant difference was found in the frequency of cataracts between male cases and controls (Fisher's exact test, $p > 0.05$).

Table 3 Cataract morphology

Number of Cases	Cataract morphology
<i>Right lens</i>	
1	Anterior subcapsular (ASC) and posterior subcapsular (PSC)
1	Posterior cortical (PC) with posterior subcapsular (PSC)
16	Posterior subcapsular (PSC). Of this total, three had associated nuclear sclerosis (NS) and one had associated posterior cortical (PC)
5	Nuclear sclerosis (NS). Two cases had associated posterior subcapsular (PSC)
4	Complete opacification.
<i>Left lens</i>	
1	Anterior subcapsular (ASC) and posterior subcapsular (PSC)
3	Posterior cortical (PC). One case had associated posterior subcapsular (PSC)
13	Posterior subcapsular (PSC) One case was associated with posterior cortical (PC) and one with nuclear sclerosis (NS)
6	Nuclear sclerosis (NS). Two cases had associated posterior subcapsular (PSC)
4	Complete opacification

CATARACTS

Twenty-nine out of 33 patients with desert lung were found to have cataract; one case with bilateral corneal opacities is not included here. All cases of cataracts were bilateral. Cataract was defined as any lens opacity on or inside the lens not necessarily requiring operation.

MORPHOLOGY OF CATARACTS (Table 3)

The morphological description of two patients was confined to bilateral mature cataract in both lenses, and no further details were available. In three cases microscopic examination of lenses following extraction revealed homogeneous, structureless, eosinophilic material.

RADIOLOGICAL FINDINGS

The appearance on chest radiographs of desert lung cases showed (1) Uniform micronodular miliary infiltrates (Figs. 1A, 1B), which were dense and well defined (15 cases). Some had an appearance reminiscent of low grade alveolar microlithiasis but with a widespread distribution. (2) In addition to miliary infiltrates there was fine reticular shadowing which was evenly and equally distributed in both lungs (15 cases). (3) Miliary infiltrates with thickening of bronchial wall (eight cases). (4) Miliary infiltrates with Kerley B lines (three cases).

None of the patients had significant clinical pulmonary symptoms or signs. Relevant laboratory tests for all patients gave normal results. Seven patients had pulmonary function tests done; four

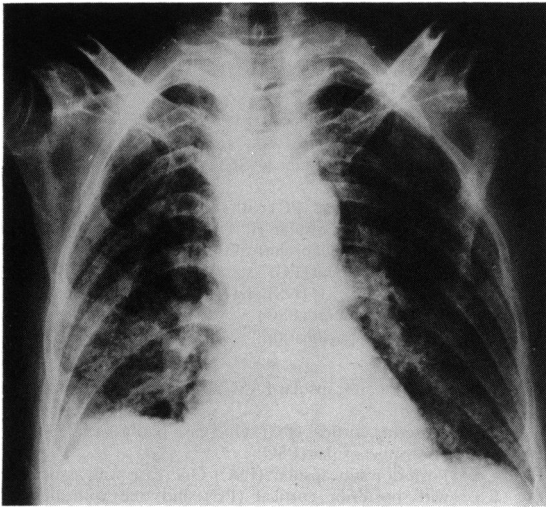


Fig. 1A Typical desert lung in a 62-year-old female patient showing diffuse micronodular pattern in both lungs.

were normal and three showed mild restrictive changes.

Transbronchial needle biopsy was performed in three cases and showed that the pulmonary miliary nodules seen on the chest radiographs were full of dust particles, being birefringent under polarised light (Fig. 2).

Discussion

Many physicians are not familiar with the disease of desert lung, so that most of these cases are misdiagnosed. Desert lung is mainly due to the high

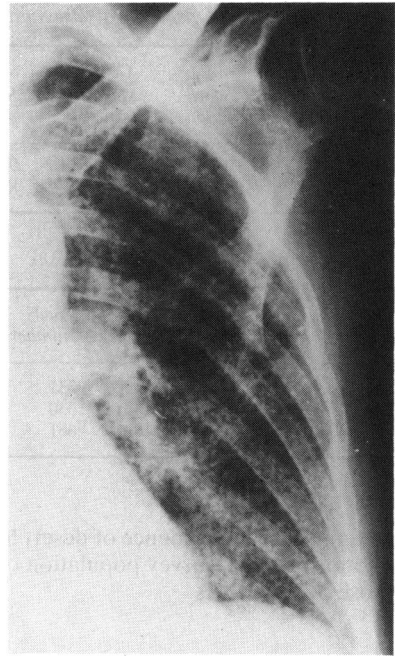


Fig. 1B Close-up view of left lung.

silica content of the inhaled particles. As much as 70% is composed of fine particles of sandy dust. The prevalence of the disease among females is not clearly understood, but may be explained by their daily activities which involve cleaning, dusting, and herding, exposing them to dust and sand much more frequently than men throughout the years.

The disparity between the average age of males (69 years) and females (59 years) may be explained by

Fig. 2 Section of the lung nodule showing lung tissue and refractile dust particles. Polarised light.

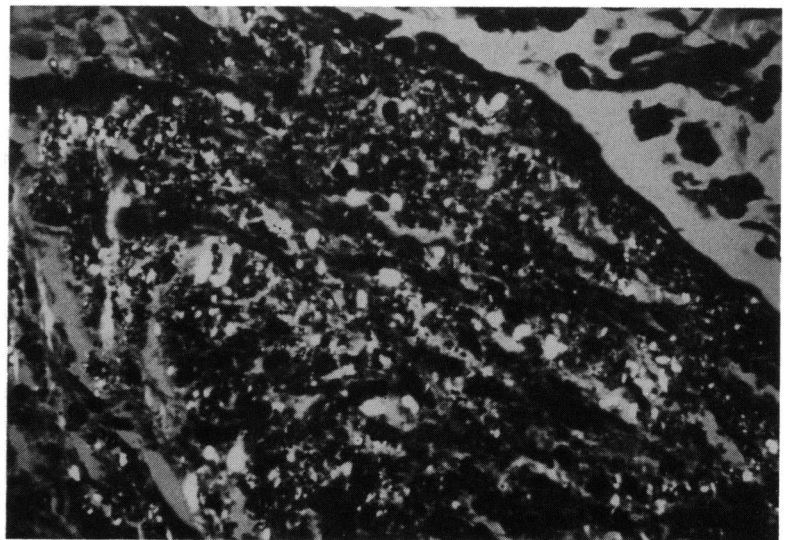


Table 4 Association between desert lung and cataracts by sex

Sex	Desert lung cases						Controls					
	Males		Females		Total		Males		Females		Total	
	No	%	No	%	No	%	No	%	No	%	No	%
Cataracts	3	60	26	93	29	88	85	26	77	25	162	26
Non-cataracts	2	40	2	7	4	12	241	74	225	75	466	74
Total	5	100	28	100	33	100	326	100	302	100	628	100

the principal work activities of men, which result in far less exposure to fine particles of dust – though disparity may be false owing to the small number of male cases analysed. It was noted that older people showed advanced radiological changes, an observation which was not found by Hirsh *et al.*⁴ After taking into consideration that there is widespread exposure to atmospheric dust, the low incidence of the disease, particularly in male patients, and that all patients were asymptomatic, one can conclude that the atmosphere has a benign effect on the lungs. In two of the three patients with restrictive changes on the pulmonary function tests, chest radiographs showed the micronodular and reticular pattern. This might suggest that the micronodular pattern alone is more benign than micronodular and reticular infiltrates. However, further study of more cases is needed to verify such a correlation. The one patient with bilateral complete corneal opacities has not been included because cataract in this patient cannot be proved or excluded. Thickening of the bronchial wall was seen in eight patients, but this finding is relatively common among even young, healthy people in the region and is probably caused by the same dusty atmosphere.

The association of desert lung and cataract (Table 4) is highly significant. Furthermore, the actual frequency of cataracts among the population over the age of 50 years must be smaller because our sample represents patients from ophthalmology clinics and not from the general population. Correlation of severity of cataracts with the extent of pulmonary changes of desert lung has not been made in the present study.

A possible explanation for the concomitance of these diseases may be explained by the use of open fire of the 'tandoor' in the rural areas. A tandoor is a one-metre high, barrel-like apparatus made of potter's clay, erected vertically above the ground and in which a fire is lit. As the tandoor is used daily for baking in the rural area, the women have to lean over and look inside it, thus exposing themselves to long periods of high temperatures and hot air inhalation. Exposure to tandoor heat is quite intense, and,

since the women have frequently to check the tandoor, they sometimes have strands of hair or even eyelashes singed. This persistent exposure to intense heat may have a dual effect: (1) damage to respiratory cilia and the resultant predisposition of the lungs to atmospheric dust deposition; this might also explain the prevalence of desert lung in female patients. (2) development of cataracts as a consequence of the long exposure of the eyes to high temperatures, a condition similar to 'glassblower's cataract.'

It is well known that exposure to high temperatures which do not produce any significant abnormality in the rest of the body will produce pathological effects on the eye. Infrared injury absorbed by the iris is transmitted to the lens and causes cataracts.⁵ The reasons for this are two fold⁶: (1) heat in the anterior segment of the eye, particularly on the pigment of the iris, will induce metabolic changes that are deleterious to the lens; (2) as the lens is avascular, dissipation of heat takes place from it at a much slower rate than from the rest of the body.

The morphological prevalence of posterior subcapsular cataracts in these patients is consistent with chronic exposure to heat and similar to the chronic exposure of infrared radiation by glassblowers and furnace workers, which causes posterior subcapsular cataracts.⁷

I would like to thank Dr Surur Shahozad, consultant ophthalmologist, University Hospital in Riyadh, for helping in the retrospective analysis of the incidence of cataracts; Dr Abdul Hafid, professor of pathology, for providing the histology section; and Professor Whitehouse for his helpful advice. I gratefully acknowledge the assistance of Dr Theresa L Swecney, of the Department of Community and Family Medicine, King Saud University, for her statistical advice. I also thank the radiologists at both university hospitals in Riyadh for their cooperation in this study.

References

- Hawass ND. Non-occupational pneumoconiosis (desert lung). *Proceedings of XV International Congress of Radiologists*, Chest and Breast volume. Brussels, Luxembourg: Interimages, 1983.
- Policard A, Collet A. Deposition of silicosis dust in the lungs of the inhabitants of the Saharan regions. *Arch Indust Hyg Occup Med* 1952; **5**: 527–34.
- Fossati C. Sulla possibilità e sulla frequenza della silicosis polmonare tra gli abitanti del deserto libico. *Med Lav* 1969; **60**: 144–9.
- Hirsch M, Bar-Ziv J, Lehmann E, Goldberg G. Simple siliceous pneumoconiosis of Bedouin females in the Negev Desert. *Clin Radiol* 1974; **25**: 507–10.
- Newell FW. *Ophthalmology principles and concepts*. 5th ed St Louis: Mosby, 1982: 171.
- Cogan D. Radiant Energy. In: Sorsby A, ed. *Modern ophthalmology*. 2nd ed. London: Butterworth, 1972: 2: 685–91.
- Peyman GA, Sanders DR, Goldberg MR. *Principles and practice of ophthalmology*. Philadelphia: Saunders 1980: 1: 520.

Accepted for publication 26 September 1986.