

Natural history of retinopathy of prematurity

W E SCHULENBURG, A PRENDIVILLE, AND R OHRI

From the Departments of Surgery and Paediatrics, Hammersmith Hospital, London W12 0HS

SUMMARY Sixty-nine infants at risk of developing retinopathy of prematurity (ROP) were entered into a prospective study to assess the incidence and natural history of the disease. Seventeen infants developed ROP, and in six eyes the disease progressed to stage IV ROP. The natural regression of a pupillary membrane and physiological vitreous haze was not influenced by the onset of ROP. Progression from stage I to stage III was rapid and the rate was influenced by the zone affected. Congestion and tortuosity of vessels in the posterior pole always signified stage III ROP. Progression from stage III to stage IV ROP was slower; it was characterised by the development of vitreoretinopathy, signified by the sudden onset of a vitreous haze. Iris congestion associated with poor mydriasis may be a grave sign indicating imminent retinal detachment. Cicatricial ROP can be divided into retinal and vitreoretinal cicatricial disease directly related to the stage of active disease reached. ROP is characterised by its self limiting nature, but the stage at which it becomes inactive varies and will influence the final outcome.

Retinopathy of prematurity (ROP) remains a persistent problem threatening visual development to a greater or lesser extent in the premature infant.¹ With the advent of vitreoretinal surgery successful anatomical results have been reported in eyes with advanced cicatricial disease.² The functional success in these eyes is doubtful, and whether surgery should be advised in such cases may pose an ethical question. A renewed interest has developed in the treatment of ROP by cryosurgery during the active stage of retinopathy.³⁻⁵ One of the problems experienced with cryosurgery is the lack of specific selection criteria for treatment at the appropriate time. The typical retinal changes characteristic of ROP and their evolution have been well reported in the past.^{6,7} Nevertheless we still have a poor understanding of the natural history of the disease and cannot explain the striking phenomenon of spontaneous regression. A better understanding of the disease is of fundamental importance if treatment of it in the acute stage is planned in the future. We report our experience of the natural history of ROP.

Materials and methods

Sixty-nine patients at risk of developing ROP

Correspondence to W E Schulenburg, FRCS, Lower Medical Corridor, Hammersmith Hospital, Du Cane Road, London W12 0HS.

admitted to the Neonatal Intensive Care Unit at the Hammersmith Hospital between May 1983 and February 1985 were entered into a prospective study to determine the incidence and natural history of the disease. The criteria for selecting high risk infants were the following: infants with a gestational age below 30 weeks and/or a birth weight below 1500 g. All other infants admitted to the unit during the study period not fulfilling these criteria and exposed to oxygen were also examined, but none of them developed ROP.

Eye examination was scheduled at three weeks after birth if the infant's condition allowed, and it was repeated at weekly intervals by one of the authors (WES) as long as the infant remained in the Intensive Care Unit. Selected infants were examined at more frequent intervals—that is, progressive stage III ROP on serial examination. Mydriasis was achieved by the instillation of phenylephrine 2.5% drops and cyclopentolate 1% drops one hour and 30 minutes before examination. The fundus was examined by indirect ophthalmoscopy with the aid of a 28 dioptre lens and scleral indentation only where indicated—that is, to differentiate between zone II and zone III disease or where inadequate information was obtained without indentation. We found that scleral indentation was essential whenever the infant speculum was used, resulting in blepharospasm and a Bell's phenomenon. When the lids were prised open

by the examiner, blepharospasm was not stimulated and adequate information could be obtained with a little patience. This technique was also followed with fundus photography, and no sedation was required. Retinal changes were recorded with a Zeiss fundus camera in selected eyes only.

After discharge the infants entered into the study were re-examined in the outpatients department at regular intervals. Ocular findings associated with prematurity were recorded and included the presence of a pupil membrane (*tunica vasculosa lentis*) and a physiological peripheral vitreous haze.

ROP changes were recorded in accordance with the international classification as soon as it became available. Stage I is characterised by the formation of a demarcation line, stage II by the formation of a retinal lesion with height and volume extending out of the retinal plane, stage III by an increase in height and volume of the retinal lesion associated with fibrovascular proliferation, and stage IV when retinal detachment develops. The retinal lesion is localised by dividing the retina into three zones centred round the optic disc. Zone I consists of a circle with the radius twice the optic disc-macula distance, zone II is more peripheral and extends from the edge of zone I to the edge of a circle with a radius of the optic disc-nasal-ora distance, and zone III is a crescent peripheral to the edge of zone II and does not involve the nasal 3 clock hours of the retina.⁸ Iris vascular changes and changes in pupil dynamics associated with ROP were recorded.

The time of onset was recorded when a demarcation line developed. As regression is a gradual process, it was difficult to be precise about the time it started. Thus, in relating the age of the infant to the stage of ROP, the age at which the maximum stage ROP had developed was used instead of the age at regression, to enable more accurate comparison between individual eyes. Infants whose eyes reached stage III plus with no evidence of regression on serial examination were entered into a paired eye study to assess the value of cryosurgery, the results of which will form part of a future study. Selection of these cases for cryosurgical treatment was based on the experience of Kingham previously reported.⁹ The control eye only was considered to the end stage of ROP in this study on the natural history, and all treated eyes excluded as soon as treatment was applied.

Results

INCIDENCE

Of 69 high risk infants 17 (24.5%) developed some degree of ROP. All cases were bilateral and sym-

metrical with the exception of two cases. In one of these the more severely affected eye had a persistent posterior hyaloid artery, and, in the second, one eye progressed to stage III and the second eye to stage II ROP only. In 34 eyes visual function was lost in seven, five of which did not receive cryosurgery, and the natural history could be followed from the time of onset to advanced cicatricial disease with a total retinal detachment. These included one case with bilateral zone I ROP and three control eyes with zone II ROP. One infant with zone I ROP was too ill to be considered for cryosurgery and eventually died at the age of 4 months. In 11 out of 17 infants no retinopathy was present at the initial examination.

PUPILLARY MEMBRANE AND VITREOUS HAZE

In 28 out of 34 eyes that eventually developed ROP a pupillary membrane was present at the initial examination. A physiological peripheral vitreous haze was present at the initial examination in 20 out of 34 eyes and cleared within four to five weeks after birth. The mean age at which regression of the pupillary membrane and peripheral vitreous haze took place was equal for both the ROP and non-ROP groups.

RETINAL VASCULAR CHANGES

In four eyes of two infants the onset of a demarcation line was observed to be preceded by dilatation and increased tortuosity of peripheral capillaries directly behind the margin of vasogenesis. A demarcation line (stage I) developed within one to two weeks thereafter in these eyes. Since the conclusion of this study we have observed that these minor vascular changes were present in the majority of eyes that developed ROP and probably always precede the onset of stage I as defined. These changes may regress and do not necessarily indicate the onset of ROP. The low incidence reported in this study does not represent the true incidence, as it did not form part of the data collection sheet and was thus not specifically documented. It was added late in the study and referred to as 'pre-ROP' changes. In eight eyes of four infants, including one who finally progressed to end stage ROP in both eyes, fine capillaries were identified on the retinal surface directly behind the demarcation line one week after diagnosis. These capillaries were fragile and gave rise to small preretinal haemorrhages in three of the eight eyes (Fig. 1). None of the eyes in this study developed a temporary retinal detachment of non-vascularised retina.

Progression to stage II ROP was characterised by the early development of a retinal shunt lesion with an associated progressively increasing congestion and tortuosity of the peripheral retinal vasculature,

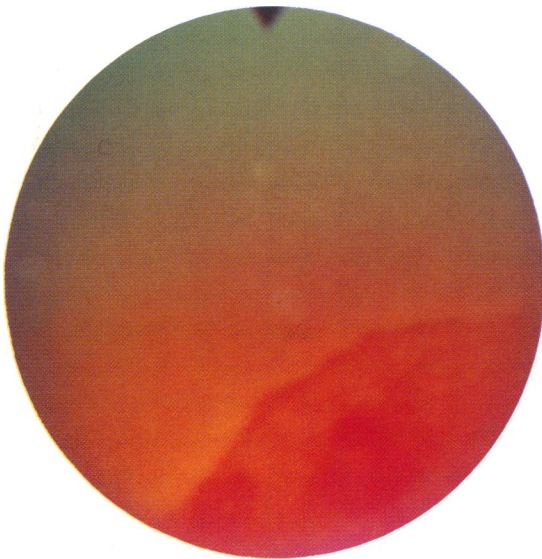

Fig. 1 Stage I ROP with a preretinal haemorrhage from abnormal surface retinal capillaries.

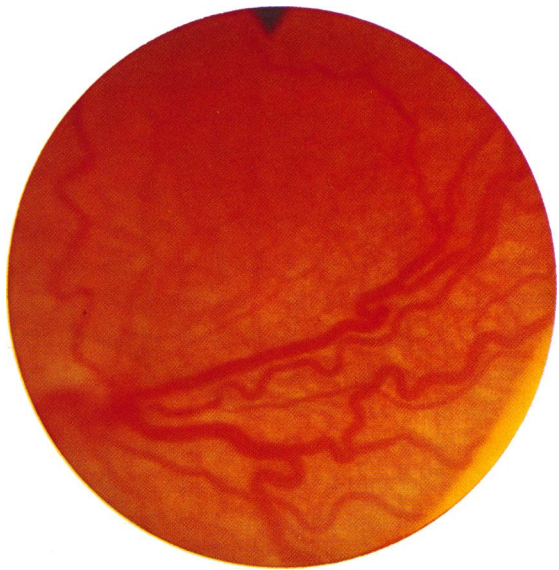

Fig. 2 Zone II stage III ROP with characteristic posterior pole congestion and increased retinal vascular tortuosity.

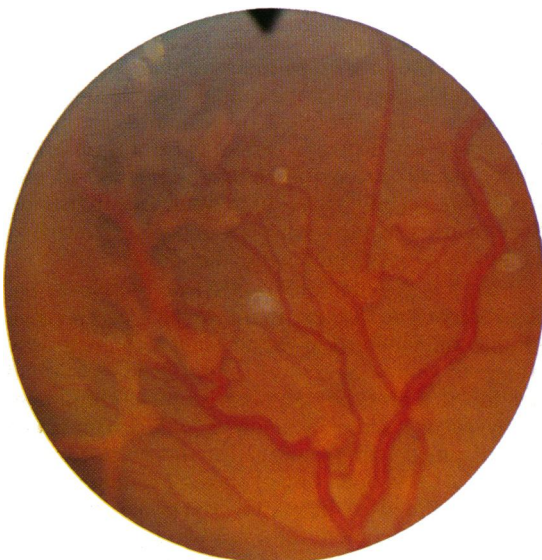

Fig. 3 Globular shunt lesions extending posterior towards the optic disc. Zone II Stage III ROP.




Fig. 4 Vitreous haze preceding retinal detachment and signifying the onset of vitreoretinopathy. Zone II stage III plus ROP.

slowly extending further posteriorly towards the posterior pole.

Congestion and tortuosity of the retinal vasculature increased proportionately to the increasing size of the retinal shunt lesion. Such involvement of the posterior pole and optic disc always indicated stage III ROP (Fig. 2) as previously reported.^{6,7} In progressive stage III ROP the retinal shunt lesion was

seen on serial examination to increase in volume and develop a fibrovascular component at the base of the lesion that projected into the vitreous perpendicular to the retina. One case with zone II stage III ROP also developed multiple globular shunt lesions on the retinal surface posterior to the main circumferential lesion in both eyes (Fig. 3). This clinical appearance has been well documented.¹⁰

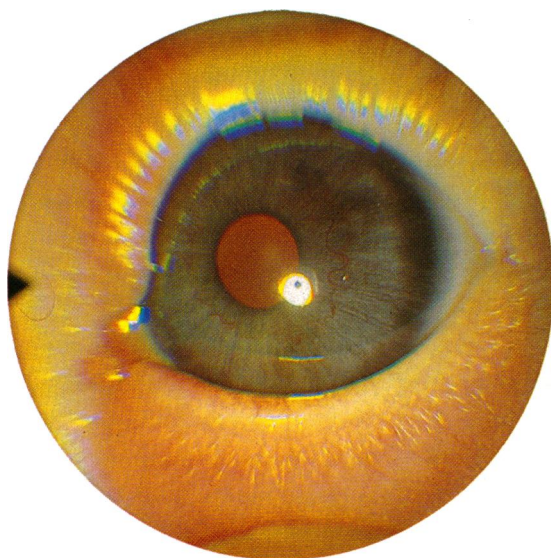


Fig. 5 Iris congestion with poor mydriasis. Zone II stage III plus ROP.

VITREORETINOPATHY

Six eyes progressed to stage IV ROP and included two zone I, one zone III, and three zone II retinopathy eyes. In the three untreated zone II eyes, and both the zone I eyes that progressed to stage IV, retinal detachment was preceded by the sudden onset of a vitreous haze one week before retinal detachment developed (Fig. 4). This characteristic vitreous change was associated with a small intragel haemorrhage from one of the retinal lesions in one eye. Clinical evidence of forward traction on the retinal shunt lesion was clearly defined by the configuration of the blood in the vitreous. This eye finally progressed to a total retinal detachment. This vitreous change was not observed in the zone III eye that progressed to retinal detachment but would have been missed if it was present and localised to the affected temporal retina.

IRIS CHANGES AND PUPIL DYNAMICS

Iris congestion with a poor response to mydriatics developed in five eyes, three zone II and two zone I eyes, with progressive stage III ROP on serial examination (Fig. 5). All five of these eyes progressed to stage IV ROP with extensive retinal detachment.

RETINAL CHANGES IN REGRESSION

Regression was characterised by a decrease in retinal vascular congestion and tortuosity associated with a simultaneous decrease in volume of the retinal shunt lesion. The formation of a 'brushborder', as previously reported by Flynn *et al.*,⁶ often coincided

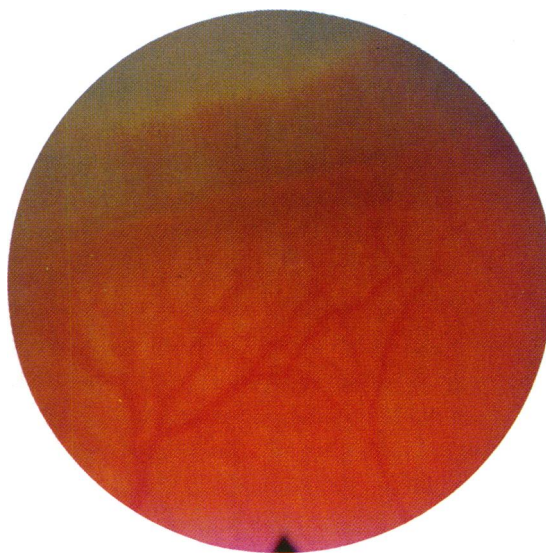

Fig. 6 'Brushborder' characteristic of early regression.

with, or followed shortly after this vascular decongestion, signifying a return to normal retinal vasogenesis (Fig. 6). The newly forming retinal vasculature peripheral to the site of the retinal shunt lesion had a characteristically stretched or wishbone configuration which was distinctly different from the normal retinal vasculature as previously reported.⁶ In one infant this second phase of retinal vascularisation became arrested for two weeks in both eyes when a temporary second demarcation line formed.

In the five eyes that progressed to extensive retinal detachment the retinal shunt tissue decreased in volume and changed in colour from a characteristic orange to yellow soon after retinal detachment had developed. Coinciding with this process a simultaneous transgel traction developed, pulling the retina (rim of purse string) up against the posterior lens surface. At this open funnel stage of retinal detachment it seemed to be purely tractional in origin. Exudative detachment followed two to three weeks later when the retinal detachment changed in character to a bullous closed funnel retinal detachment. No retinal breaks were observed in any of the reported eyes.

STAGE ROP RELATED TO AGE OF INFANT FOR ZONES I, II, AND III

The age at onset of ROP was similar for the three zones, with an average age of 6.5 weeks. Further progression had a striking similarity in all three zones, with a relatively rapid development up to stage III, followed by a relatively long interval between the onset of stage III and progression to

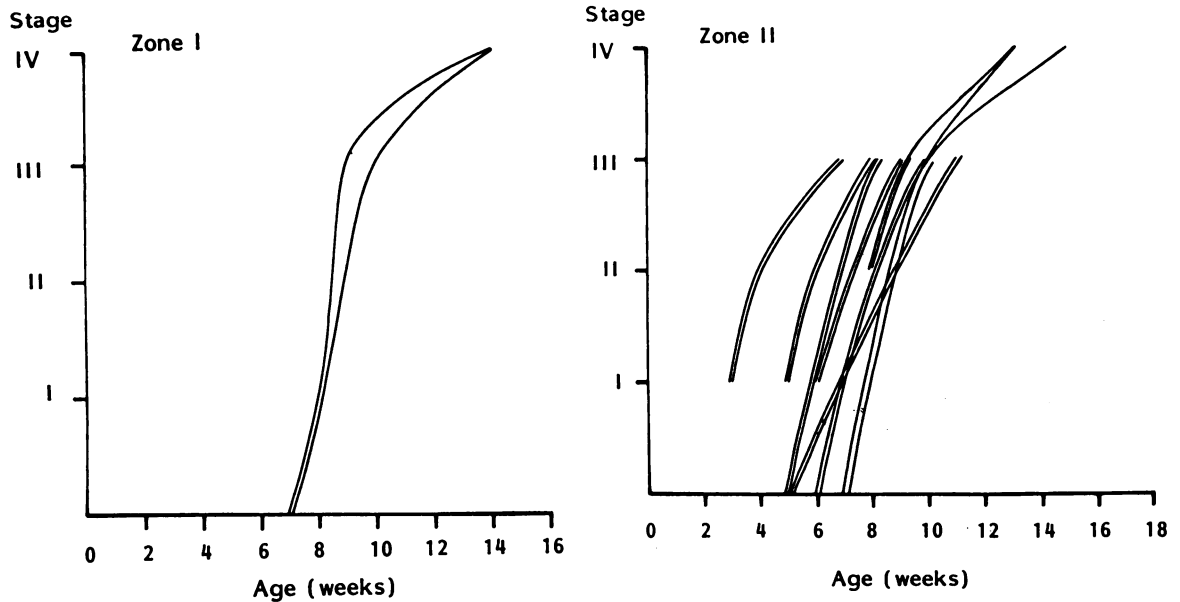


Fig. 7 Age of infant (weeks) related to the stage of ROP for zones I, II, and III.

Table 1 Mean duration of ROP in weeks for zones I, II, and III at the different stages of evolution of the retinal lesion

Zone I			
Age at onset in weeks	Stage I 7.5 (2)*	Stage III 10 (2)	Stage IV 14.5 (2)
Time interval in progression	Stage I to III	Stage III to IV	2.5 weeks
Overall duration active ROP	7 weeks		4.5 weeks
Zone II			
Age at onset in weeks	Stage I 6.6 (16)	Stage III 9.6 (16)	Stage IV 13.6 (3)
Time interval in progression	Stage I to III	Stage III to IV	3 weeks
Overall duration active ROP	7 weeks		4 weeks
Zone III			
Age at onset in weeks	Stage I 7.5 (16)	Stage III 12.9 (5)	Stage IV 20 (1)
Time interval in progression	Stage I to III	Stage III to IV	5.4 weeks
Overall duration active ROP	12.5 weeks		7.1 weeks

stage IV ROP (Fig. 7, Table 1). However, in general, progression to stage III was more rapid in zone I ROP and slowest in zone III ROP, with a duration of 2.5 weeks in zone I, 3.0 weeks in zone II, and 5.4 weeks in zone III before stage III was reached. Progression from stage III to stage IV ROP followed after a duration of 4.5 weeks in zone I, 4.0 weeks in zone II, and 7.1 weeks in zone III ROP. The mean overall duration before the maximum stage was reached was 7.0 weeks for zones I and II and 9.4 weeks for zone III ROP. The number of eyes included in this study was too small to allow statistical analysis, but confirms a trend in the rate of development through the different stages for zones I, II, and III.

*Number of eyes in parentheses.

Table 2 Retinal sequelae in infants in whom the disease process did not progress beyond stage III ROP

Retinal sequelae	Case no.						
	1	2	3	4	5	6	7
Optic disc dragging	+		+	+	+		
Pre-retinal fibrosis		+					+
Wishbone vessels		+			+	+	+
Increased tortuosity		+	+			+	+
Zone	III	II	II	III	III	II	II
Stage (maximum)	III	III	III	III	II	III	III

SEQUELAE

Permanent retinal sequelae were recorded in seven infants who did not progress to stage IV or vitreoretinal ROP (Table 2). These findings were recorded at the age of 6 to 18 months when co-operation was poor and accurate clinical examination of the fundus difficult. The reported results may thus not be an accurate representation of the true incidence of permanent retinal sequelae in this group. Retinal changes were related either to the retinal vasculature or to residual fibrous tissue on the retinal surface at the previous site of a retinal shunt lesion, with or without associated surface traction on the retina. Of the five eyes that progressed to vitreoretinal ROP, and finally developed a total retinal detachment, all developed microphthalmos with anterior displacement of the iris-lens diaphragm and shallowing of the anterior chamber. In one infant with zone II ROP and an obliterated anterior chamber band keratopathy developed in both eyes.

Discussion

No cases of ROP presented outside the defined group of high risk infants, so the adopted criteria were accurate in identifying infants at risk of developing ROP.

Vascular congestion in the posterior pole was confirmed as an important clinical sign which acted as an indicator of the activity of the shunt lesion and indicated whether it was still in an active phase. Similarly, decreased congestion and tortuosity indicated early regression. These characteristic posterior pole changes may thus be a helpful clinical sign to paediatricians screening infants for ROP who may not be familiar with the indirect ophthalmoscope and scleral indentation, necessary for accurate grading. Furthermore, iris congestion associated with a poor mydriatic response should be regarded as a warning sign that the disease process has reached an advanced stage, when further progression to stage IV becomes a real danger.

From the observations made in this study it became evident that the disease process in ROP is self

limiting, with a clinically identifiable time of onset and an end stage when the disease process becomes inactive regardless of the stage of ROP previously reached. Permanent retinal sequelae are directly related to the maximum stage reached. In advanced ROP, stage III and stage III plus, the severity of cicatricial ROP will depend on whether or not vitreoretinopathy had developed. In eyes where the disease remained confined to the retina only, cicatricial ROP will be limited to relatively minor preretinal fibrosis and associated surface tractional retinal changes. Those eyes that continue to progress after stage III had been reached will ultimately develop vitreoretinopathy with severe consequences. Mousel reported a similar vitreous change in one case but referred to it as an 'inflammatory reaction'.¹¹ Cicatricial disease is characterised by extensive tangential and transgel retinal traction and invariably progresses to extensive retinal detachment and blindness in zones I and II ROP. In zone III disease it is confined to the temporal periphery only and will result in varying degrees of temporal retinal drag related to the stage and volume of the retinal lesion at the time of regression. A localised temporal retinal detachment may develop in these eyes. It would thus be practical to classify cicatricial disease in two main categories, retinal and vitreoretinal cicatricial disease (Fig. 8). Infants at risk of developing ROP should be screened at regular intervals after the age of 4 weeks. In cases that had progressed to stage III ROP serial examination by the same clinician is of fundamental importance to identifying early signs of either regression or progression if cryosurgery is planned.

A critical stage is reached at three to four weeks after the onset of stage III ROP, especially in zone I and II ROP, where a higher incidence of a more advanced stage disease can be expected. If no sign of

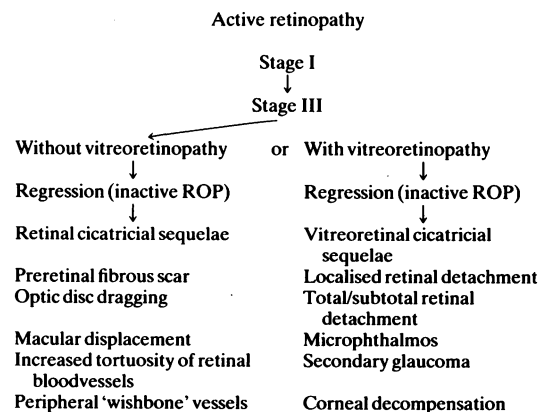


Fig. 8 A schematic representation of the development of cicatricial ROP.

regression can be detected on serial examination at this stage, a real danger of further progression to vitreoretinopathy exists, and cryosurgical intervention should be considered.

A better understanding of the natural history of ROP may enable us to establish more accurate selection criteria in eyes considered for cryosurgical intervention. Not only will this enable us to assess the effectiveness of cryosurgery more accurately, but also prevent unnecessary treatment in future.

The authors thank Mr David McLeod for his advice in preparing this manuscript and Mr John Arnold for his excellent photographic assistance. This work was supported by a locally organised research grant and the colour prints by 3M.

References

- 1 Shohat M, Reisner HS, Krikler R, Nissenkorn I, Yassur J, Ben-Sira I. Retinopathy of prematurity: incidence and risk factors. *Pediatrics* 1983; **72**: 159–63.
- 2 Machemar R. Closed vitrectomy for severe retrolental fibroplasia. *Ophthalmology* 1983; **90**: 436–41.
- 3 Reisner SH, Amir I, Shohat M, Krikler R, Nissenkorn I, Ben-Sira I. Retinopathy of prematurity: incidence and treatment. *Arch Dis Child* 1985; **60**: 698–701.
- 4 Patz A. Current therapy of RLF. *Ophthalmology* 1983; **90**: 425–7.
- 5 Ben-Sira I, Nissenkorn I, Grunwald E, Yassur Y. Treatment of acute retrolental fibroplasia by cryopexy. *Br J Ophthalmol* 1980; **64**: 758–62.
- 6 Flynn JT, O'Grady GE, Kushner BJ, Cantolino S, Milam W. Retrolental fibroplasia: I. Clinical observations. *Arch Ophthalmol* 1977; **95**: 217–23.
- 7 Flynn J. Acute proliferative retrolental-fibroplasia: evolution of the lesion. *Graefes Arch Clin Exp. Ophthalmol* 1975; **195**: 101–11.
- 8 Committee for the Classification of Retinopathy of Prematurity. An international classification of retinopathy of prematurity. *Arch Ophthalmol* 1984; **102**: 1130–4.
- 9 Kingham JD. Acute retrolental fibroplasia. II. Treatment by cryo-surgery. *Arch Ophthalmol* 1978; **96**: 2049–53.
- 10 Garoon I, Epstein G, Segall M, Rabb M, LaFranco F, Quirk T. Vascular tufts in retrolental fibroplasia. *Ophthalmology* 1980; **87**: 1128–32.
- 11 Mousel DK. Cryo-therapy for retinopathy of prematurity. A personal retrospective. *Ophthalmology* 1985; **92**: 375–8.

Accepted for publication 13 August 1986.