

Cryptococcal meningitis presenting as uveitis

S P STONE,¹ J BENDIG,² J HAKIM,³ P E KINNEAR,³ B S AZADIAN,² AND F CLIFFORD-ROSE¹

¹From the Departments of ¹Neurology, ²Microbiology, and ³Ophthalmology, Charing Cross Hospital, London W6

SUMMARY A patient presented with a posterior uveitis. An inferior plaque of retinal exudation was seen. Full investigation failed to establish a cause until six weeks later, when cryptococcal meningitis developed. The patient was immunocompetent. Exudation in relation to retinal vessels is unusual in idiopathic posterior uveitis, and cryptococcosis should be considered in the differential. Diagnosis is by lumbar puncture or vitreous aspiration.

Cryptococcosis is a well recognised infection of immunocompromised patients. It usually presents with meningitis. Uveitis is a secondary complication. We report an immunocompetent patient who presented with posterior uveitis of unknown cause six weeks prior to developing cryptococcal meningitis. A localised exudate in relation to retinal vessels is unusual in idiopathic posterior uveitis and should alert the clinician to the possibility of cryptococcosis.

Case report

A 39-year-old, previously well, Tanzanian Indian, who had not left the UK for 12 years, presented to his local hospital with disturbance of vision in his right eye. Best corrected visual acuities were 6/18 OD, 6/6 OS. Refraction was -0.25 (both eyes). He had a uveitis and chorioretinitis which was treated with topical steroid (dexamethasone) but did not improve. He consulted an ophthalmologist directly, who confirmed posterior uveitis, noted a focal plaque, and investigated fully. After four weeks the patient presented to another hospital with right eye pain and mild biparietal headache. Visual acuities were 6/18 OD, 6/5 OS. Refraction was -0.25 both eyes. Anterior and posterior uveitis was present in the right eye with macular oedema, vitreous cells and retinal exudate (an inferior plaque). The left eye was normal. There was no evidence elsewhere of sarcoidosis, tuberculosis, inflammatory bowel disease, or seronegative arthritis. The erythrocyte sedimenta-

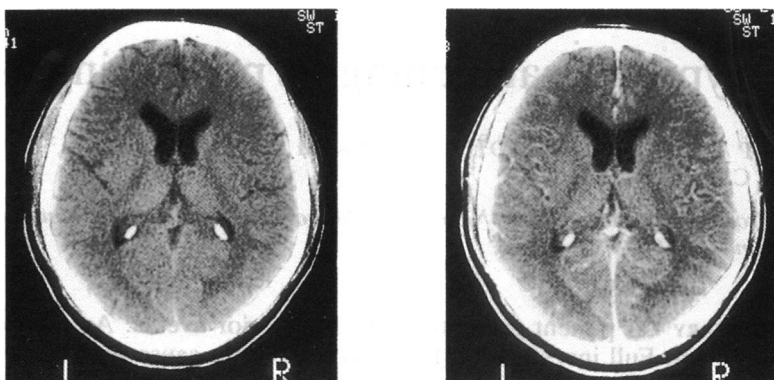
tion rate was 51 mm in the first hour, but chest x-ray and full blood count were normal; syphilis serology, autoantibodies, acute and convalescent serology (toxoplasma, cytomegalovirus, herpes simplex, and Epstein-Barr) were negative. On this basis idiopathic posterior uveitis was diagnosed. Treatment with 60 mg prednisolone daily was begun. Vision improved over five days to 6/9 OD, with resolution of macular oedema.

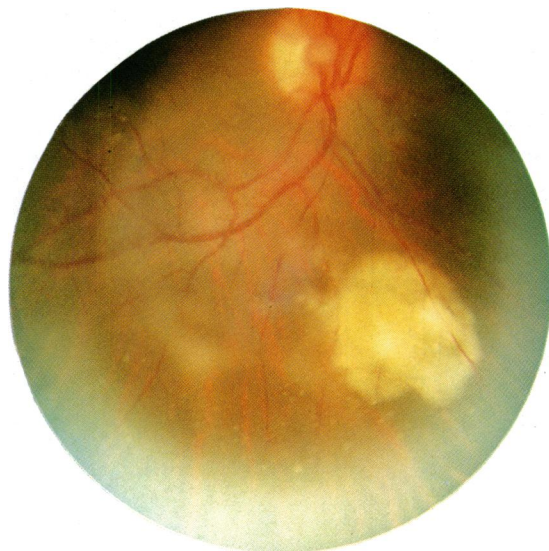

Fig. 1 Right fundus showing an inferior plaque of retinal exudation.

Correspondence to Dr S P Stone, Department of Neurology, St Bartholomew's Hospital, West Smithfield, London EC1A 7BE.

Fig. 2 CT brain scan: both cuts taken at the same level through the thalamus and internal capsule. The patient has been injected with contrast medium before the right hand scan was done, which reveals meningeal enhancement seen as a brighter white outline of the sulci.



Two weeks later he presented to another hospital complaining of three days' violent headache, photophobia, and vomiting. There was a pyrexia of 39.5°C without meningism or focal neurological signs. The right vitreous was cloudy. Retinal exudate was seen (Figure I). Tuberculous meningitis was suspected because he was Indian and on steroids. He was referred to the Regional Neurosciences Centre at Charing Cross Hospital. A CT scan showed meningeal enhancement (Figure II). Examination of the cerebrospinal fluid (CSF) revealed white cells 396/m³ (70% lymphocytes, raised protein (0.72 g/l, normal 0.1–0.5 g/l) and low glucose (1.4 mmol/l, normal 2.8–4.7 mmol/l).

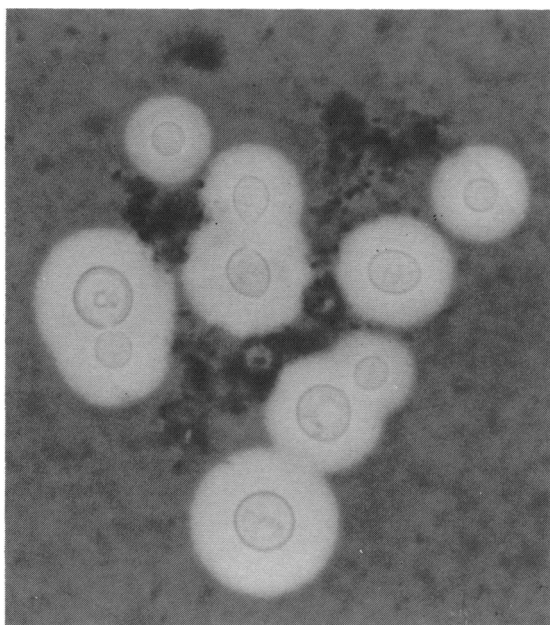


Fig. 3 Indian ink stain of cerebrospinal fluid smear showing *Cryptococcus neoformans* with negative staining capsules.

Gram stain and Indian ink (Figure III) showed moderate numbers of encapsulated yeasts. *Cryptococcus neoformans* was isolated on blood, chocolate, and Sabouraud's agar after 48 hours' incubation at 37°C and subsequently confirmed as serotype A by the Mycological Reference Laboratory. The latex agglutination test for *C. neoformans* capsular antigen was positive with a titre of 200 in the CSF and 64 in the serum.

Chest x-ray, midstream urine, full blood count (lymphocytes $2.1 \times 10^9/l$), glucose, and liver function tests were normal. There was no clinical evidence of malignant disease or reticulosis and he was not at risk of AIDS. HTLV-III antibody and hepatitis B antigen were negative. The Th/Ts ratio was normal. Direct questioning revealed that he was regularly exposed to large amounts of pigeon faeces (the main environmental source of *Cryptococcus neoformans*) when he rearranged the electrical wiring on the roof of his local Hindu temple. Culture of faeces from the roof grew a *Cryptococcus* species, but not *C. neoformans*.

He was treated with intravenous amphotericin 0.5 mg/kg and flucytosine 250 mg four times daily for six weeks. Repeat lumbar puncture at two and five weeks showed a progressive fall in the antigen titre to less than 1:2. His headache resolved, his acuity returned to 6/6, 6/5, but exudates remained when he was discharged. Three months later both CSF and ophthalmological examination were normal. He remained well six months later.

Discussion

Although human beings frequently come into contact with *Cryptococcus neoformans*, clinical disease is rare, but subclinical infection may be common. The main source of the organism is pigeon droppings,¹ which it colonises; 0.1 g of dried pigeon droppings from a sidewalk under a New York City fire escape contained 50 million cryptococci.² The organism is disseminated by wind currents, and in one notable

experiment conducted in the tower of a church belfry contaminated by pigeon manure was recovered from air, being carried in particles small enough to enter an alveolus.³ It thus enters the lung as an infectious inhalant dust and then spreads to meninges, bone, kidney, and other organs. The pulmonary and neurological manifestations are well documented,^{4,7} with infection of the central nervous system most commonly presenting as meningitis, but occasionally as hydrocephalus or an intracranial mass.⁷

A third of over 100 known respiratory cases were asymptomatic,⁵ so that subclinical disease is common. There are 500–15 000 estimated cases of subclinical lung disease per annum in New York City alone,⁸ and there is immunological evidence of subclinical disease in pigeon breeders^{9,10} as well as necropsy evidence of unsuspected cryptococcal lesions in patients dying of unrelated disease.¹¹ Subclinical or chronic meningitis can culminate in hydrocephalus or give rise to transient neurological symptoms.^{12–14}

The AIDS outbreak has focused Western attention on cryptococcosis as a disease of the immunosuppressed.¹⁵ In the UK in 1985 28 out of 31 cases were immunocompromised, nine by AIDS (Mackenzie D, personal communication). In the Orient, however, 86–89% are immunocompetent, as shown by series from Singapore,¹⁶ Malaysia,^{17,18} South Africa (blacks),¹⁹ and Australia (aborigines).²⁰ The most recent of these reports⁷ counsels a high index of suspicion in otherwise healthy orientals. It has been suggested that these apparently immunocompetent individuals may be 'genetic hyporesponders' on the basis of immunological studies showing that surviving cryptococcosis patients have a selective failure of lymphocyte responses to *C. neoformans*^{21,22} and a long-lasting inability to produce antibodies to the organism.²³

Recent exposure to a large amount of pigeon excreta may predispose to infection, and our patient recalls kicking a pile of droppings into the air and noting the offensive odour a few weeks prior to onset of his ocular disease. Despite circumstantial evidence^{24,25} only two cases have been reported of the isolation of the organism from the suspected source.^{26,27} In one of these a doctor who contracted cryptococcal meningitis had spent much time in a hospital library near an air conditioner laden with pigeon droppings, culture of which yielded a heavy growth of *C. neoformans*.²⁶ Recent work suggests that not all cryptococcosis originates from pigeon droppings.²⁸

The combination of chorioretinitis and exudation in relation to retinal vessels is extremely unusual in idiopathic posterior uveitis but has been described in cryptococcal eye disease,^{12,13,29–32} where focal and

miliary lesions may also be seen.^{29,33} Diagnosis is by lumbar puncture^{14,29} or by vitreous aspiration.^{30,34} Ocular disease usually complicates meningitis by direct or haematogenous spread.³⁵ It is rare in the immunocompetent³¹ and rarer still in the absence of other organ disease,³⁶ though it is common in cryptococcosis for the primary site of infection (usually the lung) to be asymptomatic¹¹ or even heal³⁷ while disease in a secondary site (usually the meninges) progresses. Eye infection has been known to regress spontaneously.^{32,33}

Uveitis usually follows neurological disease.^{12,13,32} There is only one previous case report of uveitis preceding cryptococcal meningitis,¹⁴ when anterior uveitis developed into a posterior uveitis which progressed over 12 months while the patient was on steroids. Transient vertigo and ataxia resolved, but CSF taken when the patient was neurologically normal had detectable antigen and eventually grew *C. neoformans*.

The likely sequence of events in our patient was as follows. An oriental, possibly a 'genetic hyporesponder,' was exposed to a large dose of *C. neoformans* which entered the lung, produced subclinical meningitis,^{12–14} and then involved the eye, becoming clinically apparent as a uveitis. At the time steroids were prescribed a mild headache had begun, possibly the first symptom of meningitis, which under the influence of steroids became fulminant.

This case emphasises that cryptococcosis can affect the immunocompetent, especially orientals,¹¹ in whom the major differential diagnosis is often tuberculosis.^{30,38} It may present as a uveitis and should be considered by the clinician whenever the combination of chorioretinitis and exudation in relation to retinal vessels occurs, or when a patient with 'idiopathic' uveitis develops even mild or transient neurological symptoms.

We thank Ms L Churchill for secretarial help.

References

- Emmons CW. Saprophytic sources of *Cryptococcus neoformans* associated with the pigeon (*Columbia livia*). *Am J Hyg* 1955; **62**: 227–32.
- Littman ML, Walker JE. Cryptococcosis: current status. *Am J Med* 1968; **45**: 922–32.
- Powell KE, Dahl BA, Weeks RJ, Tosh FE. Airborne *Cryptococcus neoformans* – particles from pigeon excreta compatible with alveolar deposition. *J Infect Dis* 1972; **125**: 412–5.
- Houk VN, Moser KM. Pulmonary cryptococcosis: must all receive amphotericin B? *Ann Intern Med* 1965; **63**: 583–96.
- Campbell GD. Primary pulmonary cryptococcosis. *Am Rev Respir Dis* 1966; **94**: 236–243.
- Cohen AA, Davis A, Finegold SA. Chronic pulmonary cryptococcosis. *Am Rev Respir Dis* 1965; **91**: 414–23.
- Tjia TL, Yeow YK, Tan CB. Cryptococcal meningitis. *J Neurosurg Psychiatry* 1985; **48**: 853–8.

- 8 Littman ML, Schneirson SS. *Cryptococcus neoformans* in pigeon excreta in New York City. *Am J Hyg* 1959; **69**: 49-59.
- 9 Walter JE, Atchison RW. Epidemiological and immunological studies of *Cryptococcus neoformans*. *J Bacteriol* 1966; **92**: 82-7.
- 10 Newberry W M Jr, Walter JE, Chandler JW, Tosh FE. Epidemiological study of *Cryptococcus neoformans*. *Ann Intern Med* 1967; **67**: 724-32.
- 11 Forbus WD. In discussion of Terplan K. Pathogenesis of cryptococcal meningitis. *Am J Pathol* 1948; **24**: 711-2.
- 12 Chapman-Smith JS, Parr DH, Say PJ. Ocular cryptococcosis in New Zealand. *NZ Med J* 1980; **91**: 291-3.
- 13 Shields JA, Wright DM, Ausburger JJ, Wolkowicz MI. Cryptococcal uveitis chorioretinitis. *Am J Ophthalmol* 1980; **89**: 210-8.
- 14 Grieco MH, Frellich DB, Louria DB. Diagnosis of cryptococcal uveitis with hypertonic media. *Am J Ophthalmol* 1971; **72**: 171-4.
- 15 Kovacs JA, Kovacs AA, Polis M, et al. Cryptococcosis in the acquired immunodeficiency syndrome. *Ann Intern Med* 1985; **103**: 533-8.
- 16 Tay Ch, Chew WLS, Lim LCY. Cryptococcal meningitis: its apparent increased incidence in the Far East. *Brain* 1972; **95**: 825-32.
- 17 Richardson PM, Mohandas A, Arumugasamy N. Cerebral cryptococcosis in Malaysia. *J Neurol Neurosurg Psychiatry* 1976; **39**: 330-7.
- 18 Pathmanathan R, Soo-Hoo Tuck Soon. Cryptococcosis in the University Hospital, Kuala Lumpur and review of published cases. *Trans R Soc Trop Med Hyg* 1982; **76**: 21-4.
- 19 Pillay N, Smijee AE. Cryptococcal meningitis: our experience in 24 black patients. *S Afr Med J* 1976; **50**: 1604-6.
- 20 Lo D. Cryptococcosis in the Northern Territory. *Med J Aust* 1976; **2**: 825-8.
- 21 Schimpff SC, Bennett JE. Abnormalities in cell-mediated immunity in patients with *Cryptococcus neoformans* infection. *J Allergy Clin Immunol* 1975; **55**: 430-41.
- 22 Diamond RD, Bennett JE. Disseminated cryptococcosis in man: decreased lymphocyte transformation in response to *Cryptococcus neoformans*. *J Infect Dis* 1973; **127**: 694-7.
- 23 Henderson DK, Bennett JE, Huber MA. Long lasting specific immunologic unresponsiveness with cryptococcal meningitis. *J Clin Invest* 1982; **69**: 1185-90.
- 24 Nauen R, Kornis RF. Quoted by White FC, Hill HE. Disseminated pulmonary calcification. *Am Rev Respir Dis* 1950; **62**: 7-11.
- 25 Muchmore HG, Rhoades ER, Nix GE, Felton FG, Carpenter RE. Occurrence of *Cryptococcus neoformans* in the environment of three geographically associated cases of cryptococcal meningitis. *N Engl J Med* 1963; **268**: 1112-4.
- 26 Littman ML. Cryptococcosis: current concepts and therapy. *Am J Med* 1959; **27**: 976-98.
- 27 Procknow JJ, Benfield JR, Rippon JW, Diener CF, Archer FL. Cryptococcal hepatitis presenting as a surgical emergency. *JAMA* 1965; **191**: 269-74.
- 28 Diamond RD. *Cryptococcus neoformans*. In: Mandell GL, Douglas RG, Bennett MD, eds. *Principles and practice of infectious diseases*. New York: Wiley. 1985: 1460-8.
- 29 Condon PI, Terry SI, Falconar H. Cryptococcal eye disease. *Doc Ophthalmol* 1977; **44**: 49-56.
- 30 O'Dowd GJ, Frable WJ. Cryptococcal endophthalmitis: diagnostic vitreous aspiration cytology. *Am J Clin Pathol* 1983; **79**: 382-5.
- 31 Doft BH, Curtin VT. Combined ocular infection with cytomegalovirus and cryptococcosis. *Arch Ophthalmol* 1982; **100**: 1800-3.
- 32 Chapman-Smith JS. Cryptococcal chorioretinitis: a case report. *Br J Ophthalmol* 1977; **81**: 411-3.
- 33 Hiles DA, Font RL. Bilateral intra-ocular cryptococcosis with unilateral spontaneous regression. Report of a case and review of the Literature. *Am J Ophthalmol* 1968; **65**: 98-108.
- 34 Beyt BE Jr. Diagnosis of cryptococcal endophthalmitis. *Am J Clin Pathol* 1984; **81**: 272.
- 35 Okun E, Butler WT. Ophthalmologic complications of cryptococcal meningitis. *Arch Ophthalmol* 1964; **71**: 52-7.
- 36 Weiss C, Perry IH, Shevsky MC. Infection of the human eye with *Cryptococcus neoformans* (*Torula histolytica*): clinical and experimental study with new diagnostic method. *Arch Ophthalmol* 1948; **39**: 739-51.
- 37 Haugen RK, Baker RD. The pulmonary lesions in cryptococcosis with special reference to subpleural nodules. *Am J Clin Pathol* 1954; **24**: 1381-90.
- 38 Stockstill MT, Kauffman CA. Comparison of cryptococcal and tuberculous meningitis. *Arch Neurol* 1983; **40**: 81-5.

Accepted for publication 16 October 1986.