

Computerised axial tomography and magnetic resonance scanning in the Tolosa-Hunt syndrome

D J B THOMAS, M C CHARLESWORTH, F AFSHAR, AND D J GALTON

From the Department of Medicine, Radiology, and Neurosurgery, St Bartholomew's Hospital, London EC1

SUMMARY A 50-year-old Asian male presented with a left sixth nerve palsy, left temporal pain, and rapidly deteriorating visual acuity in the left eye. A high resolution CT scan and magnetic resonance scan showed a left retro-orbital enhancing lesion extending from the lateral margin of the cavernous sinus on to the greater wing of the sphenoid and into the left orbit. Arteriography was normal. On high dose steroid therapy there was total resolution of the lesion. The value of imaging techniques in this condition is discussed.

The Tolosa-Hunt syndrome is a rare but well recognised cause of painful ophthalmoplegia¹ characterised by a granulomatous deposit in the region of the anterior cavernous sinus² which is usually steroid responsive. The position of this lesion makes histological confirmation difficult and dangerous, and as the differential diagnosis includes inflammatory vascular and neoplastic lesions³ accurate imaging techniques are invaluable. CT scanning is of value in the diagnosis of this condition, but the appearances are not specific. This paper includes magnetic resonance scans, which have not previously been reported in this condition.

Case report

An Asian male aged 50 presented with a four-month history of diplopia and decreasing visual acuity which was preceded by three years of left-sided headaches. He dated the diplopia from an accident at work when some machine oil was splashed in his eye. The only past history was of a head injury three years prior to presentation. Physical examination revealed a left-sided sixth cranial nerve lesion with some proptosis on that side. Visual acuity was 6/6-9, and Goldmann perimetry was normal. There was reduced sensation to pinprick over the first branch of the trigeminal on the left.

Shortly after admission there was a rapid deterioration in the visual acuity of the left eye (from 6/6-9 to 6/36). He was immediately started on high-

dose steroids (16 mg dexamethasone/day), which produced a dramatic improvement in visual acuity.

An initial high resolution IGE 9800 CT scan showed an enhancing lesion at the lateral margins of the cavernous sinus, the greater wing of the sphenoid, and extended into the orbit (Figs. 1A, 1B). The magnetic resonance (MR) scan showed slight proptosis of the left eye with a pseudotumour in the posterior part of the left orbit (Fig. 1C). Arterio-

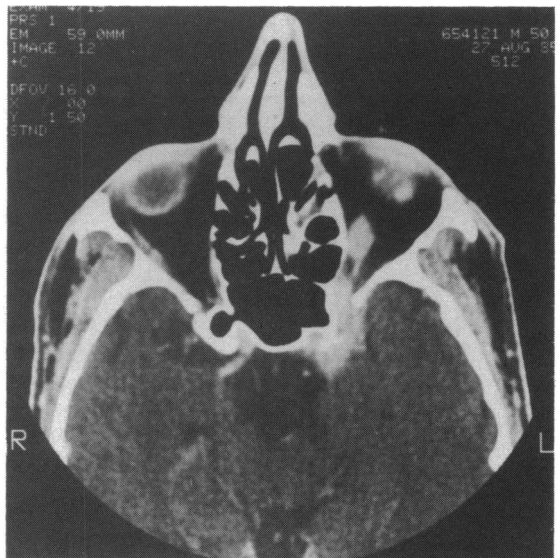

Fig. 1A Axial CT scan showing enhancing lesion extending into the left orbit.

Correspondence to Dr D J B Thomas, Mount Vernon Hospital, Northwood, Middlesex.

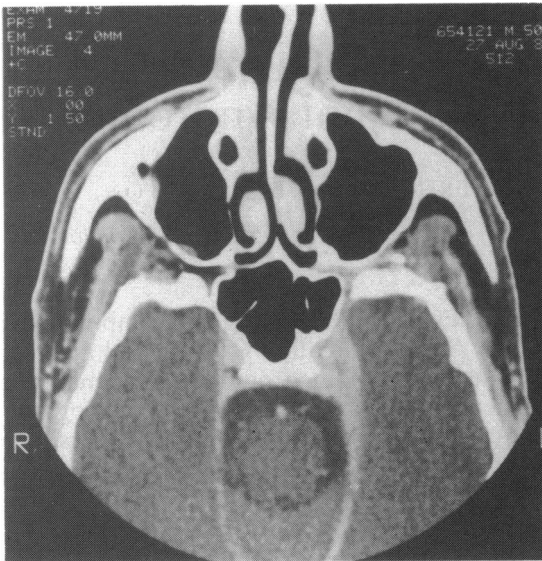


Fig. 1B Axial CT scan showing marked distortion of cavernous sinus.

graphy was normal. High resolution CT and MR scans repeated six months after initiation of steroid treatment were normal (2A, 2B, 2C). Visual evoked responses (VER) from the left eye were compatible with a compressive lesion before steroids were started. There was normal latency, depressed amplitude, and distorted diphasic waveform. After six months on reducing steroid dosage the VER has returned to normal. High-dose steroid therapy was maintained for the whole of the four-month period. An early attempt to reduce steroids precipitated a

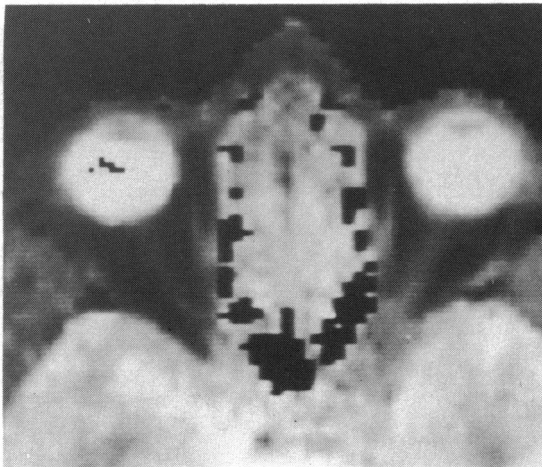


Fig. 1C T1 mode MR scan showing lesion extending into left orbit.

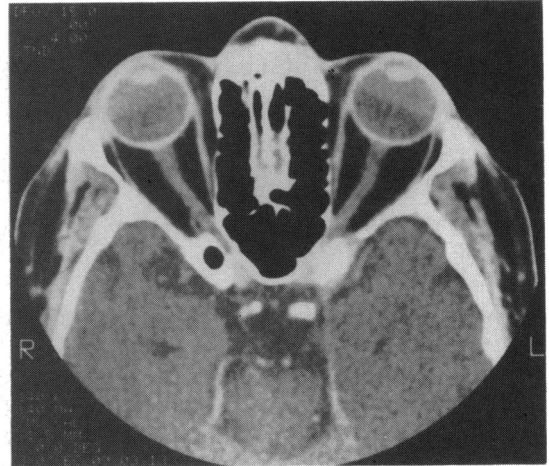


Fig. 2A Repeat CT scan of Fig. 1A cut six months after steroid treatment.

marked deterioration in visual acuity. However, prolonged high-dose steroids resulted in a cushingoid appearance and marked proximal myopathy, and probably contributed to another admission to hospital, when the patient presented with an acute febrile illness, dyspnoea, and radiological evidence of diffuse bilateral pneumonia. The pneumonia responded to intravenous ampicillin and erythromycin, and the radiological appearance returned to normal. The only blood titres to change during this period were cytomegalovirus (from 1/64 to 1/1024). The patient is at present well and on a small dose of steroids.

Other investigations. Erythrocyte sedimentation rate, 10 mm in the first hour. Mantoux test -ve.

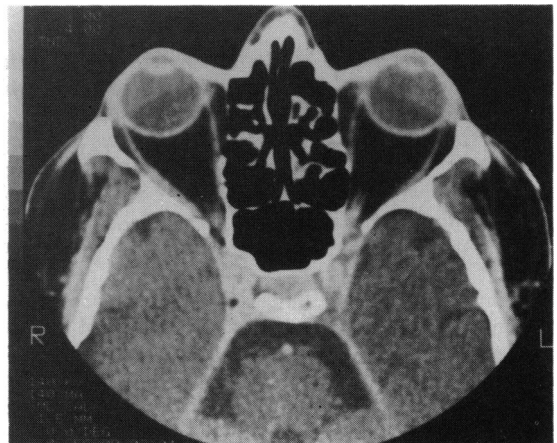


Fig. 2B Repeat CT scan of Fig. 1B cut six months after steroid treatment.

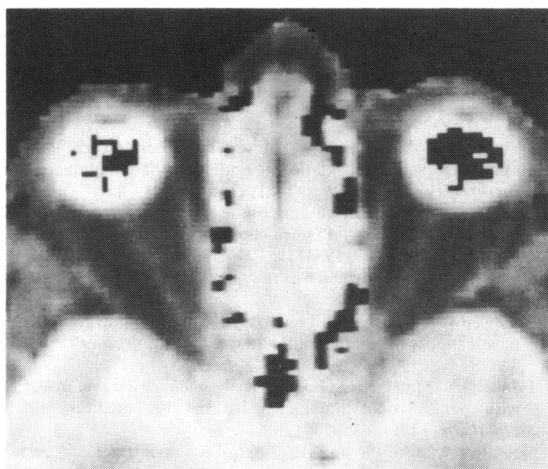


Fig. 2C Repeat MR scan six months after steroid treatment.

Kveim test -ve. Cerebrospinal fluid: protein 0.40 g/l, cells—1 mononuclear cell, cerebrospinal fluid glucose 3.5 mmol/l. VDRL test -ve. Bronchial biopsy normal.

METHODS

High-resolution CT scanning was carried out with the IGE 9800 using 2 mm cuts. Scans were taken in the axial plane and reconstructed in the coronal and sagittal planes. 150 ml of iohexol (Omnipaque) was used for contrast. Magnetic resonance scanning was carried out on the MD800 (0.80 Tesla resistive magnet scanner) in the axial plane on T1 mode (TR 1000 ms, T1+200 ms). The visual evoked response was performed with a standard checkerboard on full fields.

Discussion

In 1961 Hunt *et al.*¹ collected six cases with the following features. Gnawing retro-orbital pain which might precede the ophthalmoplegia and neurological involvement of any combinations of nerves passing through the cavernous sinus. The symptoms might last for days or weeks, and although spontaneous remission did occur there was sometimes residual deficit and attacks might recur subsequently. Earlier Tolosa² had reported on the histology from a patient with similar symptoms who had died. Histology showed a non-specific granulomatous lesion characterised by proliferative fibroblasts and by infiltration of the septa on the walls of the sinus with lymphocytes and plasma cells. Since then there have been sporadic reports of non-specific histology. Although the Tolosa-Hunt syndrome is a well recognised but rare cause of painful ophthalmoplegia, it

remains a diagnosis of exclusion,⁴ with many other lesions such as aneurysms, tumour and even diabetic microangiopathy being reported as mimicking it.⁵

When this syndrome was first recognised it was not possible to obtain direct views of the anterior cavernous sinus, and indirect procedures such as orbital venography and angiography were necessary. CT scanning has now made it possible to visualise this lesion accurately but the appearances are non-specific. However, they are invaluable in monitoring the responses to treatment. Magnetic resonance tomography is a non-invasive method for soft tissue imaging, and, as the images are not degraded by bone, it provides an excellent technique for visualising bony structures such as the orbit. The main factors influencing soft tissue contrast in magnetic resonance are proton density (PD), proton spin lattice relaxation time (T1), and spin-spin relaxation time (T2). The last two constants describe the exponential return to equilibrium of proton magnetisation after excitation. The structures of the normal orbit are easily recognised because of the contrast provided by orbital fat. This has a high proton content and short relaxation time, which makes it appear black on T modes. The lens also appears black, and the coats of the eye are contrasted against the vitreous, which is white because of its slow relaxation time. Orbital bone is not seen on T images. Intraorbital tumours such as metastatic carcinoma or lymphoma appear grey on the T image, and, although the appearance for carcinoma is the same on the PD image, that for lymphoma may appear white. Smith *et al.*⁶ have reported two orbital pseudotumours due to presumed inflammatory change which also appear grey on the T image, and this is similar to the magnetic resonance scan appearance in our patient. Pseudotumours appear less well delineated than real tumours, and there is no bone erosion. The virtual disappearance of the lesion after steroid treatment makes it likely to be a steroid responsive inflammatory disease.

Although histological examination is desirable, the inaccessibility of the lesion makes the procedure difficult and hazardous. In the past attempts at biopsy have been associated with high morbidity and mortality.⁷ Recently a new technique has been described, in which a fine needle is directed under CT guidance.⁴ This appears to have been most successful in the user's hands diagnosing unsuspected aspergillosis, but has not been used widely outside that unit.

There are several interesting points in the patient's response to treatment and the clinical course of the disease. The subject was a middle-aged Asian who presented with a sixth nerve lesion, headache, and rapidly deteriorating visual acuity. It has been sug-

gested that this condition is common in patients of Asian descent, but this is disputed.⁸ There was a dramatic response to high-dose steroid therapy, with rapid clearing of pain and improvement of vision. The diplopia has been slow to improve and still has not entirely disappeared. It is interesting that the patient continually mentions strange colour perception and abnormalities of vision, which have persisted in spite of normal visual evoked responses, visual acuities, and Goldmann perimetry. Some patients with the Tolosa-Hunt syndrome have abnormalities of contrast sensitivity which are not identified by conventional visual function tests. The precise mechanism for this remains obscure, but it has been suggested the lesion is due to damage to large fast-conducting fibres which project from the retinal ganglion to magnocellular layers of the lateral geniculate ganglion.⁹

Although cases of Tolosa-Hunt syndrome may remit spontaneously, in general they require treatment with steroids and are very steroid sensitive. Pain is the most responsive symptom and usually disappears within 48 hours of high-dose steroid treatment. Some authors have suggested this could be used as a therapeutic trial because results are so consistent.¹⁰ In our patient high levels of dexamethasone were required (16 mg per day), and this resulted in profound proximal myopathy with a cushingoid facies. However, there was no worsening of the patient's mild diabetes or hypertension. Finally the

presumed cytomegalovirus pneumonia was probably related to steroid induced immunosuppression, though it has been reported in healthy persons.¹¹

References

- 1 Hunt WE, Meagher JN, Lefever HE, Zerman Z. Painful ophthalmoplegia: its relation to indolent inflammation of the cavernous sinus. *Neurology* 1961; **11**: 56-62.
- 2 Tolosa E. Periarteriotic lesions of the carotid siphon with clinical features of a carotid infra-clinoidal aneurysm. *J Neurol Neurosurg Psychiatry* 1954; **19**: 300-2.
- 3 Lahke J. Superior orbital fissure syndrome. *Arch Neurol* 1962; **7**: 289-300.
- 4 Rowed DW, Kassel EE, Lewis AJ. Transorbital intracavernous needle biopsy in painful ophthalmoplegia. *J Neurosurg* 1985; **62**: 776-80.
- 5 Jabs DA, Miller NR, Green WR. Ischaemic optic neuropathy with painful ophthalmoplegia in diabetes mellitus. *Br J Ophthalmol* 1981; **65**: 673-8.
- 6 Smith FW, Cherryman GR, Singh AK, Forrester JV. Nuclear response tomography of the orbit at 3.4 MHz. *Br J Radiol* 1985; **58**: 947-57.
- 7 Dornan TL, Espir LE, Gale EAM, Tattersall RS. Remittent painful ophthalmoplegia: and Tolosa-Hunt syndrome. *J Neurol Neurosurg Psychiatry* 1979; **42**: 270-5.
- 8 Spillane JD. The geography of neurology. *Br Med J* 1972; **ii**: 506-12.
- 9 Fallowfield LJ, Rees JE. Psychophysical assessment of a patient with Tolosa-Hunt syndrome. *J Neurol Neurosurg Psychiatry* 1983; **46**: 576-8.
- 10 Mathew NT, Chandy J. Painful ophthalmoplegia. *J Neurol Sci* 1970; **11**: 243-56.
- 11 Idell S, Johson M, Beauregard L, Leamur N. Pneumonia associated with rising cytomegalovirus antibody titres. *Thorax* 1983; **38**: 957-8.

Accepted for publication 10 February 1987.