

Idiopathic bilateral lipid keratopathy*

EDUARDO ALFONSO,^{†1-3} LOURDES ARRELLANES,⁵
S ARTHUR BORUCHOFF,^{1,3} L DAVID ORMEROD,^{1,3,4}
AND DANIEL M ALBERT^{2,3}

From the ¹Cornea Service and ²Cogan Eye Pathology Laboratory of the Massachusetts Eye and Ear Infirmary, ³Department of Ophthalmology, Harvard Medical School, ⁴Eye Research Institute, Boston Massachusetts, USA, and ⁵Hospital para la Prevencion de la Ceguera, Mexico City, Mexico

SUMMARY A 52-year-old Mexican man presented with asymptomatic, bilaterally symmetrical lipid infiltrates of the cornea and adjacent limbus. No evidence of previous ocular disease or systemic disorder of lipid metabolism could be detected. Penetrating keratoplasty of the right eye was required. The cornea was rigid and thick, with posterior bulging into the anterior chamber. Light microscopy revealed deep corneal lipid granules, foamy histiocytes, vascularisation, and chronic non-granulomatous inflammation. Transmission electron microscopy showed extracellular lipid spaces and numerous intracytoplasmic lipid vacuoles in histiocytes, keratocytes, conjunctival epithelium, and the endothelium of blood vessels in the corneal stroma and adjacent limbal conjunctiva. Histochemical analysis revealed the presence of neutral fats, free fatty acids, cholesterol, and phospholipids.

Opacification of the cornea due to the deposition of lipids may be primary without evidence of previous corneal vascularisation, or secondary to either pre-existing corneal disease with vascular exudation or systemic disturbances of lipid metabolism.¹⁻³

We report an unusual case of idiopathic, bilaterally symmetrical lipid keratopathy associated with extensive neovascularisation, severe limbal involvement, and stromal lipid deposition.⁴ The patient had no previous ocular disease or lipoprotein disorder; this suggests the primary nature of this condition.⁵

Case report

A 52-year-old Mexican man had a slowly progressive yellow infiltrate in the superior cornea of the right eye over a five-year period and a similar lesion for three

years in the left eye. There were no associated symptoms and no history of ocular disease or trauma. The patient had been treated for hypertension with α -methyl dopa (Aldomet) for two years. Laboratory values for serum cholesterol (3.70 mmol/l) and triglycerides (1.40 mmol/l) were normal. Serum lipid electrophoresis revealed no chylomicrons and normal patterns for β , pre- β , and α lipoproteins. Other laboratory values were normal and included the following: glucose 5.0 mmol/l, alkaline phosphatase 99 U/l, haemoglobin 166 g/l, haematocrit 49.5%, white blood count 9.5×10^9 /l, and a normal leucocyte differential count. The VDRL rest result was non-reactive. A chest x-ray and electrocardiogram were normal.

The best corrected visual acuities were hand motions in the right eye and 6/7.5 in the left eye. Slit-lamp examination of the right cornea revealed a yellowish white mass that occupied almost three-fifths of the superior cornea, including the visual axis (Fig. 1A). The superior limbus between the 10 and 2 o'clock positions was markedly elevated, and numerous, large, superficial, and deep stromal vessels extended into the abnormal corneal mass in this area (Fig. 1B). Clinically the entire thickness of the superior stroma was affected. In the left eye a

*Part of this paper was presented by Dr Boruchoff at the Castroviejo Society Meeting, San Francisco, California, on 29 September 1985, and by Dr Alfonso at the Eastern Ophthalmic Pathology Society, Frenchman's Reef, St Thomas, on 1 November 1985.

†Present address: Bascom Palmer Eye Institute, University of Miami, Miami, Florida 33101, USA.

Correspondence to Daniel M Albert, MD, David G Cogan Eye Pathology Laboratory, 243 Charles Street, Boston, MA 02114, USA.

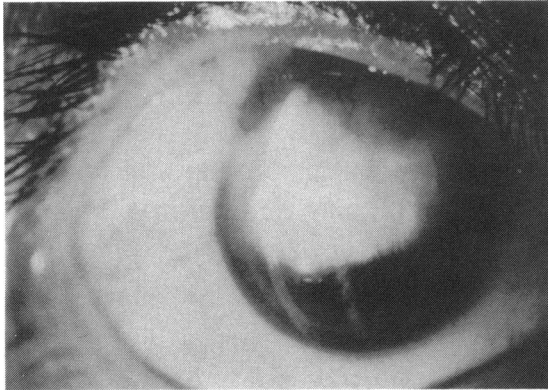


Fig. 1A

Fig. 1 A: Right cornea with superior lipid infiltration extending into the visual axis. B: Thickening and vascularisation of superior limbal area of right eye. C, D: Left eye showing similar findings to right eye but without extension of lipid infiltrate into the visual axis.

smaller lesion with similar characteristics was found (Figs. 1C, D). The other findings of the ocular examination were normal.

A central penetrating keratoplasty of the right eye was performed. At surgery the affected part of the cornea was rigid and bulged posteriorly into the anterior chamber and apposed the superior iris. The postoperative period was unremarkable, and there was no evidence of recurrence of the disorder at the six-month follow-up appointment.

HISTOPATHOLOGY

Specimens of limbal conjunctival biopsies and the 7.5 mm corneal button were obtained and trisected in the operating room. One fragment was placed in 2% glutaraldehyde and embedded in Epon, and thin sections were used for transmission electron micro-

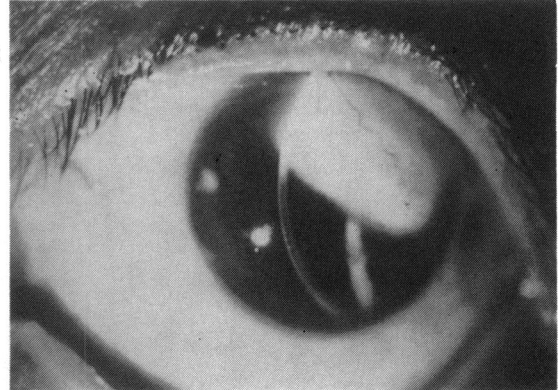


Fig. 1C

scopy. A second fragment was fixed in 10% buffered formaldehyde, embedded in paraffin, sectioned, and stained with haematoxylin and eosin, periodic acid-Schiff, Congo red, and alcian blue. A third fragment was frozen at -70°C , sectioned, postfixed in 37% formaldehyde fumes for 15 minutes, and stained for fats.

LIGHT MICROSCOPY

The conjunctival specimen consisted of a connective tissue fragment lined by non-keratinised squamous epithelium of normal thickness and showed mild to moderate intracellular oedema of the basal cell layer. Moderate numbers of goblet cells were present. The substantia propria contained blood vessels, rare plasma cells, and lymphocytes.

The corneal specimen was thickened posteriorly (Fig. 2A). The corneal epithelium showed moderate oedema of the basal cell layer. At the periphery a fibrocellular pannus was interposed between the epithelium and the intact Bowman's layer. The superficial stroma was normal. The deep stroma was extremely thickened, especially centrally, with

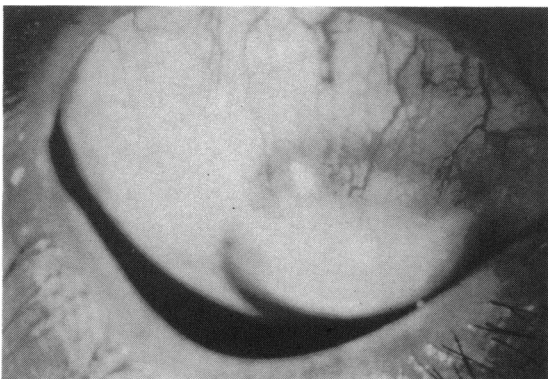


Fig. 1B

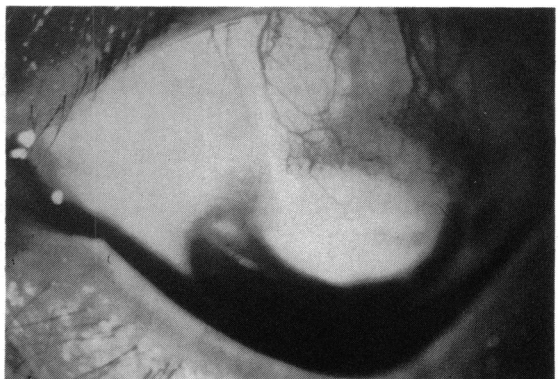

Fig. 1D

Fig. 2A *Right eye. Thickening and posterior bulging of corneal specimen caused by lipid and inflammatory infiltrate (haematoxylin and eosin, $\times 5$).*

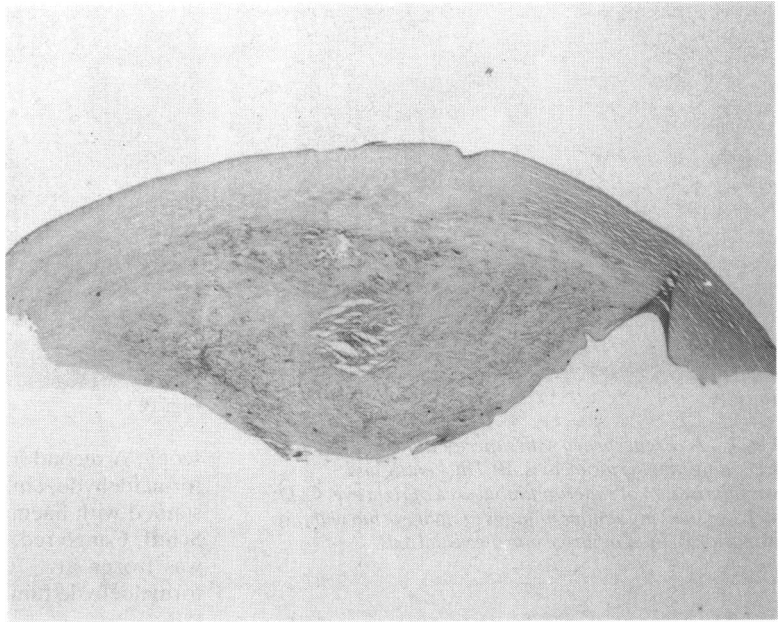


Fig. 2A

moderate vascularisation and disorganisation of the collagen fibrils (Fig. 2B). This area was heavily infiltrated by lipid laden histiocytes, lymphocytes, and plasma cells. Scattered epithelioid cells were also present. Descemet's membrane appeared intact. The

corneal endothelium contained focal areas of pigment deposition.

TRANSMISSION ELECTRON MICROSCOPY

The conjunctival epithelium contained both intra-

Fig. 2B *Posterior cornea showing vascularisation and disorganisation of collagen lamellae. The infiltrate consisted of lipid laden histiocytes, lymphocytes, plasma cells, and epithelioid cells (haematoxylin and eosin, $\times 15$).*

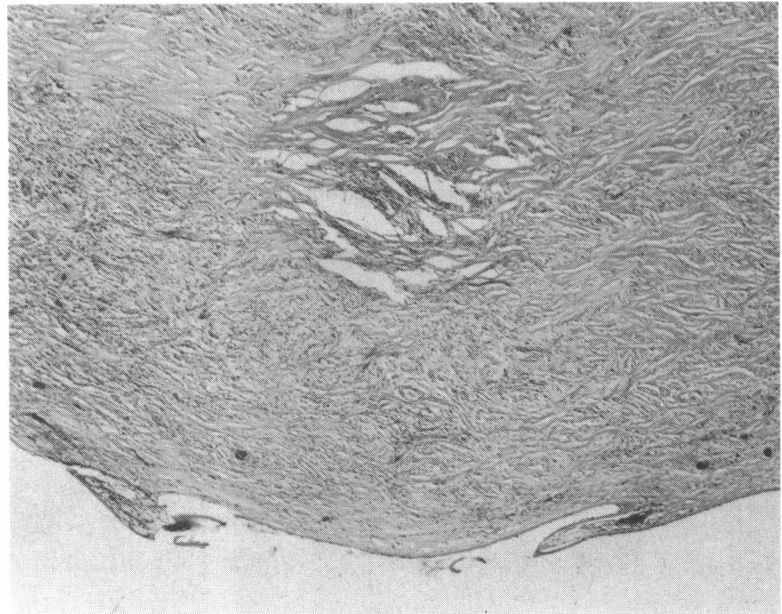


Fig. 2B

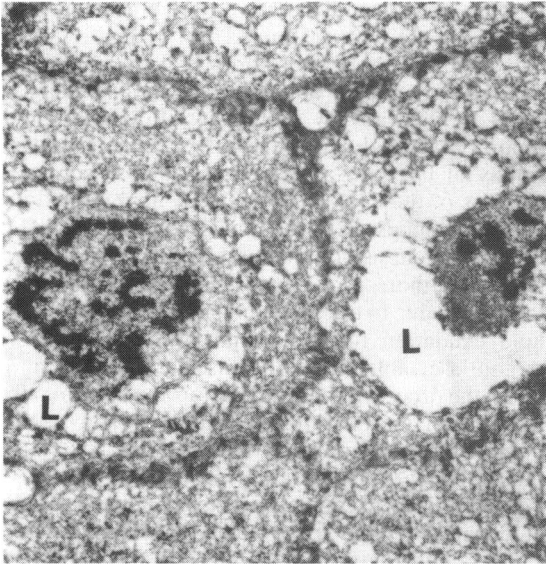


Fig. 3A

Fig. 3 Transmission electron microscopy of the right eye, showing spaces where lipids (L) had dissolved. A: Conjunctival epithelium ($\times 6130$). B: Marked degenerative changes in keratocytes (arrow) and collagen lamellae (C) ($\times 7710$). C: Histiocyte, containing rough endoplasmic reticulum (ER) and red blood cell (RBC) ($\times 9390$). D: Vascular endothelium and intravascular red blood cells (RBC) ($\times 8000$).

cellular vacuoles and extracellular spaces, which probably contained lipids prior to fixation (Fig. 3A).

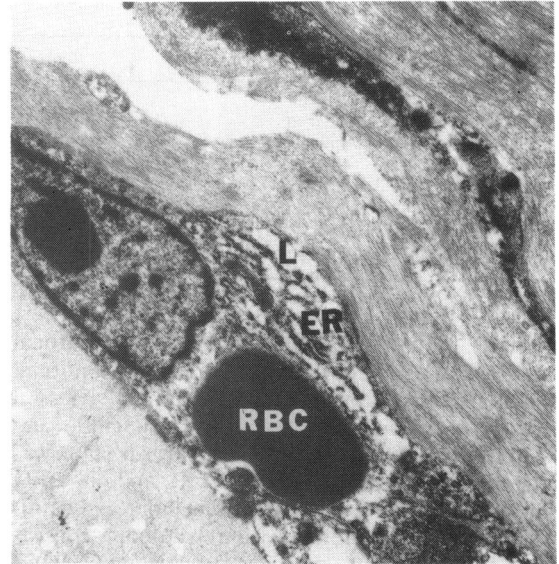


Fig. 3C

The substantia propria and vascular endothelium also contained 'lipid' spaces.

In the cornea there were marked degenerative changes in the keratocytes and disruption of the posterior collagen lamellae (Fig. 3B). Histiocytes and neovascular endothelium were vacuolated extensively (Figs. 3C, D), and adjacent keratocytes (Fig. 3D) were pyknotic.

HISTOCHEMICAL EXAMINATION

After sectioning and postfixing the frozen tissue in

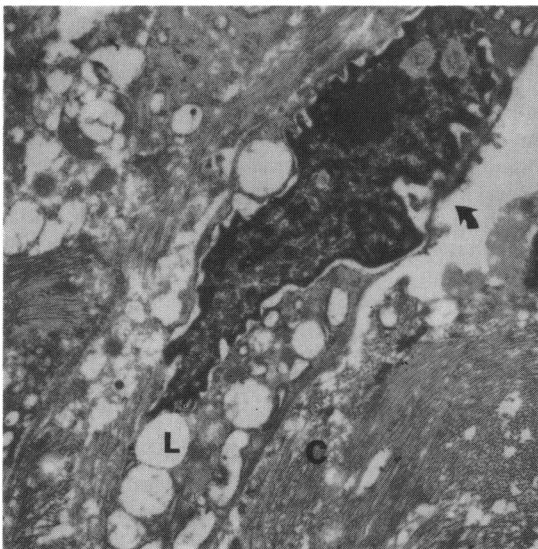


Fig. 3B

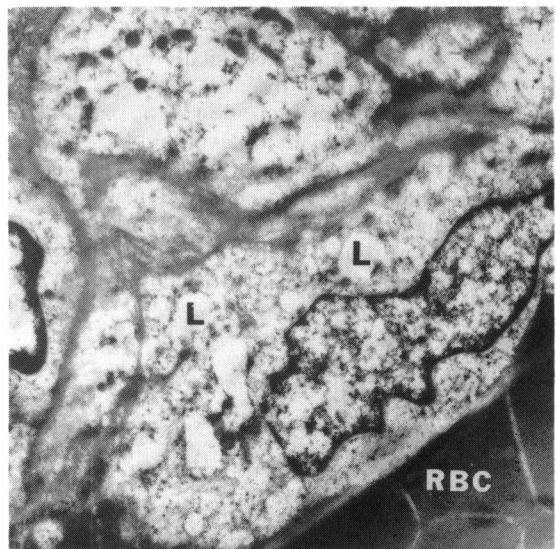


Fig. 3D

Table Histochemical data

Stain	Substance tested for	Result
Congo red	Amyloid	Negative
Masson trichrome	Collagen	Negative
Alcian blue	Acid mucopolysaccharide	Negative
Periodic acid-Schiff	—	Negative
Alizarin red	Calcium	Negative
Oil-red-O	Triglycerides, neutral fats	Positive
Sudan black B	Neutral fats, phospholipids	Positive
Baker	Phospholipids, galactolipids	Positive

formalin fumes we noted that the area of corneal infiltration was somewhat birefringent. No abnormal staining was observed with alcian blue, Masson trichrome, Congo red, periodic acid-Schiff, and bacterial and fungal stains. The alizarin stain was negative. The Baker, Sudan black B, and oil-red-O stains were positive for both intracellular and extracellular fat. The material was interpreted as consisting of neutral fats, free fatty acids, cholesterol crystals, and small amounts of phospholipids (Table).

Discussion

Deposition of lipids in the cornea has been described in several pathological conditions,⁴ including lipid keratopathy, lipoidal degeneration, Schnyder's crystalline dystrophy, corneal xanthoma, corneal arcus, and corneal xanthogranuloma. Occasionally lipids may be deposited in the cornea secondary to systemic lipoprotein disorders (reviewed by Schaefer³), including Tangier disease, lecithin cholesterol acyltransferase deficiency, and familial high-density lipoprotein deficiencies. In lipoprotein disorders the involvement is usually bilateral, but corneal vascularisation is absent.

Corneal arcus, a lipid infiltration of the paralimbal cornea adjacent to Bowman's layer and Descemet's membrane, is thought to be part of the normal aging process in patients over 50 years old. An association with hyperlipoproteinaemia in patients under the age of 40 is controversial. The lipoprotein infiltration of corneal arcus is primarily extracellular, with no associated cellular degeneration or inflammation. Corneal arcus appears clinically as peripheral grey areas separated from the limbus by a lucid interval, but limbal vasculature, corneal temperature, and local blood flow modify the lipid deposition.⁶ Fine and associates have reported a case of primary lipoidal degeneration of the cornea associated with arcus senilis.⁷

Abnormal proliferation of lipocytes can lead to lipid deposition in the cornea in conditions such as juvenile xanthogranuloma. Raised limbal dermoids

should also be included in the differential diagnosis.

Cogan and Kuwabara coined the term lipid keratopathy to describe the deposition of fatty plaques in or adjacent to areas of abnormal corneal vascularisation.⁴ In their review of the literature they cited reports that used various terms, such as fatty dystrophy of the cornea, dystrophia adiposa corneae, adiposis of the eye, xanthomatosis, lipid interstitial keratitis, lipidosis corneae, and secondary steatosis. The pathogenesis of lipid keratopathy, as described by these authors, is related to prior vascularisation of the cornea due to trauma or inflammation, leading to lipid exudation in areas adjacent to the vessels. Argon laser ablation of the vascular channels may arrest the process of lipid deposition and occasionally aid in resolving the lipid infiltrate.⁸ Experimentally induced corneal vascularisation can also lead to fatty infiltration of the cornea.⁹

Several cases of corneal lipid deposition not associated with previous eye trauma, inflammation, or systemic disorders of lipid metabolism have been reported.¹⁰⁻¹² Baum¹⁰ described a 72-year-old woman with unilateral lipid infiltration of the cornea, associated with a slight limbal conjunctival injection. A few deep blood vessels extended into the lesion from the adjacent corneoscleral limbus. Thin-layer and gas-liquid chromatography detected the presence of cholesterol but no other lipids.

A case of an asymptomatic 31-year-old man reported by Barishak and Stein¹¹ had a unilateral corneal lipid infiltration similar in clinical appearance to that of our patient. Vascularisation was present in the lesion as well as in the adjacent corneoscleral limbus. The plaque contained mostly cholesterol and neutral fats, with cholesterol esters and fatty acids present in small quantities.

Our patient shares several clinical features with other cases.¹⁰⁻¹² No systemic or ocular disorder was present to explain the lipid deposition in the cornea in any of the four patients, yet they showed severe vascularisation of the cornea and adjacent corneoscleral limbus. No symptoms of ocular inflammation had been present prior to or at the time of initial examination. Our case is analogous to that of Croxatto *et al.*¹² in its insidious, bilaterally symmetrical presentation and thickened, rigid corneas.

Lipid keratopathy may be associated with concurrent symptoms of ocular inflammation with systemic abnormalities of lipid metabolism. For example, Friedlaender and associates reported a case of a 55-year-old woman with bilateral lipid infiltrates of the cornea,¹³ who differed from our patient in having a mildly raised blood cholesterol level and clinical evidence of ocular inflammation, including pain, photophobia, central corneal epithelial defects, and a diffuse erythematous rash on the face, chest,

and hands. Jack and Luse¹⁴ described a 51-year-old woman with raised blood triglycerides who had an asymptomatic corneal lipid deposition in an area of a previously excised pterygium.

In contrast most other cases of lipid keratopathy directly complicate corneal neovascularisation following trauma or keratitis and are associated commonly with a systemic disorder of lipid metabolism;^{13,14} these conditions are classified as secondary lipid keratopathies. The absence of previous ocular disease and the apparently normal pre-morbid corneas in the present case and in those of Baum,¹⁰ Barishak and Stein,¹¹ and Croxatto *et al.*¹² suggest that these cases should be classified as primary lipid keratopathies (idiopathic). The remarkable symmetry and disease pattern of our case and that of Croxatto *et al.*¹² also provide support for a primary rather than a secondary cause.

The nature of the process in the idiopathic cases is unclear. Low-grade inflammation at the corneal scleral limbus or ocular surface, which was unnoticed by the patient but caused corneal vascularisation and subsequent lipid deposition, is one possible explanation. The finding in our case and others¹¹ of 'lipid' spaces in the vascular endothelium of the lesion and adjacent conjunctiva could represent a primary functional defect of the vascular endothelial cells with leakage of fats into the adjacent corneal tissues. This in turn could induce secondary inflammation followed by corneal vascularisation and further fat exudation.⁴ Cogan and Kuwabara¹⁵ and Jack and Luse¹⁴ proposed that a derangement of corneal cells might lead to necrosis and exposure of intracellular fatty material as the initial event leading to inflammation, vascularisation, and further deposition of fats into the corneal stroma. This derangement might be caused by an intrinsic defect, inflammatory toxins, or trauma.

In animal models experimentally induced corneal vascularisation sometimes progresses to lipid exudation into the adjacent corneal tissue, though hypercholesterolaemia in the early phases of neovascularisation is usually a necessary precondition of experimental lipid keratopathy. The beagle⁵ and Cuban tree frog (Albert DM, personal communication, 1986), however, provide animal models of naturally occurring primary lipid keratopathy. Further laboratory investigations are required to clarify these pathophysiological questions as to the nature of lipid keratopathy in humans.

In our case histochemical analysis of the corneal button revealed the presence of neutral fats, free

fatty acids, cholesterol, and a small amount of phospholipids. Barishak and Stein¹¹ found cholesterol and neutral fats, and Baum¹⁰ only cholesterol, in their cases. Croxatto and colleagues¹² found neutral fats, cholesterol, and phospholipids. In cases of corneal lipid deposition, corneal and plasma lipids should be analysed comparatively to ascertain whether a systemic metabolic fat abnormality is the cause.

David G Cogan, MD, and Lorenz Zimmerman, MD, reviewed the histopathological slides. Robert R McMukin, MD, and Ian W McLean, MD, examined the sections stained for lipids. Diego Cuevas Cancino, MD, provided clinical information. This study was supported in part by the Heed/Knapp Fellowship (1984–6), EY05769 (NIH), and National Society for the Prevention of Blindness (Dr Alfonso).

References

- West C. Corneal disease. In: Peyman GA, Sanders DR, Goldberg MF, eds. *Principles and practice of ophthalmology*. Philadelphia: Saunders, 1980: 410–2.
- Smolin G. Dystrophies and degenerations. In: Smolin G, Thoft RA, eds. *The cornea: scientific foundations and clinical practice*. Boston, Little, Brown, 1983: 333.
- Schaefer EJ. Clinical, biochemical, and genetic features in familial disorders of high density lipoprotein deficiency. *Arteriosclerosis* 1984; **4**: 303–22.
- Cogan DG, Kuwabara T. Lipid keratopathy and atheroma. *Trans Am Ophthalmol Soc* 1958; **56**: 109–22.
- Roth AM, Ekins MB, Waring III GO, Gupta LM, Rosenblatt LS. Oval corneal opacities in beagles. III. Histochemical demonstration of stromal lipids without hyperlipidemia. *Invest Ophthalmol Vis Sci* 1981; **21**: 95–106.
- Fielder AR, Winder AF, Sheraidah GAK, Cooke ED. Problems with corneal arcus. *Trans Ophthalmol Soc UK* 1981; **101**: 22–6.
- Fine BS, Townsend WM, Zimmerman LE, Lashkari MH. Primary lipoidal degeneration of the cornea. *Am J Ophthalmol* 1974; **78**: 12–23.
- Marsh RJ, Marshall J. Treatment of lipid keratopathy with the argon laser. *Br J Ophthalmol* 1982; **66**: 127–35.
- Stock EL, Mendelsohn AD, Lo GG, Ghosh S, O'Grady RB. Lipid keratopathy in rabbits: an animal model system. *Arch Ophthalmol* 1985; **103**: 726–30.
- Baum JL. Cholesterol keratopathy. *Am J Ophthalmol* 1969; **67**: 372–5.
- Barishak YR, Stein R. Lipid keratopathy. *Ann Ophthalmol* 1974; **6**: 377–80.
- Croxatto JO, Dodds CM, Dodds R. Bilateral and massive lipoidal infiltration of the cornea (secondary lipoidal degeneration). *Ophthalmology* 1985; **92**: 1686–90.
- Friedlaender MH, Cavanagh HD, Sullivan WR, Gallagher MJ, Dickersin GR. Bilateral central lipid infiltrates of the cornea. *Am J Ophthalmol* 1977; **84**: 781–7.
- Jack RL, Luse SA. Lipid keratopathy: an electron microscopic study. *Arch Ophthalmol* 1970; **83**: 678–91.
- Cogan DG, Kuwabara T. Lipogenesis by cells of cornea. *Arch Pathol* 1955; **59**: 453–6.

Accepted for publication 5 March 1987.