

A fatal case of necrotising fasciitis of the eyelid

R WALTERS

From Southampton Eye Hospital, Wilton Avenue, Southampton SO9 4XW

SUMMARY A fatal case of necrotising fasciitis in a 35-year-old man is described and the differential diagnosis and management discussed.

Necrotising fasciitis is a potentially fatal skin infection which is being increasingly recognised as an underdiagnosed condition. It requires prompt diagnosis, investigation, and treatment. Early surgical debridement is, in combination with suitable intravenous antibiotics, the mainstay of treatment.

Case report

In December 1985 a previously fit 35-year-old factory manager was referred by his general practitioner to the Casualty Department of the Southampton Eye Hospital with a 12-hour history of increasing redness and swelling of his right upper lid. He said that two days previously he had been poked in the same eye by his daughter (who had been playing with her guinea-pig) but that he had been symptomless until the day of presentation.

On examination he was febrile (38°C) and clearly unwell. His right eyelid was markedly erythematous, swollen, and tender, and there was a copious purulent discharge from the eye. The oedema and erythema extended to his temple as far as the hairline and down the right side of his face to the mouth. Because of the considerable swelling it was difficult to examine his eyes, but there was no proptosis and the ocular movements were full. The visual acuity of the right eye was reduced (6/24) and that of the left was good (6/4). The conjunctiva was very oedematous but there was no obvious injury, and the anterior segment was otherwise unremarkable. The pupil reactions were normal and fundal examination revealed no abnormality. The left eye was normal. A provisional diagnosis was made of preseptal cellulitis with septicaemia, and he was admitted to hospital. Swabs from the infected eye were sent for urgent microscopy and culture and blood cultures

were taken. The Gram stain revealed Gram-positive cocci. He was then treated with intravenous cefotaxime and gentamicin and topical chloramphenicol and gentamicin drops. Because of the poor visual acuity of the right eye it was thought that an orbital cellulitis could not be excluded despite the normal eye movements and absence of proptosis. He was therefore transferred to the General Hospital under the care of an ear, nose, and throat consultant in order to exclude underlying sinus disease and an associated abscess.

Skull x-rays (including sinus views) revealed no abnormality and he was therefore continued on his medical treatment (with the addition of intravenous metronidazole), the presumed diagnosis being preseptal cellulitis. Over the ensuing 12 hours his general condition improved. His temperature fell and his appetite returned. However, the swelling and erythema of the lid and face remained unchanged.

Twenty-one hours after his admission he suffered a

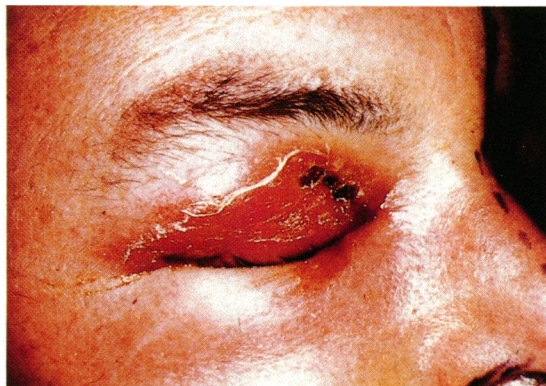

Fig. 1 Close up view of the upper lid, showing its violet hue and black areas of focal necrosis.

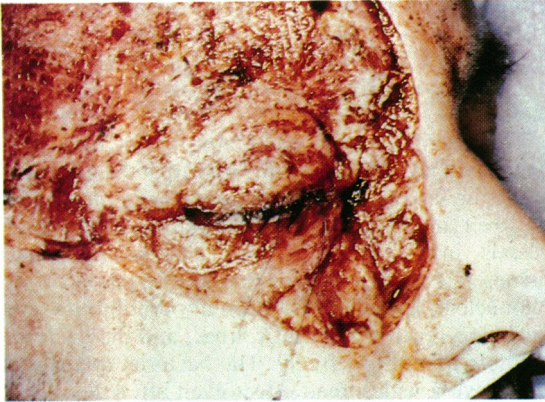


Fig. 2 Close up view of debrided area around the eye. The lid suture through the upper lid margin enabled the lid to be opened for the application of drops.

cardiorespiratory arrest and clearly incurred hypoxic brain damage. He was resuscitated and transferred to the Intensive Care Unit. The cause of his arrest at that time remained a mystery in spite of his being intensively investigated. Chest x-rays, CT brain scan, and lumbar puncture were normal. Specifically, there was no evidence of intracerebral or intraorbital disease. His temperature rose again, and his white cell count was $22 \times 10^9/l$ (with a predominant neutrophilia).

By this stage the lid pathology was beginning to reveal its true nature. The lids took on a violet hue and bullae developed. Later, dark areas of focal necrosis appeared (Fig. 1). These features suggested necrotising fasciitis as the true diagnosis as opposed to the initial diagnosis of cellulitis.

Although the original swab grew *Streptococcus viridans* and *Staphylococcus albus*, the original blood culture and a subsequent lid swab yielded β -haemolytic streptococcus (*Streptococcus pyogenes*). All the organisms were sensitive to cefotaxime (this presumably accounted for the resolution of the initial bacteraemia). Benzylpenicillin was added specifically to counter the streptococci. Anaerobic organisms were not isolated. Serological tests revealed a positive anti-DNAse B titre but a negative anti-streptolysin A titre.

As soon as the diagnosis of necrotising fasciitis was made the patient was taken to theatre and extensive areas of his face, lids, and scalp were surgically debrided (Fig. 2). Thereafter the patient's skin condition improved, but the hypoxic brain damage he had incurred during cardiac arrest was sufficient to prevent a recovery of consciousness, and he died 11 days after admission.

The debrided lid and scalp tissue was sent for

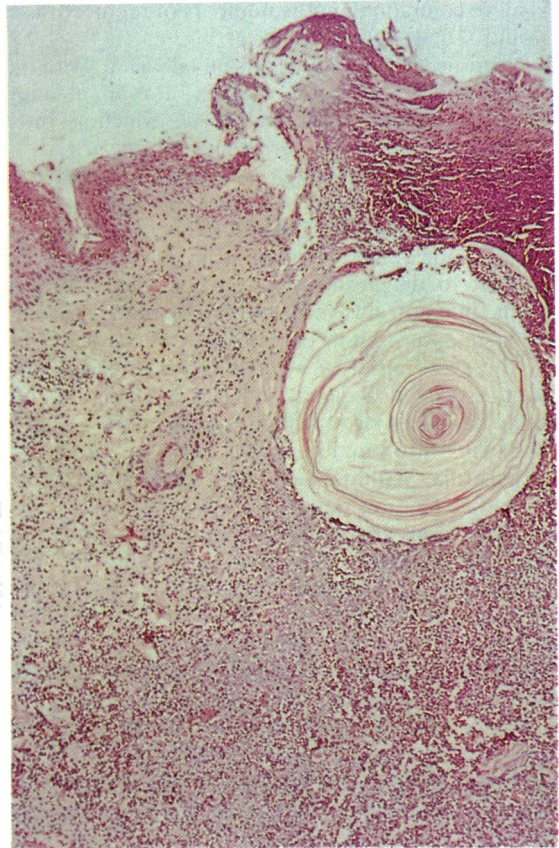

Fig. 3 Histological section through the excised upper lid tissue, showing the ulcerated skin and acute inflammation extending through the dermis. Haematoxylin and eosin.

histological examination and showed extensive acute inflammatory changes. In the upper lid the epidermis was ulcerated and acute inflammatory changes extended throughout the epidermis and dermis, with thrombus formation in some blood vessels. (Fig. 3). Organisms were not demonstrated despite the use of special stains.

Discussion

Necrotising fasciitis has been recognised as a dangerous and often fatal condition since the American Civil War.¹ However, it was first accurately described as a distinct clinical entity by Meleney in 1924.^{2,3} Among its synonyms are streptococcal gangrene, hospital gangrene, gangrenous erysipelas, and necrotising erysipelas. Fournier's gangrene is probably also the same condition.⁴ Although originally reported as a relatively rare condition, it is being increasingly recognised that it has probably been underdiagnosed^{5,6} in the past and

is more common than the numbers of reported cases would at first suggest.

Necrotising fasciitis occurs at all ages, with no statistical difference in race or sex.⁷ It is an infection of the skin and subdermal tissue which is most frequently caused by *Streptococcus pyogenes*^{1,5,8-11} (group A β -haemolytic streptococcus (BHS)), though *Staphylococcus aureus*^{5,7,8,11} and various Gram-negative rods^{7,11-13} have also been isolated.

The appearance of necrotising fasciitis may be difficult to diagnose in the early stages. There is often, but not always, a history of injury, usually trivial in nature. In its early stages it is characterised by the acute onset of a painful erythematous rash with associated oedema, which is indistinguishable from cellulitis or early erysipelas. The patient is usually profoundly unwell, with a fever and tachycardia. Within 24–48 hours the tell-tale pathognomonic features develop.^{2,3,9} There is a deepening red/violaceous discolouration of the skin with blistering (these bullae can again be confused with erysipelas). Subsequently, black patches of necrosis appear. The affected area may be numb or anaesthetic. The legs are the commonest site for the infection,^{5,9} though it can appear anywhere on the body. The area around the eye is not an infrequent site.¹⁴⁻¹⁶ After four to five days frank cutaneous gangrene develops, which if untreated tends to separate by suppuration by the eighth to tenth day. Lymphangitis and lymphadenopathy are unusual.^{9,10,17}

The diagnosis is made principally on the clinical features. However, some investigations are helpful. The white cell count is usually markedly raised (with a neutrophilia). Blood cultures and swabs from the affected site should be taken before antibiotic therapy is instigated. Evidence of streptococcal infection is provided by a raised anti-DNAse B titre

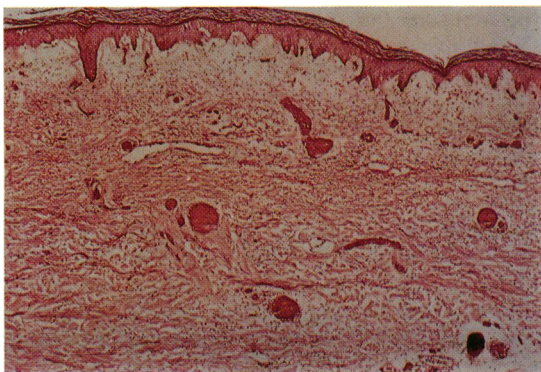


Fig. 4 Histopathology of necrotising fasciitis demonstrating thrombosis in the blood vessels, in the acutely inflamed dermis. H and E.

in most cases and the anti-hyaluronidase titre may also be raised.^{5,18,19} The ASO titre, however, is not usually raised in skin infections¹⁸ and therefore is not helpful in making the diagnosis of necrotising fasciitis.

The essential histological feature of the disease is necrosis of the deep fascia and spread of the infection along the fascial planes, with secondary gangrene of the overlying skin due to thrombosis of the blood vessels in the subepidermal and subcutaneous tissues^{5,10} (Fig. 4). A massive infiltrate of polymorphonuclear leucocytes is present. Antibiotics are unable to reach the necrotic areas, and the bacteria are able to multiply freely. The bacterial toxins can thus have a widespread effect even after the initial septicaemia has been treated. The tissue damage is probably caused by bacterial necrotoxins and thus can also be responsible for some of the pathology remote from the site, which may include glomerulonephritis (resulting in renal failure) and endocarditis.¹⁵

Initial treatment consists of prompt and intensive intravenous antibiotics. Although the most likely causative pathogen is *Str. pyogenes*, it is wise to cover other possible organisms such as *Staph. aureus* and coliforms. A cephalosporin such as cefuroxime or cefotaxime in high doses is suitable. Penicillin G should be added if streptococci are isolated. Despite adequate antibiotic treatment, patients may still die.⁵ Therefore as soon as the diagnosis has been established clinically the affected area should be surgically excised.^{2,3,10,14,20-23} This is necessary in spite of the fact that the patient may symptomatically improve after treatment with antibiotics.

There is a considerable mortality from necrotising fasciitis (8–50%).^{2,8,11,24,25} Although associated illnesses, particularly diabetes mellitus, contribute to this poor prognosis, the principal factors are the time taken to make the diagnosis and delay in surgical intervention.^{5,11,26} The decision to debride the infected area is especially difficult when the face is involved because the cosmetic implications are considerable. However, it must be done, and quickly, if increased morbidity and even death are to be avoided.

In summary, necrotising fasciitis is a potentially lethal condition in which speedy investigation, diagnosis, intensive antibiotic treatment, and early surgical debridement is the correct course of management.

I would like to thank Mr Andrew Elkington for his help and advice and for his kindness in allowing me to present this patient, who was under his care. I am grateful also to Dr Barbara Leppard for her advice, to Professor Weller for his help with the histopathology slides, and to Miss Sara Hipwell for preparing this paper for submission.

References

- 1 Investigations upon the Nature, Causes and Treatment of Hospital Gangrene as it Prevailed in the Confederate Armies 1861–1865. New York, US Sanitary Commission, Surgical Memoirs of the War of Rebellion, 1871. Quoted in Meleney FL. *Treatise on surgical infections*. New York: Oxford University Press, 1948: 15.
- 2 Meleney FL. Hemolytic streptococcus gangrene. *Arch Surg* 1924; **9**: 317–63.
- 3 Meleney FL. Differential diagnosis between certain types of infectious gangrene of skin. *Surg Gynecol Obstet* 1933; **56**: 847–67.
- 4 Cooper DA, Joske RA. Acute streptococcal gangrene of the skin. *Aust NZ J Surg* 1954; **23**: 268–72.
- 5 Leppard BJ, Seal DV. The value of bacteriology and serology in the diagnosis of necrotising fasciitis. *Br J Dermatol* 1983; **109**: 37–44.
- 6 Collins RN, Nadel MS. Gangrene due to the haemolytic streptococcus—a rare but treatable disease. *N Engl J Med* 1965; **272**: 578–80.
- 7 Rea WJ, Wyrich WJ. Necrotising fasciitis. *Ann Surg* 1970; **172**: 957–64.
- 8 Wilson B. Necrotising fasciitis. *Am Surg* 1952; **18**: 416–31.
- 9 White WL. Haemolytic streptococcus gangrene. A report of seven cases. *Plast Reconstr Surg* 1953; **11**: 1–14.
- 10 Strasburg SM, Silver MS. Haemolytic streptococcus gangrene. An uncommon but frequently fatal infection in the antibiotic era. *Am J Surg* 1968; **115**: 763–8.
- 11 Crosthwait RW Jr, Crosthwait RW, Jordan GL. Necrotising fasciitis. *J Trauma* 1964; **4**: 148–57.
- 12 Ledingham IMcA, Tehrani MA. Diagnosis, clinical course and treatment of acute dermal gangrene. *Br J Surg* 1975; **62**: 364–72.
- 13 Fallahzadeh H, Altenbernd E, Mays E. Necrotizing fasciitis. *Am Surg* 1972; **40**: 352–4.
- 14 Buchanan CS, Haserick JR. Necrotising fasciitis due to group A beta-haemolytic streptococci. *Arch Dermatol* 1970; **101**: 664–8.
- 15 Seal D, Leppard B, Widdowson J, McGill J, Tormey P. Necrotising fasciitis due to *Streptococcus pyogenes*. *Br Med J* 1980; **282**: 1419–20.
- 16 Schott EG. Gangrene of the eyelids. *Ind Med Surg* 1966; **29**: 27–9.
- 17 Hammar H, Wang ERL. Erysipelas and necrotising fasciitis. *Br J Dermatol* 1977; **96**: 409–19.
- 18 Wannamaker LW. Differences between streptococcal infections of the throat and skin. *N Engl J Med* 1970; **272**: 78–85.
- 19 Kaplan EL, Wannamaker LW. Suppression of the anti-streptolysin O (ASO) response by lipids extracted from the skin: an explanation or the feeble ASO response following streptococcal pyoderma. *Clin Res* 1973; **21**: 881–6.
- 20 McCafferty EL Jr, Lyons C. Suppurative fasciitis as the essential feature of haemolytic streptococcus gangrene. With notes on fasciotomy and early wound closure as the treatment of choice. *Surgery* 1948; **24**: 438–42.
- 21 Meleney FL. Haemolytic streptococcus gangrene. Importance of early diagnosis and early operation. *JAMA* 1929; **92**: 2009–12.
- 22 Beathard GA, Guckiar JC. Necrotising fasciitis due to group A beta-hemolytic streptococci. *Arch Intern Med* 1967; **120**: 63–7.
- 23 Le Froch JL, Molavi A. Necrotising skin and sub-cutaneous infections. *J Antimicrob Chemother* 1982; **9** (suppl A): 183–92.
- 24 Defore WW Jr, Mattok KL, Dang MH, Crawford R, Jordan GL. Necrotising fasciitis: a persistent surgical problem. *J Am Coll Emergency Physicians* 1977; **6**: 62–5.
- 25 Galosi AF, Herman WP. Fasciitis necroticans. *Dtsch Med Wochenschr* 1979; **104**: 1095–9.
- 26 Rea WJ, Wyrich WJ. Necrotising fasciitis. *Ann Surg* 1970; **172**: 957–64.

Accepted for publication 23 April 1987.