

Acquired Brown's syndrome in a patient with combined lichen sclerosus et atrophicus and morphea

J OLVER¹. AND P LAIDLER²

From the Departments of ¹Ophthalmology, University Hospital of Wales, Heath Park, Cardiff CF4 4CY, and ²Pathology, University of Wales College of Medicine, Heath Park, Cardiff CF4 4XN

SUMMARY A 49-year-old woman with generalised lichen sclerosus et atrophicus and morphea developed bilateral Brown's syndrome. Some of the skin lesions were in the vicinity of the trochlea. A characteristic feature of morphea is subcutaneous fibrosis, so we postulate that the cause of the Brown's syndrome was mechanical tethering of the superior oblique tendon by deep subdermal fibrosis. Histopathological diagnosis was made from biopsies of similar lesions on the patient's face.

In 1950 H W Brown¹ first published his series of seven cases with the following clinical features: slight downdrift of the affected eye on adduction; limitation of elevation on adduction; widening of the palpebral fissure on adduction; no overaction of the ipsilateral superior oblique; V exo pattern; positive traction test.

He suggested that this syndrome was due to congenital paralysis of the inferior oblique muscle resulting in a short anterior superior oblique tendon sheath. In a further publication² he divided his cases of superior oblique tendon sheath syndrome into two types—true and simulated cases. The true cases were those with a congenitally short anterior sheath of the superior oblique tendon. These patients had a positive traction test. The simulated cases were all others, either congenital or acquired. The congenital simulated cases were postulated to have a thick posterior tendon or firm attachment of the posterior sheath to the tendon. The acquired cases were of inflammatory origin.

In 1975 Parks and M Brown³ reviewed the theories of true Brown's syndrome and were unable to demonstrate H W Brown's findings of a short anterior sheath except in two of the 24 patients in whom they had surgically explored the orbit. They suggested that the usual cause of Brown's syndrome was a restrictive connective tissue band situated posteriorly and inferiorly to the globe. In 1977 Parks⁴ suggested that Brown's syndrome was due to a taut

tendon for which tenectomy was effective treatment and remarked that the superior oblique tendon did not have a sheath, but that the anterior half of the tendon actually penetrated Tenon's capsule, to which it was attached by an elastic connective tissue sleeve.

Whereas true Brown's syndrome, which often resolves spontaneously or can be treated surgically, has a limited number of causes, acquired Brown's syndrome is a diverse group that is often difficult to treat, particularly if the syndrome is caused by trauma. Acquired Brown's syndrome occurs rarely and usually in an older age group than true Brown's syndrome of childhood.^{1,2} Non-traumatic inflammatory causes of acquired Brown's syndrome have been reported to include frontal sinusitis,⁵ rheumatoid arthritis,^{6–8} and juvenile chronic arthritis.^{9,10} No obvious cause may be found in some cases.¹¹ Traumatic causes are either surgical (following frontal sinus surgery¹² or a superior oblique tuck¹³) or more commonly non-surgical,¹⁴ when a sharp instrument enters the upper nasal quadrant of the orbit. Occasional cases have been reported as having other more unusual causes such as a secondary deposit in the orbit from a primary carcinoma of the prostate.¹⁵

The present case report describes an additional cause of acquired Brown's syndrome—combined lichen sclerosus et atrophicus and morphea. An understanding of the histological changes in this skin condition indicates one mechanism for the diplopia in some cases of acquired Brown's syndrome and thereby provides a rational basis for the management of the ophthalmic problems in such cases.

Correspondence to Miss J Olver, FRCS, Moorfield's Eye Hospital, City Road, London EC1V 2PD.

Case history

A 49-year-old woman with a clinical and histological diagnosis of lichen sclerosus et atrophicus and morphoea was referred from the dermatology clinic in August 1984 because of increasing diplopia. She had first noticed double vision 12 months previously. This had become increasingly noticeable, particularly on looking up and to the left.

One month after the onset of diplopia the patient developed discrete firm white plaques round the right eye extending on to the forehead. Similar plaques became apparent round the left eye. She noticed a bullous lesion on her hip and a large skin lesion on her neck, for which she sought the advice of a dermatologist. A biopsy was taken from the bullous lesion on her right hip, and histological examination indicated a diagnosis of morphoea.

Within a few months she also developed patches of scaly depigmentation on her right cheek and on the front of her neck, with a larger area affecting her forehead in an 'en coup de sabre' distribution (Figs. 1A, B). This lesion extended to the midline of the forehead, up into the scalp, where there was associ-

ated frontal alopecia, and down over the superonasal quadrant of the orbit to the lid margin nasally with associated loss of cilia and supracilia. There was a thickened area of skin over the region of the right trochlea and the right interpalpebral fissure was narrowed by 1.5 mm in comparison with that on the left. The discrete lesions over the left brow and superonasal orbit became more noticeable with time. Later two further biopsies from her cheek and forehead showed combined lichen sclerosus et atrophicus and morphoea.

She had a corrected visual acuity of 6/4 in each eye and had a compensatory head posture consisting of chin elevation and a small head turn to the left, with which she avoided diplopia in the primary position. She had an exotropia in elevation and an exophoria in the primary position when wearing glasses. There was slight underaction of her right eye on laevo-elevation and minimal underaction of her left eye on dextro-elevation (Fig. 2). Her diplopia was most marked on laevo-elevation. No click was heard or felt over either trochlea. The Hess chart (Fig. 3A) was consistent with a bilateral Brown's syndrome, more marked on the right than the left. In the right eye a

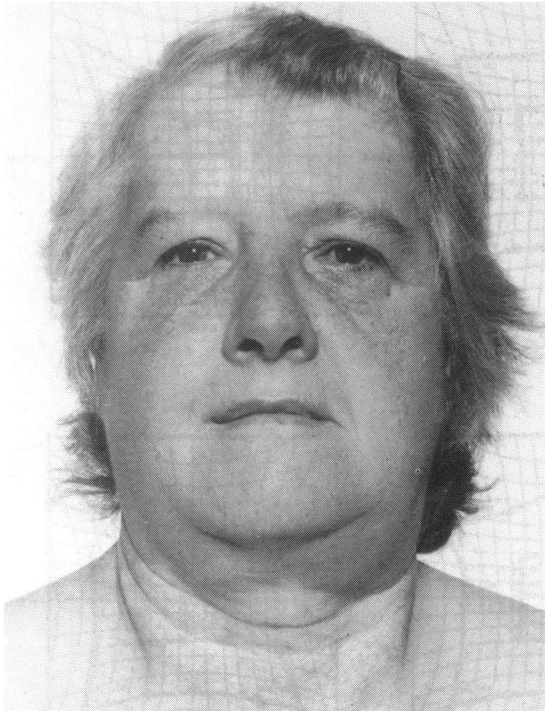

Fig. 1A

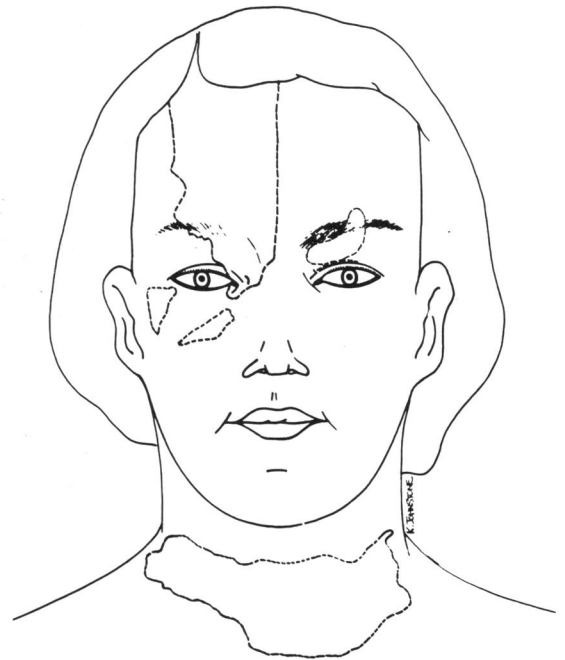


Fig. 1B

Figs. 1A, B Distribution of plaques and en coup de sabre lesion of lichen sclerosus et atrophicus. These lie over the region of the trochleae on both sides.

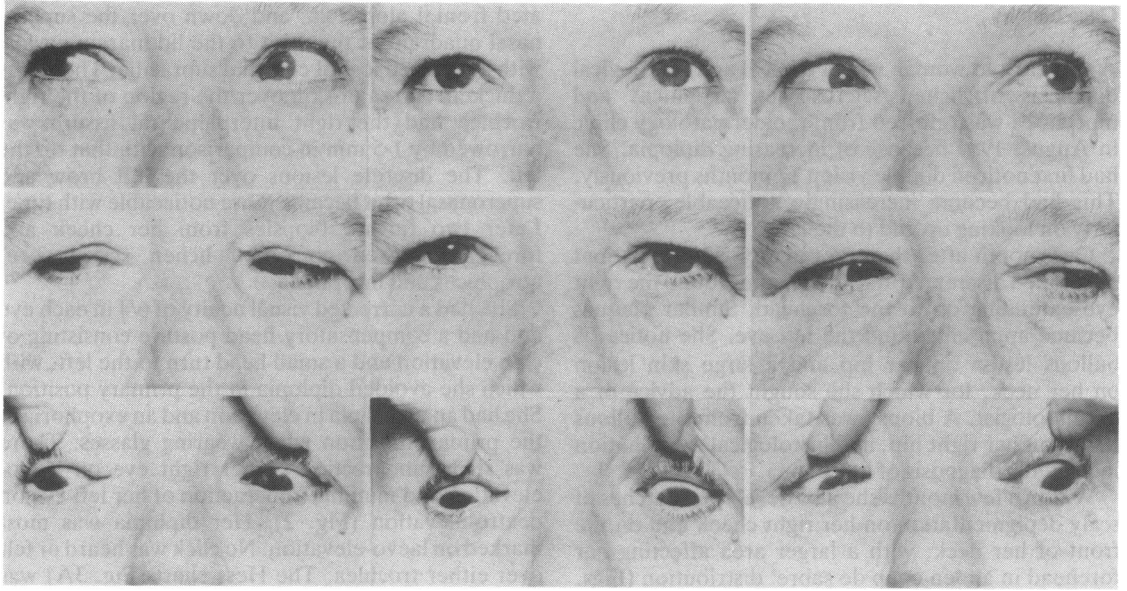


Fig. 2 Nine positions of gaze showing bilateral Brown's syndrome.

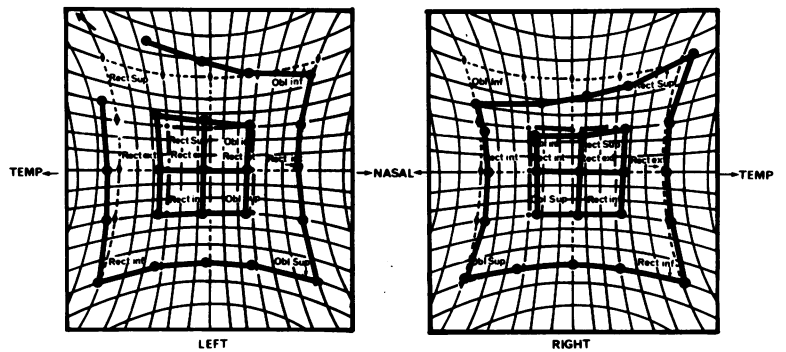


Fig. 3A

Fig. 3 A: Hess chart demonstrates the apparent underaction of the inferior oblique muscles and overaction of the superior oblique muscles of the bilateral Brown's syndrome. August 1984. B: Hess chart shows slight worsening six months later.

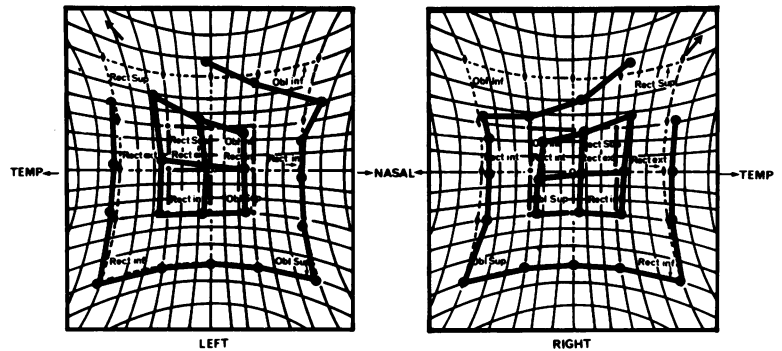


Fig. 3B

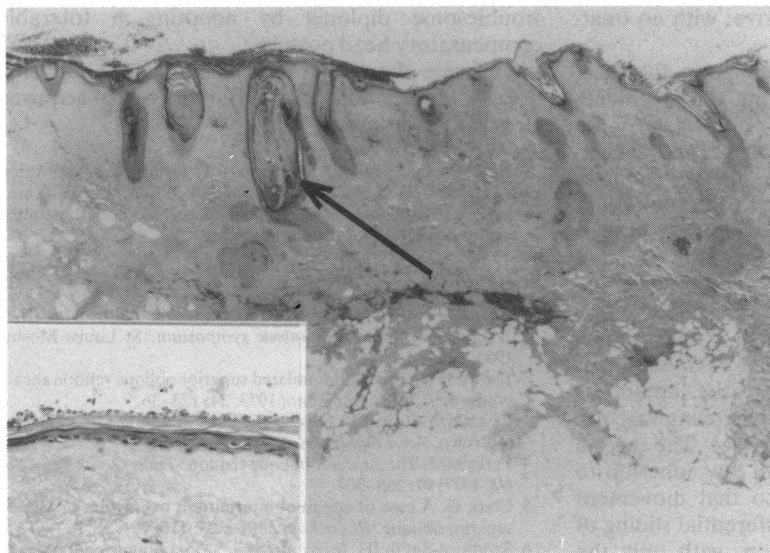


Fig. 4 Skin biopsy from forehead. At low magnification there is apparent distension of hair follicles by plugs of keratin (arrow) and extension of dermal collagen into subcutaneous fat. At higher magnification (inset) the epidermis can be seen to be atrophic without showing degeneration of the basal layers, and there is oedema and flattening of the papillary dermis. The appearances indicate combined morphea and lichen sclerosus et atrophicus. H and E, $\times 17$ (inset, H and E, $\times 67$).

forced duction test confirmed marked limitation of elevation on adduction and slight limitation of elevation in abduction. In the left eye there was slight limitation of elevation in adduction. During the following six months new skin lesions became apparent and existing skin lesions progressed. The diplopia on elevation became more noticeable (Fig. 3B). She continues to be followed up and there have been no further changes of her acquired Brown's syndrome.

HISTOPATHOLOGY

A punch biopsy of the bullous lesion on her right hip had shown haemorrhagic subepidermal bullae, a perivascular chronic inflammatory cell infiltrate, and periadenexal inflammation with thickening of dermal collagen which was of a hyaline appearance. These features indicated a histological diagnosis of morphea.

Two further skin biopsies were examined: one from the forehead at the margin of the largest (en coup de sabre) lesion and one from a small lesion on the right cheek. Both biopsies were similar in appearance in histological sections (Fig. 4). The epidermis was atrophic and separated from the reticular dermis by an area of oedema within the collagen. There was no evidence of liquefaction of the basal layer of the epidermis. Follicular plugging was observed, and there was fibrosis of the dermis extending into the subdermal fat. A perivascular acute and chronic inflammatory cell infiltrate was seen, particularly in the deeper layers of the dermis. Although there was follicular plugging, the distribution of the inflamma-

tory infiltrate was not consistent with discoid lupus erythematosus. The deep extension of fibrosis, combined with epidermal atrophy, follicular plugging, and oedema of the papillary dermis indicates a histological diagnosis of combined lichen sclerosus et atrophicus and morphea.

Discussion

In this case of bilateral acquired Brown's syndrome the diplopia preceded the manifestation of the skin lesions and increased in severity as the skin lesions grew in extent. In morphea the fibrosis is believed to start in the lower dermis,¹⁶ which supports the view that the diplopia was caused by morphea of the overlying skin.

Ophthalmic problems previously reported to be associated with morphea are many and various. They include loss of cilia and supracilia, tarsal atrophy, iritis, iridopalpebral atrophy,¹⁷ unilateral glaucoma,¹⁸ heterochromia,¹⁹ atrophy of skin and muscle including extraocular muscle occurring with en coup de sabre lesion,^{20,21} perilimbal vascular anomaly,²² corneal opacity and fundal changes.²³ This patient had loss of cilia and supracilia, raised intraocular pressures, and episcleritis as complications of her morphea in addition to Brown's syndrome.

Lichen sclerosus et atrophicus has been described as occurring on the eyelid,²⁴ producing lid notching and ectropion.²⁵ Combined lichen sclerosus et atrophicus and morphea is rare^{26,27} and is thought to be a manifestation of the same disease process; it tends to behave as morphea alone and is usually

self-limiting or gradually progressive; with no treatment is effective.

The histopathology of skin lesions on the face, clinically similar to those overlying the trochlea, showed the infiltration of deep fibrosis into the subdermal fat which is part of the morphoea component of the combined skin disease. We postulate that bands of fibrosis extended into the perisheath region round the trochlea and mechanically limited the passive movement of the superior oblique tendon in elevation in adduction.

The function of the trochlea has been studied by various authors.²⁸⁻³⁰ Helveston *et al.*²⁸ have shown from light and electron microscopical examination of eight specimens of trochlea that the tendon is separated from the trochlea by an encircling vascular layer and an outer thin bursa-like space. The tendon is composed of parallel fibres with low adhesion to each other along their length, so that movement through the trochlea occurs by differential sliding of the fibres in a telescoping fashion, with only the central fibres completing the whole excursion. Excess fluid in this bursa or distension of the vascular sheath is postulated to restrict movement through the trochlea, causing an acquired Brown's syndrome which may be associated with a click.

Sevel²⁹ demonstrated from 54 embryological and fetal specimens the existence of fine trabeculae between the tendon and the trochlea, the persistence of which into adulthood may prevent this sliding movement and limit the excursions of the tendon in the congenital form of Brown's syndrome.

Koorneef³⁰ considered that the orbital connective tissue and the extraocular muscles functioned as a single anatomical entity. He has demonstrated from histological thick sections of the orbit that the superior oblique tendon has many connective tissue bands with the medial aponeurosis of the levator muscle and also large numbers of septa passing to the globe along the course of the tendon from the trochlea to the posterior surface of the eye. Accordingly, it is not surprising that perisheath scarring in the medial upper quadrant should mechanically limit passive movement of the superior oblique tendon to produce a Brown's syndrome.

Repeated peritrochlear steroid injections have been reported by Beck and Hickling³¹ to be effective in cases of Brown's syndrome occurring with rheumatoid arthritis and in acquired cases presumed to be due to acute stenosing tenosynovitis.³² Peritrochlear injection of steroids was not carried out in this case, as morphoea rarely responds to local infiltration of steroids or systemic treatment. This is probably because there is already established fibrosis in the deep dermis by the time the skin lesions have appeared. In addition this patient was able to avoid

troublesome diplopia by adopting a tolerable compensatory head posture.

This case shows that morphoea of the periorbital skin should be added to the list of causes of acquired Brown's syndrome.

We thank Mr Paul Mills for allowing us to report this case and Alison Firth (Orthoptic clinical teacher UHW) for her help; Karen Johnstone (MEH) for the drawings and the Medical Illustration department at UHW for the photographs.

References

- 1 Brown HW. Congenital structural muscle anomalies. In: Allen JH, ed. *Strabismus ophthalmic symposium*. St Louis: Mosby, 1950: 205-36.
- 2 Brown HW. True and simulated superior oblique tendon sheath syndromes. *Doc Ophthalmol* 1973; **34**: 123-36.
- 3 Parks MM, Brown M. Superior oblique tendon sheath syndrome of Brown. *Am J Ophthalmol* 1975; **78**: 82-6.
- 4 Parks MM. The superior oblique tendon. *Trans Ophthalmol Soc UK* 1977; **97**: 288-304.
- 5 Clark E. A case of apparent intermittent overaction of the left superior oblique. *Br Orthopt J* 1966; **23**: 116-7.
- 6 Sandford-Smith JH. Intermittent superior oblique tendon sheath syndrome: a case report. *Br Orthopt J* 1969; **53**: 412-7.
- 7 Sims J. Acquired apparent superior oblique tendon sheath syndrome. *Br Orthopt J* 1971; **28**: 112.
- 8 Killian PJ, McClain B, Lawless OJ. Brown's syndrome: an unusual manifestation of rheumatoid arthritis. *Arthritis Rheum* 1977; **20**: 1080-3.
- 9 Wang FM, Wertenbaker C, Behrens MM, Jacobs JC. Acquired Brown's syndrome in children with juvenile rheumatoid arthritis. *Ophthalmology* 1984; **91**: 23-6.
- 10 Moore AJ, Morin JD. Bilateral acquired inflammatory Brown's syndrome. *J Paediatr Ophthalmol Strabismus* 1985; **1**: 26-30.
- 11 Goldhammer Y, Smith JL. Acquired intermittent Brown's syndrome. *Neurology* 1974; **24**: 666-8.
- 12 Blanchard CL, Young LA. Acquired superior oblique tendon sheath (Brown's) syndrome. *Arch Otolaryngol* 1984; **110**: 120-2.
- 13 Nolan J. Tucking of the superior oblique. *Br Orthopt J* 1966; **23**: 313-40.
- 14 Jackson OB, Nankin SJ, Scott WE. Traumatic simulated Brown's syndrome: a case report. *J Paediatr Ophthalmol* 1979; **16**: 160-2.
- 15 Booth-Mason S, Kyle GM, Rosser M, Bradbury P. Acquired Brown's syndrome: an unusual cause. *Br J Ophthalmol* 1985; **69**: 791-4.
- 16 Fleischmajer R, Nedwich A. Generalised morphoea. 1. Histology of dermis and subcutaneous tissue. *Arch Dermatol* 1972; **106**: 509-14.
- 17 Serup J, Alsbrink PH. Localised scleroderma 'en coup de sabre' and iridopalpebral atrophy in the same line. *Acta Derm Venereol (Stockh)* 1983; **63**: 75-7.
- 18 Perrot H, Durand L, Thivolet J, Millon M, Ortonne J-P. Sclerodermie en coup de sabre et glaucome chronique homolateral. *Ann Dermatol Venereol* 1977; **104**: 381-6.
- 19 Stone RA, Scheie HG. Periorbital scleroderma associated with heterochromia iridis. *Am J Ophthalmol* 1980; **90**: 858-61.
- 20 Serup J, Serup L, Sjo O. Localised scleroderma 'en coup de sabre' with external eye muscle involvement at the same line. *Clin Exp Dermatol* 1984; **9**: 196-200.
- 21 Cords R. Strichformige Gesichtsatrophie und Auge. *Ber Dtsch Ophthalmol Ges* 1928; **47**: 53-9.
- 22 Taylor P, Talbot EM. Perilimbal vascular anomaly with ipsilateral en coup de sabre morphoea. *Br J Ophthalmol* 1985; **69**: 60-2.
- 23 Segal P, Jablonska S, Mrzyglod S. Ocular changes in linear scleroderma. *Am J Ophthalmol* 1961; **51**: 807-13.

- 24 Laws HW, Kalz F. Lichen sclerosus et atrophicus of the eyelid. *Can J Ophthalmol* 1968; **3**: 39-42.
- 25 Nancarrow JD, Jawad SMA. A rare case of severe bilateral ectropion from scleroderma. *Plast Reconstr Surg* 1981; **67**: 352-4.
- 26 El Baba F, Frangich GT, Jackson Iliff W, Hood A, Green R. Morphoea of the eyelids. *Ophthalmology* 1982; **89**: 1285-8.
- 27 Tafelkruyer J, Claessens FLE. Lichen sclerosus et atrophicus and scleroderma circumscripta. *Dermatologica* 1978; **156**: 313-7.
- 28 Helveston EM, Merriam WW, Ellis DE, Shellhamer RH, Gosling CG. The trochlea: a study of the anatomy and physiology. *Ophthalmology* 1982; **89**: 124-33.
- 29 Sevel D. Brown's syndrome—A possible aetiology explained embryologically. *J Pediatr Ophthalmol Strabismus* 1981; **18**: 26-31.
- 30 Koorneef L. Orbital connective tissue. In: Duane TD, Jaeger AE, eds. *Biomedical foundations of ophthalmology*. Philadelphia: Harper and Row, 1982: ch. 32: 21-2.
- 31 Beck M, Hickling P. Treatment of bilateral superior oblique tendon sheath syndrome complicating rheumatoid arthritis. *Br J Ophthalmol* 1980; **64**: 358-61.
- 32 Hermann JS. Acquired Brown's syndrome of inflammatory origin. Response to locally injected steroids. *Arch Ophthalmol* 1978; **96**: 1228-32.

Accepted for publication 23 April 1987.