

Graves' ophthalmopathy: I. Simple CT estimates of extraocular muscle volume

E SVERKER HALLIN¹ AND STEVEN E FELDON²

From the ¹Department of Ophthalmology, University of Göteborg, Sweden; and the ²Department of Ophthalmology and Neurological Surgery, University of Southern California School of Medicine, Los Angeles, California, USA

SUMMARY Graves' ophthalmopathy is an autoimmune inflammatory process affecting primarily the extraocular muscles. The enlargement of these muscles is responsible for most of the important manifestations of the disease, including proptosis, lid retraction, diplopia, and optic neuropathy. Recently the optic neuropathy has been shown to correlate with extraocular muscle volume as determined by computed tomography (CT). In the present study simplified measures of the extraocular muscles imaged by CT are described, which also correlate highly with the development of optic neuropathy.

Recently Feldon and coworkers¹ described a method for calculating the extraocular muscle volume of patients with Graves' ophthalmopathy, using high resolution computed tomographic sections. They demonstrated that the risk of developing optic nerve compression increased with extraocular muscle size and diminution of function.^{2,3} Unfortunately the time and equipment necessary to calculate extraocular muscle volume limited the general application of this technique. The purpose of this paper is to explore alternative methods of determining extraocular muscle volume that might be more easily accomplished in the clinical setting.

Materials and methods

Computed tomographic scans were obtained from 152 orbits of 76 patients with Graves' ophthalmopathy. Some of these patients were included in prior studies.¹⁻³ Their average age was 50.1 years (range, 12 to 82); there were 14 men and 62 women.

APPARATUS

A GE 9800 or GE 8800 CT scanner was available for performing the orbital scans. In all but nine patients non-overlapping adjacent slices through the entire orbit (including roof and floor) were obtained in the axial plane at 1.5 mm intervals; in the nine patients

slices were obtained at other intervals of 5 mm or less. The CT scans were imaged at window widths of 250 or 500 and at CT numbers of 0 to +20 Hounsfield units. These were quantitatively analysed with an image analyser.¹ An attached pen enabled contours to be traced and digitised for analysis. Packaged software provided with the image analyser was used to determine relative and absolute areas and volumes of structures by evaluating mid-orbital and serial two-dimensional sections.

PROCEDURE

Axial CT scans were obtained at an angle of 0 to -10° relative to the canthal-meatal line. Gentle eye closure was used to limit volume averaging produced by eye movement during the scan and to prevent asymmetric extraocular muscle contraction that might increase apparent muscle thickness. The filmed image of each slice was traced precisely. The bony orbit, extraocular muscle, optic nerve, and globe were outlined. In addition the 'muscle area' and the 'preseptal area' of the mid-orbital axial CT section, defined as that section imaging the crystal-line lens, the optic nerve head, and the optic canal, were calculated separately. The muscle area was defined as the sum of the medial and lateral areas. The preseptal area was defined as all tissue anterior to a line connecting the lateral orbital rims, limited by the soft tissue laterally and the orbital wall medially. A cross-section of this mid-orbital cut was defined as

Correspondence to E Sverker Hallin, MD, Ogonkliniken, Sahlgrenska sjukhuset, S-413 45 Göteborg, Sweden.

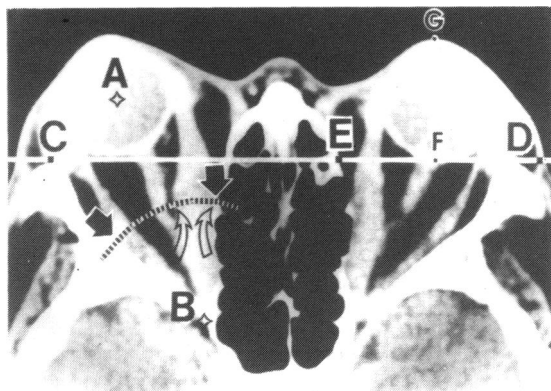


Fig. 1 Mid-orbital section of a CT scan in a patient with Graves' ophthalmopathy. Point A is the centre of the globe. Point B is the orbital apex. The dashed arc is equidistant from point B, including the midpoint of AB. Along the arc, orbital width (black arrows), medial muscle width (open arrows), and intraconal fat width are measured. Line CD is defined by the anterior extent of the lateral bony orbital rim. Preseptal area is calculated to include all tissue anterior to line ED. Proptosis is defined as the distance FG.

an arc including the midpoint between the orbital apex and the geometric centre of the globe (Fig. 1). Along this cross-section, muscle width and the ratio of bony orbital width to intraconal fat width were calculated. Proptosis was defined as the distance between the apex of the cornea and a line connecting the lateral orbital rims as they appear on the mid-orbital axial section of the CT scan.

Orbital volumes were calculated by sequentially evaluating adjacent sections with the computed image analyser. Morphometric techniques were used

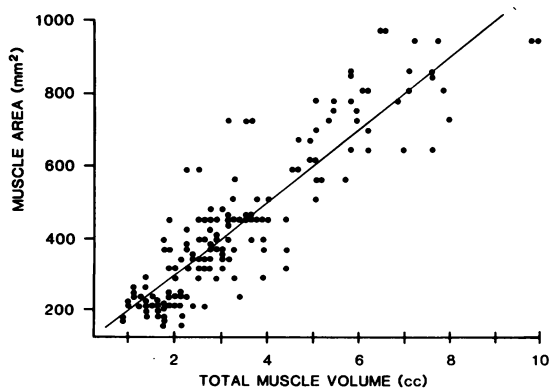


Fig. 2 Scatterplot comparing muscle area with total extraocular muscle volume. For this and all succeeding figures the solid line represents the least squares linear regression and the horizontal axis represents total extraocular muscle volume.

Table 1 Correlation of mid-orbital CT muscle areas with muscle volumes

Muscle area	Total EOM volume	Horizontal EOM volume	Vertical EOM volume
Muscle area	0.89*	0.87	0.84
Medial rectus	0.88	0.87	0.81

* $p < 0.001$ for $r > 0.36$.

EOM = extraocular muscle.

that had previously been found to be accurate to within 7% to 10% for measurement of CT images. Errors due to volume averaging were minimised by using thin slices. In prior studies variation between individuals for single muscles, estimated as the average ratio of single-muscle standard deviation to single-muscle mean volume, was 0.35.¹⁻³

Because rectus muscles could not be reliably distinguished from adjacent extraocular muscles, the following pairs of muscles were analysed together: the levator and superior rectus, the superior oblique and medial rectus, and the inferior oblique and inferior rectus. The lateral rectus was analysed by itself. The volume of each muscle group was computed separately and compared with the overall volume of the orbit, after scaling the CT image so that the cross-sectional diameter of the globe on mid-orbital CT slice was made equal to 24 mm. In this study each muscle is referred to by the included rectus muscle.

Results

COMPARISON OF MUSCLE AREA OF THE MID-ORBITAL SECTION WITH EXTRAOCULAR MUSCLE VOLUME

A plot of total muscle area of the mid-orbital axial

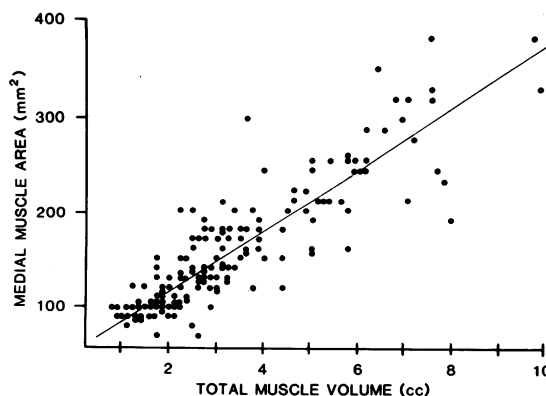


Fig. 3 Scatterplot comparing medial rectus muscle area with total extraocular muscle volume.

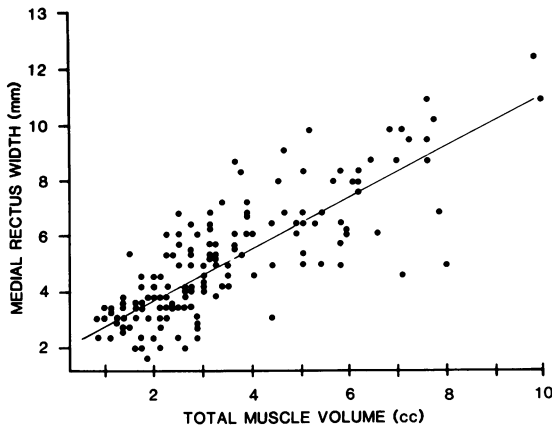


Fig. 4 Scatterplot comparing medial rectus muscle width with total extraocular muscle volume.

section ('muscle area') compared with total extraocular muscle volume is shown in Fig. 2. Least squares linear regression demonstrated a correlation between these two measures of 0.89. Correlations of muscle areas with total, horizontal, and vertical extraocular muscle volumes (all significant at $p < 0.001$) are summarised in Table 1. A comparison of muscle area with horizontal muscle volume had a correlation of 0.87, and that of muscle area with vertical muscle volume had a correlation of 0.84. In comparing the area of just the medial rectus to the total muscle volume, shown in Fig. 3, the correlation was 0.88. Thus the area of the extraocular muscle, singly or together, imaged in the mid-orbital section appeared to reflect fairly accurately the total extraocular muscle volume.

COMPARISON OF MID-ORBITAL MUSCLE AND BONY WIDTH WITH EXTRAOCULAR MUSCLE VOLUME

Muscle width, a measure easier to obtain than orbital volume, was evaluated along an arc drawn through the mid-orbital point (Fig. 1). The plot of medial rectus muscle width compared with total extraocular

Table 2 Correlation of other measures obtained on mid-orbital CT slice to muscle volumes

Other measures	Total EOM volume	Horizontal EOM volume	Vertical EOM volume
Medial rectus width	0.80*	0.79	0.75
Preseptal area	0.79	0.75	0.78
Proptosis	0.65	0.61	0.63
Orbit/fat ratio	0.61	0.65	0.52
Intraconal width	0.16 (NS)	—	—

* $p < 0.001$ for $r > 0.36$.
EOM=extraocular muscle.

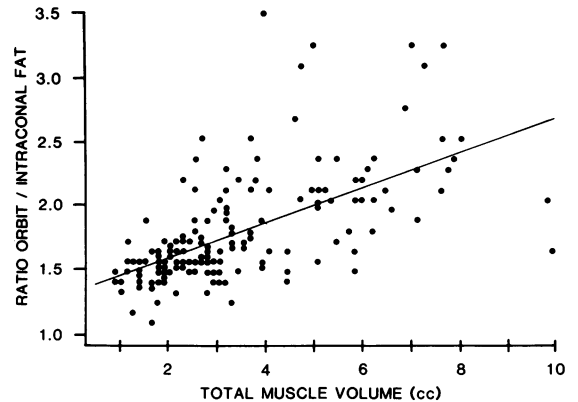


Fig. 5 Scatterplot comparing the orbit/fat ratio with total extraocular muscle volume.

muscle volume, shown in Fig. 4, gave a correlation of 0.80. Intraconal fat width was evaluated as a possible indirect measure of extraocular muscle encroachment on the optic nerve. However, the correlation with extraocular muscle volume was poor ($r = 0.16$). The ratio of bony orbital width to intraconal orbital fat (orbit/fat ratio) along the arc subtended across the mid-orbital position was also calculated (Fig. 5), but had a better correlation (0.61) with total extraocular muscle volume (Table 2).

INDIRECT MEASURES OF EXTRAOCULAR MUSCLE VOLUME

Periorbital swelling, known to correlate with extraocular muscle volume clinically,² was identified on the CT scan by determining the area of the preseptal tissue on the mid-orbital section. Correlation between the preseptal area on a mid-orbital CT slice and total extraocular muscle volume, as plotted in Fig. 6, was 0.79.

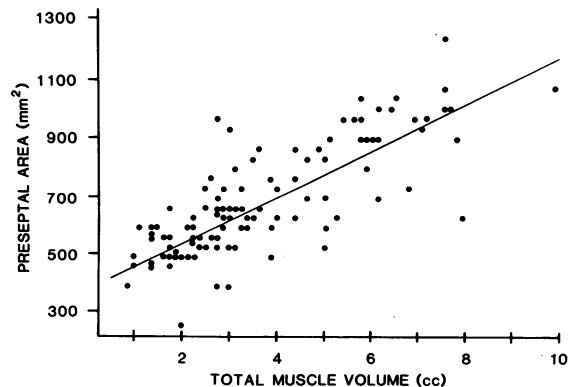


Fig. 6 Scatterplot comparing the preseptal area with total extraocular muscle volume.

Proptosis, measured from the CT scans directly rather than obtained clinically, was evaluated as a possible measure of extraocular muscle volume; correlation was 0.65. Correlations of the indirect measures with horizontal and vertical extraocular muscle volume, as well as with total extraocular muscle volume (significant at $p < 0.001$), are summarised in Table 2.

Discussion

The principal alteration of the orbit in Graves' ophthalmopathy is enlargement of the extraocular muscles. This was first observed by Rundle and Pochin⁴ in cadavers and later confirmed both intraoperatively by Naffziger⁵ and radiologically by CT scan.^{1-3 6-9} The importance of extraocular muscle volume in causing optic neuropathy in Graves' disease has been emphasised⁶⁻⁸ and quantitatively assessed.^{1-3 9}

Owing to the complexity and expense of obtaining and quantitatively analysing multiple thin axial CT sections, the development of alternative quantitative techniques for assessing the risk of optic neuropathy in Graves' ophthalmopathy is of clinical importance.^{2 3} In our radiographic study we looked at several measures of the orbital tissues that might correlate well with total extraocular muscle volume, but which would be easier to obtain either by computing tissue areas from a single axial section or by simply using a curvilinear measure at a fixed anatomical location within the orbit. Our results suggest that high correlations exist between a variety of mid-orbital tissue areas or linear measures and total extraocular muscle volume. Although some of these measures could be determined manually by the ophthalmologist, most CT scanners have software that can be used to map areas and calculate distances on single sections. Ideally radiologists could provide this clinically important, quantitative information to the ophthalmologist. Even proptosis and periorbital

swelling may be more reliably estimated from the CT scan, because CT measures seem to improve the correlation of these measures with extraocular muscle volume substantially ($r = 0.65$ to 0.79) compared with their clinically obtained counterparts ($r = 0.29$ to 0.43).^{2 10}

This study was supported in part by the Carmen and Bertil Regner's Fund, the Crown Princess Margareta's Fund, and by grant No. EY03908 awarded by the National Institutes of Health (USA).

ESH is a research fellow in the Department of Ophthalmology, University of Southern California School of Medicine.

References

- 1 Feldon SE, Weiner JM. Clinical significance of extraocular muscle volumes in Graves' ophthalmopathy: A quantitative computed tomography study. *Arch Ophthalmol* 1982; **100**: 1266-9.
- 2 Feldon SE, Muramatsu S, Weiner JM. Clinical classification of Graves' ophthalmopathy: identification of risk factors for optic neuropathy. *Arch Ophthalmol* 1984; **102**: 1469-72.
- 3 Feldon SE, Lee CP, Muramatsu SK, Weiner JM. Quantitative computed tomography of Graves' ophthalmopathy: extraocular muscle and orbital fat in development of optic neuropathy. *Arch Ophthalmol* 1985; **103**: 213-5.
- 4 Rundle FF, Pochin EE. The orbital tissues in thyrotoxicosis: a quantitative analysis relating to exophthalmos. *Clin Sci* 1944; **5**: 51-74.
- 5 Naffziger HC. Pathologic changes in the orbit in progressive exophthalmos, with special reference to alterations in the extraocular muscles and the optic disks. *Arch Ophthalmol* 1933; **9**: 1-12.
- 6 Trokel SL, Hilal SK. Submillimeter resolution CT scanning of orbital diseases. *Ophthalmology* 1980; **87**: 412-7.
- 7 Kennerdell JS, Rosenbaum AE, El-Hoshy MH. Apical optic nerve compression of dysthyroid optic neuropathy on computed tomography. *Arch Ophthalmol* 1981; **99**: 807-9.
- 8 Trokel SL, Jakobiec FA. Correlation of CT scanning and pathologic features of ophthalmic Graves' disease. *Ophthalmology* 1981; **88**: 553-64.
- 9 Hallin S. Distribution of extraocular muscle swelling in endocrine exophthalmos. *Proc VII Congr Eur Ophthalmol (Helsinki)* 1985: 528-9.
- 10 Hallin ES, Feldon SE. Graves' ophthalmopathy: II. Correlation of clinical signs with measures derived from computed tomography. *Br J Ophthalmol* 1988; **72**: 678-82.

Accepted for publication 2 July 1987.