

Blepharochalasis*

DONALD J BERGIN,¹ CLINTON D McCORD,³ TIMOTHY BERGER,²
HOWARD FRIEDBERG,³, AND WILLIAM WATERHOUSE¹

From the ¹Ophthalmology Service, Department of Surgery, and the ²Dermatology Service Department of Medicine, Letterman Army Medical Center, Presidio of San Francisco, California 94129-6700; and the ³Department of Ophthalmology, Emory University School of Medicine, Atlanta, Georgia 30322, USA

SUMMARY Blepharochalasis is an uncommon disorder distinguished by recurrent episodes of eyelid oedema in young patients. A hypertrophic form, manifested as fat herniation, and an atrophic form, manifested as fat atrophy, have been described. Ptosis with excellent levator function, laxity of the lateral canthal structures with rounding of the lateral canthal angle, nasal fat pad atrophy, and redundant eyelid skin develop after many episodes of eyelid swelling. Fine wrinkling, atrophy, and telangiectasias characterise the excess eyelid skin. We describe four cases of this syndrome in which external levator aponeurosis tuck, blepharoplasty, lateral canthoplasty, and dermis fat grafts were used to correct atrophic blepharochalasis after the syndrome had run its course.

Blepharochalasis is an uncommon disorder characterised by recurrent, non-painful, non-erythematous episodes of eyelid oedema. It must be distinguished from dermatochalasis, which is an involutional change of eyelids and is associated with loose, redundant skin.¹ Beer² was the first to describe this entity in 1807, and Fuchs³ coined the term blepharochalasis in 1896. It has been divided into hypertrophic and atrophic forms.^{4,5} In the hypertrophic form recurrent oedema results in orbital fat herniation through a weakened orbital septum. Most patients who have blepharochalasis present in an atrophic condition with atrophy of redundant eyelid skin and superior nasal fat pads. Most of these atrophic patients do not go through a hypertrophic phase.

Multiple attacks of eyelid oedema result in thinning, stretching, and atrophy of eyelid tissues. The eyelid skin becomes redundant, discoloured, and atrophic, appearing like wrinkled cigarette paper. The upper eyelids are more commonly affected, but the lower eyelids may also be involved. Laxity of the lateral canthal tendon results in rounding of

the lateral canthal angle and blepharophimosis. Dehiscence and thinning of the levator aponeurosis results in blepharoptosis associated with excellent levator palpebrae superioris function.⁶ Pseudo-epicanthal folds are formed by atrophy of the superior nasal fat pads. Numerous cases of blepharochalasis have been reported.⁷⁻²⁴ Our report describes four patients who had atrophic blepharochalasis that was treated surgically.

Case reports

CASE 1

A 27-year-old woman had numerous attacks of upper and lower eyelids oedema in the previous 12 years, each lasting 3 to 5 days. The last attack had been one year earlier. She was in excellent health and had no family history of eyelid oedema. She was allergic to many foods and animal dandruff. The serum Cholinesterase inhibitor level was within normal limits.

4 mm of bilateral upper eyelid ptosis, high supratarsal eyelid creases, and excellent levator function were noted (Fig. 1). There was fine wrinkling and mild hyperpigmentation of redundant eyelid skin, with multiple fine telangiectatic subcutaneous vessels. Mild atrophy of the upper nasal fat pads and dehiscence of lateral canthal tendon was evident (Fig. 2, left). A blepharoplasty and external levator aponeurosis tuck by the anterior approach corrected

*Presented in part at the meeting of the American Society of Oculoplastic and Reconstructive Surgery, New Orleans, Louisiana, 8 November 1986.

Correspondence to Donald J Bergin, MD, Southeastern Eye Center, 3312 Battleground Avenue, Greensboro, NC 27410, USA.

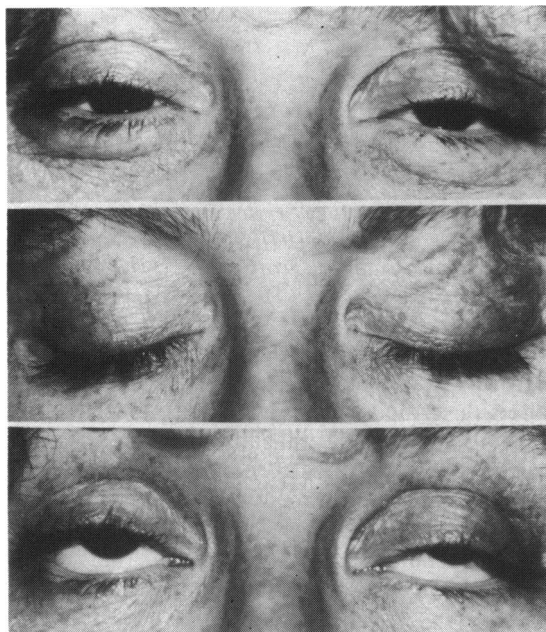


Fig. 1 Case 1: 4 mm of ptosis, high supratarsal eyelid creases, and excellent levator function. 'Cigarette paper' thinning and telangiectasias of excess upper eyelid skin are evident. Note mild atrophy of nasal fat pad and pseudoepicanthal fold.

the high lid crease, redundant skin, and blepharoptosis (Fig. 3). Lower eyelid blepharoplasty was combined with lateral horizontal eyelid shortening to attach the lateral border of the tarsus to the periorbita near Whitnall's tubercle. This procedure resulted in reformation of the lateral canthal angle (Fig. 2, right).

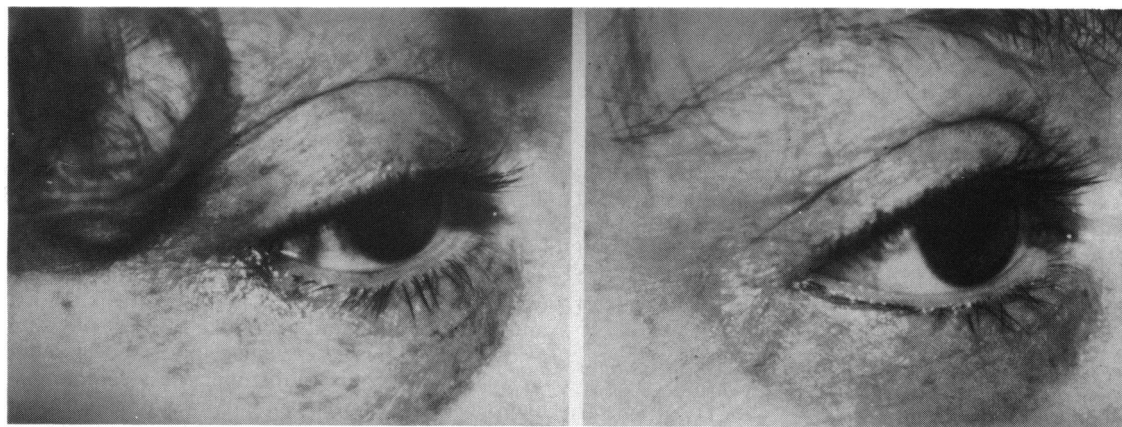


Fig. 2 Case 1: preoperative photograph (left) shows rounding of the lateral canthal angle. Postoperative photograph (right) one year later shows reformation of lateral canthal angle.

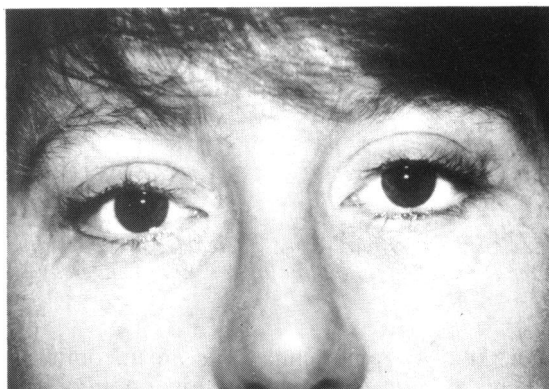

Fig. 3 Case 1: photograph shows corrected features one year after four-lid blepharoplasty, upper eyelid levator aponeurosis tuck, and reformation of lateral canthal angle.

CASE 2

A 28-year-old woman had bilateral acquired blepharoptosis of several years' duration (Fig. 4, left). She had recurrent attacks of upper eyelid oedema from ages 13 to 20, each lasting about three days. She had no allergies and her family history was negative. Test results with edrophonium chloride (Tensilon) and for serum Cl esterase inhibitor level were normal. Examination revealed bilateral ptosis of 3 mm, with excellent levator function and high supratarsal lid creases. The lid skin was atrophic, with prominent subcutaneous blood vessels. The atrophic nasal fat pads resulted in pseudoepicanthal folds (Fig. 4, right). Rounding of the lateral canthal angle was present. Other ocular and physical examinations gave normal results. An external levator aponeurosis tuck was combined with a blepharoplasty. The levator aponeurosis was markedly thin-

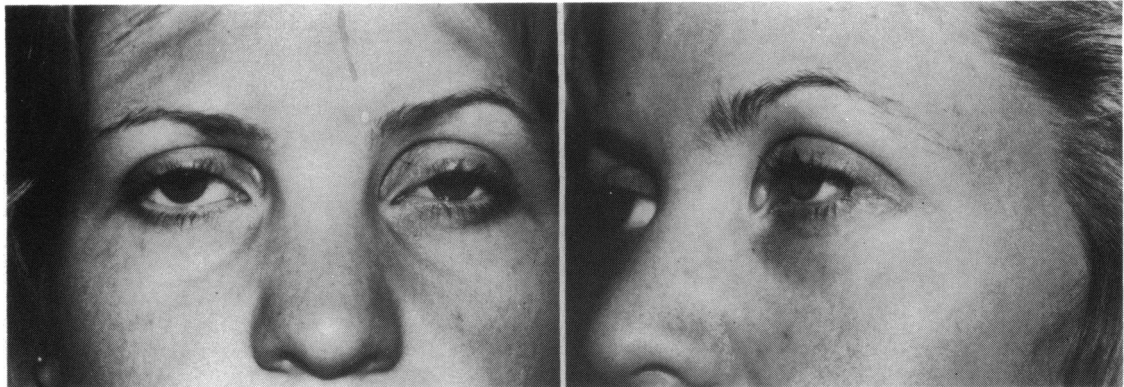

Fig. 4 Case 2: photograph (left) shows ptosis and high supratarsal lid crease. Photograph (right) shows prominent nasal fat pad atrophy, pseudoepicanthal fold, and rounded lateral canthal angle.

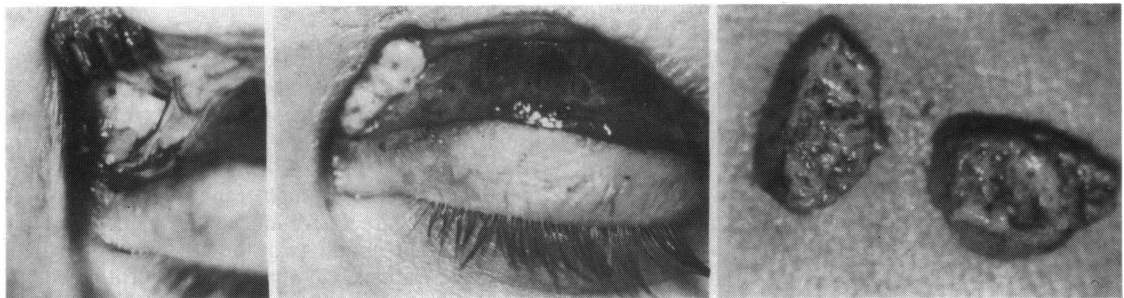


Fig. 5 Case 2: photographs show (left) exposed atrophic superior nasal fat pad (centre), dermis fat graft fixed to periorbital roof with double-armed 5-0 absorbable suture, and (right) dermis fat graft consisting mostly of dermis.

ned (Fig. 5, centre). A dermis fat graft from the abdomen was placed in the superior nasal fat pocket and fixated to the periorbital of the orbital roof with a 5-0 absorbable suture (Fig. 5). A lateral canthoplasty reformed the lateral canthal angle. Four months after operation there was some residual nasal ptosis of the

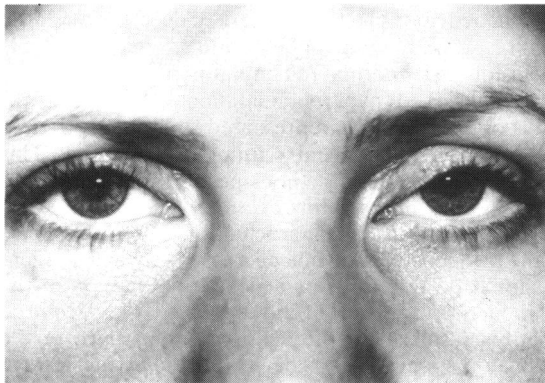

Fig. 6 Case 2: photograph shows results one year after bilateral upper eyelid blepharoplasty, external levator aponeurosis tuck, dermis fat graft, and lateral canthoplasty.

left upper eyelid, but an excellent cosmetic result was noted (Fig. 6).

Surgical specimens from the first two cases gave identical histopathological findings. The epidermis was focally thin. Occasional vacuolated basal cells were noted. Melanin laden macrophages were present in the upper dermis. Vessels in the upper dermis were dilated and focally surrounded by a scant number of mononuclear cells. Elastic tissue stains showed a decreased amount of elastic tissue in the papillary and upper reticular dermis. Middle and deep dermal elastic fibres were fragmented and focally clumped.

CASE 3

A 20-year-old woman had had repeated attacks of upper and lower eyelid oedema since her early teens, with gradual onset of ptosis. She was allergic to pollen, moulds, and coconuts, and she had received injections for allergy in the past. There was no family history of eyelid oedema or ptosis. She was in excellent health, and the results of a physical examination were normal with the exception of her eyelids. Blepharoptosis, excellent levator function, and high

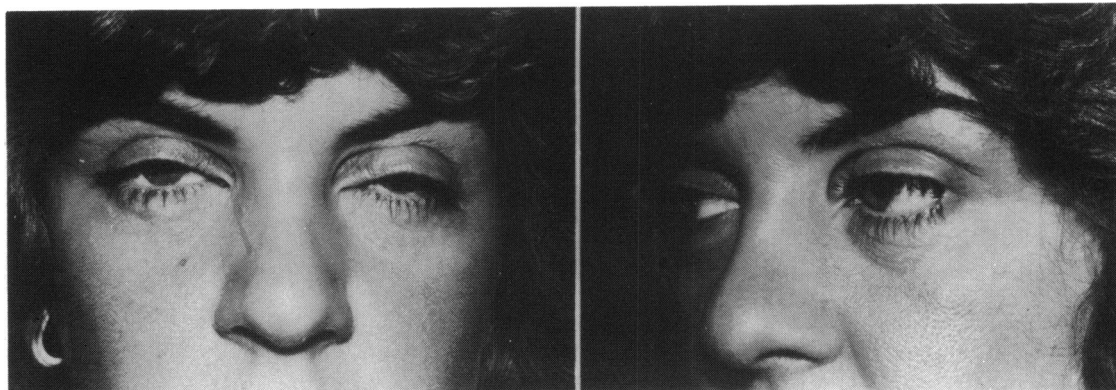

Fig. 7 Case 3: photograph (left) show ptosis, redundant, atrophic eyelid skin, and high superior tarsal lid crease. Lateral view (right) shows nasal fat pad atrophy, psuedoepicanthal fold, and rounded lateral canthal angle.

lid creases were noted (Fig. 7). Slight hyperpigmentation was present in the excess upper eyelid skin, which had fine wrinkling and telangiectasias. Atrophy of the superior nasal fat pads and pseudoepicanthal folds was prominent (Fig. 7). The lateral canthal tendon was dehiscenced. Four-lid blepharoplasty, external levator aponeurosis tuck, lateral canthoplasty, and dermal fat grafts to the superior nasal fat pockets corrected these abnormalities (Fig. 8).

CASE 4

A 13-year-old girl had multiple attacks of right and lower eyelid oedema for three years. In the spring she had trouble with allergies that were described as minor, and she was allergic to penicillin. There was no family history of similar problems. Her serum level of Cl esterase inhibitor was within normal limits. Right-sided wrinkling of the upper eyelid skin, upper eyelid ptosis, superior nasal fat pad atrophy, and lateral canthal tendon dehiscence were noted. These conditions were corrected by an upper eyelid blepharoplasty, external levator aponeurosis tuck, dermis fat graft, and lateral canthoplasty.

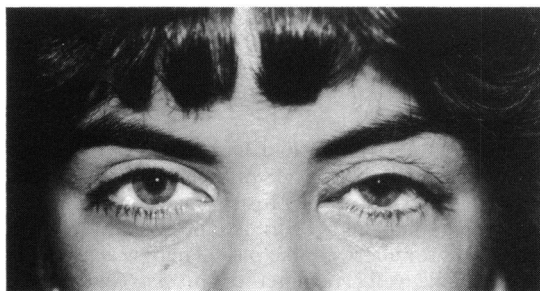

Fig. 8 Case 3: photograph shows results six months after four-lid blepharoplasty, external levator aponeurosis tuck, dermis fat graft, and lateral canthoplasty.

Discussion

Although our four cases occurred in women, blepharochalasis affects both sexes equally.⁸ It is a disease of young people, who have symptoms that usually begin in the teens and become less frequent after a number of years. Blepharochalasis is not a hereditary disease, though Ranjini *et al.* speculated that autosomal recessive inheritance had occurred in one case.⁹ The aetiology of the attacks of oedema is unknown. Patients who have angioneurotic oedema may develop signs of blepharochalasis,²⁵ but normal Cl esterase inhibitor levels ruled out this diagnosis in our cases.

Our histopathological findings correlated with the clinical picture and were similar to those in previous reports.^{5,24,26} In response to recurrent inflammation and dilatation, blood vessels are increased in number and luminal size. Dermal elastic fibres are decreased in number and fragmented. This change occurred in part as the result of mechanical distortion of these fibres by repeated episodes of stretching resulting from oedema. The focally marked decrease of elastic fibres, even in the papillary dermis, suggests specific elastolysis by dermal inflammatory cells. The clinically observed hyperpigmentation of the lids was histopathologically represented by upper dermal melanin being present within macrophages. This hyperpigmentation is a non-specific finding observed after many inflammatory disorders of the skin.

Treatment for blepharochalasis is surgical. Since the frequency of oedema decreases with age, surgery should be deferred for at least one year from the previous attack of eyelid oedema. The acquired ptosis results from stretching or dehiscence of the levator aponeurosis. The retraction of the levator aponeurosis elevates the eyelid crease because of the fascial connections from the aponeurosis to the skin. An external approach to the levator aponeurosis tuck

is recommended, because it offers better exposure of the abnormal anatomy and can be combined with an upper eyelid blepharoplasty through the same incision. By fixing the skin edges to the edge of the levator aponeurosis, normal symmetrical lid creases can be created. Local anaesthesia is preferred so that eyelid position can be adjusted readily at the time of surgery, decreasing the incidence of overcorrection that is common in the correction of acquired ptosis. In addition, through this incision a dermis-fat graft can be affixed to the periorbital in the superior nasal fat pocket with a double-armed 5-0 absorbable suture. More dermis than fat should be used; an additional 30% overcorrection usually gives an excellent cosmetic result. If there is redundancy of the lower eyelid skin, a lower eyelid blepharoplasty is performed in combination with a lateral canthoplasty. A lateral canthotomy, inferior cantholysis, and lateral full-thickness horizontal shortening of the eyelid may be performed if necessary. A 4-0 polypropylene suture is used to fixate the lateral edge of the tarsus to the periorbital near Whitnall's tubercle. This procedure will reform the lateral canthal angle.

The views expressed in this article are those of the authors and do not reflect the official policy or position of the Department of the Army, Department of Defense, or the US Government.

References

- 1 Tenzel RR, Stewart WB. Blepharo-confusion—Blepharochalasis or dermatochalasis? *Arch Ophthalmol* 1978; **96**: 911–2.
- 2 Beer IJ. *Lehre von den Augenkrankheiten, als Leitfaden, zu Seinen öffentlichen Vorlesungen entworfen*. Vienna: Huebner und Wolke: 1807; **2**: 109.
- 3 Fuchs E. *Ueber Blepharochalasis (Erschlaffung der Lidhaut)*. *Wien Klin Wochenschr* 1896; **9**: 109–10.
- 4 Collin JRO, Beard C, Stern WH, Schoengarth D. Blepharochalasis. *Br J Ophthalmol* 1979; **63**: 542–6.
- 5 Custer PL, Tenzel RR, Kowalczyk AP. Blepharochalasis syndrome. *Am J Ophthalmol* 1985; **99**: 424–8.
- 6 Older J. Levator aponeurosis disinsertion in the young adult. A Cause of ptosis. *Arch Ophthalmol* 1978; **96**: 1857–8.
- 7 Goldberg R, Seiff S, McFarland J, Simons K, Shorr N. Floppy eyelid syndrome and blepharochalasis. *Am J Ophthalmol* 1986; **102**: 376–81.
- 8 Alvis BY. Blepharochalasis. Report of a case. *Am J Ophthalmol* 1935; **18**: 238–45.
- 9 Ranjini G, Janaki C, Premalatha S, Zahra A. Blepharochalasis—a case report. *Indian J Dermatol* 1984; **29**: 35–8.
- 10 Heckel EB. Blepharochalasis with ptosis: report of a case. *Am J Ophthalmol* 1921; **4**: 273–5.
- 11 Stieglitz LN, Crawford JS. Blepharochalasis. *Am J Ophthalmol* 1974; **77**: 100–2.
- 12 Benedict WL. Blepharochalasis. Report of three cases. *JAMA* 1926; **87**: 1735–9.
- 13 Iliff CE. Dermatochalasis and blepharochalasis of the upper lids. *Ophthalmology* 1978; **85**: 709–11.
- 14 Friedenwald JS. Further note on blepharochalasis. *Arch Ophthalmol* 1923; **52**: 367–8.
- 15 Stieren E. Blepharochalasis—report of two cases. *Ann Ophthalmol* 1914; **23**: 625–32.
- 16 Eisenstodt LW. Blepharochalasis with double upper lip. *Am J Ophthalmol* 1949; **32**: 128–30.
- 17 Tapasztó L, Liszkaý L, Vass Z. Some data on the pathogenesis of blepharochalasis. *Acta Ophthalmol (Kbh)* 1963; **41**: 167–75.
- 18 Hadley HG. Dermatomolysis palpebrarum (blepharochalasis). *Rocky Mountain Med J* 1940; **37**: 517–9.
- 19 Castanares S. Classification of baggy eyelids deformity. *Plast Reconstr Surg* 1977; **59**: 629–33.
- 20 Finney JL, Peterson HD. Blepharochalasis after a bee sting. *Plast Reconstr Surg* 1984; **73**: 830–2.
- 21 Ghose S, Kalra BR, Dayal Y. Blepharochalasis with multiple system involvement. *Br J Ophthalmol* 1984; **68**: 529–32.
- 22 Verhoeff FH, Friedenwald JS. Blepharochalasis. *Arch Ophthalmol* 1922; **51**: 554–9.
- 23 Titche LL, O'Connor MJ. Blepharochalasis. *Am J Ophthalmol* 1951; **34**: 1314–6.
- 24 Brazin SA, Stern LJ, Johnson WT. Unilateral blepharochalasis. *Arch Dermatol* 1979; **115**: 479–81.
- 25 Gelfand JA, Boss GR, Conley CL, Reinhart R, Frank MM. Acquired Cl esterase inhibitor deficiency and angioedema. A review. *Medicine* 1979; **58**: 321–8.
- 26 Weidler WB. Blepharochalasis. Report of two cases with the microscopic examination. *JAMA* 1913; **61**: 1128–33.

Accepted for publication 20 August 1987.