

# Epithelial downgrowth: a 30-year clinicopathological review

MARK J WEINER,<sup>1</sup> JOSEPH TRENTACOSTE,<sup>2</sup> DAVID M PON,<sup>3</sup>  
AND DANIEL M ALBERT<sup>1</sup>

*From the <sup>1</sup>Massachusetts Eye and Ear Infirmary and Harvard Medical School; the <sup>2</sup>Bascom-Palmer Eye Institute; and the <sup>3</sup>Department of Ophthalmology, The University of Chicago, USA*

**SUMMARY** We performed a retrospective clinicopathological review of 124 patients with epithelial downgrowth seen over a 30-year-period at the Massachusetts Eye and Ear Infirmary. The purpose of this study was to determine predisposing factors in the development of epithelial downgrowth, diagnostic symptoms and signs, and the results of various types of treatments. The incidence of this condition after cataract surgery was 0.12%, decreasing to 0.08% over the latter decade. 82% of postsurgical patients with epithelial downgrowth presented to the ophthalmologist within one year following surgery, commonly complaining of decreasing visual acuity, red eye, and pain. The most common presenting signs of epithelial downgrowth were retrocorneal membrane, which was seen in 45% of patients, glaucoma in 43%, corneal oedema in 21%, and a positive Seidel test in 23%. We found that a variety of conditions predispose to epithelial downgrowth but that no one factor was present in all cases. Damage to the underlying endothelium, corneal stromal vascularisation, and stromal downgrowth appeared to be important events not emphasised in prior studies. The angle was partially or totally closed in 87% of enucleation specimens. Patients treated surgically underwent fewer enucleations than those treated medically or not treated.

Epithelial downgrowth is a serious though relatively uncommon complication of ocular surgery and trauma which frequently results in blindness from intractable glaucoma. In the older literature 17–26% of all enucleations after cataract surgery are reported to be due to this complication.<sup>1–7</sup> Treatment of it has met with little success despite attempts with a variety of methods.

We reviewed all cases of epithelial downgrowth histologically diagnosed in the David G Cogan Eye Pathology Laboratory at the Massachusetts Eye and Ear Infirmary (MEEI) over a 30-year period. The object of this study was to re-evaluate and update the known predisposing factors in the development of epithelial downgrowth, diagnostic symptoms and signs, and the results of various types of treatments.

## Materials and methods

One hundred thirty-nine cases of epithelial down-

growth recorded in the files of the David G Cogan Eye Pathology Laboratory at the MEEI from January 1953 to May 1983 were reviewed, and pathological specimens were examined to confirm the diagnosis. The specimens examined histopathologically are listed in Table 1. Fifteen cases diagnosed clinically to have epithelial downgrowth could not be confirmed histologically from available slides and were excluded.

The medical records of all histologically confirmed cases were reviewed. The patient's age, sex, type of surgical procedure or trauma, length of time before clinical presentation, presenting signs and symptoms, concurrent illnesses, medications, and visual acuity at the time of enucleation were recorded. The operative notes of patients who had undergone surgery were reviewed for type and number of sutures, presence and type of conjunctival flap, and operative complications. The patients' ophthalmologists were contacted for clinical findings on follow-up visits. Details of various modes of therapy used in the treatment of epithelial downgrowth, as well as the results and the amount of follow-up, were compiled.

Correspondence to Daniel M Albert, MD, Massachusetts Eye and Ear Infirmary, 243 Charles Street, Boston, Massachusetts 02114, USA.

Table 1 Specimen type used to confirm diagnosis of epithelial downgrowth

Specimen type	Surgical % of patients eyes		Trauma % of patients eyes	
Corneal button alone	28	26	2	11
Iridectomy alone	21	20	0	0
Iridectomy followed by enucleation*	6	6	1	6
Enucleation alone	33	31	13	72
Anterior chamber tap alone	10	9	2	11
Anterior chamber tap followed by enucleation*	2	2	0	0
Iridectomy and corneal button*	4	4	0	0
Iridectomy and anterior chamber tap*	2	0	0	0
Total	120	100	19	100

\*Counted as two specimens in total.

The pathological specimens were reviewed and evaluated for: appearance and organisation of the epithelium, location and extent of downgrowth, and the presence of an unclosed wound or fistula, incarcerated tissue, stromal vascularisation, or synechiae. The presence of partial or complete angle closure and the depth of the anterior chamber were recorded as well.

## Results

One hundred twenty-four histopathologically confirmed cases of epithelial invasion of the anterior chamber were seen at the MEEI between January 1953 and May 1983. Of these, 106 followed surgical procedures and 18 ocular trauma. Table 2 details the surgical procedures which preceded epithelial downgrowth.

## EPIDEMIOLOGY

The ratio of males to females was 1:1.7 in the surgical group and 3.5:1 in the trauma group. The age at the time of surgery ranged from 3 to 89 years. Sixty-eight of the 106 surgical patients were over the age of 60. In contrast, the post-trauma patients ranged from 10 to 58 years of age at the time of trauma, with a mean of 26 years. Although there was approximately equal involvement of the right and left eye in the surgical group (54 vs 52), the right eye was twice as frequently involved in the trauma group (12 vs 6).

A total of 44 496 cataract extractions were performed at the MEEI between January 1953 and May 1983, 22 272 of which were completed between January 1973 and May 1983. Fifty-four of the patients with epithelial downgrowth after cataract extraction over the entire 30-year period and 17 over the last decade were operated on at the MEEI. Thus the minimum incidence of epithelial downgrowth after

Table 2 Surgical procedures preceding epithelial downgrowth

Surgery	Number of % eyes	
Intracapsular cataract extraction	76	72
Planned extracapsular cataract extraction	9	8
Unplanned extracapsular cataract extraction	6	6
Penetrating keratoplasty	13	12
Pterygium excision	1	1
Aspiration of aqueous	1	1
Total	106*	100

\*Includes two patients with bilateral epithelial downgrowth.

cataract extraction at the MEEI over the entire 30-year period was 0.12%, dropping to 0.076% in the last decade. 75% of patients presented to the clinician with epithelial downgrowth within the first six postoperative months, with a mean of five months (Fig. 1).

## CLINICAL REVIEW

Of the surgical cases 11% were noted to have operative complications at or immediately following surgery. Of these, 50% had vitreous loss. Persistent hypotony, lens capsule rupture, inadvertent filtering bleb, and anterior chamber haemorrhage were also reported. Of those who had epithelial downgrowth following cataract extraction conjunctival flaps were limbal based in 16% and fornix based in 52%. In 32% the data were not available. The fornix based flap was most commonly used at MEEI; however, the exact number of limbus vs fornix based flaps during this 30-year period was not obtainable.

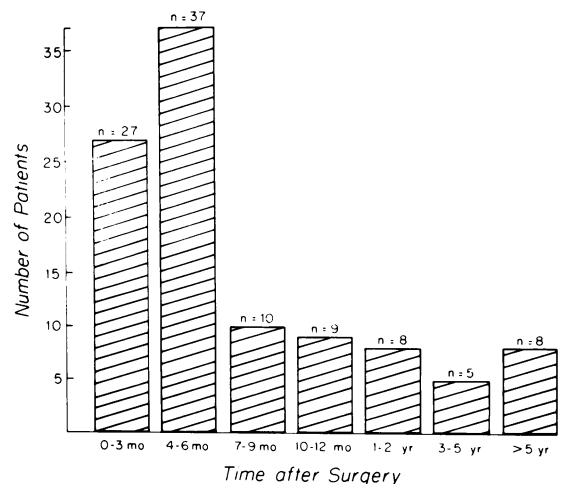


Fig. 1 Time to presentation with epithelial downgrowth after ocular surgery.

Table 3 Presenting chief complaint in patients with epithelial downgrowth

Symptom	Surgical patients	%	Trauma patients	%
Decreasing visual acuity	35	34	6	33
Red eye	19	18	2	11
Pain (without glaucoma)	14	13	7	39
Tearing	6	6	0	0
Photophobia	2	2	2	11
Foreign body sensation	2	2	1	6
Flashes of light	1	1	0	0
No symptoms recorded	25	24	0	0
Total	104	100	18	100

Five of the postsurgical patients were taking anti-coagulants for phlebitis and pulmonary embolism. No other medication was identified as affecting the development of epithelial downgrowth.

Visual acuity at the time of enucleation was less than 20/200 in all cases. The reason for enucleation of eyes was painful glaucoma in a blind eye in the majority of patients. The presenting chief complaints from patients with epithelial downgrowth are itemised in Table 3, while the presenting signs are detailed in Table 4.

#### PATHOLOGY

Epithelial downgrowth was most often found in the form of sheets of cells, less commonly in cysts or as scattered islands of cells. All enucleations were of eyes with epithelial downgrowth in the form of sheets alone or sheets and cysts. In 17 of the postsurgical specimens surface epithelium extended through the wound and into the anterior chamber. The most

Table 4 Presenting signs in patients with epithelial downgrowth\*

Sign	Surgical patients	%	Trauma patients	%
Retrocorneal membrane	48	46	1	6
Painful glaucoma	32	31	4	22
Positive Seidel test	24	23	1	6
Corneal oedema	22	21	4	22
Hypotony	17	16	4	22
Painless glaucoma	14	13	1	6
Iritis	11	11	1	6
Pupillary distortion	10	10	2	11
Iris cyst	8	8	1	6
Anterior chamber cyst	8	8	6	33
Discharge	5	5	1	6
Band keratopathy	5	5	3	17
Bullous keratopathy	3	3	0	0
Flat anterior chamber	2	2	0	0
Iris whitening on photocoagulation	2	2	0	0
Retinal detachment	1	1	1	6
Vitreous haze	1	1	0	0

\*Many patients had more than one sign of epithelial downgrowth.

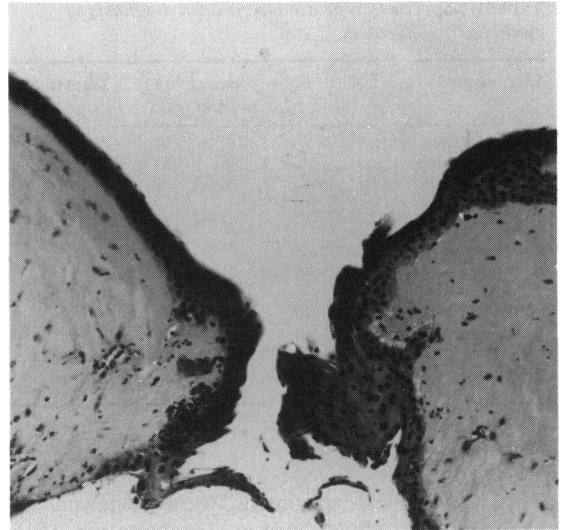


Fig. 2 Fistulous wound lined with downgrowing epithelium. H and E,  $\times 60$ .

typical finding consisted of one to three layers of stratified non-keratinised squamous epithelium of conjunctival or corneal origin extending over the posterior cornea and on to the anterior iris (Figs. 2, 3). Unfortunately the source of the epithelium could not be certainly identified in the majority of the specimens because of limited tissue for further

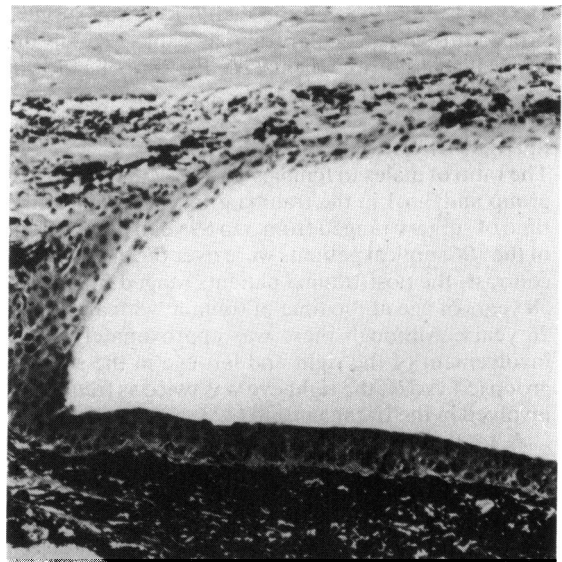


Fig. 3 Epithelium growing on posterior surface of cornea, across the angle, and on to the anterior surface of the iris. H and E,  $\times 65$ .

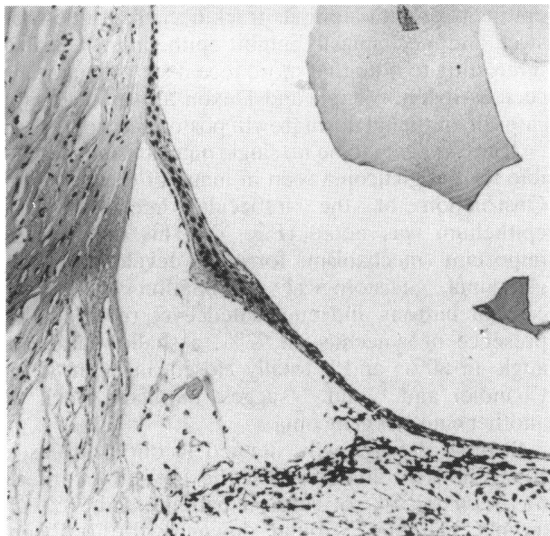


Fig. 4 Epithelium growing across the angle. H and E,  $\times 57$ .

studies. Obstruction of the trabecular meshwork was noted in several cases (Fig. 4). Table 5 lists the findings in corneal button and enucleation specimens.

#### TREATMENT

We recorded the course of 75% of the postsurgical patients for a three-year period. 62% of these patients were treated surgically, 11% were treated medically, and the remainder had no therapy. Surgical treatments included excision of downgrowth, iridectomy, cryotherapy, cautery, vitrectomy, penetrating keratoplasty, cyst aspiration, and photocoagulation. Medical treatments included radiation therapy, alcohol and potassium

chloride swabbing, steroids, and antibiotics. Many of the patients were treated with more than one mode of therapy. 63% of the surgically treated eyes had excision of the downgrowth, and 50% of those eyes also had an iridectomy. Penetrating keratoplasty was performed in 29% of surgically treated eyes. In most cases medical therapy consisted of topical and systemic steroids and antibiotics.

Of the post-surgical patients 52% eventually underwent enucleation. Only 19% of patients treated with surgical excision and iridectomy resulted in enucleation. 21% of patients treated with penetrating keratoplasty had enucleations. All patients treated medically and 95% of those with no therapy indicated in the chart had enucleations.

#### Discussion

Epithelial invasion of the anterior chamber has been reported most frequently after cataract surgery and ocular trauma, though its occurrence after penetrating keratoplasty,<sup>8-10</sup> pterygium removal, aspiration of aqueous, and passage of a transcorneal (McCannel) suture<sup>11</sup> has been noted. This study confirms the results of earlier reports with 86% of our cases occurring after cataract extraction and 12% after penetrating keratoplasty.

The incidence of reported cases of epithelial downgrowth following surgical procedures over the 30-year study period at MEEI was calculated to be 0.12%, decreasing to 0.076% over the latter decade. This trend confirms an earlier but smaller study by Christensen, who observed a decrease over a 20-year period at the University of Oregon.<sup>7</sup> The decrease in the rate of occurrence may be due to improved surgical technique with the development of microsurgical instrumentation and improved suture material resulting in better wound closure.

A fistulous wound may predispose to epithelial downgrowth by facilitating egress of epithelial tissue. In corneal button and enucleation specimens we found that only 18% of the postsurgical patients had incarceration of iris or lens capsule in the wound. However, fistulous wounds were present in 26% of postsurgical patients and 56% of post-trauma patients. As might be expected, a higher incidence of uveal tissue was noted intracorneally after trauma than after surgery. Our results contrast with an earlier study by Allen and Duehr,<sup>12</sup> who found incarceration in 17 of 20 postsurgical patients. We saw several examples of invading epithelium in suture tracks consistent with those described by Dunnington and Regan.<sup>13</sup>

The biochemical and physical substrate necessary for epithelial growth in the anterior chamber has been debated by previous investigators. Experi-

Table 5 Findings in corneal button and enucleation specimens

Finding	Surgical		Trauma	
	% of patients	% of specimens	% of patients	% of specimens
Fistula	19	26	9	56
Stromal vascularisation	65	89	15	94
Stromal downgrowth	40	55	6	38
Shallow anterior chamber*	37	90	10	71
Normal anterior chamber*	4	10	4	29
Peripheral anterior synechiae	52	71	12	75
Incarcerated iris	11	15	4	25
Incarcerated lens capsule	2	3	1	6
Open angle*	4	10	3	21
Closed angle*	37	90	11	79
Foreign body	0	0	1	6

\*Determined only in enucleated specimens.

mental studies have shown that aqueous alone cannot support the growth of epithelium.<sup>14</sup> While we found that cellular growth on the anterior iris was more luxuriant than on the posterior cornea, averaging three to five cell layers in thickness, in 19% of our postsurgical cases, there was no epithelial downgrowth on the iris.

Stromal vascularisation was seen in 89% of the corneal and enucleation specimens from postsurgical patients and in 94% of the trauma patients. Several eyes had areas of stromal vascularisation up to 6 mm from the wound, but the majority of blood vessels were situated along the tract of the wound. We suggest that stromal vascularisation appears to be an important source of nutrition for the downgrowing epithelium. The influence of the vascularity of the substrate on which epithelium grows has been previously noted by Cogan.<sup>15</sup>

While wound fistula and stromal vascularisation are thought to promote epithelial downgrowth, experimental evidence suggests that the presence of endothelium inhibits epithelial growth in organ culture through direct intercellular interactions.<sup>16</sup> Fry<sup>17</sup> had observed an absence of marked degeneration of corneal endothelial cells in six cases of epithelial downgrowth, even in places where the endothelium was not covered by invading epithelium. Our study has shown attenuation or disruption of endothelium in most cases in which the epithelium has migrated to the posterior cornea, supporting the conclusions of Cameron *et al.*<sup>16</sup> We could not determine whether the endothelial disruption preceded or resulted from the epithelial downgrowth.

Dunnington<sup>18</sup> believed that the use of corneoscleral sutures in cataract extraction was responsible for a higher incidence of epithelial downgrowth. However, Allen and Duehr<sup>12</sup> reviewed 5246 cataract operations and found that multiple corneoscleral sutures did not increase the incidence of downgrowth. We found that efficient closure of the incision with improved surgical technique and instrumentation appears to decrease the incidence of epithelial downgrowth, while the number of sutures used did not appear to be an important factor.

We made note of the type of suture material used during surgery to determine whether this was a risk factor. Dunnington and Regan<sup>19</sup> noted rapid proliferation of epithelium along the track of silk suture but not along surgical gut. In another study Dunnington and Regan<sup>13</sup> stated that epithelial downgrowth was produced when silk sutures were used, but could not be produced with surgical gut. Our data show no difference in the incidence of downgrowth after the use of either suture type. This is somewhat surprising when one reasons that silk favours

epithelial growth along its track because it does not swell and mechanically inhibit epithelium. It is also interesting to note that more recent suture materials such as nylon, Vicryl, and Dexon also had several cases of epithelial downgrowth postoperatively.

There appears to be no single mechanism responsible for the glaucoma seen in many of our patients. Obstruction of the trabecular meshwork by epithelium was noted (Fig. 4). This may be an important mechanism for the development of glaucoma.<sup>20</sup> Histological examination of all the corneal buttons and enucleated eyes revealed the presence of synechiae in 73%, a shallow anterior angle in 80%, and a totally closed angle in 85%. Chandler and Grant<sup>21</sup> suggest pupillary block as another cause of glaucoma.

Stromal downgrowth, defined in our study as a collagenous proliferation on the posterior cornea, was seen in 55% of surgical patients and 38% of trauma patients. Stromal downgrowth has been previously reported after trauma<sup>22</sup> and surgery.<sup>7,19,23</sup> Allen<sup>5</sup> found 36% of eyes enucleated after cataract extraction had stromal downgrowth and similar findings were reported by Dunnington.<sup>23</sup> To our knowledge there are no previous reports of the presence of stromal downgrowth in cases of epithelial downgrowth. Our results indicate that, although stromal downgrowth occurs more commonly than does epithelial downgrowth following surgery or trauma,<sup>5</sup> it is associated with epithelial downgrowth in only 38 to 55% of cases.

The source of epithelium for downgrowth is probably conjunctival in most cases. While we were often unable to differentiate conjunctival from corneal epithelium, none of the patients who underwent a planned or unplanned extracapsular cataract extraction showed evidence of lens epithelial migration. We consider it is highly unlikely that lens epithelium is a source of epithelium for downgrowth.

Epithelialisation of the anterior chamber can occur in the form of sheets or cysts; individual cells seen on anterior chamber taps have separated from sheets or cysts. 93% of surgical cases and 78% of traumatic cases had at least some epithelial downgrowth in the form of sheets. When analysing enucleated eyes we found that all enucleations had epithelial downgrowth in the form of sheets. This confirms the belief that patients with cysts tend to have a better prognosis<sup>24</sup> or respond to treatment more favourably than do patients who have sheets of epithelial downgrowth.

Binder and Binder<sup>25</sup> and Bick<sup>26</sup> found that when the prothrombin levels was less than 30% of normal there was inhibition of early fibroblast formation, allowing the epithelium to grow freely down the wound and into the anterior chamber. Five of our

postsurgical patients were anticoagulated for phlebitis and pulmonary embolism, raising the possibility that anticoagulants may adversely affect epithelial downgrowth patients. No other medication was identified as affecting the development of epithelial downgrowth.

Various surgical and medical techniques have been devised for treatment of epithelial downgrowth.<sup>27-32</sup> Despite extensive attempts by many investigators the prognosis even with treatment remains bleak, most eyes having a visual acuity of 20/200 or worse postoperatively.<sup>29,30</sup> Our study confirms the poor prognosis in this disease, though it does suggest that treatment improves outcome in some cases. No single method of treating the epithelial downgrowth could be singled out as being the most effective. However, those eyes treated with at least some surgical technique fared better than those treated by antibiotics or steroids alone. The latter group had enucleated eyes in eight out of 10 cases. Admittedly this better outcome may reflect biased case selection for operative intervention. Some of the patients treated by surgical procedures developed postoperative complications including glaucoma, corneal oedema, and hypotension, though it is not clear how many resulted from the presence of intraocular epithelium as opposed to the surgical treatment. Other authors have also reported complications such as vitreous haze, retinal detachment, ciliary body detachment, hyphaema, vitreous haemorrhage, and a residual fistula. A recently developed animal model confirms that destruction of all invading epithelium is difficult.<sup>33</sup> Perhaps new therapeutic methods employing antimetabolites together with surgical intervention will prove effective in halting, if not eradicating, this disease process.

This work was supported in part by NEI EY01917 (Dr Albert) and by the Heed Ophthalmic Foundation (Dr Weiner).

#### References

- Schulze R, Duke J. Causes of enucleation following cataract extraction. *Arch Ophthalmol* 1965; **73**: 74-9.
- Paufique L, Hervouet F. L'invasion épithéliale de la chambre antérieure après opération de cataracte. *Ann Oculist (Paris)* 1964; **197**: 105-29.
- Blodi F. Failures of cataract extractions and their pathologic explanation. *J Iowa Med Soc* 1954; **44**: 514-6.
- Dunnington J. Ocular wound healing with particular reference to the cataract incision. *Arch Ophthalmol* 1956; **56**: 639-59.
- Allen J. Epithelial and stromal ingrowths. *Am J Ophthalmol* 1968; **65**: 179-82.
- Payne B. Epithelialization of the anterior segment II. *Am J Ophthalmol* 1958; **45**: 182-4.
- Christensen L. Epithelialization of the anterior chamber. In: Boyd BF, Christensen L, Irvine AR Jr, et al., eds. *Symposium on cataracts*. St Louis: Mosby, 1965: 219-25.
- Leibowitz HM, Elliott JH, Boruchoff SA. Epithelialization of the anterior chamber following penetrating keratoplasty. *Arch Ophthalmol* 1967; **78**: 613-7.
- Sugar A, Meyer RF, Hood CI. Epithelial downgrowth following penetrating keratoplasty in the aphake. *Arch Ophthalmol* 1977; **95**: 464-7.
- Bennett T, D'Amico RA. Epithelial inclusion cyst of iris after keratoplasty. *Am J Ophthalmol* 1974; **77**: 87-9.
- Abbott RL, Spencer WH. Epithelialization of the anterior chamber after transcorneal (McCannel) suture. *Arch Ophthalmol* 1978; **96**: 482-4.
- Allen J, Duehr P. Sutures and epithelial downgrowth. *Am J Ophthalmol* 1968; **66**: 293-4.
- Dunnington J, Regan E. The effect of sutures and of thrombin upon ocular wound healing. *Ophthalmology* 1951; **55**: 761-72.
- Regan E. Epithelial invasion of the anterior chamber. *Trans Am Ophthalmol Soc* 1957; **55**: 741-72.
- Cogan D. Experimental implants of conjunctiva into the anterior chamber II. *Am J Ophthalmol* 1955; **39**: 165-72.
- Cameron JD, Flaxman BA, Yanoff M. In vitro studies of corneal wound healing: epithelial-endothelial interactions. *Invest Ophthalmol Vis Sci* 1974; **13**: 575-9.
- Fry W. In discussion of Perera CA. Epithelium in the anterior chamber of the eye after operation and injury. *Ophthalmology* 1937; **42**: 164.
- Dunnington J. Ocular wound healing with particular reference to cataract incision. *Trans Ophthalmol Soc UK* 1955; **75**: 137-71.
- Dunnington J, Regan E. Absorbable sutures in cataract surgery. *Arch Ophthalmol* 1953; **50**: 545-56.
- Terry T, Chisholm A, Schonberg A. Studies on surface-epithelium invasion of the anterior segment of the eye. *Am J Ophthalmol* 1939; **22**: 1083-110.
- Chandler P, Grant W. *Lectures on glaucoma*. Philadelphia: Lea and Feibiger, 1965: 243.
- Levkoieva E. The regeneration of wounds of external membrane of the eye in the light on new pathologico-anatomical results. *Br J Ophthalmol* 1947; **31**: 336-61.
- Dunnington J. Wound rupture with tissue incarceration. In: Haik GM, ed. *Symposium on diseases and surgery of the lens*. St Louis: Mosby, 1957: 161.
- Harbin T, Maumenee A. Epithelial downgrowth after surgery for epithelial cyst. *Am J Ophthalmol* 1974; **78**: 1-4.
- Binder R, Binder H. Experimental Untersuchungen bei den Einfluss von Antocoagulantien auf die Heilung von Hornhautschnittwunden. *Graefes Arch Clin Exp Ophthalmol* 1954; **155**: 337-44.
- Bick M. Heparinization of the Eye. *Am J Ophthalmol* 1949; **32**: 663-70.
- Verhoeff F. In discussion of paper by Vail D. Epithelial downgrowth into the anterior chamber following cataract extraction arrested by radium treatment. *Trans Am Ophthalmol Soc* 1935; **33**: 306.
- Maumenee A. Epithelial invasion of the anterior chamber. *Ophthalmology* 1957; **61**: 51-7.
- Stark W, Michaels R, Maumenee A, Cupples H. Surgical management of epithelial ingrowth. *Am J Ophthalmol* 1978; **85**: 772-80.
- Brown S. Treatment of advanced epithelial downgrowth. *Ophthalmology* 1973; **77**: 618-22.
- Sugar H. Further experience with posterior lamellar resection of the cornea for epithelial implantation cyst. *Am J Ophthalmol* 1967; **64**: 291-9.
- Brown S. Results of excision of advanced epithelial downgrowth. *Ophthalmology* 1979; **86**: 321-8.
- Burris TE, Nordquist RE, Rowsey JJ. Cryopexy of epithelial downgrowth. *Cornea*, in press.